

# Generalized epilepsies: a review<sup>1</sup>

Hans Lüders, M.D., Ph.D.  
Ronald P. Lesser, M.D.  
Dudley S. Dinner, M.D.  
Harold H. Morris III, M.D.

**In this discussion of the pathophysiology of generalized seizures, the authors conclude that current evidence supports a primarily cortical origin, and that there is a continuum between strictly partial seizures at one end of the spectrum and definite generalized seizures at the other. Typical interictal electroencephalogram (EEG) patterns seen in patients with generalized seizures and their clinical correlations are discussed, and the ictal EEG patterns are subdivided according to their relationship to interictal EEG patterns. Special tests, such as sleep, photic stimulation, hyperventilation, evoked potentials, computer analysis, and prolonged EEG video-monitoring, which enhance diagnostic ability, are reviewed.**

**Index terms:** Epilepsy • Seizures

**Cleve Clin Q** 51:205-226, Summer 1984

The International Federation of Societies for Electroencephalography and Clinical Neurophysiology (IFSECN)<sup>1</sup> classification of seizures distinguishes two main groups: (a) generalized, and (b) partial.

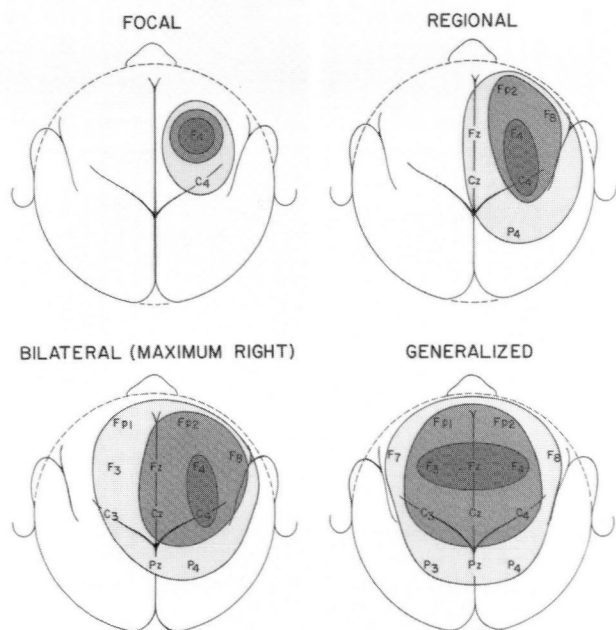
In partial seizures, only a limited portion of the brain is involved whereas in generalized seizures, the brain is affected diffusely. In extreme cases, these two groups can be clearly differentiated, e.g., focal motor seizures with no secondary generalization vs. generalized tonic-clonic seizures with no aura and apparently bilateral, bisynchronous EEG onset. Most seizures, however, fall somewhere between these extremes. Moreover, focal seizures tend to trigger secondary generalized seizures, and differentiation is particularly difficult when the focal component is of short duration. In some patients, all clinical seizures are

---

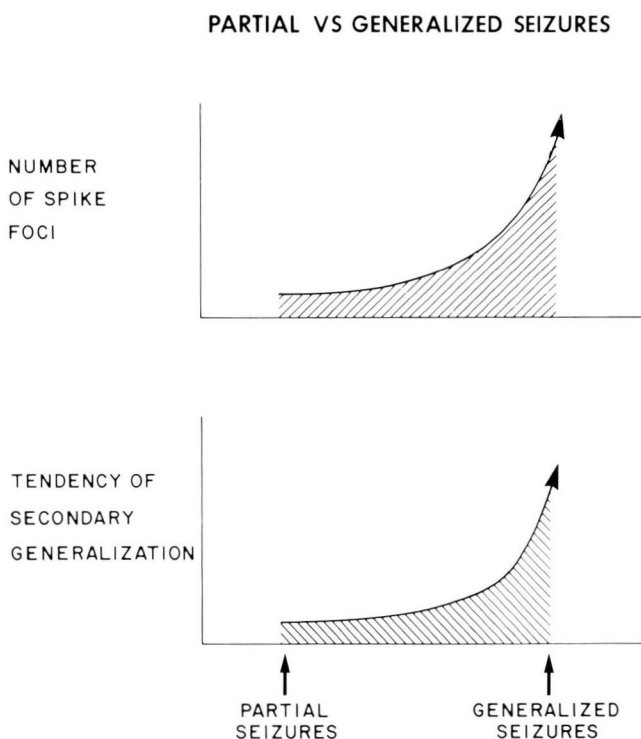
<sup>1</sup> Department of Neurology (H.L., R.P.L., H.H.M.) and Plastic Surgery (D.S.D.), The Cleveland Clinic Foundation. Submitted for publication and accepted Oct 1983.

0009-8787/84/02/0205/22/\$5.95/0

Copyright © 1984 by the Cleveland Clinic Foundation



**Fig. 1.** Continuum between partial seizures (upper left) and generalized seizures (lower right), showing the distribution map of interictal epileptiform discharges. Darkened area = 90%–100% of the maximum amplitude of spike; area within the darkest circle = more than 80% of the maximum amplitude of the spike.



**Fig. 2.** Continuum between partial and generalized seizures, depending on the number of spike foci and tendency toward secondary generalization.

apparently of generalized onset and their focal nature can be detected only by EEG studies and/or videotape monitoring. In those with two epileptogenic foci and a marked tendency to secondary generalization, the distinction between partial and generalized is usually impossible. Multiple (three or more) epileptogenic foci almost invariably result in secondary generalization, and these cases are usually classified as generalized seizures. Two conclusions can be drawn from these observations:

- (a) It is frequently impossible to distinguish clearly between partial and generalized seizures. There appears to be a continuum between clear-cut partial seizures at one end of the spectrum and generalized seizures at the other (Fig. 1), most falling somewhere in between.
- (b) If we move along the spectrum from partial toward generalized seizures, we can conclude, by extrapolation, that “generalized” seizures are actually multifocal seizures with an extreme tendency for secondary generalization (Fig. 2). This concept will be discussed in detail later.

From the surgeon’s point of view, however, a clear line must be drawn between “partial” and “generalized” seizures, i.e., will resection of a limited area of cortex abolish the seizures or not? The affirmative implies that (a) all seizures are triggered from one focus, and (b) there are no other secondary foci capable of triggering seizures after resection of the primary focus. These surgical criteria can occasionally be met even in the presence of a marked tendency for secondary generalized seizures.

Influenced by these surgical criteria and the concept of a continuum, we use the following practical subdivision of seizures:

- (a) *Partial seizure disorder:* Electroclinical information indicates that resection of a limited area of cortex would abolish the seizures, e.g., left mesial temporal focus.
- (b) *Generalized seizure disorder:* Electroclinical evidence indicates that resection of even an extensive area of cortex would not abolish the seizures.

**Pathophysiology of generalized seizures**

Modern theories of the pathogenesis of generalized spike and wave complexes began with Penfield and Jasper<sup>2</sup> (Fig. 3). They assumed that primary “generalized” seizures (e.g., generalized absences) are essentially secondary to a focal ab-

normality in poorly defined, deep-seated midline gray structures called the "centrencephalon." In other words, the group most famous for pioneering surgical treatment of focal cortical epilepsy suggested that "generalized" epilepsy is an expression of a fairly focal subcortical triggering mechanism. In the words of Jasper and Kershman:<sup>3</sup>

The sudden loss of consciousness (in an absence) is a form of onset comparable to "tingling of one hand" in a patient with cortical focal seizures. In cases of focal cortical onset, minor attacks may be noted as "whirling lights" when the epileptic discharge is confined to the occipital lobe. Minor attacks of the bilaterally synchronous 3/sec wave and spike form are associated with loss of consciousness when the discharge is confined to centers (or circuits) primarily concerned with this function.

The following observations constitute the basis for the centrencephalic theory:

- (a) The cortical epileptiform discharges seen in primary generalized seizures tend to be generalized and almost perfectly bilaterally synchronous from the beginning.
- (b) Stimulation of deep-seated midline gray nuclei can produce bilateral synchronization of the EEG,<sup>4</sup> and under appropriate conditions, bursts of spike and slow wave complexes.<sup>5</sup>

The most vocal arguments against the centrencephalic theory came almost two decades later from the same Montreal group, now under the leadership of Peter Gloor<sup>6</sup> (*Fig. 4*) and can be summarized as follows:

- (a) Intracarotid injection of convulsants (Metrazol) produces generalized 3-Hz spike and wave complexes and clinical absences. Intravertebral injection of convulsants has no effect or arrests seizures.<sup>6,7</sup>
- (b) Diffuse cortical application of penicillin produces generalized 3-Hz spike and wave complexes in relatively low concentration whereas its injection into subcortical gray structures does not.<sup>8</sup>

From the latter observation, Gloor<sup>6</sup> concluded that diffuse "hyperexcitability" of the cortex is an essential factor in the pathogenesis of generalized seizures. However, he did not totally discard his preceptor's concept of the centrencephalon. He was impressed by the sudden onset and abrupt termination of generalized bursts of 3-Hz spike and wave complexes that resemble the turning on and off of a light switch. Looking for a pacer-

maker mechanism, he was able to demonstrate that, in cats pretreated with penicillin I.M. (to produce diffuse hyperexcitability), bursts of 3-Hz spike and wave complexes were triggered most readily from the same deep-seated, nonspecific midline gray structures that produced the recruiting response. He postulated, therefore, that primary generalized seizures are produced by an abnormal interplay of both, namely, cortex and subcortical midline gray structures (reticulo-cortical theory). He did not commit himself directly, but the obvious implication is that generalized seizures result from hyper-reactivity of the cortex to afferent impulses from the midline subcortical gray structures, which act as trigger (or pacer-maker) mechanisms. In a recent article,<sup>6</sup> he stated:

The concept (of reticulo-cortical epilepsy) can be summarized as follows: There is a mild diffuse epileptogenic state of the cortex. The cortex is hyperexcitable and responds by elaborating spike and wave discharges preferentially, but not exclusively, to volleys that originate from the thalamus, particularly those that normally produce spindles and recruiting response.

This reticulo-cortical theory is currently the most widely accepted.

Although Gloor's work in cats is certainly convincing, there is no need to attribute an active pathogenetic role to the subcortical gray structures, as the name "reticulo-cortical epilepsy" implies. We believe that the evidence primarily suggests that generalized epilepsies are an expression of a pathological degree of diffuse cortical epileptogenicity (*Fig. 5*). Subcortical gray structures certainly participate in bilateral synchronizing mechanisms and in diffuse modulation of cortical activity. However, there is no evidence to suggest that these physiological cortico-subcortical mutual interactions are pathological in patients with generalized seizures.

The following points support the cortical theory:

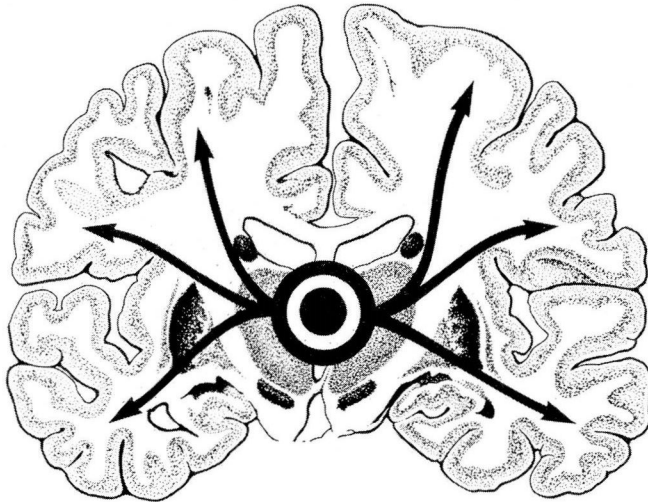
- (a) Gloor's evidence<sup>6</sup> of diffuse cortical hyperexcitability supports the cortical theory directly (see above).
- (b) Focal cortical epileptogenic lesions can produce generalized spike and wave complexes and generalized seizures without evidence of subcortical gray structure lesions, for example, mesial frontal lesions.<sup>9,10</sup> In these cases, interictal focal spikes were recorded from the mesial frontal region, stimulation of the focus produced seizures, and resec-



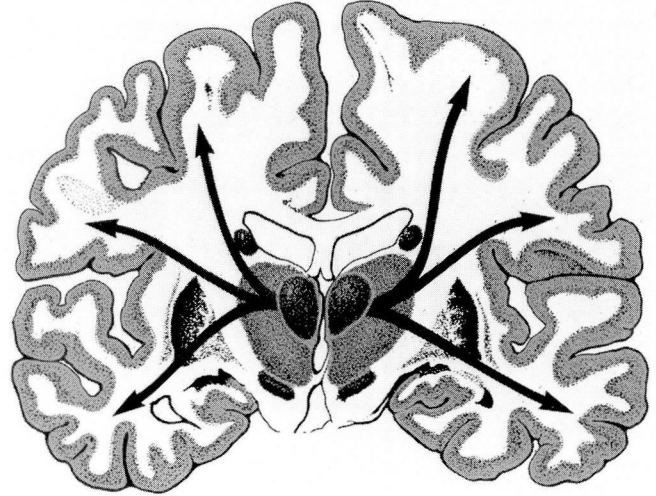
### CENTRECEPHALIC THEORY PENFIELD AND JASPER

### CORTICO-RETICULAR THEORY GLOOR

3



4



### CORTICAL THEORY

5

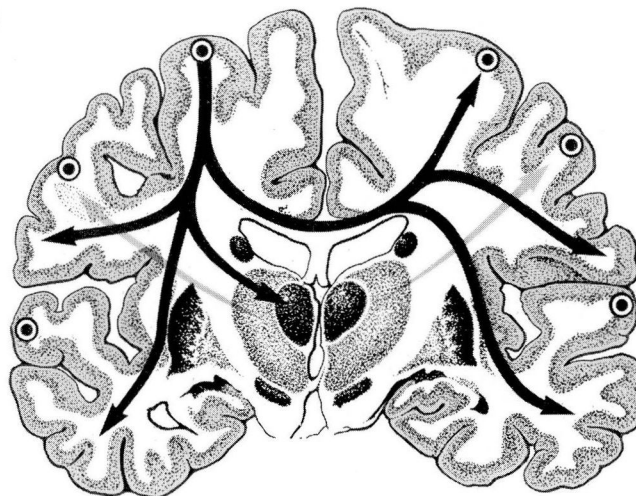

Fig. 3. Centrecephalon theory<sup>2</sup>

Fig. 4. Cortico-reticular theory<sup>6</sup>

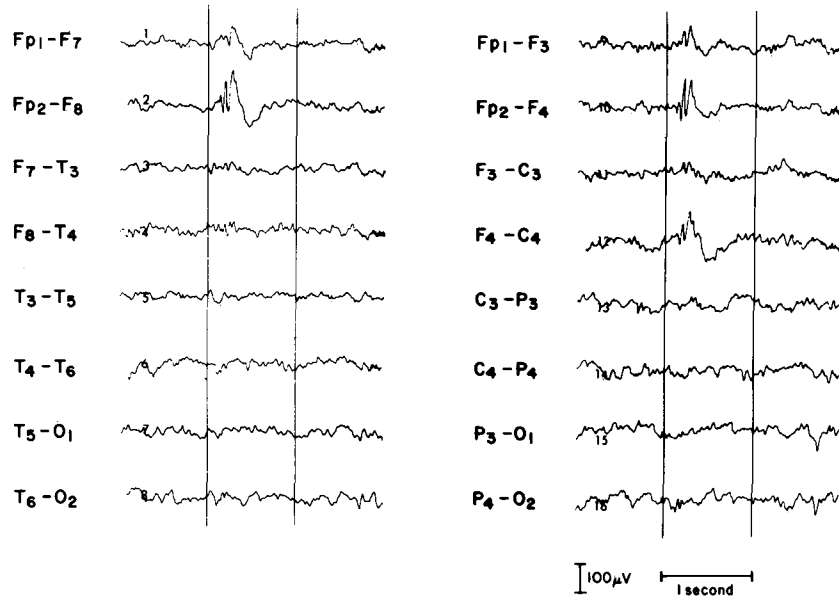
Fig. 5. Cortical theory

tion of the focus abolished the clinical seizures, none of which has been demonstrated in subcortical gray structures. Focal lesions of the subcortical gray structures are not accompanied by epilepsy.

- (c) Patients with generalized seizures frequently exhibit focal epileptiform discharges (Figs. 6-8), mostly in the frontocentral regions and shifting from one hemisphere to another. Occasionally, these discharges involve other regions, but always shift from one hemi-

sphere to another. Figures 9, 10, and 11 show the distribution of interictal discharges in a patient with idiopathic generalized tonic-clonic seizures. It illustrates a continuum between strictly focal discharges and generalized spike and wave complexes involving progressively larger areas of the cortex. Bilateral discharges may begin earlier or have a significantly higher amplitude on one side. On EEG, the picture of an individual discharge is indistinguishable from a focal cor-

**ABSENCE SEIZURES  
RIGHT FRONTAL SPIKES**



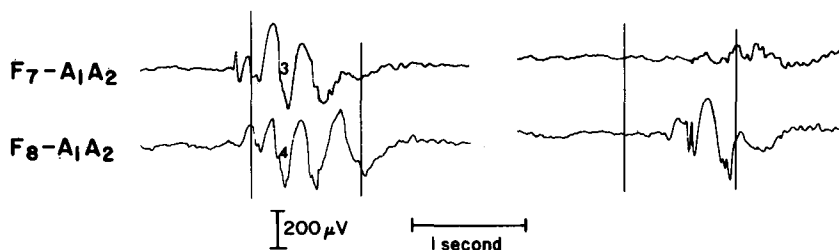
**Fig. 6.** Patient with typical absence seizures, showing extremely focal spikes limited to Fp2 and to a lesser degree F4.

tical epileptogenic lesion with marked tendency to secondary bilateral synchrony, except that in generalized epilepsies, the foci preceding the generalized discharges shift between the two hemispheres.

- (d) Detailed analysis of spike foci by electrocorticography usually reveals involvement of an extensive cortical area (10 cm<sup>2</sup> or more) harboring innumerable spike foci firing independently or in groups (Figs. 12-15). Occasionally, these small spike foci fire synchronously and are usually the only dis-

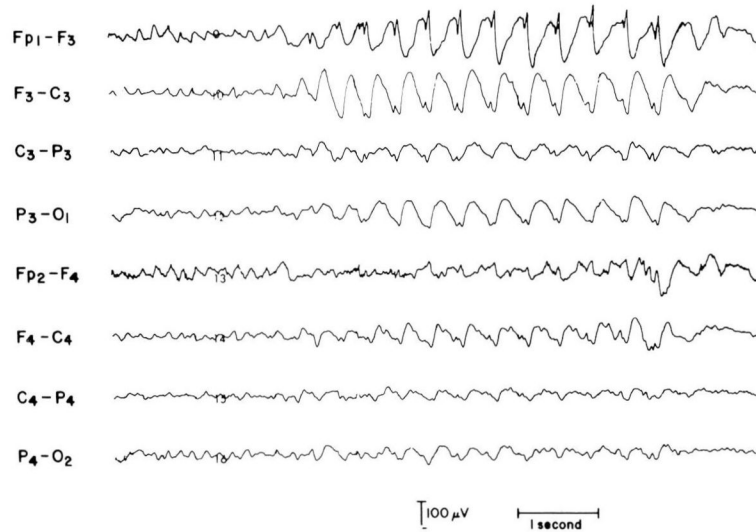
charges that can be detected from the scalp. There is usually no evidence of subcortical gray pathology in these cases, and resection of the cortical focus frequently abolishes the seizures. A similar phenomenon can occur when an entire hemisphere is affected. Figures 16 and 17 illustrate the bridge between focal and generalized epilepsy. Both probably consist of multifocal independent spike foci, discrete in partial epilepsy but covering the whole cortex in generalized epilepsy (Fig. 18). Penicillin-induced spike foci in cats

**ABSENCE SEIZURES  
INDEPENDENT LEFT AND RIGHT FRONTAL SPIKES**



**Fig. 7.** Patient with typical absence seizures, showing independent left and right frontal spikes. The short burst on the left side clearly originates at F7 and then becomes bilateral. The burst on the right side is limited to F8 throughout.

**GENERALIZED 3Hz SPIKE-AND-WAVE COMPLEXES  
ASYMMETRIC DISTRIBUTION**



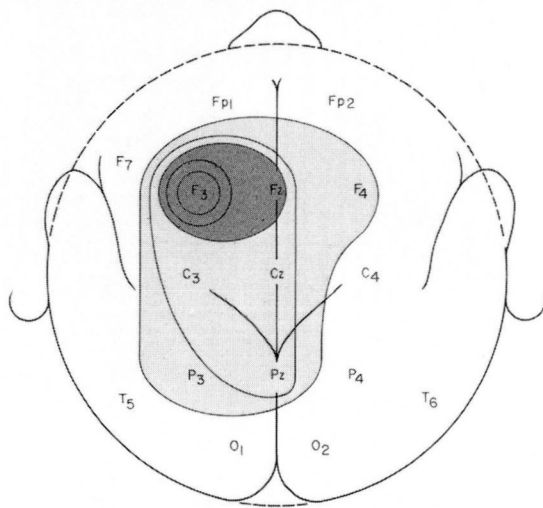
**Fig. 8.** Patient with typical absence seizures, showing a burst of generalized spike and wave complexes which is clearly lateralized to the left side. At other times, the patient had generalized bursts which were symmetrically distributed.

will fire independently if relatively weak and far apart, but synchronously if stronger and/or closer together.<sup>11</sup>

(e) Similar clinical syndromes may show either bilateral multifocal independent spikes or generalized spike and wave complexes. With

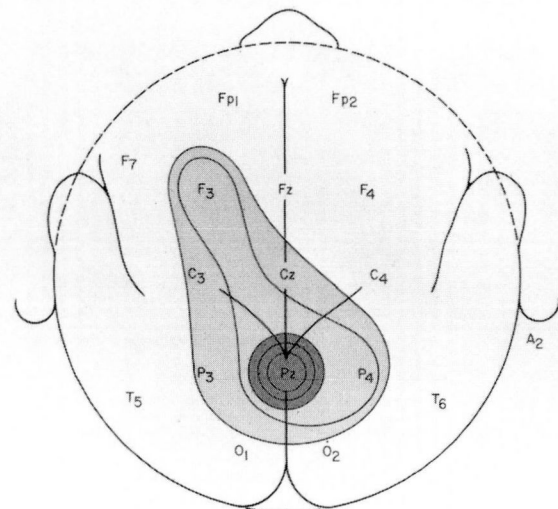
maturation, the EEG may evolve from multifocal independent spikes to generalized spike and wave complexes. For example, patients with minor motor seizures exhibit generalized slow spike and wave complexes, but many also show bilateral multifocal in-

**INTERICTAL EPILEPTIFORM DISCHARGES  
18 YEAR OLD MAN WITH GENERALIZED TONIC-CLONIC SEIZURES**



**Fig. 9.** Distribution map of an interictal epileptiform discharge in a patient with idiopathic generalized tonic-clonic seizures. Darkened area = 100%; first circle >90%; second circle >80%.

**INTERICTAL EPILEPTIFORM DISCHARGES  
18 YEAR OLD MAN WITH GENERALIZED TONIC-CLONIC SEIZURES**



**Fig. 10.** Distribution map of an interictal epileptiform discharge in a patient with idiopathic generalized tonic-clonic seizures. Darkened area = 100%; first circle >90%; second circle >80%.



dependent spikes, some evolving from this pattern to generalized slow spike and wave complexes on maturation.

We conclude, therefore, that generalized epilepsy is an expression of diffuse cortical epileptogenicity that is exhibited on the EEG as multifocal independent spikes with a marked tendency to secondary generalization. As this tendency increases, the multifocal spikes evolve into generalized spike and wave complexes. There is no need to assume pathology in the subcortical gray structures. This does not imply that the normal functions of the gray structures do not influence the cortical discharges in patients with generalized seizures just as they do in those with focal epilepsy. Increase in spike frequency during sleep and triggering of spikes by stimulation of subcortical gray structures is seen as frequently in focal as in generalized seizures. One speaks of "cortical epilepsy" in reference to focal seizures since the pathology is mainly cortical. This is probably also true for generalized epilepsies.

**Primary vs. secondary bilateral synchrony**

The centrencephalic theory conceives primary bilateral synchrony (primary generalized epilepsies) to be seizures triggered from the "centrencephalon," whereas secondary bilateral synchrony would be a focal cortical epilepsy secondarily triggering generalized spike and wave complexes by firing into the centrencephalon (Fig. 19).

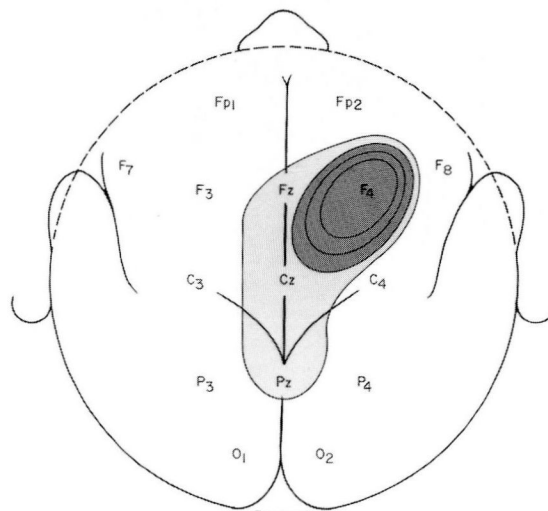
The cortical theory assumes that secondary bilateral synchrony is a common mechanism for both "primary" generalized seizures and focal seizures with secondary generalized spike and wave complexes (Fig. 20). The difference between the two is that (a) in generalized seizures, multiple bilateral cortical foci tend to trigger secondarily generalized bursts, whereas (b) in focal seizures with secondary diffuse spike and slow wave complexes, a single cortical focus triggers the bursts.

**Interictal epileptiform discharges**

*I. Specific abnormality: generalized epileptiform discharges*

The only EEG abnormality which supports the diagnosis of generalized seizures is generalized epileptiform discharges, usually in the form of spike and wave or sharp and wave complexes. Less frequently, polyspikes or polysharp waves, paroxysmal beta or alpha, or other patterns are

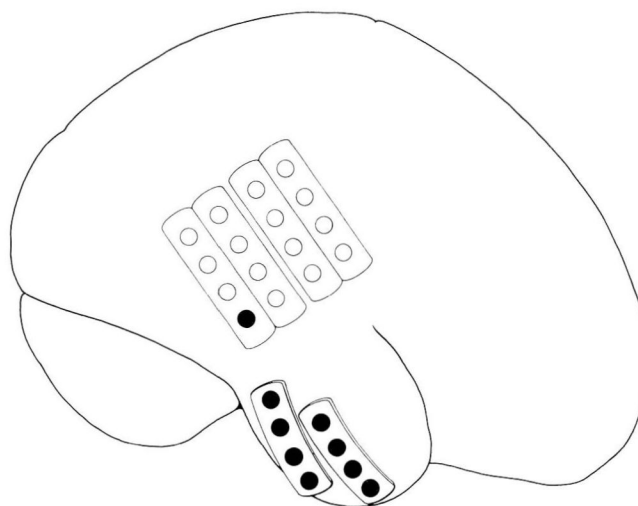
INTERICTAL EPILEPTIFORM DISCHARGES  
18 YEAR OLD MAN WITH GENERALIZED TONIC-CLONIC SEIZURES



**Fig. 11.** Distribution map of an interictal epileptiform discharge in a patient with idiopathic generalized tonic-clonic seizures. Darkened area = 100%; first circle >90%; second circle >80%.

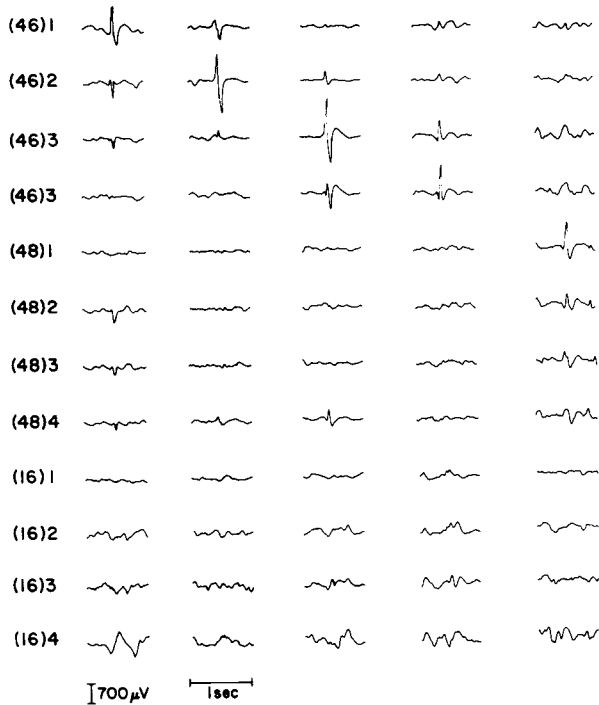
seen. However, once the epileptiform nature of the discharge has been established, the distribution of the discharge is more important than the waveform.

EPILEPTOGENIC AREA  
MULTIPLE INDEPENDENT SPIKE FOCI

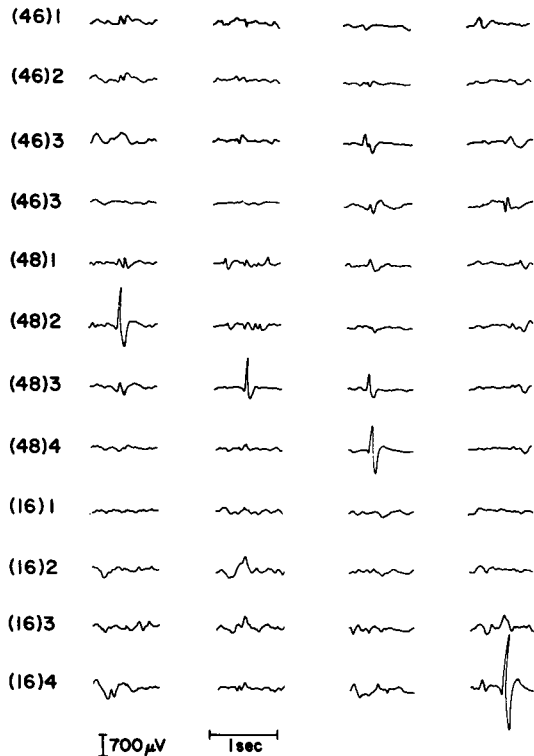


**Fig. 12.** Diagram traced directly from a lateral skull radiograph of a patient with intractable complex partial seizures, showing the outline of the skull and six subdurally implanted flaps, each containing four contacts. The two flaps in the anterior temporal lobe were implanted to detect the main epileptogenic focus. The posterior four flaps were implanted to define the posterior edge of the focus prior to resection.

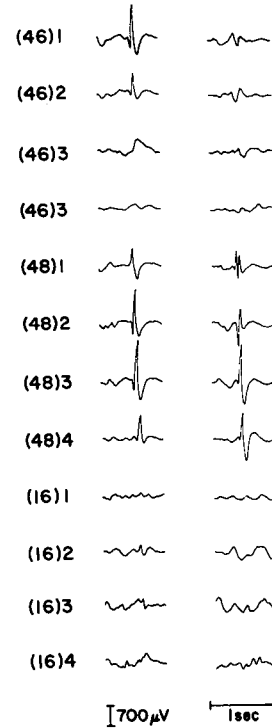
13 **EPILEPTOGENIC AREA**  
**MULTIPLE INDEPENDENT SPIKE FOCI**



14 **EPILEPTOGENIC AREA**  
**MULTIPLE INDEPENDENT SPIKE FOCI**

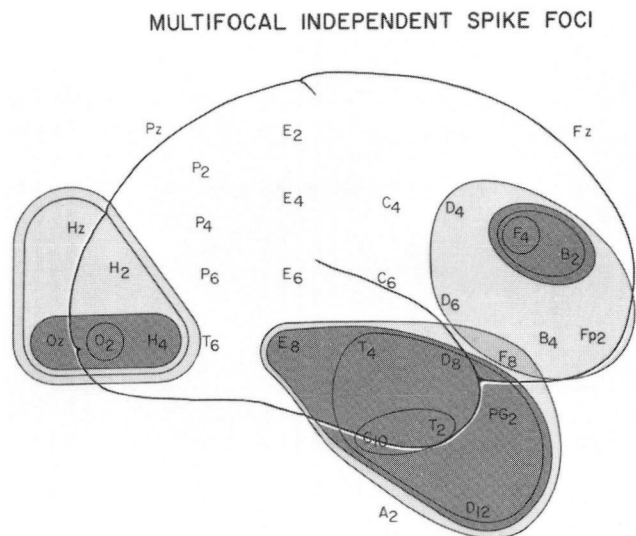


15 **EPILEPTOGENIC AREA**  
**MULTIPLE INDEPENDENT SPIKE FOCI**



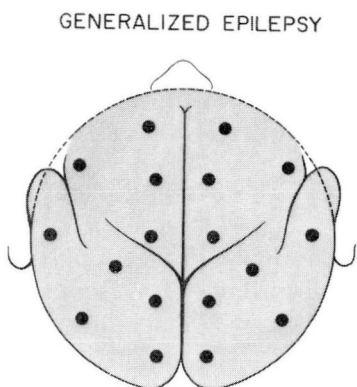
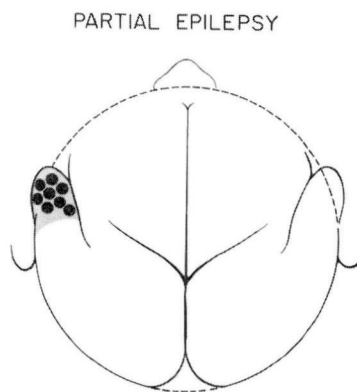
**Figs. 13-15.** Recordings made via the two flaps in the anterior temporal pole (#46 and 48) and one flap (the one with the black dot in Fig. 12) of the more posteriorly implanted electrodes (#16); independent spike foci from all electrodes are marked in black. These foci stem from electrodes 46(1), 46(2), 46(3), 46(4), and 48(1) (Fig. 13) electrodes 48(2), 48(3), 48(4), and 16(4) (Fig. 14), and electrodes 46(1), 46(2), 48(1), 48(2), 48(3), and 48(4) [first column] and electrodes 48(1) 48(2), 48(3) and 48(4) [second column] (Fig. 15).





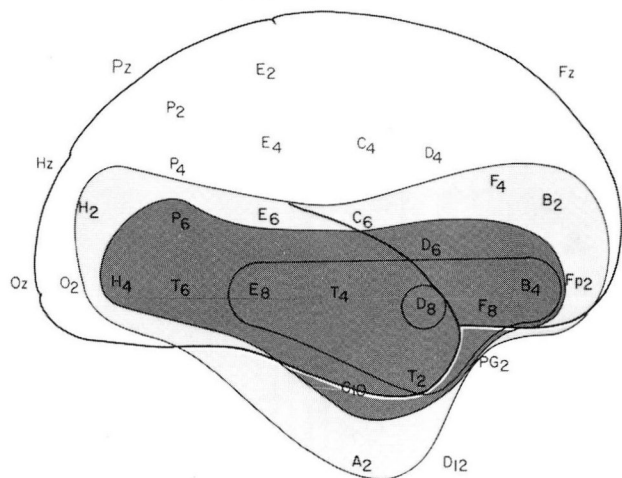
**Figure 16.** Intractable partial seizures starting with visual hallucinations and evolving into left-sided clonic seizures (there were no generalized tonic-clonic seizures) in a patient with right hemiatrophy and mild left hemiparesis. The awake recordings showed almost continuous right occipital spikes at a repetition rate of approximately 1 Hz. During sleep, the right occipital focus was significantly less frequent and independent right frontal and right temporal spikes were activated. [See Fig. 1 for explanation of isopotential lines.]

In generalized seizures, discharges tend to be diffuse but are not of equal amplitude in all electrodes. Invariably, a clearly defined field is seen, the maximum occurring usually at the superior frontal or sometimes at the central electrodes. A marked dropoff is seen posteriorly and



**Fig. 18.** Diagram showing the similarity between partial and generalized epilepsy. Both are expressions of multifocal independent spike foci with a marked tendency toward synchrony, the only difference being the cortical area involved.

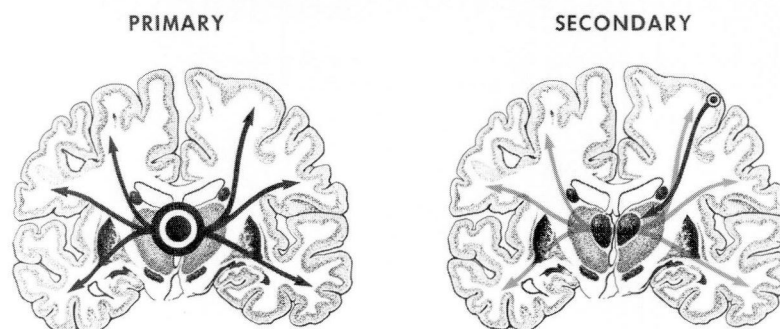MULTIFOCAL INDEPENDENT SPIKE FOCI  
WIDESPREAD DISCHARGE



**Fig. 17.** Same patient as in Figure 16. During sleep, the patient also had widespread right hemispheric discharges, with the three foci illustrated in Figure 16 firing synchronously.

into the temporal region. Ear electrodes, particularly the nasopharyngeal or sphenoidal, are involved minimally or not at all. Sometimes this dropoff posteriorly and laterally is so accentuated that the discharges resemble bifrontal or bicentral spikes more than generalized spike and wave complexes. Another important characteristic of generalized seizures is the frequent occurrence of unilateral focal spikes (*Figs. 6-11*) in the frontal or central region that shift from side to side. In cases with infrequent discharges, a sample of 20-30 minutes may, for example, show only isolated right frontal spikes and no left frontal or generalized discharges. Additional recordings will be necessary to differentiate between a focal right frontal and a generalized seizure disorder with an interictal focal epileptiform manifesta-

### BILATERAL SYNCHRONY (CENTRECEPHALIC THEORY)



**Fig. 19.** Centrecephalon theory. Primary bilateral synchrony is depicted on the left and secondary bilateral synchrony on the right.

tion. In other words, even in a generalized seizure disorder, the EEG may exhibit considerable focal manifestations. In our laboratory, these focal features are described in the body of our reports, but not in the classification and impression if consistent with a generalized seizure disorder.

Generalized discharges are usually asymmetric, but the maximum shifts from side to side. All transition forms along the following continuum can be seen: (a) strictly unilateral focal spikes; (b) bifrontal maximum left or right hemisphere; (c) "generalized" maximum left or right hemisphere; and (d) "generalized" bilateral symmetrical (Fig. 1).

These focal features support the theory that generalized seizures are an expression of bilateral multiple cortical spike foci (Fig. 18).

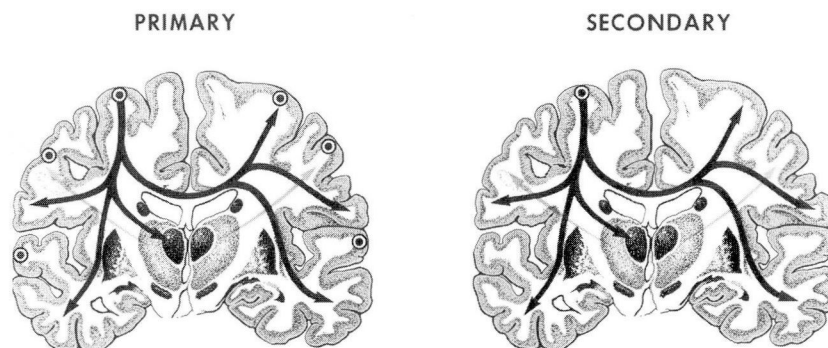
#### II. Neurophysiology of spike and slow wave complex

The most widely accepted hypothesis is that the spike is an excitatory event correlating with excitatory postsynaptic potentials (EPSPs) at the surface of the cortex, whereas the slow wave is inhibitory, being produced by inhibitory postsynaptic potentials (IPSPs) in the deep cortical layers.<sup>12</sup> The superficial and deep location of the EPSPs and IPSPs explains why both events (spike and slow wave) are scalp-negative (Fig. 21).

#### III. Specificity of generalized spike and wave complexes

Specific epileptiform discharges are by definition waveforms that are clearly differentiated from physiological activity. Borderline waveforms, however, are difficult to classify. For practical purposes, only waveforms of clearly patho-

### BILATERAL SYNCHRONY (CORTICAL THEORY)



**Fig. 20.** Cortical theory, showing primary bilateral synchrony on the left and secondary bilateral synchrony on the right.



logical significance should be classified as epileptiform. Conservative reading will greatly increase the specificity of the EEG. Note, however, that a "normal" EEG by no means excludes epilepsy; when documentation is crucial for diagnosis, additional recordings frequently solve the problem.

To increase the specificity of the EEG, generalized epileptiform discharges should be differentiated from the following activity:

- (a) *Nonspecific burst of generalized slow waves.* Bursts of generalized slow waves not associated with spikes or sharp waves have absolutely no epileptogenic significance. They are seen more often in patients with generalized epilepsy,<sup>13</sup> but also in a variety of physiological circumstances (hyperventilation, sleep) and in different diseases without clinical epilepsy (e.g., metabolic encephalopathy).
- (b) *Bursts of generalized slow waves with intermixed sharp transients.* The burst of generalized slow waves seen in the hypnagogic-hypnopompic state and during hyperventilation is occasionally accompanied by sharp transients, usually of relatively long duration (sharp-wave-like). Less frequently, transients are of short duration (spike-like), but of relatively low amplitude compared with the following slow-wave component. This is associated only with hypnagogic hypersynchrony, the spike-like component limited to the beginning of the burst. When bursts of generalized spike and wave complexes occur only during the hypnagogic-hypnopompic state and/or during hyperventilation, the possibility of "over-reading" should be considered. If the epileptiform nature of the pattern is not absolutely clear, an additional stage II sleep and/or resting awake recording should be obtained.
- (c) *Vertex sharp transients.* Vertex sharp transients of sleep frequently are extremely sharp and occasionally cannot be clearly differentiated from epileptiform transients. The typical prepositivity and extreme sharpness of the rising phase and the characteristic spike-slow wave sequence help to identify truly epileptogenic events. Persistence of sharp transients during the waking state will also indicate its epileptogenic character. In doubtful cases, however, it is wise to insist on additional recordings before making a decision.

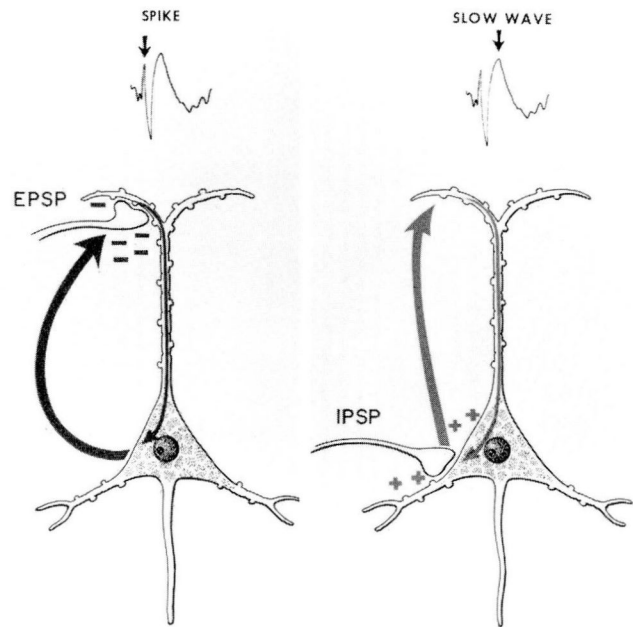
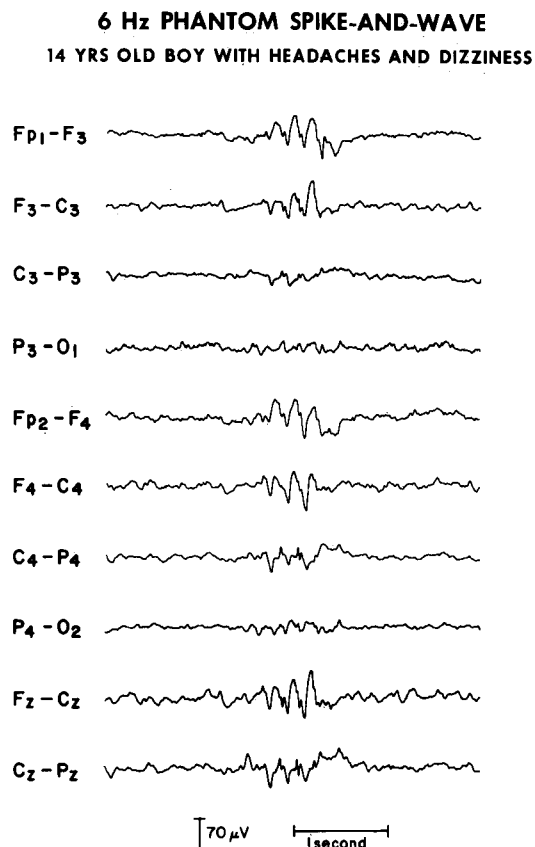


Fig. 21. Superficial EPSPs (spikes) and deep-seated IPSPs (slow waves) produce the same current flow, and hence deflections have the same polarity when recorded from the surface.

- (d) *Six-hertz phantom spike and wave complexes.* This pattern consists of a burst of slow waves intermixed with low-amplitude sharp transients of short duration (spike-like) which repeat at 4–7 Hz (Fig. 22). Usually, the slow waves are much more conspicuous than the sharp transients, and the whole burst rarely lasts more than two seconds. However, frequency of spike repetition is only one of many characteristics of this pattern. Bursts of spike and wave complexes with clearly outstanding, high-amplitude spikes are epileptogenic even if the spikes repeat at 6 Hz (Fig. 23). Usually, the differentiation of epileptogenic and nonepileptogenic 6-Hz spike and wave complexes is clearcut. In doubtful cases, it is always safe to assume that one is dealing with a nonepileptogenic pattern and additional recordings can be requested.
- (e) *Photoparoxysmal pattern.* Photoparoxysmal patterns consisting of sharp transients time-locked to the stimulus, predominating in the posterior head regions have no diagnostic value, being frequently seen in normal controls and nonepileptic patients. The only useful diagnostic pattern is a generalized, self-sustained photoparoxysm not time-locked to the stimulus, with clearly defined



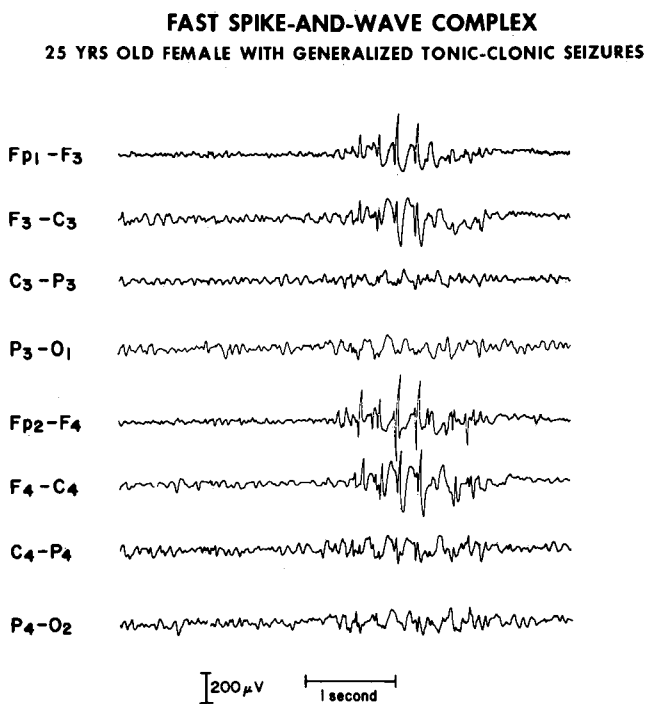


**Fig. 22.** Short burst of 6-Hz phantom spikes and waves in a 14-yr-old boy with headaches and dizziness, but no history of epilepsy

spikes. A relatively high incidence of different types of photoparoxysmal patterns has been reported in normal children aged five to 15 years.<sup>14</sup> Nevertheless, a photoparoxysmal pattern meeting the above stringent criteria can be classified as epileptogenic, even in young children.

False-positive tests will be rare if spike and wave complexes are rigidly defined and nonspecific abnormalities excluded. However, spike and wave complexes in apparently nonepileptic patients do not always imply over-reading. The EEG abnormality may be a subclinical manifestation of an epileptogenic tendency. In a study by Zivin and Ajmone Marsan,<sup>15</sup> 15% of nonepileptic patients with spike and wave complexes eventually developed seizures during follow-up studies.

False-positive tests can frequently lead to an erroneous diagnosis of epilepsy or to an incorrect classification of seizure type. A negative test (even under-reading) should not confuse the astute clinician as a negative EEG by no means excludes



**Fig. 23.** Twenty-five-year-old woman with generalized tonic-clonic seizures and generalized fast spike and wave complexes.

epilepsy. Additional recordings will frequently clarify the diagnosis.

#### IV. Normal EEG

In some types of epilepsy, normal EEG readings are more likely than epileptiform manifestations, e.g., in adults with infrequent generalized tonic-clonic seizures.

The single most important factor which determines the probability of recording epileptiform abnormalities is the *frequency of seizures*. This varies from patient to patient, but in individuals, the correlation is excellent: Those with frequent seizures almost invariably display EEG abnormalities.<sup>16</sup> Conversely, those with infrequent seizures will probably not show specific abnormalities on routine EEG.

A word of caution: Patients with one or more "spells" a day and normal EEGs may not be epileptics. These patients should undergo intensive EEG monitoring and induction of these episodes by suggestion to determine their origin.

#### Ictal EEG

##### I. Ictal EEG patterns

The ictal EEG in patients with generalized seizures can be divided according to the relationship between interictal and ictal patterns:

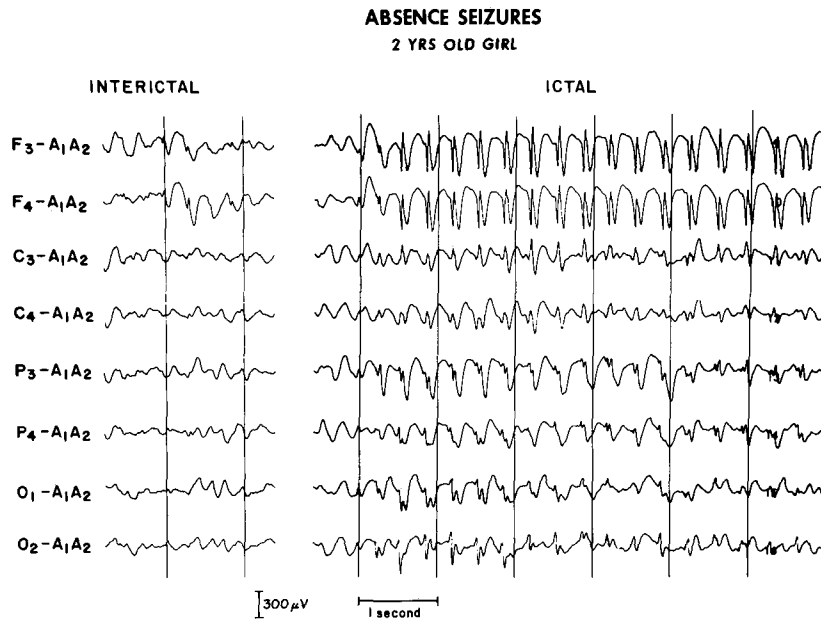


Fig. 24. Interictal and ictal patterns in a patient with generalized absence seizures

- (a) *Ictal pattern = prolonged interictal pattern.* The ictal pattern consists of generalized spike and wave complexes (similar or identical to interictal spike and wave complexes) (Fig. 24). In these cases, symptomatology is dominated by alterations of consciousness (i.e., typical absences in patients with classical 3-Hz spike and wave complexes and atypical ["bland"] absences in patients with slow spike and wave complexes).
- (b) *Ictal pattern = intense interictal pattern.* This is usually seen in myoclonic seizures. Low-amplitude polyspike and wave complexes are usually asymptomatic whereas those of higher amplitude are accompanied by myoclonic jerks. Their intensity is directly related to amplitude and duration of the polyspikes.
- (c) *Ictal pattern  $\neq$  interictal pattern.* In these cases, the interictal patterns are isolated sharp waves, spikes, or spike and wave complexes, but the ictus consists of or starts with an electrodecremental and/or paroxysmal fast pattern (Fig. 25). Tonic seizures, akinetic seizures, and infantile spasms usually are associated with a five- to 10-second electrodecremental pattern with superimposed paroxysmal fast activity which not infrequently has progressively higher amplitude and slower frequencies. Generalized tonic-clonic seizures start in the same way during the

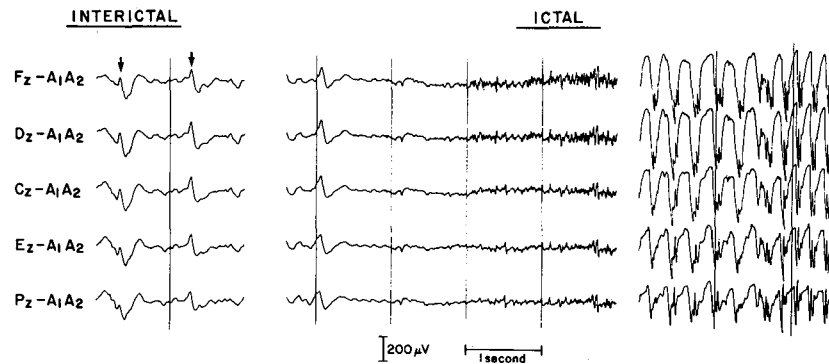
tonic phase, but then evolve into spike and wave complexes of progressively higher amplitude but slower repetition rate. Clinically, this is accompanied by transition from the tonic to the clonic phase. Occasionally, evolution from one pattern to another is seen, the most typical from 3-Hz spike and wave complexes or polyspike and wave complexes to generalized tonic-clonic seizures (Fig. 26).

## II. Electroclinical correlations

In Part I on the neurophysiology of spike and wave complexes, the spike was associated with EPSPs and the following slow wave with IPSPs.

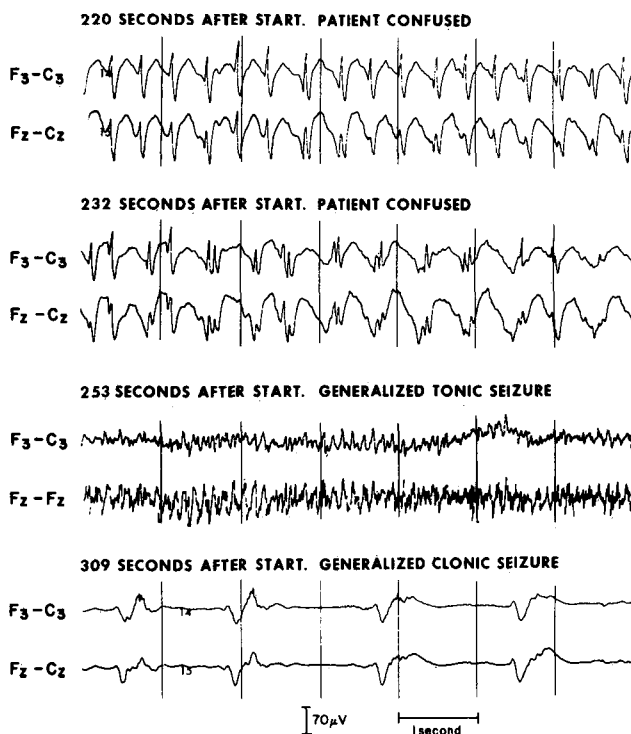
The spike component of the spike and wave complex is asymptomatic when of relatively long duration ("sharp wave") as in slow spike and wave complexes. When the spike is of fast evolution (actual "spike"), it produces myoclonic jerks whose intensity is related to the amplitude of the spike component. The typical example is the burst of 3-Hz spike and wave complexes accompanied by myoclonic jerks of the eyelids at a similar repetition rate. With repetitive spikes occurring in fast succession (up to 30–40 Hz), the intensity of the motor manifestation increases progressively. Short bursts of polyspikes (usually followed by prominent slow waves) tend to produce violent generalized myoclonic jerks, e.g., bursts of polyspike and waves seen in myoclonic epilepsy. Longer runs of spikes ("paroxysmal

**GENERALIZED TONIC-CLONIC SEIZURES**  
23 YRS OLD MAN



**Fig. 25.** Twenty-three-year-old man with generalized tonic-clonic seizures and interictal epileptiform discharges on the left side. The middle tracing shows the start of a seizure with an electrodecremental episode; the latter part of that tracing shows a paroxysmal fast and/or muscle artifact which coincides clinically with the tonic phase. The last trace on the right shows spike and wave complexes, associated clinically with the clonic phase. Dz = between Fz and Cz (International System); Ez = between Cz and Pz.

**ABSENCE AND GENERALIZED TONIC-CLONIC SEIZURE**  
12 YRS HISTORY OF GENERALIZED TONIC-CLONIC SEIZURES



**Fig. 26.** Evolution from absence to generalized tonic-clonic seizure. During the first 220 sec, the EEG showed extremely regular generalized 2.5-Hz spike and wave complexes; and the patient was extremely confused, but answered simple questions or commands. At 232 sec, the spike and wave pattern became irregular, but no clinical change was noticed. At 253 sec, the patient had a tonic seizure and the EEG showed an electrodecremental pattern with a superimposed paroxysmal fast and/or muscle artifact. At 309 sec, the patient had generalized clonic seizures and the EEG showed periodic sharp-wave transients.

fast”) tend to produce tonic seizures like the tonic phase of generalized tonic-clonic seizures.

The slow wave of spike and wave complexes is not accompanied by myoclonic or tonic motor phenomena and actually tends to inhibit them. In the evolution from generalized tonic to clonic seizures, the spikes decrease progressively in repetition rate and are followed by slow waves of progressively longer duration and higher amplitude. The motor manifestations strictly follow the temporal evolution of the spike component evolving from the tonic phase into a generalized “tremor” when the repetition rate of the spikes decreases to approximately 10 Hz, and then into clonic seizures when spike and wave complexes at progressively slower repetition rate appear on the EEG.

The main clinical manifestation of bursts of spike and wave complexes not accompanied by myoclonic phenomena (or in which the myoclonic jerks are only a secondary symptom) is alteration of consciousness, for example, the bursts of 3-Hz spike and wave complexes typically associated with absences. The degree of alteration of consciousness is a complex function of type and duration of a burst and point in time within the burst. Three-hertz spike and wave complexes of less than three seconds are usually not associated with clinical symptomatology. Bursts of more than five seconds, however, are usually manifested clinically or subclinically. Reaction time is prolonged in 43% of cases at the initiation of bursts of 3-Hz spike and wave complexes, in 80% before 0.5 seconds, and in only 68% after four



seconds.<sup>7</sup> The progressive recovery of consciousness as the bursts become longer is clearly evident in patients with absence status who, despite continuous generalized spike and wave complexes, usually show only mild alterations of consciousness. Another example is the almost continuous slow spike and wave complexes (Lennox-Gastaut) associated with only very mild alteration of consciousness simulating mental retardation. Not infrequently this is attributed to an underlying static encephalopathy and only becomes evident when the patient shows a clear recovery of intellectual function following the disappearance of the spike and wave complexes.

Intimately related to the alteration of consciousness are automatisms. The occurrence of automatisms in absence seizures is directly related to the duration of the bursts of 3-Hz spike and wave complexes. Bursts of more than six seconds are accompanied by automatisms in 50% of these patients and bursts of more than 12 seconds in 90%.<sup>18</sup> The mechanism of generation of the automatisms is probably closely linked to the alteration of consciousness and has no direct correlation with myoclonic, clonic, or tonic motor manifestations. Automatisms are well-coordinated, frequently repetitive motor manifestations for which the patient is amnesic. They probably represent a type of release phenomenon from conscious control of motor activity and should be clearly differentiated from involuntary myoclonic, clonic, or tonic motor manifestations produced directly by epileptogenic cortical activity. This differentiation is particularly important in patients with focal epilepsy in whom lateralization of focal myoclonic, clonic, or tonic motor activity is an extremely useful localizing sign. Lateralization of an automatism is of absolutely no localizing value.

Alterations of consciousness in patients with 3-Hz spike and wave complexes is produced, according to the centrencephalic theory, by an epileptic discharge in deep-seated subcortical gray structures ("consciousness center"). Assuming that generalized epilepsy is primarily a diffuse cortical disease, the best explanation for the alteration of consciousness is the generalized cortical discharge which would interfere diffusely with normal cortical functions.

The electroclinical correlations mentioned above represent only general trends. The exact clinical correlation of any given EEG pattern cannot be predicted with certainty. The typical example is the burst of 3-Hz spike and wave

complexes. Bursts of similar morphology and duration may show a variety of clinical manifestations: (a) asymptomatic; (b) interference with initiation of movement, but not with repetitive movements; (c) interference with all voluntary movements; and/or (d) interference with memory. Bursts of longer duration, more widespread distribution, and higher amplitude are clearly correlated with the more severe clinical manifestation. For any given burst in any given patient, however, no definite prediction can be made.

### Postictal EEG

In generalized seizures associated with alterations of consciousness only, the postictal EEG, independent of the duration of the spell, is not changed significantly as compared with the preictal baseline EEG.

Generalized motor seizures are frequently associated with postictal EEG abnormalities. Both degree and duration of these postictal changes are directly related to the duration and intensity of the motor manifestations. Isolated myoclonic jerks, even when violent, are not associated with postictal abnormalities. Short, generalized, tonic seizures are also frequently not followed by postictal changes. Generalized tonic-clonic seizures, however, are almost always followed by postictal abnormalities. Prolonged generalized tonic-clonic seizures, particularly when accompanied by severe motor manifestations, will be followed by marked postictal changes in the EEG-like diffuse flattening (less than 20  $\mu$ V delta EEG) or burst-suppression pattern. Abnormal postictal EEG patterns occasionally persist for many hours. This is particularly true in patients who have had a series of seizures or status epilepticus.

Postictal EEG changes show strict correlation with clinical postictal symptomatology. Flat EEG, burst-suppression pattern, and diffuse slow activity in the delta range (replacing the alpha rhythm) are usually accompanied by clinical postictal coma. Diffuse theta rhythm (replacing the alpha rhythm) will be associated with stupor. The postictal EEG pattern is very helpful in the differentiation of real and psychogenic seizures. Psychogenic "spells" frequently consist of violent shaking of all extremities followed by unresponsiveness. During the violent stage, the EEG is usually completely obscured by EMG and movement artifacts. During the following stage of "unresponsiveness," however, the EEG exhibits normal alpha activity. In patients with real seizures,

postictal unresponsiveness is always associated with marked EEG slowing.

The neurophysiological mechanism of postictal slowing has not been clearly elucidated. The most probable explanation is neuronal "exhaustion" resulting from imbalance of energy reserves, the demand for energy exceeding supply. This imbalance is the product of two factors:

- (a) Neuronal activity is greatly increased with a corresponding increase of energy demand.
- (b) Motor activity consumes a significant part of the energy supply and may interfere with respiration and thus restrict oxygen intake.

The fact that postictal slow activity is seen almost exclusively with generalized tonic-clonic seizures is understandable if we consider the above factors. Generalized tonic-clonic seizures exhibit the most intense epileptiform manifestations and the most violent motor activity. Both factors obviously contribute to the energy deficit. In patients with seizures not associated with motor activity, the supply of energy is not affected. The mechanism responsible for postictal slow activity ("neuronal exhaustion"), however, is not necessarily responsible for terminating the seizure. Many seizures, e.g., absences associated with 3-Hz spike and wave complexes, do not produce postictal slow activity, but tend to stop within 10–15 seconds. In these cases, an active inhibitory mechanism could be postulated.

### Characteristic EEG patterns

#### I. Typical clinical correlates

The following EEG patterns have definite clinical correlations:

- (a) 3-Hz spike and wave complex: generalized absence
- (b) Slow spike and wave complex: minor motor seizures
- (c) Hypsarrhythmia: infantile spasm
- (d) Multifocal independent spikes: minor motor seizures or infantile spasms
- (e) Polyspike and wave complex: myoclonic seizures.

#### II. The concept of typical EEG patterns

A real EEG pattern is obviously far more complex than the idealized waveforms described above. For example, patients with 3-Hz spike and wave complexes may also show focal left and right frontal spikes and bursts of polyspike and wave

**Table.** Typical clinical correlates

EEG pattern	Clinical correlate
3-Hz spike and wave complex	Generalized absence
Slow spike and wave complex	Minor motor seizures
Hypsarrhythmia	Infantile spasm
Multifocal independent spikes	Minor motor seizures or infantile spasms
Polyspike and wave complex	Myoclonic seizures

complexes in sleep. Moreover, the repetition rate of the so-called "3-Hz" spike and wave complexes only exceptionally is exactly 3 Hz. In the following section, the main characteristics of the patterns cited above are described in detail.

(a) *Three-hertz spike and wave complexes.* The definitive pattern consists of bursts of spike and wave complexes lasting at least three seconds, at a repetition rate of approximately 3 Hz with a short spike component (50–80 msec). Spike and wave complexes tend to have a faster repetition rate at the beginning (4–5 Hz), then stabilize at around 3 Hz (always more than 2.5 Hz) during the main part of the burst, finally slowing down again at the end. The bursts have a clearly defined onset and end abruptly. Frequently, shifting asymmetries occur at the beginning of the burst. The bursts occur most frequently in the waking and the REM sleep stage and are activated by hyperventilation. The most characteristic feature is the association with clinical or subclinical unresponsiveness. This is easily tested with a clicker (see below). Bursts of spike and wave complexes with some atypical features should be thus classified as 3-Hz spike and wave complexes only if associated with relative unresponsiveness. Otherwise, they are simply called generalized spike and wave complexes. Conservative labeling of the 3-Hz spike and wave pattern will significantly increase its specific correlation with clinical absences. It is important to remember that an EEG pattern classified as generalized spike and wave complexes strongly supports the diagnosis of generalized epilepsy and certainly is compatible with clinical absences even if not specific for this type of epilepsy.

The classification of a record as "3 Hz spike and wave complexes" depends on the presence of the above described typical burst. Other types of epileptiform discharges, however, are seen almost always in addition to the typical 3-Hz spike and wave

complexes (Fig. 27). This includes focal left or right frontal spikes, atypical short bursts of spike and wave complexes, and irregular bursts of polyspikes and waves. The last two patterns are most frequent in slow-wave sleep when the long bursts are replaced by progressively more frequent bursts of shorter duration, irregular repetition rate, and the appearance of polyspikes. There are exceptions to this rule, however, and occasionally, bursts of 3-Hz spike and wave complexes are seen exclusively during sleep. With the epileptiform discharges, a change in the stage of sleep, arousal, or apnea can be observed, indicating that these bursts are symptomatic. On the other hand, it is not infrequent that a patient with absence seizures may only show atypical bursts of generalized spike and wave complexes during sleep. This often occurs when the patient is clinically asymptomatic or exhibits only generalized tonic-clonic seizures at the time of the test.

- (b) *Slow spike and wave complexes.* The most characteristic and necessary pattern consists of bursts of spike and wave complexes of at least three seconds repeating at less than 2.5 Hz. The "spike" component of the spike and wave complexes is actually a sharp wave with a relatively long duration of more than 80 msec. Frequently, a significant proportion of the record is occupied by slow sharp and wave complexes in bursts of variable duration. Only rarely can one distinguish a difference in clinical behavior between the portion of the EEG occupied by slow spike and wave complexes and those free of epileptiform discharges. The clicker test (see below) is usually unreliable because patients are uncooperative. Despite the apparent lack of clear correlation between bursts of slow spike and wave complexes and behavioral alterations, an impressive change in behavior is occasionally noticed on disappearance of the slow spike and wave pattern from the EEG because of treatment or other reasons. Besides, in the occasional patient with infrequent but long bursts of slow spike and wave complexes, a behavioral change can be correlated with each burst (relative unresponsiveness, complex automatisms). Frequently, the background rhythm of patients with slow spike and wave complexes is relatively slow for the age of the patient.

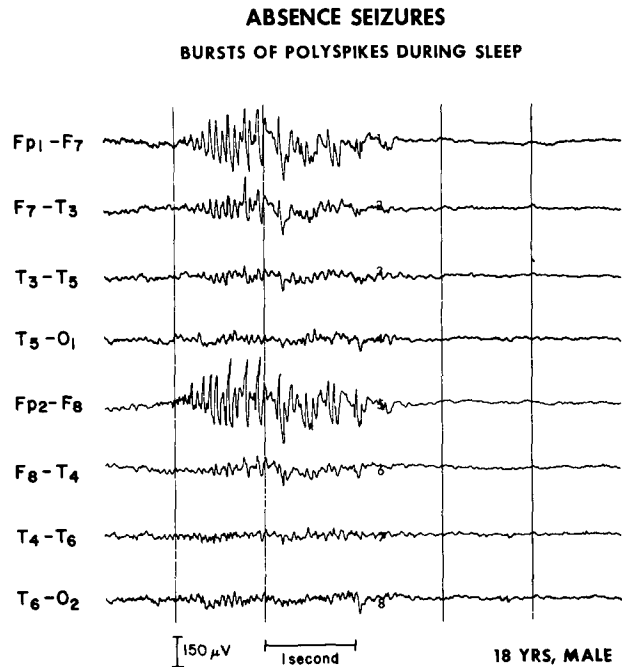
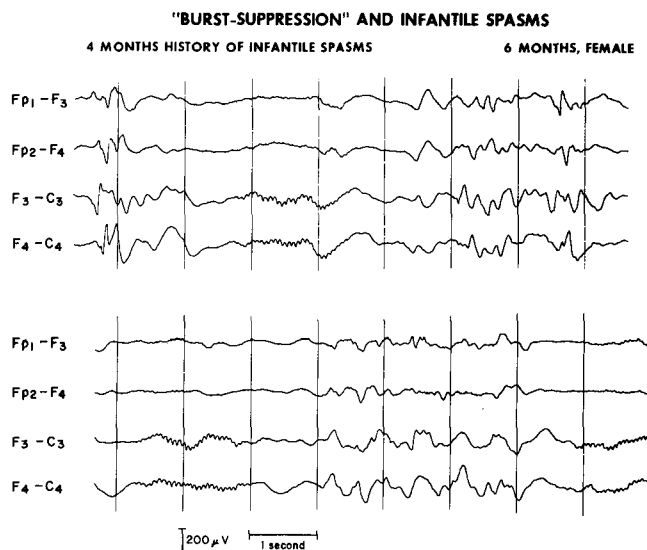


Fig. 27. Burst of polyspikes during sleep in a patient with generalized absence seizures

Almost always, one sees other epileptiform discharges, such as generalized atypical spike and wave complexes, focal left or right frontal spikes, and occasionally, in more atypical locations, particularly in the occipital areas. Irregular, short bursts of polyspike and wave complexes during sleep are also noticed. A fairly characteristic feature is the occurrence of electrodecremental episodes, frequently with superimposed paroxysmal fast activity. These episodes vary between one and 10 seconds and are most frequent during sleep. Longer episodes are typically associated with either tonic, akinetic, or atonic seizures or their combination.

- (c) *Hypsarrhythmia.* The most characteristic and necessary pattern for this EEG classification consists of continuous multifocal independent spikes superimposed on a slow background in the delta range which has an average amplitude of at least 300  $\mu$ V. During sleep, the epileptiform discharges are more prominent and tend to group in one- to 10-second bursts of slow waves with superimposed multifocal spikes. These bursts are separated by relatively low amplitude EEG segments. This pattern has been erroneously labelled "burst-suppression" (Fig. 28), but the "suppression" consists of EEG





**Fig. 28.** Patient with infantile spasms and a burst-suppression pattern during sleep. Sleep spindles occurred preferentially during the so-called "suppression" phase.

activity of relatively lower amplitude compared with the high amplitude bursts. Absolute measurement of amplitude frequently reveals values between 20–70  $\mu$ V, and one may see well-developed sleep spindles during these periods. Perhaps the French expression, *trace paroxystique*, better describes this phenomenon.

Infantile spasms are typically associated with five- to 10-second electrodecremental patterns, which may be associated with low-amplitude paroxysmal beta or alpha waves, particularly at the end. The pattern is frequently inconspicuous and can easily be missed. Careful clinical observation by the technologist and the corresponding notations on the record are extremely helpful for correct identification of the ictal nature of this pattern.

As in all other typical patterns, one may see generalized spike and wave, or polyspike and wave complexes.

- (d) *Multifocal independent spikes.* This pattern is very similar to hypsarrhythmia except that the background is not in the delta range and/or is of less than 300  $\mu$ V amplitude. The ictal patterns are identical to slow spike and wave complexes, or hypsarrhythmia. It is important to differentiate the multifocal independent spike pattern from the multifocal independent sharp waves frequently seen in benign focal epilepsy of childhood.

The main characteristics of multifocal in-

dependent sharp waves of benign focal epilepsy of childhood are as follows:

- (1) The posterior background rhythm is within normal limits for its age group.
  - (2) The epileptic discharges are sharp waves (duration longer than 80 msec) and not spikes.
  - (3) The sharp waves are followed by predominantly positive slow waves, with a negative phase of usually lower amplitude than the preceding sharp wave.
  - (4) The sharp waves are of extremely stereotyped waveform, even if varied in amplitude.
  - (5) *Horizontal* bipoles are characteristic, even if not always present.
  - (6) The discharges are inhibited by mental activation, hyperventilation, photic stimulation, and increase markedly during sleep. Not infrequently, the pattern is present only during sleep.
  - (7) They are not associated with atypical generalized spike and wave complexes.
  - (8) Usually there are only three to four discrete foci which fire independently, or one will trigger the other.
- (e) *Polyspike and slow wave complex.* Polyspike and slow wave complexes are frequently seen during sleep in association with any of the above patterns. In addition, it is not infrequent to see spike and wave complexes with two or three spikes preceding the slow wave in patients who do not have myoclonic epilepsy. Therefore, this pattern is of very limited specificity and is of diagnostic value only in the awake tracing with a prominent polyspike component.

## Special tests

### I. Sleep

Sleep is an excellent activation procedure for interictal epileptiform discharges in all types of generalized epilepsies. It is a natural activation procedure with essentially no risk for the patient and no false positives. It is frequently said that hyperventilation is the best activator for 3-Hz spike and wave complexes. This is true if one is looking for typical 3-Hz spike and wave complexes and/or absence seizures. In patients with absence seizures for whom the routine awake tracing including hyperventilation is negative, activation of atypical spike and wave complexes during sleep is not infrequent.

## II. Photic Stimulation

Photic stimulation is a relatively selective activator of generalized epileptiform discharges. Focal epileptiform discharges (including occipital) are usually inhibited and rarely triggered by photic stimulation.

In photic stimulation, the most frequently activated seizures are generalized myoclonic jerks, clinical absences, or generalized tonic-clonic seizures. It is important to differentiate between photomyoclonic response (exaggerated physiologic myoclonus elicited by intermittent photic stimulation) which has no diagnostic significance and the photoparoxysmal patterns characteristic of generalized epilepsies.

In a small subgroup of patients with photoparoxysmal responses, seizures will be triggered only by intermittent photic stimulation (photosensitive patients). In this group, the use of lenses can prevent the seizures. Lenses can be tested in the EEG lab by studying their effect on photoparoxysmal response. However, photoparoxysmal responses may fluctuate considerably over time, and therefore, reproducibility of results is essential to reach any conclusion.

Some photosensitive patients are pattern-sensitive, i.e., photoparoxysmal EEG responses and even seizures can be activated by a special geometric pattern. To find it, the patient scans different patterns under strong illumination under EEG monitoring, particularly from the occipital region.

## III. Hyperventilation

Hyperventilation is an excellent activator of 3-Hz spike and wave complexes, but may also be effective in other types of generalized epileptiform discharges. It is extremely useful to determine whether bursts of spike and wave complexes are clinically symptomatic. There are two simple methods to objectively demonstrate whether a burst of spike and wave complexes is associated with absences:

- (a) *Respiration monitoring*: Most bursts of spike and wave complexes associated with unresponsiveness will be accompanied by a momentary interruption of hyperventilation by a period of apnea. This can be easily demonstrated by a respiratory monitor (*Fig. 29*); however, spontaneous respiration is frequently not altered during absence seizures (*Fig. 30*).
- (b) *Clicker*: This is a simple device to detect short

lapses of consciousness (*Fig. 31*). The technologist pushes a button which produces a clearly audible click, and the patient is asked to push another button as fast as possible when he hears the click. Both push buttons are monitored on either the same or an independent EEG channel. During hyperventilation, the responsiveness of the patient is tested every 10–20 seconds. When a burst of spike and wave complexes occurs, the technologist pushes the button as soon as possible. For short bursts, the patient can also be asked to push the button continuously. Symptomatic bursts are clearly identified because the patient will stop pushing the button. Some patients continue pushing the button repeatedly during bursts of spike and wave complexes, but are unable to push the button in response to random clicks produced by the technologist. This is because automatic activity tends to be less affected than voluntary initiation of movement during bursts of 3-Hz spike and wave complexes. Other patients will continue responding to the clicker, but with a certain delay. Patients with slow spike and wave complexes frequently show no alteration of responsiveness in association with bursts of epileptiform activity (*Fig. 32*).

It is very important to remember that hyperventilation normally activates bursts of slow waves which not infrequently have associated sharp transients. These bursts result from respiratory alkalosis with secondary relative brain anoxia. Frequently, the patient also has paresthesia of the distal extremities and lips, dizziness, and occasionally, slight alteration of consciousness with unresponsiveness and amnesia for words he had been asked to remember during the bursts of slow waves. The patient may stop hyperventilating and become unresponsive to clicks. This is greatly activated by relative hypoglycemia and may disappear completely if sugar is given. This phenomenon is infrequent, but indicates that unresponsiveness during a burst activated during hyperventilation is not sufficient proof of its epileptogenic character.

## IV. Evoked potentials

Giant visual and somatosensory evoked potentials have been described in patients with myoclonic epilepsy and/or photosensitivity. The am-

ABSENCE SEIZURES

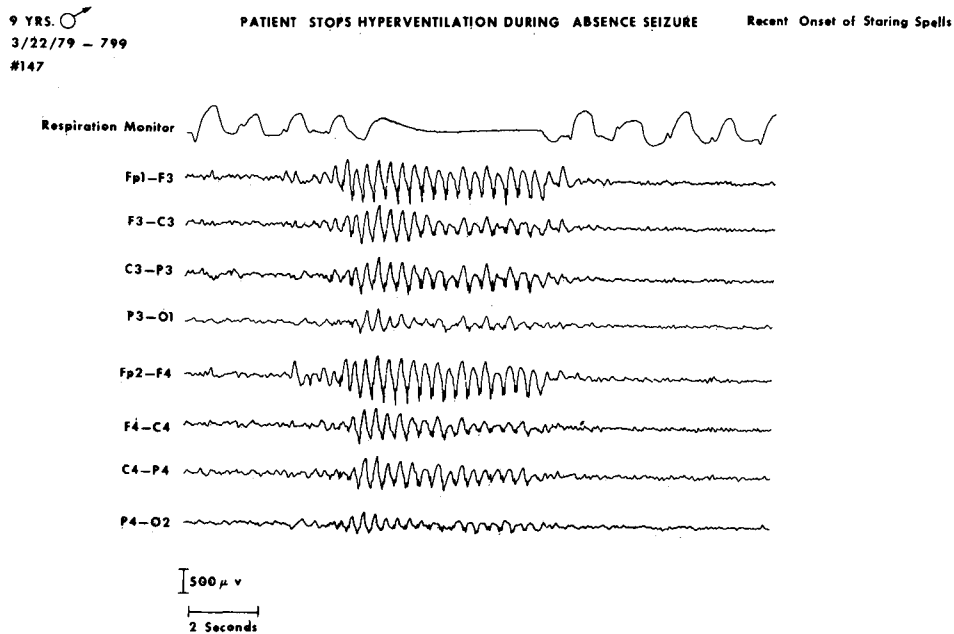


Fig. 29. Apnea associated with clinical absence seizures activated by hyperventilation

plitude of the evoked potentials is directly related to the severity of the epileptic condition at the time of the test. Halliday<sup>19</sup> showed that the amplitude is increased only in patients with progressive myoclonic epilepsy exhibiting myoclonic jerks at the time of the test. In addition, treatment with anticonvulsants will reduce the amplitude of the evoked potentials if it has been effective in controlling the myoclonic jerks.

The giant somatosensory evoked potentials seen in patients with myoclonic epilepsy are of special interest. In these patients, the subcortical evoked potentials are of normal amplitude and the first abnormal high amplitude components are N18, and particularly P20. There is universal agreement that P20 is a cortically generated evoked potential, and most authors also assume that N18 is at least partially of cortical nature.

ABSENCE SEIZURE

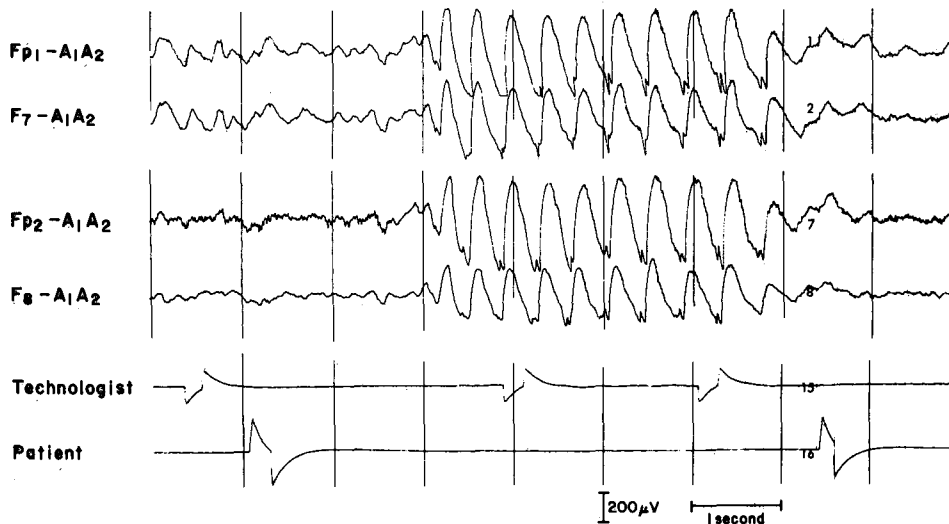
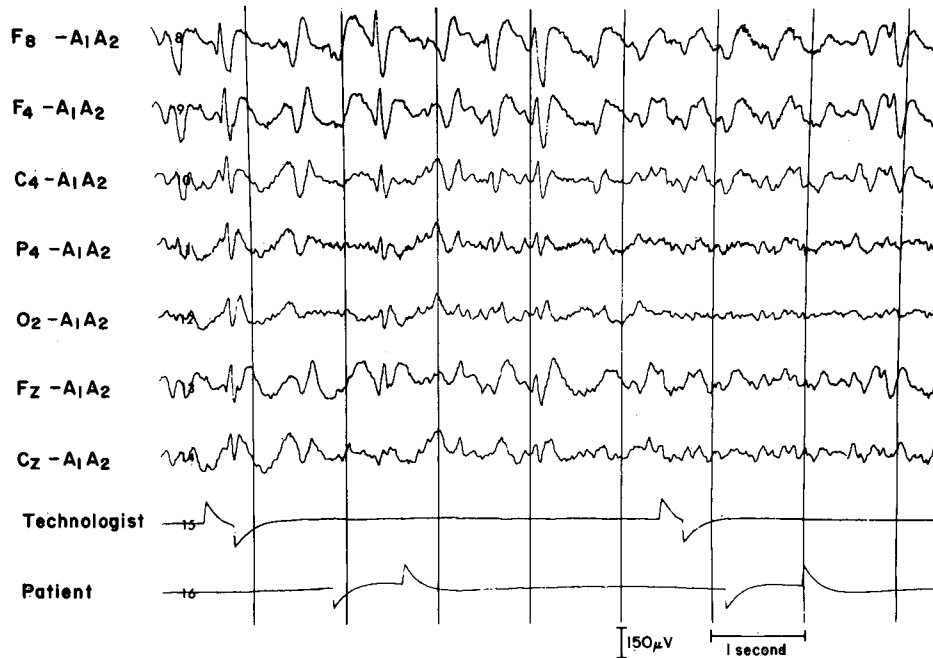


Fig. 30. No alteration of spontaneous respiration is seen in this patient during an absence seizure.



**SLOW SPIKE-AND-WAVE COMPLEX**  
**29 YR OLD MAN WITH MINOR MOTOR SEIZURES**



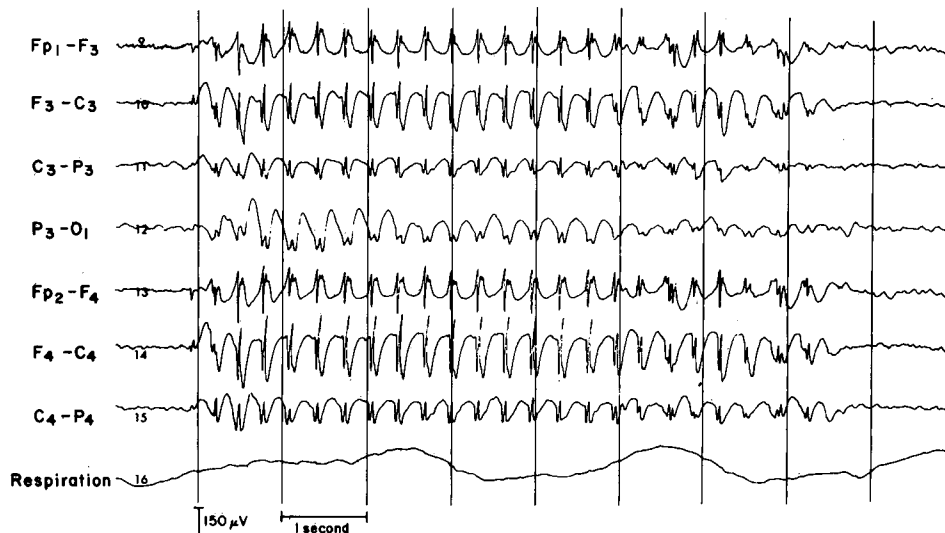
**Fig. 31.** During a short absence seizure, this patient became unresponsive; however, he responded as soon as the seizure was over.

This supports the theory that myoclonic epilepsies are primarily due to hyperexcitability of cortical neurons and do not result from subcortical gray pathology producing excessive thalamocortical discharges. This supports the cortical theory of generalized epilepsies developed in Part I.

*V. Spatial display*

Three-dimensional pictures of the potential fields can be obtained via digital computer.<sup>20</sup> These methods define the distribution of epileptiform discharges more accurately than routine

**ABSENCE SEIZURE**  
**NO ALTERATION OF SPONTANEOUS RESPIRATION**



**Fig. 32.** Burst of slow spike and wave complexes not associated with unresponsiveness

recordings and can assist in the differentiation of primary and secondary bilateral synchrony (Daube and Klass, unpublished data).

#### VI. Computer-assisted statistical analysis of EEG transients

Digital computer techniques for semiautomatic statistical analysis of time or amplitude relationships between epileptiform discharges have been developed.<sup>5</sup> These techniques are used to differentiate primary from secondary bilateral synchrony. In bilateral synchrony (typical absences), the interhemispheric time differences of the epileptiform discharges centered around 0 msec and ranged within  $\pm 20$  msec with shifting lateralization. In secondary bilateral synchrony, consistent leading of one hemisphere was characteristic. In one patient with a left hemispheric neoplasm and left focal seizures, statistical analysis of a burst of apparently bisynchronous spike and wave complexes revealed that the left hemisphere consistently preceded the other by an average of 6.4 msec.<sup>21</sup> In generalized bursts of spike and wave complexes triggered from one hemisphere, the time interval between approximately bisynchronous epileptiform discharges is similar to the one observed in so-called "primary" bilateral synchrony. The only difference is that in primary bilateral synchrony either side can be leading. These findings are consistent with the findings in Part I that primary bilateral synchrony is actually a special type of secondary bilateral synchrony in which multiple foci in both hemispheres can trigger bursts of generalized spike and wave complexes.

#### VII. Intensive EEG and videotape monitoring

In patients who have clinically generalized seizures but the EEG points to a focal abnormality, intensive EEG and videotape monitoring may be helpful in the differential diagnosis. Detailed analysis of clinical seizure onset occasionally reveals clearly defined focal symptomatology. When the focal clinical manifestations correspond with the focal disturbances in the EEG and are consistent over time, the diagnosis of a focal seizure disorder can be made with confidence.

#### References

1. IFSECN. A glossary of terms commonly used by clinical electroencephalographers. *Clin Neurophysiol* 1974; **37**:538-548.
2. Penfield W, Jasper H. *Epilepsy and the functional anatomy of the human brain*. Boston, Little, Brown, 1954.
3. Jasper H, Kershman J. Electroencephalographic classification of the epilepsies. *Arch Neurol Psychiat* 1941; **45**:903-943.
4. Morison RS, Dempsey EW. Study of thalamocortical relations. *Amer J Physiol* 1942; **135**:281-292.
5. Jasper H, Droogleever-Fortuyn J. Experimental studies on the functional anatomy of petit mal epilepsy. *Res Publ Assoc Res Nerv Ment Dis* 1946; **26**:272-298.
6. Gloor P. Generalized cortico-reticular epilepsies. Some considerations on the pathophysiology of generalized bilaterally synchronous spike and wave discharge. *Epilepsia (Aust)* 1968; **9**:249-263.
7. Gloor P, Testa G. Generalized penicillin epilepsy in the cat: effects of intracarotid and intravertebral pentylenetetrazol and amobarbital injections. *Electroenceph Clin Neurophysiol* 1974; **36**:499-515.
8. Gloor P, Quesney LF, Zumstein H. Pathophysiology of generalized penicillin epilepsy in the cat: the role of cortical and subcortical structures. II. Topical application of penicillin to the cerebral cortex and to subcortical structures. *Electroenceph Clin Neurophysiol* 1977; **43**:79-94.
9. Bancaud J. Role du cortex cérébral dans les épilepsies (généralisées) d'origine organique. Apport des investigations stéréoelectroencéphalographiques (S.E.E.G.) à la discussion de la conception centrencephalique. *Presse Med* 1971; **79**:669-673.
10. Bancaud J, Talairach J, Bonis A, Schaub G, Szikla G, Morel P, Bordasferer M. La stéréoelectroencéphalographie dans l'épilepsie. Paris, Masson et Cie, 1965.
11. Lueders H, Bustamante LA, Zablow L, Goldensohn ES. The independence of closely spaced discrete experimental spike foci. *Neurology (NY)* 1981; **31**:846-851.
12. Pollen DA. Intracellular studies of cortical neurons during thalamic induced wave and spike. *Electroenceph Clin Neurophysiol* 1964; **17**:398-404.
13. Kooi KA. *Fundamentals of electroencephalography*. New York, Harper and Row, 1971.
14. Petersen I, Sellden U, Eeg-Olofsson O. The evolution of the EEG in normal children and adolescents from 1 to 21 years. [In] Rémond A, ed. *Handbook of EEG and Clinical Neurophysiology*, Vol. 6B, 1975.
15. Zivin L, Marsan CA. Incidence and prognostic significance of "epileptiform" activity in the EEG of non-epileptic subjects. *Brain* 1968; **91**:751-778.
16. Adams DJ, Lueders H. Hyperventilation and 6-hour EEG recording in evaluation of absence seizures. *Neurology (NY)* 1981; **31**:1175-1177.
17. Browne TR, Penry JK, Porter RJ, Dreifuss FE. Responsiveness before, during, and after spike-wave paroxysms. *Neurology (Minneapolis)* 1974; **24**:659-665.
18. Penry JK, Porter RJ, Dreifuss FE. Simultaneous recording of absence seizures with video tape and electroencephalography. A study of 374 seizures in 48 patients. *Brain* 1975; **98**:427-440.
19. Halliday AM. Cerebral evoked potentials in familial progressive myoclonic epilepsy. *J Roy Coll Phys (Lond)* 1967; **1**:123-134.
20. Lueders H, Daube JR, Taylor WF, Klass DW. A computer system for statistical analysis of EEG transients. [In] Kellaway P, Petersen I, eds. *Quantitative Analytic Studies in Epilepsy*. New York, Raven Press, 1976.
21. Lueders H, Daube J, Johnson J, Klass DW. Computer analysis of generalized spike and wave complexes. *Epilepsia* 1980; **21**:183.