

Improved evaluation of pulmonary disease with gallium-67 emission tomography¹

James K. O'Donnell, M.D.
Raymundo T. Go, M.D.
Edward M. Cordasco, M.D.
David H. Feiglin, M.D.
Joseph A. Golish, M.D.
Atul C. Mehta, M.D.
Muzaffar Ahmad, M.D.
William J. MacIntyre, M.D.

Gallium-67 scintigraphy is helpful in the noninvasive evaluation of neoplastic and inflammatory pulmonary diseases. Single-photon emission computed tomography (SPECT) provides tomographic reconstructions of radioisotope distribution in the body. The addition of SPECT to gallium-67 scanning in more than 180 patients demonstrated an improvement in the already high sensitivity for the presence and extent of bronchogenic carcinoma, sarcoidosis, infection, and interstitial disease. Specificity is also improving as characteristic tomographic patterns of abnormal uptake in various conditions are becoming evident.

Index terms: Lung diseases • Lung neoplasms • Tomography, emission computed

Cleve Clin Q 52:525-531, Winter 1985

¹Departments of Nuclear Medicine (J.K.O., R.T.G., D.H.F., W.J.M.) and Pulmonary Disease (E.M.C., J.A.G., A.C.M., M.A.), The Cleveland Clinic Foundation. Submitted for publication July 1985; accepted July 1985. ht

0009-8787/85/04/0525/07/\$2.75/0

Copyright © 1985, The Cleveland Clinic Foundation

Medical imaging with gallium-67 was first proposed for the staging of neoplastic disease in 1969.¹ Shortly thereafter, it was also reported to be useful in the localization of inflammatory lesions.^{2,3} Within these two broad categories, Ga-67 scintigraphy has since proved beneficial for the noninvasive evaluation of a wide variety of diseases. These applications have developed despite a lack of exact knowledge of the mechanisms by which gallium localizes in pathologic tissues. It is known that the gallium ion behaves chemically very much like the ferric ion, having similar binding and transport properties.⁴

The increasing applications for Ga-67 imaging in neoplastic and inflammatory disease have paralleled the advancement of nuclear medicine technology. Several factors have improved the accuracy of Ga-67 imaging in recent

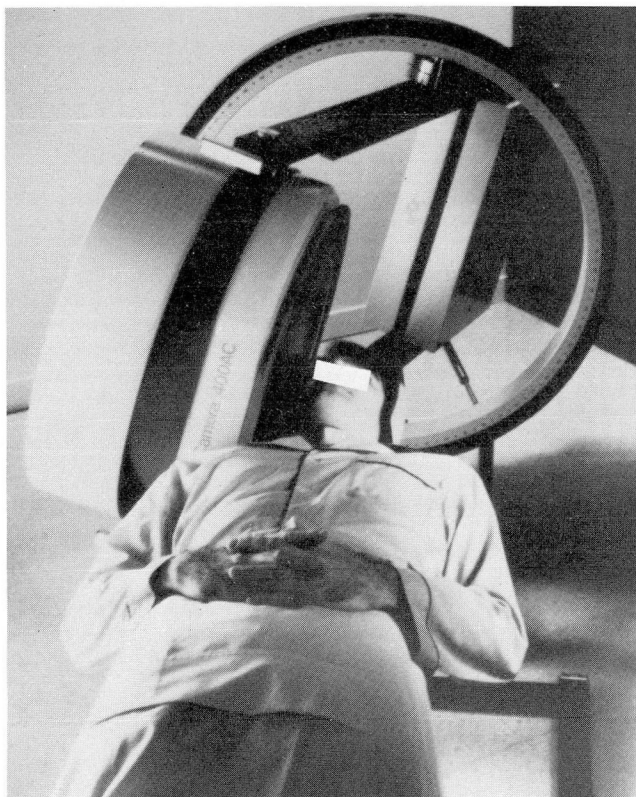


Fig. 1. Rotating gantry gamma camera. Note that the detector head is mounted on a circular gantry allowing image acquisition over a 360-degree range around the patient.

years. The scintillation gamma camera has almost totally replaced the rectilinear scanner for image acquisition. These newer cameras have advanced electronic capabilities, including specific triple-peak Ga-67 energy settings, that have resulted in improved image visualization. Knowledge of the radiation dosimetry for Ga-67 has been refined, allowing the administered dose of the isotope to be increased with no hazard to the patient. Finally, digital image acquisition with the aid of

Table. Diagnoses

Diagnosis	No.
Controls	12
Bronchogenic carcinoma	41
Sarcoidosis	39
Pneumonia	33
Interstitial fibrosis	31
Pneumoconioses	29
Pulmonary abscess	6
Tuberculosis, inactive	3
Total	194

dedicated imaging computers has become common.

A recent technique deriving from the use of computer acquisition is that of single-photon emission computed tomography (SPECT). This method of constructing tomographic images of isotope distribution within the body has added significant sensitivity and accuracy to lesion detection in cardiac, brain, and liver imaging.⁵⁻⁹ To determine the clinical value of this technique as applied to gallium scintigraphy, we have now performed Ga-67 SPECT in conjunction with routine planar Ga-67 imaging in more than 180 adult patients referred for the evaluation of a variety of suspected pulmonary diseases.

Methods

The distribution of referral diagnoses is shown in the *Table*. The control group consisted of patients for whom SPECT studies of the thorax were obtained when there was no clinical or other radiographic suspicion of pulmonary disease. These patients were usually referred for localization of intra-abdominal or extremity lesions. The patients in each of the other categories included those with known diagnoses at the time of scanning as well as patients referred without a specific diagnosis but subsequently documented to have disease.

The thoracic concentration of Ga-67 is normally very low, although there is some variable activity present in the first 24-48 hours after injection, due mostly to isotope in the circulating blood pool. Therefore, each of the patients in this series underwent both planar and SPECT image acquisition at least 48 hours after the intravenous injection of 6-10 millicuries (222-370 MBq) of Ga-67 citrate.

Planar imaging involved acquisition of anterior and posterior views of the chest for an accumulation of 500 thousand counts with the patient lying supine under a gamma camera.

For SPECT image acquisition, 64 views of the thorax were obtained in a 360-degree arc around the supine patient. This required a gamma camera mounted on a rotating gantry apparatus and interfaced to a minicomputer programmed for digital image acquisition (*Fig. 1*). Approximately 10 million total counts were obtained in the thirty minutes of acquisition time. These 64 frames of raw data were subsequently reconstructed by the computer using algorithms very similar in prin-

principle to the reconstruction provided by transmission axial tomographic (CT) scan computers. The final images provided for interpretation represented multiple image sections through the thorax of about 6-mm thickness. They were available in the coronal and sagittal planes as well as the standard transverse or transaxial orientation.

The normal planar views of the thorax (Fig. 2) demonstrate the lack of pulmonary activity and the normal uptake in the bone, thoracic cage, and liver.

The normal SPECT study (Fig. 3) likewise demonstrates lack of significant lung uptake. Several additional advantages result from the tomographic techniques. The potential interfering effect due to superposition of thoracic bony structures over the site of interest, especially in evaluating the mediastinum, is eliminated. It is also possible to localize focal lesions more accurately by consideration of multiple body planes with various orientations. Another advantage, not visible in these examples, is the use of a color display that enhances image contrast and lesion detectability.

Since the report of our initial experience with this technique in 1983,¹⁰ an ongoing series has confirmed that Ga-67 SPECT greatly enhances the usefulness of this isotope in pulmonary disease.

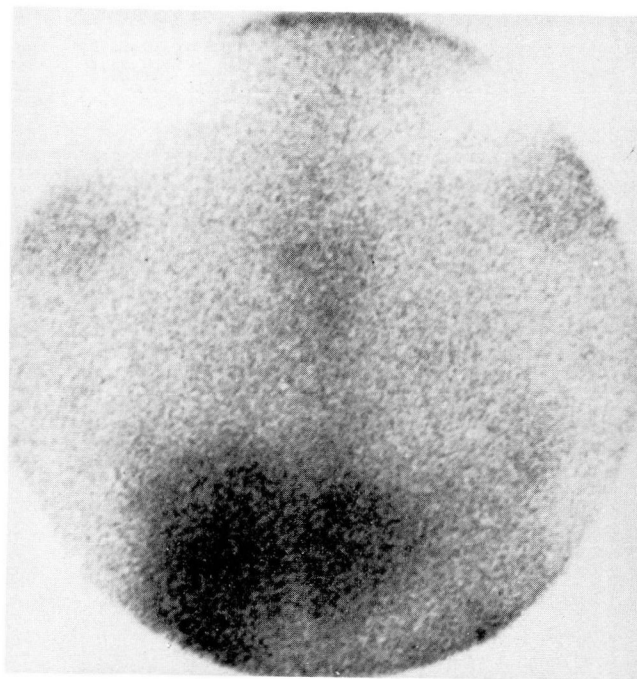
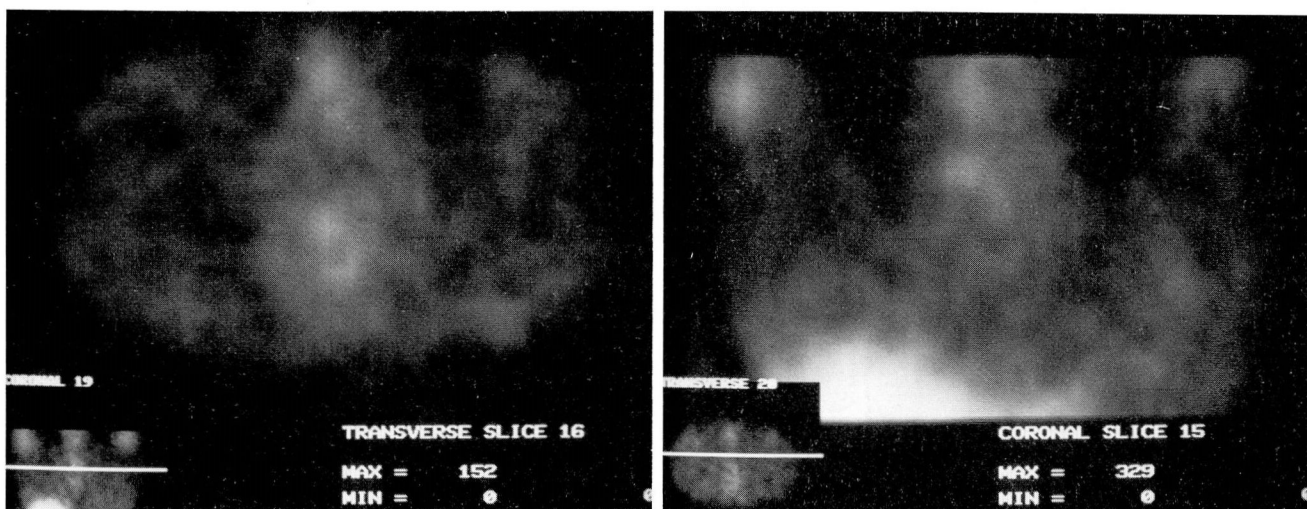


Fig. 2. Normal planar Ga-67 scan. Anterior view of the thorax shows lack of pulmonary activity and normal uptake by the liver and by bones of the sternum and shoulder.



A, B

Fig. 3. Normal SPECT Ga-67 scans.

A. Transverse image (same orientation as for CT images) through the midthorax shows normal low pulmonary background activity with slight uptake in the sternum and vertebral spine.

B. Coronal image through the central mediastinum. Normal uptake is seen in the dome of the liver.

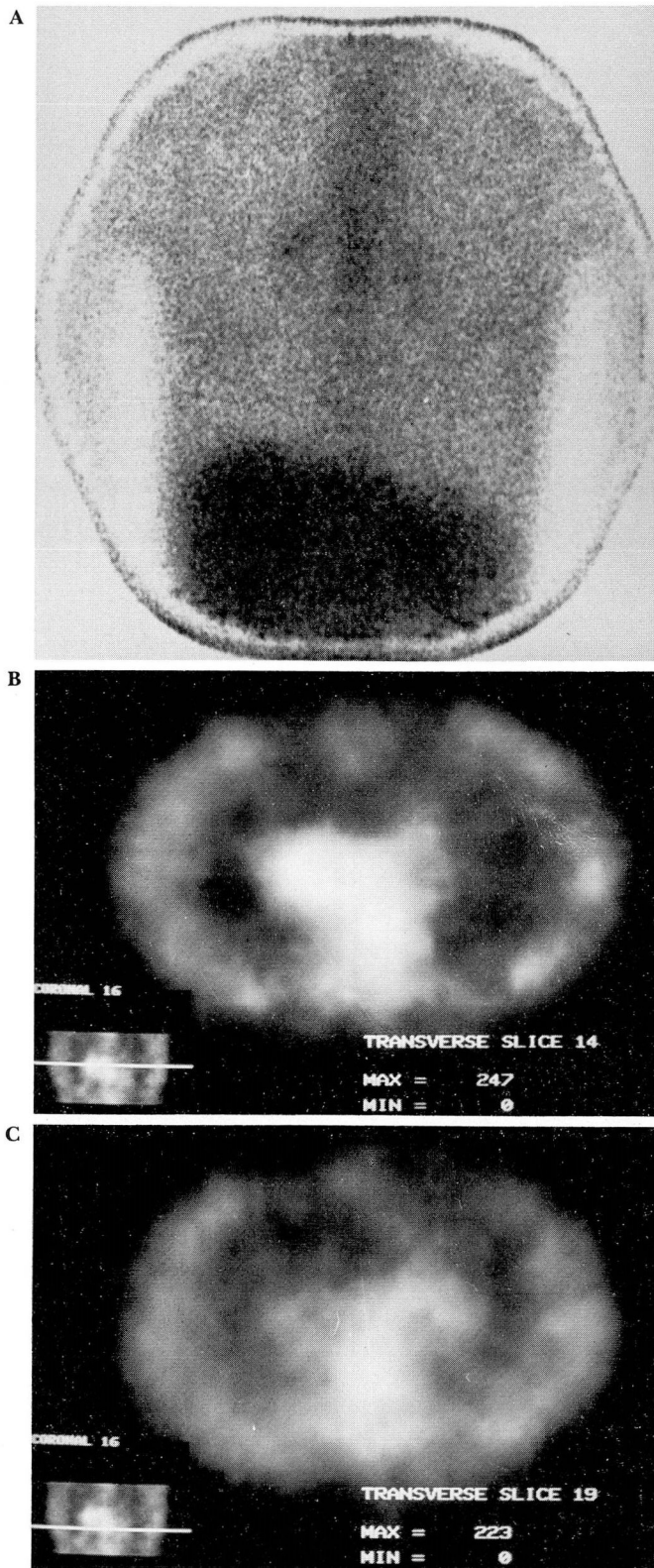


Fig. 4. Bronchogenic carcinoma.

A. Recurrent adenocarcinoma several years after right upper lobe resection. Planar scan shows gallium uptake in the right and possibly left hilar areas, but the mediastinum has no obvious activity aside from normal sternal uptake.

B. Transverse SPECT image confirms intense right hilar uptake with spread to the adjacent mediastinum.

C. Transverse SPECT image several centimeters caudal to **B.** At this level there is definite left hilar involvement and continuing mediastinal spread. All these findings were documented at thoracotomy.

Clinical applications

Bronchogenic carcinoma

Previous studies have shown planar Ga-67 scanning to be useful in the detection and staging of bronchogenic carcinoma.^{11,12} Gallium scanning is particularly accurate for evaluating potential mediastinal involvement¹³ and postoperative recurrence.¹⁴ SPECT further enhances this staging capability by eliminating superimposed sternal or vertebral uptake and by lessening the effect of the high circulating background gallium activity (*Fig. 4*). Initial comparisons with mediastinoscopy or thoracotomy have been excellent and SPECT may prove to be the noninvasive method of choice for evaluating potentially operable bronchogenic tumors.¹⁵ Ga-67 scanning is less sensitive for detecting metastases to the lung from other primary sites such as breast.¹⁶

Sarcoidosis

The lesions of active sarcoidosis have an extremely high affinity for gallium and scintigraphy is a sensitive indicator both for the extent of organ involvement and for the degree of disease activity. Planar Ga-67 scanning is more sensitive than the chest radiograph in detecting hilar node involvement.¹⁷ Comparisons with other parameters, such as angiotensin converting enzyme and serum lysozyme levels, have been variable.^{18,19} The patterns of uptake, including parotid gland involvement, frequently suggest the specific diagnosis.²⁰ A completely negative scan is strongly predictive of the absence of active disease.¹⁸ The primary advantage of Ga-67 SPECT imaging in pulmonary sarcoidosis is the more accurate localization of involvement in the hilar and mediastinal regions (*Fig. 5*). Our experience with

SPECT confirms earlier reports of the value of serial scanning as an indicator of response to steroid therapy.^{21,22}

Infection

Ga-67 scanning is a well-established aid to the diagnosis and follow up of inflammatory and infectious processes.²³ Applications in lung imaging include delineation of the extent of pneumonia in patients with abnormal baseline radiographs, early detection of opportunistic infection, and differentiation of pulmonary infections from infarction. Particularly in cases where a focal acute process such as empyema is superimposed on chronic underlying disease, SPECT is helpful in accurate diagnosis. The greater contrast afforded by the tomographic technique results in far better sensitivity for lesion detection (Fig. 6). Several studies have also documented the effectiveness of Ga-67 scans in diffuse infectious processes such as *Pneumocystis carinii* pneumonia.^{24,25} The scan will often show diffuse increased uptake before radiographic findings develop and SPECT is even more sensitive for these early subtle changes. Recent work using indium-111-labeled leukocytes has shown promise in detecting infection,²⁶ but large clinical studies comparing this technique with Ga-67 scanning for pulmonary disease remain to be done.

Interstitial disease

Ga-67 is known to localize in diffuse parenchymal lung conditions in proportion to the degree of inflammatory pneumonitis that either precedes or coexists with chronic fibrotic changes.²⁷ The inflammatory components of idiopathic pulmonary fibrosis and many occupational pneumoconioses can be accurately estimated.²⁸ Planar scans, however, are limited in their ability to demonstrate this increased uptake in the thorax relative to the normal Ga-67 activity in the ribs and the spine. Also normal liver and spleen uptake often mask subtle changes in the lung bases. Gallium-index techniques have been proposed to quantify inflammatory activity better, but these methods are somewhat subjective for choosing regions of interest and still suffer from the effects of superimposed bone and soft tissue. Our initial experience with SPECT imaging has been encouraging (Fig. 7).

Even mild degrees of abnormal uptake are identifiable and SPECT is much more accurate

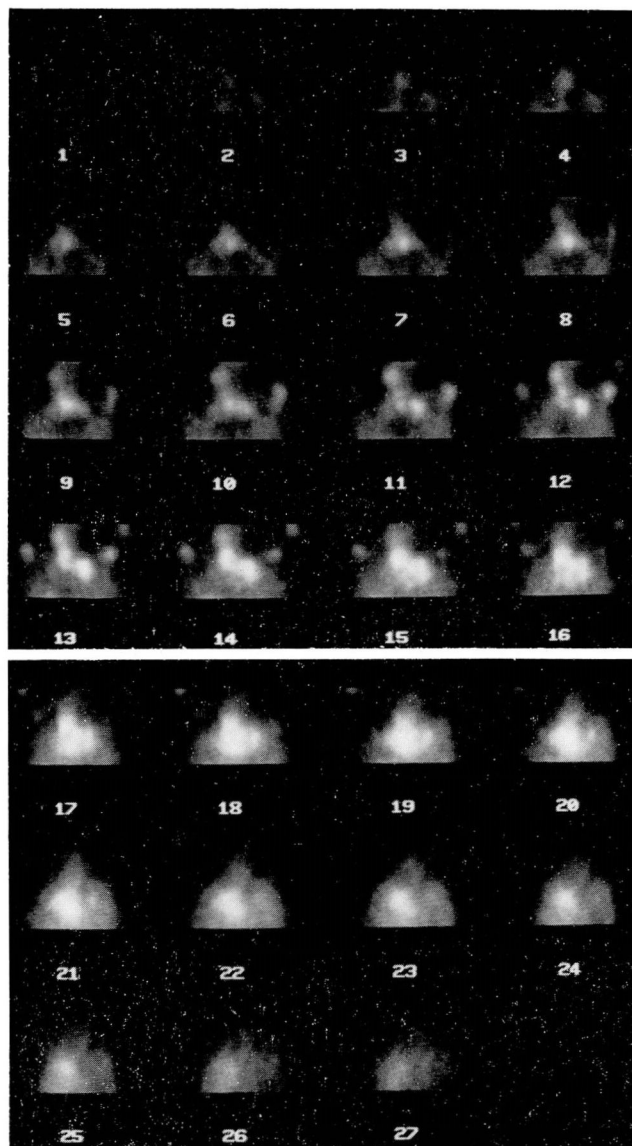


Fig. 5. Sarcoidosis. Multisection image sequence in the coronal plane progressing from anterior to posterior (1 to 27). There is central left hilar uptake extending posteriorly and bilaterally to involve the entire perihilar and mediastinal regions. Sections 11-13 also document extension to the supraclavicular and cervical nodes on the right.

in discerning the characteristically diffuse but uneven involvement of various lung regions. Regional quantification of activity based on the tomographic section information is currently being investigated at our institution.

Discussion

The addition of SPECT techniques to routine Ga-67 scanning has increased its already high

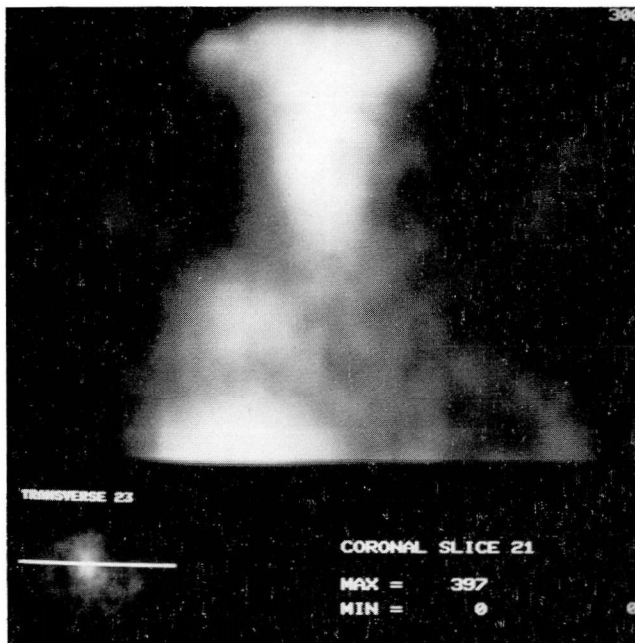


Fig. 6. Empyema. Focal accumulation of Ga-67 can be seen above the hepatic dome in the right lower lobe of this febrile patient, who had diffuse planar scan uptake and chest radiographic evidence of fibrotic change from pneumoconiosis.

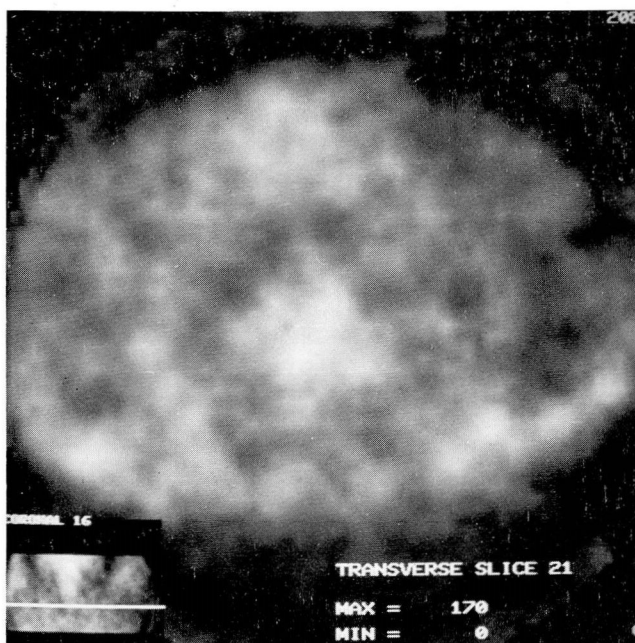


Fig. 7. Interstitial fibrosis. Transverse image demonstrates diffuse increased Ga-67 activity, slightly worse on the right, confirming a significant component of alveolitis. (Compare with *Figure 3A*.)

sensitivity for detection of disease. As appropriate for any screening procedure, the high sensitivity and predictive value of a negative scan provide accurate data for clinical decision making. The reputed nonspecificity of Ga-67 imaging is lessened by SPECT and will most likely continue to decrease as we enlarge our experience in identifying tomographic patterns of isotope distribution in various diseases. The primary advantage of the improved accuracy provided by SPECT is twofold, in the increased sensitivity for the detection of focal disease and in the documentation of disease activity in diffuse conditions.

The data obtained in tomographic studies are highly reproducible. Serial SPECT evaluations are thus reliable in determining the course of pulmonary disease activity over time and the potential response to therapeutic maneuvers. This seems to be particularly true in documenting the beneficial response to steroid therapy.

Emission tomography is emerging as a distinct improvement in the clinical application of Ga-67 scintigraphy to pulmonary disease. All patients referred to our clinic for Ga-67 evaluation of intrathoracic disease now undergo additional SPECT imaging in order to maximize the physiologic information available to guide diagnostic and therapeutic decisions.

Acknowledgment

We are grateful to Joyce Orban and Sandra O'Connell for manuscript preparation and to Robert Maynard for photography.

J. K. O'Donnell, M.D.
Department of Nuclear Medicine
The Cleveland Clinic Foundation
9500 Euclid Avenue
Cleveland, Ohio 44106

References

1. Edwards CL, Hayes RL. Tumor scanning with ^{67}Ga citrate. *J Nucl Med* 1969; **10**:103-105.
2. Lavender JP, Lowe J, Barker JR, Burn JI, Chaudhri MA. Gallium 67 citrate scanning in neoplastic and inflammatory lesions. *Br J Radiol* 1971; **44**:361-366.
3. Littenberg RL, Taketa RM, Alazraki NP, Halpern SE, Ashburn WL. Gallium-67 for the localization of septic lesions. *Ann Intern Med* 1973; **79**:403-406.
4. Hoffer P. Gallium: mechanisms. *J Nucl Med* 1980; **21**:282-285.
5. Jaszczak RJ, Whitehead FR, Lim CB, Coleman RE. Lesion

- detection with single-photon emission computed tomography (SPECT) compared with conventional imaging. *J Nucl Med* 1982; **23**:97-102.
6. Cook SA, Go RT, Napoli CA, et al. Comparison of 201-Tl planar images of myocardial perfusion with single photon transaxial tomographic images. *J Nucl Med* 1981; **22**:P34.
 7. Nohara R, Kambara H, Suzuki Y, et al. Stress scintigraphy using single-photon emission tomography in the evaluation of coronary artery disease. *Am J Cardiol* 1984; **53**:1250-1254.
 8. Lee RGL, Hill TC, Holman BL, Uren R, Clouse ME. Comparison of N-isopropyl (I-123) *p*-iodoamphetamine brain scans using Anger camera scintigraphy and single-photon emission tomography. *Radiology* 1982; **145**:789-793.
 9. Strauss L, Bostel F, Clorius JH, Raptou E, Wellman H, Georgi P. Single-photon emission computed tomography (SPECT) for assessment of hepatic lesions. *J Nucl Med* 1982; **23**:1059-1065.
 10. O'Donnell JK, Go RT, MacIntyre WJ, Napoli CA, Armstrong KL. Ga-67 emission tomography in the detection of suspected pulmonary lesions. (abstract) *J Nucl Med* 1983; **24**:P114.
 11. DeLand FH, Sauerbrunn BJL, Boyd C, et al. ⁶⁷Ga-citrate imaging in untreated primary lung cancer: preliminary report of cooperative group. *J Nucl Med* 1974; **15**:408-411.
 12. Thesingh CW, Driessen OMJ, Daems WT, et al. Accumulation and localization of gallium-67 in various types of primary lung carcinoma. *J Nucl Med* 1978; **19**:28-30.
 13. Alazraki NP, Ramsdell JW, Taylor A, Friedman PJ, Peters RM, Tisi GM. Reliability of gallium scan chest radiography compared to mediastinoscopy for evaluating mediastinal spread in lung cancer. *Am Rev Resp Dis* 1978; **117**:415-420.
 14. Hatfield M, MacMahon H, Ryan JW, et al. The role of gallium scanning in the detection of post-operatively recurrent lung cancer. (abstract) *J Nucl Med* 1985; **26**:P109-P110.
 15. O'Donnell JK, Go RT, Feiglin DH, et al. Gallium-67 emission tomography in bronchogenic carcinoma. (abstract) *Radiology* 1984; **153**:P247.
 16. Richman SD, Ingle JN, Levenson SM, et al. Usefulness of gallium scintigraphy in primary and metastatic breast carcinoma. *J Nucl Med* 1975; **16**:996-1001.
 17. Heshiki A, Schatz SL, McKusick KA, Bowersox DW, Soin JS, Wagner HN. Gallium 67 citrate scanning in patients with pulmonary sarcoidosis. *AJR* 1974; **122**:744-749.
 18. Gupta RG, Bekerman C, Sicilian L, Oparil S, Pinsky SM, Szidon JP. Gallium 67 citrate scanning and serum angiotensin converting enzyme levels in sarcoidosis. *Radiology* 1982; **144**:895-899.
 19. Weinreb RN, Barth R, Kimura SJ. Limited gallium scans and angiotensin converting enzyme in granulomatous uveitis. *Ophthalmology* 1980; **87**:202-209.
 20. Wiener SN, Patel BP. ⁶⁷Ga citrate uptake by the parotid glands in sarcoidosis. *Radiology* 1979; **130**:753-755.
 21. Niden AH, Mishkin FS, Khurana M. Use of gallium⁶⁷ lung scan to assess pathologic activity of pulmonary sarcoidosis. (abstract) *Am Rev Resp Dis* 1976; **113**(suppl):164.
 22. Johnson DG, Johnson SM, Harris CC, Piantadosi CA, Blinder RA, Coleman RE. Ga-67 uptake in the lung in sarcoidosis. *Radiology* 1984; **150**:551-555.
 23. Hoffer P. Gallium and infection. *J Nucl Med* 1980; **21**:484-488.
 24. Levin M, McLeod R, Young Q, et al. *Pneumocystis pneumonia*: importance of gallium scan for early diagnosis and description of a new immunoperoxidase technique to demonstrate *Pneumocystis carinii*. *Am Rev Respir Dis* 1983; **128**:182-185.
 25. Barron TF, Birnbaum NS, Shane LB, Goldsmith SJ, Rosen MJ. *Pneumocystis carinii* pneumonia studied by gallium-67 scanning. *Radiology* 1985; **154**:791-793.
 26. Goodwin DA, Doherty PW, McDougall IR. Clinical use of indium-111 labeled white cells: an analysis of 312 cases. [In] Thakur ML, Gottschalk A, eds. *Indium-111 Labeled Neutrophils, Platelets and Lymphocytes*. New York, Trivirium, 1981, pp 131-145.
 27. Line BR, Fulmer JD, Reynolds HY, et al. Gallium-67 citrate scanning in the staging of idiopathic pulmonary fibrosis: correlation with physiologic and morphologic features and bronchoalveolar lavage. *Am Rev Respir Dis* 1978; **118**:355-365.
 28. Siemsen JK, Sargent EN, Grebe SF, Winsor DW, Wentz D, Jacobson G. Pulmonary concentration of Ga⁶⁷ in pneumoconiosis. *AJR* 1974; **120**:815-820.