

Aneurysm of the interatrial septum¹

John H. Wilson, M.D.
Harry M. Lever, M.D.
Douglas S. Moodie, M.D.

A case is reported of aneurysm of the interatrial septum that was initially diagnosed as a right atrial myxoma using angiography. Two-dimensional echocardiography revealed a redundant interatrial septum that showed striking phasic motion. The differential diagnosis and clinical implications are discussed in light of available previous reports of interatrial septal aneurysms.

Index terms: Aneurysm • Heart septal defects, atrial

Cleve Clin Q 53:105-108, Spring 1986

Aneurysms of the interatrial septum are rare lesions that are probably congenital. They may be associated with other congenital defects, and may even be caused by lesions that markedly increase pressure in one atrium. At catheterization these aneurysms may appear as an angiographic filling defect, which may be confused with other lesions such as an intracardiac tumor.¹ The differential diagnosis also includes a thrombus, an atrial septal hematoma,² the Chiari network,³ and the eustachian valve.⁴ Congenital aneurysms of other areas of the left⁵ and right⁶ atrial walls have also been reported.

Case report

A 54-year-old woman was referred for evaluation and treatment of a suspected right atrial myxoma. She had a

history of parasternal pain and tenderness for 17 years. This had previously been diagnosed as Tietze's syndrome. She had no history of fever, systemic illness, heart murmur, nor systolic clicks. Four months before referral, a routine electrocardiogram prior to minor foot surgery was thought to show a previous myocardial infarction. She underwent cardiac catheterization, which showed a right atrial filling defect thought to represent a right atrial myxoma, and she was referred for further evaluation. The coronary arteries were normal.

Physical examination revealed a 54-year-old woman in no distress. Her blood pressure was 140/90. Auscultation of the heart revealed a regular rhythm with a rate of 70 beats per minute. There were no murmurs nor clicks. A fourth beat was present. The lungs were clear. The remainder of the examination was normal. A chemistry profile and a complete blood count were unremarkable. The electrocardiogram (Fig. 1) showed low voltage and left axis deviation. A chest radiograph was normal.

An echocardiogram was obtained and revealed a large aneurysm of the interatrial septum. The interatrial septal aneurysm appeared as a sail-like structure that moved dramatically during the cardiac cycle. It buckled toward the right atrium during late systole and early diastole, and then abruptly moved toward the left atrium during late diastole (Fig. 2). Right-sided cardiac catheterization to rule out an atrial septal defect was undertaken. No oxygen step-up was demonstrated, and injection of contrast material into the right atrium revealed no shunt lesion. A 24-hour holter monitor study revealed a predominant sinus rhythm with premature ventricular beats occasionally in couplets, but no atrial arrhythmias and no tachycardia. The patient was discharged without treatment.

Discussion

Aneurysms of the interatrial septum are usually asymptomatic.⁷ Physical findings are usually normal. The only reported abnormality on physical examination is a midsystolic click.⁸ Abnormalities of electrocardiograms and chest radiographs are usually not present, or are related to the presence of other lesions. Most cases have

¹ Department of Cardiology, The Cleveland Clinic Foundation. Submitted for publication Aug 1985; accepted Oct 1985. ht

0009-8787/86/01/0105/04/\$2.00/0

Copyright © 1986, The Cleveland Clinic Foundation

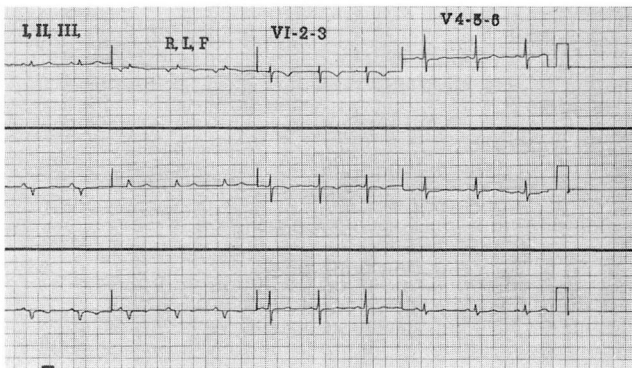


Fig. 1. Electrocardiogram demonstrating low voltage and left axis deviation.

been discovered following catheterization or surgery to define or correct other lesions. In some cases the association appears to be fortuitous, and in others there may be a causal relation. Lesions that cause increased pressure in either the left or right atrium may cause bulging of the septum. Aneurysms of the interatrial septum have been reported in association with tricuspid atresia⁹ and the hypoplastic right-sided heart syndrome,¹⁰ both of which cause increased right atrial pressure, and aortic stenosis,⁴ which causes increased left atrial pressure. Aneurysm of the atrial septum has also been reported in association with other congenital anomalies, including mitral prolapse¹¹ and transposition of the great arteries.⁴ Some cases of atrial septal aneurysm are associated with atrial septal defects.^{4,5} In addition an atrial septal aneurysm following spontaneous closure of an atrial septal defect has been reported.¹² There have been only a handful of cases where an antemortem diagnosis has been made in isolation.¹³

The incidence of these aneurysms at autopsy appears to be much greater than indicated by premortem diagnosis. Silver and Dorsey reported an incidence of 1% in a group of 1,578 autopsies.⁷ All had been asymptomatic. Now that echocardiography⁴ is widely available, the antemortem diagnosis of this condition will almost certainly increase. Other diagnostic methods that have been helpful include cardiac catheterization⁹ and digital subtraction angiography.¹⁴

A characteristic movement of the aneurysm, with bowing into the right atrium during late systole and early diastole, and into the left atrium during late diastole, was seen in our patient, and

has also been described by Canny et al.¹⁵ This movement is probably caused by instantaneous differences in right and left atrial pressures during the cardiac cycle.

Antemortem diagnosis of an aneurysm of the interatrial septum is unusual. Complications do not appear to be common, but embolic events, presumably due to the formation of a thrombus in the aneurysm, can occur.¹⁶ Also, a case of obstruction of the pulmonary veins in a patient with tricuspid atresia has been reported.¹⁷

The optimal management of such patients is not known. While emboli have been reported, the role of anticoagulation has not been established. No cases of endocarditis have been reported in association with this lesion, thus antibiotic prophylaxis would not seem to be indicated. Nor are there reports of ventricular arrhythmias in patients with atrial septal aneurysms. Supraventricular arrhythmias associated with this condition have recently been reported in three neonates.¹⁸

Harry M. Lever, M.D.
The Cleveland Clinic Foundation
9500 Euclid Avenue
Cleveland, OH 44106

References

1. Thompson JI, Phillips LA, Melmon KL. Pseudotumor of the right atrium: Report of a case and review of its etiology. *Ann Int Med* 1966; **64**:665-667.
2. Orbison JL, Mostofi FK. Hematoma of interatrial septum. *Am Heart J* 1956; **51**:636-663.
3. Werner JA, Cheitland MD, Gross BW, Speck SM, Ivey TD. Echocardiographic appearance of the Chiari network: Differentiation from right-heart pathology. *Circulation* 1981; **63**:1104-1109.
4. Gondi B, Nanda NC. Two-dimensional echocardiographic features of atrial septal aneurysms. *Circulation* 1981; **63**:452-457.
5. Foale RA, Gibson TC, Guyer DE, Gillam L, King ME, Weyman AE. Congenital aneurysms of the left atrium: Recognition by cross-sectional echocardiography. *Circulation* 1982; **66**:1065-1069.
6. Morrow AG, Behrendt DM. Congenital aneurysm (diverticulum) of the right atrium. *Circulation* 1968; **38**:124-128.
7. Silver MD, Dorsey JS. Aneurysms of the septum primum in adults. *Arch Pathol Lab Med* 1978; **102**:62-65.
8. Alexander MD, Bloom KR, Hart P, D'Silva F, Murgo JP. Atrial septal aneurysm: A cause for midsystolic click. *Circulation* 1981; **63**:1186-1188.

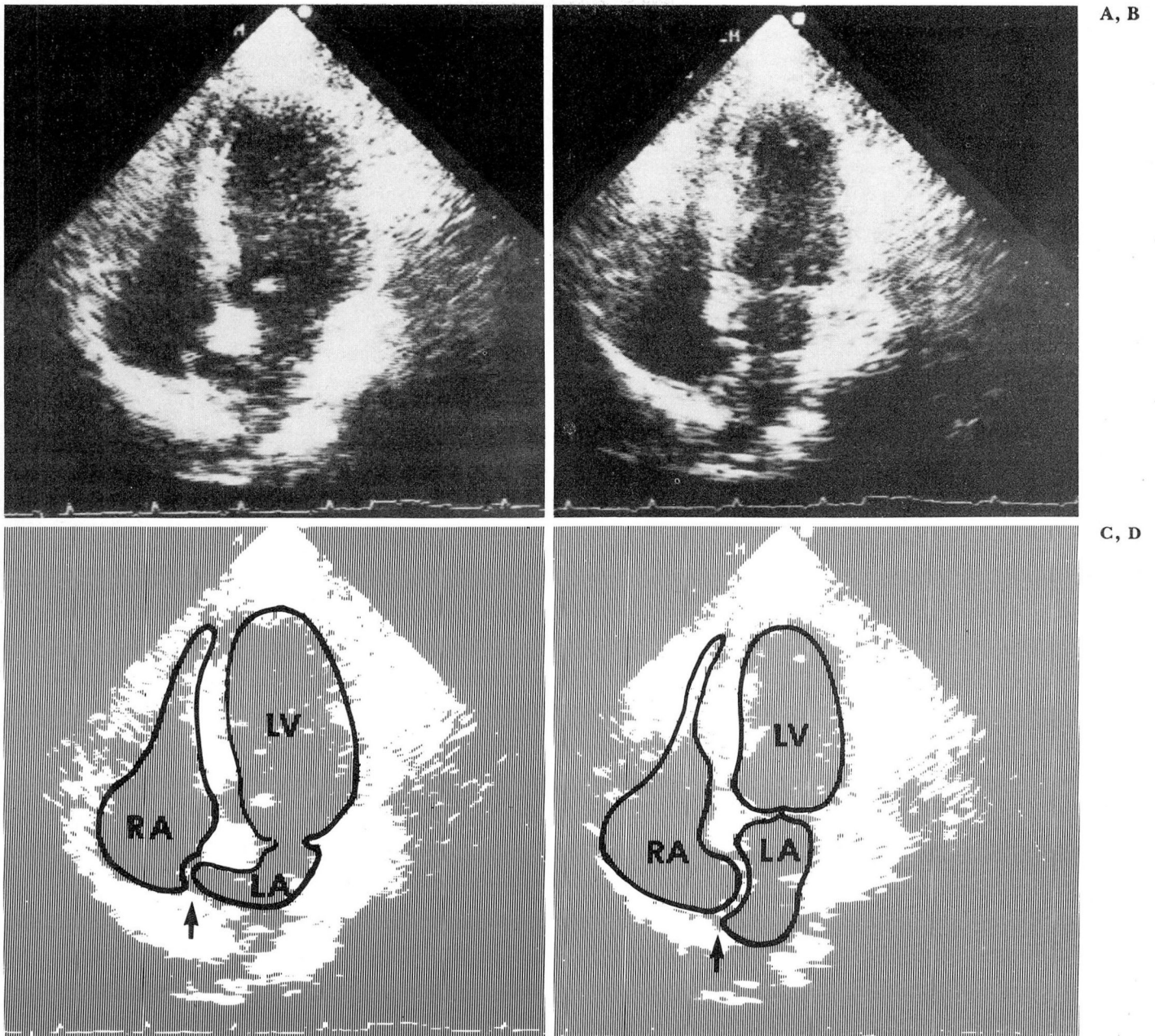


Fig. 2. Two-dimensional echocardiogram in an apical four-chamber view.
 A and C. Early diastolic frames demonstrating bowing of the interatrial septal aneurysm into the right atrium.
 B and D. Early systolic frames demonstrating bowing of the interatrial septal aneurysm into the left atrium.

9. Freedom RM, Rowe RD. Aneurysm of the atrial septum in tricuspid atresia: Diagnosis during life and therapy. *Am J Cardiol* 1976; **38**:265-267.
10. Sahn DJ, Allen HD, Anderson R, Goldberg SJ. Echocardiographic diagnosis of atrial septal aneurysm in an infant with hypoplastic right heart syndrome. *Chest* 1978; **73**:227-230.
11. Wysham DG, McPherson DD, Kerber RE. Asymptomatic aneurysm of the interatrial septum. *J Am Coll Cardiol* 1984; **4**:1311-1314.
12. Awan IH, Rice R, Moodie DS. Spontaneous closure of atrial septal defect with interatrial aneurysm formation. *Ped Cardiol* 1982; **3**:143-145.
13. Lazar AV, Pechacek LW, Mihalick MJ, DeCastro CM, Hall RJ. Aneurysm of the interatrial septum occurring as an isolated anomaly. *Cathet Cardiovasc Diag* 1983; **9**:167-173.

14. Yiannikas J, Moodie DS, Sterba R, Gill CC. Intravenous digital subtraction angiography to assess aneurysms of the ventricular and atrial septum pre- and postoperatively. *Am J Cardiol* 1984; **53**:383-385.
15. Canny M, Drobinski G, Thomas D, et al. Anévrisme de la cloison interauriculaire: diagnostic échocardiographique. *Arch Mal Coeur* 1984; **77**:337-342.
16. Grosogeat Y, Lhermitte F, Carpentier A, Facquet J, Al-homme P, Tran T. Anévrisme de la cloison interauriculaire révélé par une embolie cérébrale. *Arch Mal Coeur* 1973; **66**:169-177.
17. Reder RF, Yea H, Steinfeld L. Aneurysm of the interatrial septum causing pulmonary venous obstruction in an infant with tricuspid atresia. *Am Heart J* 1981; **102**:786-789.
18. Pernot C, Cloez JL, Khalife K, Hda A, Marçon F. Dysrythmies supraventriculaires du nouveau-né et anévrisme du septum interauriculaire. *Arch Fr Pediatr* 1984; **41**:21-25.