

# Pulmonary infiltrates and eosinophilia revisited

DAVID P. MEEKER, MD

■ Diseases characterized by pulmonary infiltrates and peripheral eosinophilia have been grouped based on a common clinical presentation. Early classification schemes viewed these syndromes as a continuum with significant overlap between categories. Although understanding of certain of these syndromes has increased, this classification system remains a useful framework for identification and diagnosis. At present, we cannot predict which patients with isolated lung involvement will progress to involvement of other organs. Early diagnosis and close follow-up are critical. Corticosteroids are the primary treatment in most of these diseases; cytotoxic agents also have a role. The role of the eosinophil in the disease process and the syndromes included in the differential diagnosis are reviewed. Loeffler's syndrome, eosinophilic pneumonia, the hypereosinophilic syndrome, allergic bronchopulmonary aspergillosis, Churg-Strauss syndrome, and tropical pulmonary eosinophilia are discussed in detail.

□ INDEX TERM: PULMONARY EOSINOPHILIA □ CLEVE CLIN J MED 1989; 56:199-211

**T**HE EOSINOPHIL, first described in 1879 by Paul Ehrlich,<sup>1</sup> has remained a relative enigma in both health and disease states. The combination of pulmonary infiltrates and eosinophilia has long fascinated the clinician, because it frequently signals a potentially reversible disorder or presents the challenge of an unusual diagnostic entity.

In a paper on pulmonary infiltrates and eosinophilia published in 1952, Reeder and Goodrich coined the term "PIE syndromes."<sup>2</sup> In the same year, Crofton et al<sup>3</sup> published their classic paper on pulmonary eosinophilia in which they divided the syndrome into five subgroups: simple pulmonary eosinophilia or Loeffler's Syndrome; prolonged pulmonary eosinophilia; pulmonary eosinophilia with asthma; tropical pulmonary eosinophilia; and polyarteritis nodosa. The authors stressed the arbitrary nature of the divisions, noting a considerable degree of overlap between some of the groups.

Authors of several recent reviews have argued for a restructured classification based on cause or on recognizable syndromes.<sup>4-6</sup> Although progress has been made in understanding specific syndromes, much has not been clarified, and the classification of Crofton et al<sup>3</sup> still serves as a useful framework in which to evaluate the patient with pulmonary infiltrates and eosinophilia. They considered the pulmonary eosinophilia syndromes, with the possible exception of tropical pulmonary eosinophilia, as part of a continuum in which there is significant overlap between categories.

Our inability to predict which patients will progress from one diagnostic category to another underscores our incomplete understanding of these disease entities. Listed in *Table 1* are syndromes in which the eosinophil appears to play a major role; a partial list of those in which it appears to play a secondary role is also included.<sup>6,7</sup> The syndromes, as currently defined, are grouped according to the original classification scheme of Crofton et al.<sup>3</sup> This article reviews the entities in-

From the Department of Pulmonary Disease, The Cleveland Clinic Foundation. Submitted June 1988; accepted Oct 1988.

Address reprint requests to D.P.M., Department of Pulmonary Disease, Cleveland Clinic Foundation, One Clinic Center, 9500 Euclid Avenue, Cleveland, Ohio 44195.

TABLE 1  
CLASSIFICATION OF PULMONARY EOSINOPHILIA

Primary pulmonary eosinophilia
Simple pulmonary eosinophilia (Loeffler's syndrome)
Parasitic infection
Drug reaction
Toxins
Prolonged pulmonary eosinophilia
Chronic eosinophilic pneumonia
Hypereosinophilic syndrome
Pulmonary eosinophilia with asthma
Allergic bronchopulmonary aspergillosis
Tropical pulmonary eosinophilia
Vasculitis
Churg Strauss syndrome
Secondary pulmonary eosinophilia
Infection
Mycobacterial infections
Fungal infections
Brucellosis
Neoplastic
Hodgkin's disease
Sarcoma
Bronchogenic carcinoma
Other
Sarcoidosis
Rheumatoid arthritis

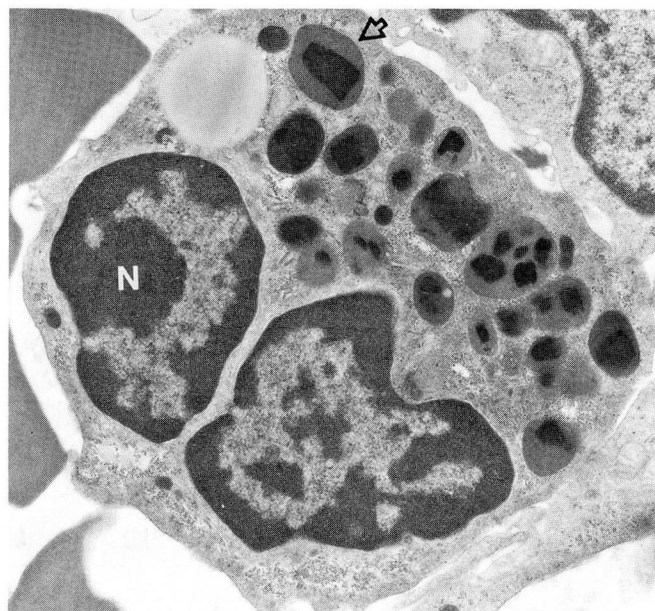


FIGURE 1. Electron photomicrograph of an eosinophil demonstrating the bilobed nucleus (N) and intracytoplasmic granules (arrow) with their electron-dense core composed of MBP and electron-radiolucent matrix (uranyl acetate, lead citrate  $\times 14,000$ ). (Courtesy of James McMahon, PhD)

cluded in the PIE syndromes, excluding those in which the eosinophilia represents only a minor component.

The secondary pulmonary eosinophilias constitute part of the differential diagnosis and may at times present with a dramatic elevation in the eosinophil count.<sup>8,9</sup> The histopathology in these diseases may mimic eosinophilic pneumonia. Failure to consider these possibilities may be potentially fatal if, for example, immunosuppressive agents are administered when there is an underlying infectious etiology.<sup>10</sup>

#### THE EOSINOPHIL

Originally considered a possible epiphenomenon, it is now recognized that the eosinophil plays an active role in the disease process. It affects the process both positively via its antihelminthic activity and as a potential modulator of the immediate hypersensitivity reaction, and negatively as a mediator of tissue damage in some hypersensitivity disease states. Research continues to identify areas not previously associated with the eosinophil, such as idiopathic pulmonary fibrosis (IPF),<sup>11,12</sup> the adult respiratory distress syndrome (ARDS),<sup>13</sup> and pregnancy.<sup>14</sup>

The structure and function of the eosinophil has been the subject of several recent reviews.<sup>14-17</sup>

The eosinophil is a bilobed granulocyte capable of ingesting bacteria, fungi, inert particles, and antigen-anti-

body complexes. In contrast to the neutrophil, the eosinophil functions inefficiently as a phagocytic cell mediating many of its effects, both beneficial and detrimental, through release of its intracellular contents. The eosinophil surface contains lysophospholipase (the Charcot-Leyden crystal protein) and receptors for IgG, IgE, and complement. Internally, it contains large and small granules that take up acid dyes such as eosin and result in the characteristic staining of the eosinophil.<sup>15</sup>

The large granules, when studied by electron microscopy, reveal an electron-dense core that consists of major basic protein (MBP) (*Figure 1*). The predominant granule protein, MBP is characterized by its strongly basic pH, with an isoelectric point greater than 10. It has only weak antibacterial activity but is toxic when released onto the surface of a parasite.<sup>16</sup> MBP exerts, in a dose-related manner, a similar toxicity when exposed to mammalian cells.<sup>18</sup> In effects that mimic the pathophysiology of asthma, MBP has been shown to impair ciliary beating and to damage guinea pig tracheal epithelium.<sup>19</sup> Its pathophysiologic role in asthma is supported by the high levels of MBP found in sputum samples from asthmatics; levels were up to 10 times those required to induce toxicity *in vitro*.<sup>20</sup> In addition to direct toxic effects, MBP may stimulate basophils and mast cells to



release histamine, further contributing to the inflammatory response.<sup>16</sup>

Proteins localized to the granule matrix include eosinophil peroxidase, which, in combination with hydrogen peroxide and a halide, is toxic to many organisms, stimulates mast cell degranulation in the rat, and inactivates leukotrienes.<sup>14,16</sup> Eosinophil cationic protein (ECP) is a basic protein that is more helminthotoxic than MBP, although quantitatively less important. ECP alters coagulation time, inhibits proliferation of cultured human peripheral blood lymphocytes, and stimulates the release of histamine from rat mast cells.<sup>14</sup> Eosinophil-derived neurotoxin (EDN) is a potent neurotoxin when injected intrathecally into rabbits or guinea pigs. Its physiologic role in humans remains unclear. Collagenase is an enzyme capable of cleaving human lung collagens type I and III.<sup>12</sup> These granule proteins, as well as a number of lipid mediators, such as leukotriene C4 and platelet-activating factor, play an integral role in producing the myriad effects associated with eosinophil activation.

The eosinophil is produced exclusively in the bone marrow in the human adult. While eosinophils are normally present in small quantities, marked increases may occur in specific disease states. This increased production has been shown to be under T lymphocyte control.<sup>15</sup> The eosinophil responds to multilineage growth regulators, such as granulocyte/macrophage colony-stimulating factor (GM-CSF) and interleukin III, and to lineage-specific eosinophil growth regulators such as eosinophil colony-stimulating factor.<sup>21</sup> In addition to stimulating production and differentiation, these growth regulators activate mature eosinophils, increasing their parasite-killing ability.<sup>14</sup> Clinically, the activated cells appear hypodense compared with eosinophils from normals, and are noted in increased concentrations in disease states associated with hypereosinophilia.<sup>22,23</sup>

The eosinophil in humans is predominantly a tissue-dwelling cell; the number of eosinophils in tissue exceeds the level in circulating blood by approximately 100–300 to one.<sup>15</sup> The eosinophil circulates for 4–10 hours before exiting into the tissue, where it persists for days. The cell is found most prominently in the submucosal tissue of organs exposed to the environment, such as the respiratory tract, the gastrointestinal tract, and the genitourinary tract. The exact regulatory mechanisms governing eosinophil distribution remain unclear. Many factors are chemotactic for eosinophil, including: activated complement, lymphocyte-derived lymphokines, mast-cell-derived histamine, eosinophilic chemotactic factor of anaphylaxis (ECF-A), and leuko-

triene B4.<sup>15</sup> Some of these factors serve not only to attract eosinophils but to immobilize them locally, as in the area of inflammation. IgE-mediated release of mast-cell chemotactic factors explains in part the localization of eosinophils in disease states such as asthma. However, in diseases such as chronic eosinophilic pneumonia or the hypereosinophilic syndrome, the mechanism remains unclear.

---

#### PERIPHERAL EOSINOPHILIA

---

Peripheral eosinophilia is the hallmark of the PIE syndromes. Crofton et al<sup>3</sup> arbitrarily defined it as “greater than 6% eosinophils on the differential white blood cell count.” However, multiple factors affect peripheral counts and significant tissue eosinophilia may be present in the absence of peripheral eosinophilia. Horn et al<sup>24</sup> measured total eosinophil counts in normals and found a mean level of  $122 \pm 74$  per  $\text{mm}^3$  with only one individual having a count greater than  $350$  per  $\text{mm}^3$ . All asthmatic patients not taking steroids had counts greater than  $350$  per  $\text{mm}^3$ . Higher counts are usually seen in patients with one of the PIE syndromes.<sup>6</sup>

Eosinophil counts undergo a diurnal variation with counts being highest at night and lowest in the morning, the converse of the normal variation in plasma corticosteroid levels. The mechanism of corticosteroid-induced eosinopenia is unclear and may relate in part to decreased eosinophil adherence and chemotaxis.<sup>25</sup> Other factors affect counts, including beta adrenergic stimulation.<sup>26</sup> Epinephrine lowers counts and beta adrenergic blockade with propranolol increases counts by a mean of 28%. Therefore, while useful as a disease marker, the eosinophil count is less useful as an index of disease severity.

---

#### SIMPLE PULMONARY EOSINOPHILIA (LOEFFLER'S SYNDROME)

---

Simple pulmonary eosinophilia or Loeffler's syndrome is characterized by transient pulmonary infiltrates, peripheral eosinophilia, and mild symptoms.<sup>3</sup> In the majority of cases in Loeffler's original series the disease was secondary to the parasitic infection *Ascaris lumbricoides*. Additional cases reviewed by Crofton et al<sup>3</sup> were attributed to miscellaneous allergens such as pollen and sulfonamides.

It is now clear that a number of helminths may, during migration through the lungs, produce transient pulmonary infiltrates and eosinophilia (Table 2). The specific life cycles of the parasites, reviewed elsewhere, are beyond the scope of this article.<sup>27</sup>

**TABLE 2**  
PARASITES CAUSING PULMONARY EOSINOPHILIA

<i>Ascaris lumbricoides</i>
Hookworm
<i>Ancylostoma duodenale</i>
<i>Necator americanus</i>
Cutaneous larva migrans
<i>Ancylostoma braziliense</i>
Visceral larva migrans
<i>Toxocara canis</i>
<i>Toxocara cetis</i>
<i>Strongyloides stercoralis</i>
<i>Paragonimus westermani</i>
Schistosomiasis
<i>Schistosoma mansoni</i>
<i>Schistosoma haematobium</i>
<i>Schistosoma japonicum</i>
<i>Trichinella spiralis</i>

Symptoms are usually self-limiting and may include cough, dyspnea, and wheezing, suggesting a diagnosis of asthma. Eosinophilia may be absent at the onset of respiratory symptoms. Compounding the diagnostic dilemma, stool samples may be negative for ova or parasites. If larval forms can be demonstrated in respiratory secretions, gastric aspirates, or by serologic testing, a positive diagnosis can be made. Due to the self-limiting nature of the respiratory symptoms, biopsy specimens have rarely been obtained.

Drug reactions constitute the other major cause of Loeffler's syndrome. A partial list of medications reported to cause hypersensitivity reactions involving the lung are included in Table 3.<sup>28-30</sup> Clinically, patients may present with fever, dyspnea, and pulmonary infiltrates. Peripheral eosinophilia often raises the possibility of a drug reaction. However, a hypersensitivity reaction with pulmonary eosinophilia may occur without a concomitant elevation in the eosinophil count.<sup>31</sup> In the patient with pulmonary infiltrates of unknown etiology, the possibility of a drug reaction should at least be entertained. Symptoms and clinical findings typically resolve when the drug is discontinued.

Lung biopsies have revealed infiltrates of eosinophils, lymphocytes, and histiocytes compatible with a diagnosis of eosinophilic pneumonia. However, in one case, a patient with a hypersensitivity reaction to sulfasalazine presented with infiltrates and peripheral eosinophilia that resolved upon cessation of the drug. Transbronchial biopsy revealed only an interstitial pneumonitis without eosinophil infiltration.<sup>32</sup>

Tissue eosinophilia, therefore, may not be a universal finding. The varied pathologic findings suggest the potential for different underlying disease mechanisms; proposed mechanisms include an allergic reaction to a

**TABLE 3**  
DRUGS THAT CAUSE HYPERSENSITIVITY LUNG DISEASE

Bleomycin
Methotrexate
Procarbazine
Nitrofurantoin
Sulfasalazine
Diphenylhydantoin
Carbamazepine
Chlorpropamide
Imipramine
Naproxen
Para-aminosalicylic acid
Penicillin
Cromolyn
Dantrolene
Methylphenidate
Mephensin carbamate
Hydralazine
Mecamylamine
Ampicillin

Modified from Cooper et al. Drug-induced pulmonary disease. *Am Rev Respir Dis* 1986; 133:488-505.

foreign antigen or a drug-induced alteration in the normal immune balance.<sup>28</sup>

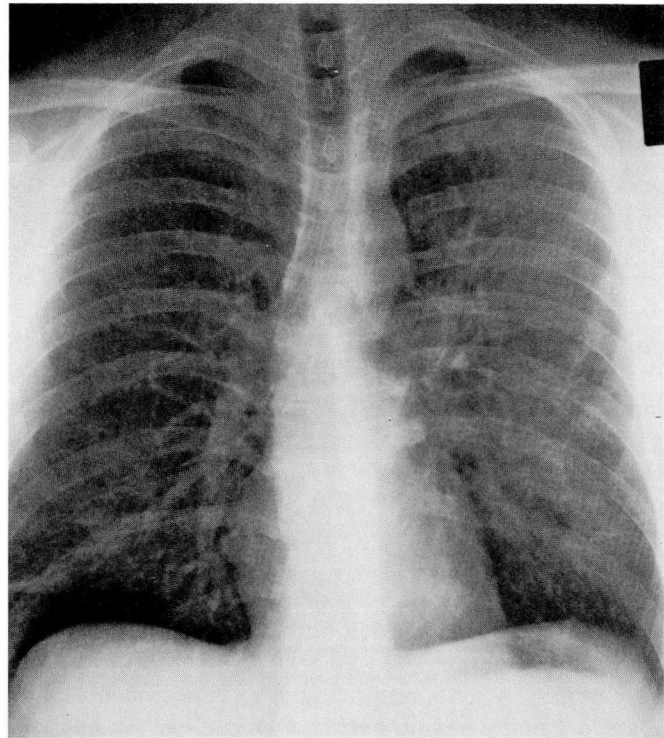
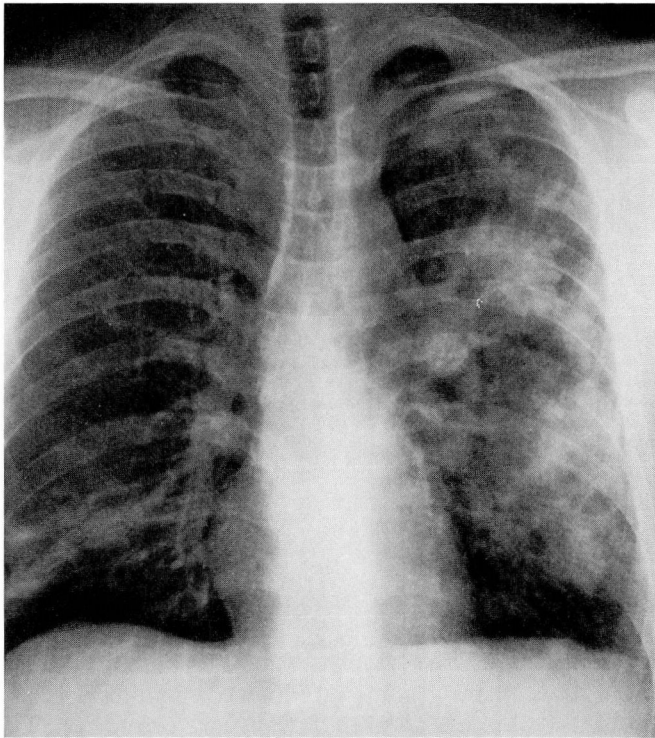
#### CHRONIC EOSINOPHILIC PNEUMONIA

Chronic eosinophilic pneumonia (CEP), a term popularized by Carrington et al<sup>33</sup> in 1969, has emerged as a distinct clinical entity, albeit of unknown etiology. The classic clinical presentation is a middle-age white female with fever, weight loss, night sweats, and dyspnea. Asthma may accompany or precede the onset of symptoms and has been noted in approximately 50% of cases.<sup>33-35</sup> The duration of illness prior to diagnosis has varied from weeks to months; early diagnosis has been more frequent with increased awareness of this syndrome.

Peripheral eosinophilia, defined as greater than 6% eosinophils, remains the hallmark of this syndrome. However, because eosinophilia is absent in up to one-third of cases, diagnosis may be delayed.<sup>33,36</sup> Additional laboratory values associated with, but not specific for, CEP, have included an elevated sedimentation rate<sup>20,21</sup> that may exceed 100 mm/hr and thrombocytosis.<sup>37</sup> Both levels have normalized with treatment. Elevated IgE levels have been reported in occasional cases and their relationship to the disease process remains unclear.<sup>38</sup>

Chest radiographic findings have been extensively described by Gaensler and Carrington.<sup>39</sup> They noted the classic peripheral opacities in 53/81 (65%) of reported cases, for which they coined the term "photographic negative of pulmonary edema" (Figure 2). Un-





A, B

FIGURE 2A. Radiograph demonstrating the peripheral infiltrates of eosinophilic pneumonia. FIGURE 2B. Radiographic clearing after two weeks of steroid therapy.

usual chest radiographic findings include pleural effusions, cavitation, and migratory pulmonary infiltrates.<sup>34,36</sup> Lymph node enlargement is unusual and may be evident on computed tomography of the chest, when not identified on the plain radiograph.<sup>40</sup> Histopathologic study of excised lymph nodes has demonstrated eosinophilic infiltration.<sup>33</sup>

Analogous to the finding of normal chest radiograph in the presence of interstitial lung disease,<sup>41</sup> eosinophilic pneumonia without infiltrates has been reported in one patient who presented with a compatible clinical picture, 48% eosinophils on bronchoalveolar lavage, and typical histopathologic findings on open lung biopsy.<sup>42</sup>

Histopathologic study in CEP reveals an interstitial and alveolar infiltration of eosinophils and macrophages, with lymphocytes and plasma cells also evident. Multinucleated giant cells and eosinophil microabscesses are commonly present.<sup>32,35,38</sup> Minimal patchy interstitial fibrosis has been noted, although a significant fibrotic response is not characteristic of CEP.<sup>33,43</sup> Electron microscopy reveals evidence of eosinophil degranulation and free eosinophil granules.<sup>35,38,43</sup> Free granules have been identified close to denuded basement membrane in various stages of disintegration, furthering the

suspicion that eosinophil granule products contribute to the architectural derangement seen in CEP.<sup>38</sup>

The debate continues over the role of bronchoalveolar lavage (BAL), transbronchial biopsy, and open lung biopsy in the diagnosis of CEP. BAL has been developed as a means of sampling cells from the small airways and alveoli. The bronchoscope is wedged into a subsegmental bronchus, followed by infusion of 20–50 mL of sterile saline. The procedure is repeated until 60–100 mL of lavage fluid has been obtained. Cell differential counts of BAL fluid from nonsmoking normal controls typically reveal 85% macrophages, 1%–2% neutrophils, < 1% eosinophils or basophils, and 7%–12% lymphocytes.<sup>44</sup> The usefulness of BAL as a means of assessing inflammatory disorders of the lower respiratory tract continues to be evaluated. BAL in CEP has revealed an increased number of eosinophils.<sup>45,46</sup> The role of BAL as a diagnostic endpoint or as a means of following therapeutic response remains to be established.

With a classic clinical presentation of eosinophilia, of peripheral infiltrates and constitutional symptoms, a diagnostic trial of corticosteroids has been advocated.<sup>47</sup> Infectious diseases, such as tuberculosis, coccidioidomycosis, histoplasmosis, and brucellosis, that may present

with eosinophilia should be considered before beginning treatment with steroids. Variations on the classic presentation have been increasingly reported; in such cases a tissue diagnosis is warranted. One atypical presentation is the adult respiratory distress syndrome, which, in the absence of a peripheral eosinophilia, may pose a considerable diagnostic challenge.<sup>36</sup> The authors of this report stress that in the presence of more extensive lung damage, the response to steroids may be delayed, and a diagnostic trial of steroids may be inconclusive.

The etiology of chronic eosinophilic pneumonia is unknown. Case reports in which the activity of CEP has paralleled the activity of other diseases, such as ulcerative colitis and eosinophilic enteritis, are intriguing in that they raise the possibility of a common antigenic stimulus.<sup>37,48</sup> However, immune complexes have not been identified in lung tissue.<sup>37</sup>

CEP, as it is presently defined, may represent a heterogeneous group of disorders with a common mechanism of tissue injury mediated by eosinophil infiltration and degranulation. Failure to identify a specific etiologic agent precludes development of a more exact classification scheme.

### Treatment

Corticosteroids are the mainstay of treatment in CEP; most patients exhibit a dramatic response to doses of 20 to 40 mg of prednisone daily. Symptomatic improvement usually occurs within hours and the chest radiograph clears within one to two weeks.<sup>34</sup> Radiographic improvement may be noted within 48 hours. Attempts to taper the steroid dose commonly result in relapse and patients may require chronic corticosteroid therapy.

---

### HYPEREOSINOPHILIC SYNDROME

---

Patients with persistent eosinophilia of unknown etiology for more than six months have been described as having the hypereosinophilic syndrome (HES). The syndrome is defined as an eosinophil count of 1500 per mm<sup>3</sup> for at least six months or death before six months with signs and symptoms of HES disease; lack of evidence for parasitic, allergic, or other recognized causes of eosinophilia despite careful evaluation; signs and symptoms or organ system involvement or dysfunction either directly related to the eosinophilia or unexplained in the given clinical setting.<sup>49</sup>

The largest series of patients with HES has been reported from the National Institutes of Health (NIH).<sup>49</sup>

Onset of disease in the majority of patients was between 20 and 50 years of age. HES has been reported in infants as young as five months.<sup>50,51</sup> Virtually any organ system may be involved, although the neurologic (64%), skin (56%), and cardiovascular (54%) systems were affected most often in the NIH study.

Cardiac involvement remains the major source of morbidity and mortality. Pathologically, endocardial fibrosis, myocardial inflammation, and mural thrombus formation develop, frequently accompanied by valvular insufficiency.<sup>49,52</sup> The pathologic findings are similar to those described in Loeffler's fibroplastic parietal endocarditis, suggesting that they may represent the same disease process. Myocardial biopsies reveal early damage to the endothelial cell and not the myocardial cell. Endothelial cell damage may serve as an initiator of thrombosis, with recurrent episodes resulting in tissue damage and fibrous thickening of the endocardium. Untreated, patients may develop congestive heart failure.

Pulmonary involvement occurs in 40% of patients.<sup>49</sup> With prolonged involvement, the disease may progress from inflammatory pulmonary disease to pulmonary fibrosis, usually with associated cardiac involvement. Autopsy studies reveal interstitial eosinophilic infiltrates and, less commonly, areas of necrosis postulated to be secondary to pulmonary microthromboemboli.<sup>53</sup> Lung pathology in HES and the other disease states associated with pulmonary eosinophilia is nonspecific. It remains impossible to predict which patients with eosinophilia and isolated lung involvement may go on to other organ system involvement. Initially, infiltrates may resolve, thereby suggesting a diagnosis of Loeffler's syndrome or CEP; additional organ system involvement becomes apparent only later. Patients with pulmonary infiltrates and eosinophilia of unclear etiology should, therefore, receive appropriate long-term follow-up.

HES, as currently defined, is a heterogeneous disorder. In some cases, the eosinophilia may reflect a clonal proliferation of cells, although no specific cellular markers have been identified to confirm this postulate. In other cases, it may reflect a response to an unidentified antigen. Eosinophilic leukemia has been placed under this heading. Blast forms should be present in the blood, bone marrow, and tissues if this diagnosis is to be made.<sup>50</sup> In two cases of HES reported from the NIH, patients presented with hypereosinophilia and a lymphocytic vasculitis.<sup>54</sup> T cell lymphoma developed several years later in both patients. The authors postulated that the eosinophilia was secondary to factors released by abnormal T cells. Regardless of the underlying etiology, organ system involvement in HES appears to be second-



ary to the eosinophilia and not the specific underlying disease state. Similar pathologic changes have been seen in patients with idiopathic HES and well-defined causes of eosinophilia.<sup>49</sup>

### Treatment

Historically, survival in HES has been poor; a 12% three-year survival has been reported.<sup>55</sup> High peripheral leukocyte counts (90,000–100,000 per mm<sup>3</sup>), blast forms in the peripheral blood, and the appearance of congestive heart failure were indicators of a poor prognosis.

In the NIH series, patients without progressive organ system dysfunction were followed up at three- to six-month intervals.<sup>49</sup> If organ system dysfunction developed, they were treated with prednisone 1 mg/kg daily and medication was tapered to an alternate day regimen. If the disease progressed while the patient was taking prednisone, hydroxyurea, 0.5 to 1.5 g/d, was added with the goal of maintaining the leukocyte count at less than 10,000 per mm<sup>3</sup>. Cardiovascular complications were managed aggressively with medical and surgical intervention. Overall survival in the treated group improved compared with the historical control group; the three-year mortality rate was 4%.

Troleandomycin, a macrolide antibiotic, exhibits a steroid-sparing effect when combined with methylprednisolone in the treatment of severe steroid-dependent asthmatics.<sup>56</sup> It proved similarly effective in one patient with HES, and it may have a future role in the treatment of this disease.<sup>57</sup>

---

### ALLERGIC BRONCHOPULMONARY ASPERGILLOSIS

---

Asthma is a frequent component of these syndromes and must be considered in the differential diagnosis of pulmonary infiltrates and eosinophilia. It is one of the diagnostic criteria of allergic bronchopulmonary aspergillosis (ABPA). Originally described in England in 1952,<sup>58</sup> ABPA has been increasingly recognized in the United States.

The disease may begin in childhood as early as age two, be managed as simple bronchial asthma, and go undiagnosed for years.<sup>59</sup> Diagnostic criteria include: asthma; blood eosinophilia greater than 1,000 per mm<sup>3</sup>; immediate cutaneous sensitivity to *Aspergillus fumigatus* (AF) antigen; elevated serum IgE concentration; precipitating antibodies to AF; history of radiographic infiltrates transient or fixed; and central bronchiectasis. Secondary criteria include: *A. fumigatus* in the sputum; history of expectoration of brown plugs or flecks; and late skin test reactivity to *Aspergillus* antigen.<sup>60</sup>

Chest radiographs may reveal transient infiltrates, “gloved finger” or “toothpaste” shadows suggestive of mucoid impaction, and bronchiectasis frequently involving the upper lobes<sup>61</sup> (Figure 3). In early stages, patients may have serologic evidence of ABPA and a normal chest radiograph.<sup>62</sup> Fibrotic changes may predominate in late stages.<sup>63</sup> Lung biopsy specimens may reveal dilated bronchi filled with inspissated mucus. Mononuclear cells and eosinophils infiltrate the bronchial walls. Lung parenchyma from areas of consolidation reveals prominent eosinophil infiltration, granuloma formation, and multinucleated giant cells.<sup>64</sup>

No single criterion is diagnostic of ABPA. Eosinophilia, serum precipitins, skin test hypersensitivity, and an elevated IgE level may all exist in the asthmatic patient without ABPA.<sup>59</sup> In addition, a patient may present with serologic criteria for ABPA without associated asthma, increasing diagnostic dilemma.<sup>65</sup> IgE and IgG antibodies against AF antigen have been detected by radioimmunoassay. They are significantly elevated in ABPA compared with normal controls and with the population of asthmatics who are skin-test reactive to AF.<sup>66</sup> Patterson et al<sup>67</sup> have proposed using IgE-AF and IgG-AF serum antibody indices from asthmatics with skin tests positive to AF as a control. The patients with ABPA would have increased antibody levels when compared with asthmatics with skin test hypersensitivity.<sup>67</sup>

*Aspergillus* species are ubiquitous in nature. In ABPA, it is presumed that *Aspergillus* hyphae are trapped in the tenacious bronchial secretions and colonize the bronchial tree, subsequently releasing antigens.<sup>59,61</sup> Although ABPA is most commonly caused by *A. fumigatus*, other *Aspergillus* species have been implicated.<sup>68</sup> The host immune response involves a polyclonal antibody response with increases in all five classes of immunoglobulins,<sup>69</sup> although most attention has been paid to the increase in IgE, IgG, and IgA antibodies against AF antigen.<sup>66,70</sup> Pulmonary damage appears to depend upon the presence of both IgE-AF and IgG-AF antibodies with IgE enhancing the tissue-damaging effects of IgG. The pathologic changes of ABPA were reproduced in monkeys when both IgE-AF and IgG-AF were present, whereas either antibody alone caused no pulmonary damage.<sup>64</sup>

Although the exact mechanism of tissue damage in ABPA is unknown, it appears to involve a multifaceted immune response. Ricketti et al<sup>71</sup> have demonstrated that basophils obtained from patients with ABPA release increased amounts of histamine when exposed to AF antigen, compared with cells obtained from patients with mold-sensitive asthma. They suggest that a similar

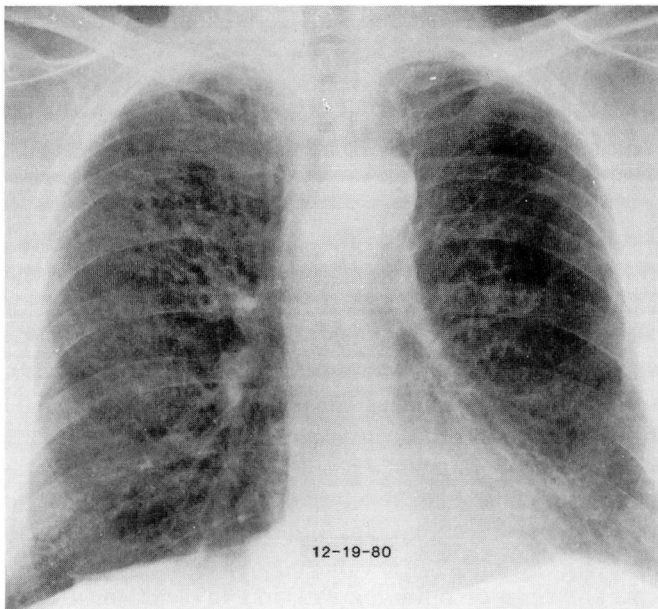
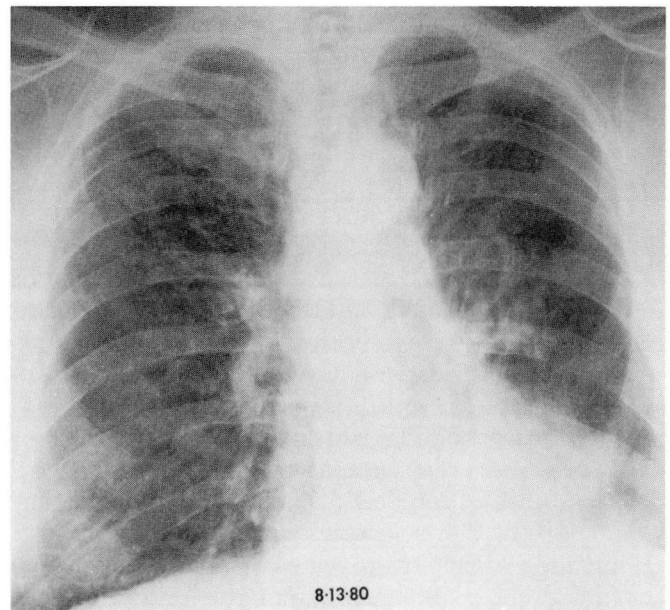
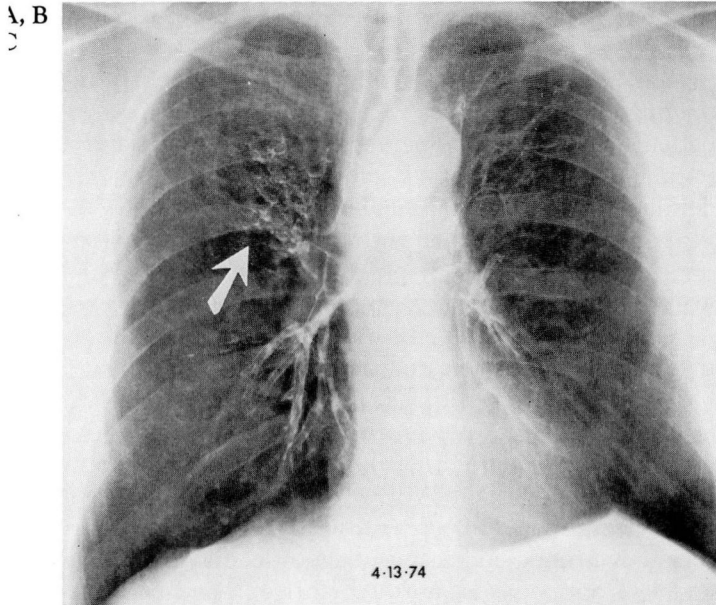


FIGURE 3A. Bronchogram demonstrating changes of proximal saccular bronchiectasis in the right upper lobe (arrow). FIGURE 3B. Chest radiograph of the same patient six years later during an exacerbation of his ABPA revealing left middle and lower lung field infiltrates. FIGURE 3C. Radiograph six months later demonstrating clearing of the left lung infiltrates.

Patients are diagnosed in stage one and are re-classified into one of the other stages after six months of tapering prednisone doses and observation. Disease progression is unpredictable and patients do not necessarily progress serially from one stage to the next.<sup>63</sup> Patterson and colleagues<sup>62</sup> argue that serologic diagnosis and early treatment in the absence of chest radiographic abnormalities may prevent progression to the fibrotic stage.

### Treatment

Prednisone remains the cornerstone of management in this disease, both in the treatment of the acute stage and recurrent exacerbations. Ricketti et al<sup>61</sup> have recommended a daily dose of 5 mg/kg/day until there is radiographic evidence of chest improvement. The dosage is then tapered to an alternate day regimen for a minimum of three months.

Improvement should be accompanied by a greater than 35% reduction in IgE levels.<sup>74</sup> Serial IgE levels are useful in following disease progression, since the patient with ABPA may be asymptomatic during an exacerbation. A two-fold increase in IgE levels heralds an exacerbation and a chest radiograph should be obtained. Evi-

pulmonary mast-cell hyperactivity of AF antigen may, in part, mediate the tissue damage in ABPA. The presence of granuloma formation and mononuclear cell infiltration have implicated a cell-mediated immune response. However, this has not been confirmed through demonstration of a peripheral cell-mediated immune response.<sup>72</sup>

Patterson et al,<sup>73</sup> in an attempt to facilitate diagnosis and management, have identified five stages of the disease: acute stage, remission, recurrent exacerbations, corticosteroid-dependent asthma, and the fibrotic stage.



dence of deterioration will require an adjustment in prednisone dosage.

A preliminary study evaluating the use of ketoconazole revealed a decrease in IgE and IgG levels when compared with placebo. Although further study is required, these findings suggest a role for ketoconazole in the treatment of ABPA.<sup>75</sup>

Long-term follow-up of eight patients with stage IV corticosteroid-dependent asthma-ABPA revealed no progression to the fibrotic stage when patients were closely followed and the prednisone dosage was adjusted at the time of exacerbations.<sup>76</sup> Similarly, a review of 17 cases with fibrotic-stage ABPA revealed stabilization of lung function in the 11 surviving patients with close follow-up and appropriate corticosteroid therapy.<sup>77</sup> This underscores the importance of considering the diagnosis of ABPA in the patient with fibrotic lung disease and asthma, as well as in the patient with the more classic presentation of pulmonary infiltrates and eosinophilia. Intervention may prevent disease progression.

---

#### CHURG-STRAUSS SYNDROME

---

The vasculitic entity polyarteritis nodosa (PAN) made up the fifth category of Crofton et al.<sup>3</sup> They noted the rarity with which PAN was associated with eosinophilia and pulmonary infiltrates. Churg and Strauss<sup>78</sup> in 1951 described a series of patients with asthma, eosinophilia, and vascular lesions similar to the type seen in PAN. This disease entity, alternatively called Churg-Strauss syndrome (CSS) or allergic angiitis and granulomatosis, remains a source of debate among those attempting to classify the systemic vasculitides.

Fauci makes a clear distinction between classic polyarteritis nodosa (PAN) and allergic angiitis and granulomatosis. The former is a necrotizing vasculitis of small and medium-sized arteries, while the latter is a disorder that: frequently involves pulmonary vessels, involves blood vessels of various types and sizes including veins and venules, has intravascular and extravascular granuloma formation, has eosinophilic tissue infiltration, and is associated with severe asthma and peripheral eosinophilia.<sup>79</sup> Cases that overlap these two syndromes or one of the other systemic vasculitides were grouped into the polyangiitis overlap syndrome.

The classic clinical syndrome of asthma, eosinophilia, and systemic vasculitis remains a relatively rarely diagnosed syndrome. Lanham et al have attributed this to rigid adherence to three major histologic criteria: necrotizing vasculitis, tissue infiltration by eosinophils, and extravascular granulomas.<sup>80</sup> They argue that only

rarely are all three factors found in one patient. Granulomas, in particular, may be difficult to find on tissue biopsy specimens.

They have divided the disease into three distinct phases in an attempt to facilitate clinical recognition of the disease. The prodromal or allergic phase is characterized by asthma with or without associated allergic rhinitis. Asthma characteristically precedes the diagnosis of vasculitis and has a variable relationship to the activity of the vasculitis. In a review of the literature by Lanham et al,<sup>80</sup> 58% of patients were free of their asthma at the onset of their vasculitis. A shorter duration from the onset of the asthma to the onset of the vasculitis was an unfavorable prognostic sign.<sup>81</sup>

Peripheral blood eosinophilia and eosinophilic tissue infiltrates mimicking Loeffler's syndrome, chronic eosinophilic pneumonia, or eosinophilic gastroenteritis characterize the second phase. Pulmonary infiltrates occurred in 72% of patients in the review by Lanham et al<sup>80</sup> and preceded the diagnosis of vasculitis in 40%. The chest radiograph pattern in CSS is non-specific, typically revealing either transient patchy infiltrates, massive bilateral nodular infiltrates without evidence of cavitation, or an interstitial pattern.<sup>81</sup> Hilar lymphadenopathy and pleural effusions have been reported.<sup>80</sup> The peripheral eosinophilia does not necessarily correlate with disease activity and may be absent at the time of presentation, particularly in patients taking steroids for control of their asthma.<sup>80</sup> When present, eosinophils may compose up to 80% of the differential count.<sup>81</sup>

Systemic vasculitis characterizes the third phase. Commonly involved organs outside the lung include: the nervous system (most commonly as a mononeuritis multiplex), the skin, and the gastrointestinal tract.<sup>80,81</sup> Cardiac involvement, as manifested by pericarditis, myocardial infarction, and congestive heart failure, is the most common cause of death (48% of cases in the review by Lanham et al<sup>80</sup>). Virtually any organ may be involved during the vasculitic phase. However, in CSS, renal involvement is mild compared with PAN or Wegener's granulomatosis, as patients rarely progress to renal failure. Renal pathologic studies, when done, have revealed a necrotizing granulomatous arteritis and patchy interstitial eosinophilic infiltrates.<sup>80,82</sup>

The etiology of CSS remains unclear. The presence of asthma, eosinophilia, and an elevated IgE level suggests an allergic process, although no specific allergen has been identified. The vasculitides, in general, are believed to be caused by immune complex deposition and complement activation in vessel walls.<sup>83,84</sup> However, specific antigen deposition has only rarely been demon-

strated. Circulating immune complexes have been identified in a portion of patients with CSS, and renal biopsy specimens have stained positive for IgM.<sup>80,82</sup> Failure to isolate immune complexes has been attributed to in situ immune-complex formation, phagocytosis, or rapid disappearance of the immune complexes from the circulation. IgE levels have been elevated in some cases and appear to correlate with the activity of the vasculitis.<sup>80,85</sup> It is postulated that IgE-mediated release of vasoactive amines facilitates immune complex deposition. However, a causal role for immune complex deposition and IgE remains unproven in CSS. Factors that predict which patient with eosinophilic pneumonia<sup>86</sup> or, as has been recently reported, with ABPA will subsequently develop systemic vasculitis are unknown.<sup>87</sup>

### Treatment

Untreated CSS is potentially fatal. Chumbley et al reported a five-year survival of 62% in patients treated primarily with steroids.<sup>81</sup> High-dose steroids (60–100 mg prednisone per day) are often required. Pulse therapy with 1 g of methylprednisolone per day for four days was effective in a patient whose condition was deteriorating on 100 mg of prednisone per day.<sup>88</sup> Combination therapy with cyclophosphamide or azathioprine is recommended in the patient who does not respond to corticosteroid therapy or has evidence of severe systemic vasculitis.<sup>84</sup>

---

### TROPICAL PULMONARY EOSINOPHILIA

---

Tropical pulmonary eosinophilia (TPE) was well-established as a distinct clinical entity, albeit of unknown etiology, at the time of the review by Crofton et al.<sup>3</sup> More recently, the discovery of elevated microfilarial antibody titers, the demonstration of microfilaria in inflammatory foci, and the clinical response to diethylcarbamazine have implicated microfilariae as the etiologic agent. The disease occurs predominantly in areas of endemic filariasis, including India, Southeast Asia, and the South Pacific Islands; it should be considered in patients with the appropriate demographic history.

TPE is presumed to be secondary to infection with human filarial species *Wuchereria bancrofti* or *Brugia malayi*. Specific species identification has been difficult because of the inability to locate microfilariae in the blood and the rarity with which they are found in tissue biopsy specimens. When found, they are usually degenerating. The present working hypothesis is that TPE represents a host hypersensitivity response to microfilariae.<sup>89</sup> Microfilariae released from adult worms are cleared by the pulmonary vasculature where they

degenerate, inciting an inflammatory reaction with subsequent injury. Why only a small number of individuals develop a hypersensitivity reaction despite the large number infected with filaria remains unclear. Levels of IgG antibodies, specifically of the IgG4 subclass, rise concomitantly with the increase in IgE. Hussain and Ottesen suggest that IgG4 may function as a blocking antibody; the ratio of IgE to IgG4, therefore, may be of importance in determining which patients will develop TPE.<sup>90</sup>

Clinically, the disease is characterized by a low-grade fever, weight loss, and fatigue.<sup>91</sup> Cough and wheezing, usually worse at night, develop. The chest radiograph may reveal a reticular nodular pattern similar to miliary tuberculosis. Less common presentations include: a normal chest radiograph, focal areas of consolidation, hilar lymphadenopathy, and pleural effusions.<sup>91,92</sup> Pulmonary-function testing may reveal a mixed obstructive and restrictive defect.<sup>93</sup>

Chronic disease may result in the permanent changes of interstitial fibrosis. Although the lung is the predominant organ involved, lymph node enlargement, pericarditis, and central nervous system involvement have been reported.<sup>91</sup>

Laboratory studies reveal eosinophilia, usually in excess of 3,000 per mm<sup>3</sup>, elevated IgE levels and elevated antifilarial antibody titers. Histopathologic studies reveal early histocyte infiltration followed by eosinophilic bronchopneumonia. The chronic disease state may reveal a mixed cellular infiltrate of histiocytes, lymphocytes, and eosinophils with increasing amounts of fibrosis.<sup>94</sup> Microfilaria are rarely found in tissue samples and, therefore, lung biopsy specimens remain non-specific and only rarely helpful as a diagnostic tool except to exclude other possible etiologies. Bronchoalveolar lavage done on patients with TPE reveals a marked eosinophil alveolitis, which improves following treatment with diethylcarbamazine and is associated with an improvement in lung function.<sup>95</sup>

### Treatment

Diethylcarbamazine is the treatment of choice; clinical improvement is seen within seven–10 days.<sup>94</sup> The chronic disease state may respond less well.

---

### CONCLUSION

---

Significant strides have been made in our understanding of the group of diseases characterized by pulmonary infiltrates and peripheral eosinophilia. The eosinophil plays an active role in the pathophysiology of



these diseases. Specific causes for tropical pulmonary eosinophilia and many causes of Loeffler's syndrome have been determined. Marked progress has been made in our understanding of allergic bronchopulmonary aspergillosis.

Despite these advances, several syndromes can only be defined clinically, and significant overlap persists between syndromes such as chronic eosinophilic pneumonia, the hypereosinophilic syndrome, and the Churg-Strauss syndrome. The original classification by Crofton et al<sup>3</sup> remains useful, if only to remind one of the overlap between the syndromes.

At present it is impossible to predict which patients may progress from a more benign disorder of isolated pulmonary eosinophilia to the multi-organ system in-

volvement found in CSS or HES. Early diagnosis and close follow-up may prevent permanent organ system dysfunction.

Corticosteroids remain the primary treatment modality for most of these diseases. Cytotoxic agents have a role in treating the patient with multi-organ system involvement. Diagnosis, management, and classification of the PIE syndromes continues to be hampered by our incomplete understanding of these syndromes.

#### ACKNOWLEDGMENT

I would like to thank Muzaffar Ahmad, MD and Herbert Wiedemann, MD for their review of the manuscript, and Patricia Senor for her technical assistance.

#### REFERENCES

- Hirsch JG, Hirsch BI. Paul Ehrlich and the discovery of the eosinophil. [In] Mahmoud AAF, Austen KF, eds. *The Eosinophil in Health and Disease*. New York, Grune and Stratton, 1980, pp 3-23.
- Reeder WH, Goodrich BE. Pulmonary infiltration with eosinophilia (PIE syndrome). *Ann Intern Med* 1952; **36**:1217-1240.
- Crofton JW, Livingstone JL, Oswald NC, Roberts ATM. Pulmonary eosinophilia. *Thorax* 1952; **7**:1-35.
- Liebow AA, Carrington CB. The eosinophilic pneumonias. *Medicine* 1969; **48**:251-285.
- Schatz M, Wasserman S, Patterson R. Eosinophils and immunologic lung disease. *Med Clin N Am* 1981; **65**:1055-1071.
- Schatz M, Wasserman S, Patterson R. The eosinophil and the lung. *Arch Intern Med* 1982; **142**:1515-1519.
- Wykoff RF. Eosinophilia. *South Med J* 1986; **79**:608-612.
- Slungaard A, Ascensao J, Zanjani E, Jacob HS. Pulmonary carcinoma with eosinophilia: demonstration of a tumor-derived eosinophilopoietic factor. *N Engl J Med* 1983; **309**:778-781.
- Dawes PT, Smith DH, Scott DL. Massive eosinophilia in rheumatoid arthritis: report of four cases. *Clin Rheumatol* 1986; **5**:62-65.
- Lombard CM, Tazelaar HD, Krasne DL. Pulmonary eosinophilia in coccidioidal infections. *Chest* 1987; **91**:734-736.
- Peterson MW, Monick M, Hunninghake GW. Prognostic role of eosinophils in pulmonary fibrosis. *Chest* 1987; **92**:51-56.
- Davis BW, Fells GA, Sun X-H, Gadek JE, Venet A, Crystal RG. Eosinophil-mediated injury to lung parenchymal cells and interstitial matrix: a possible role for eosinophils in chronic inflammatory disorders of the lower respiratory tract. *J Clin Invest* 1984; **74**:269-278.
- Hällgren R, Samuelsson T, Venge P, Modig J. Eosinophil activation in the lung is related to lung damage in adult respiratory distress syndrome. *Am Rev Respir Dis* 1987; **135**:639-642.
- Gleich GJ. Current understanding of eosinophil function. *Hosp Prac* 1988; **23**:137-160.
- Weller PF. Eosinophilia. *J Allergy Clin Immunol* 1984; **73**:1-10.
- Gleich GJ, Loegering DA. Immunobiology of eosinophils. *Ann Rev Immunol* 1984; **2**:429-459.
- Venge P, Håkansson L, Peterson CGB. Eosinophil activation in allergic disease. *Int Arch Allergy Appl Immunol* 1987; **82**:333-337.
- Hastie AT, Loegering DA, Gleich GJ, Kueppers F. The effect of purified human eosinophil major basic protein on mammalian ciliary activity. *Am Rev Respir Dis* 1987; **135**:848-853.
- Frigas E, Loegering DA, Gleich GJ. Cytotoxic effects of the guinea pig eosinophil major basic protein on tracheal epithelium. *Lab Invest* 1980; **42**:35-43.
- Frigas E, Loegering DA, Solly GO, Farrow GM, Gleich GJ. Elevated levels of the eosinophil granule major basic protein in the sputum of patients with bronchial asthma. *Mayo Clin Proc* 1981; **56**:345-353.
- Enokihara H, Hamaguchi H, Sakamaki H, Hazama S, Saito K, Furusawa S, Shishido H. Specific production of eosinophil colony stimulating factor from sensitized T cells from a patient with allergic eosinophilia. *Br J Haematol* 1985; **59**:85-91.
- Prin L, Capron M, Gosset P, et al. Eosinophilic lung disease: immunological studies of blood and alveolar eosinophils. *Clin Exp Immunol* 1986; **63**:249-257.
- Fukuda T, Dunnette SL, Reed CE, Ackerman SJ, Peters MS, Gleich GJ. Increased numbers of hypodense eosinophils in the blood of patients with bronchial asthma. *Am Rev Respir Dis* 1985; **132**:981-985.
- Horn BR, Robin ED, Theodore J, Van Kessel A. Total eosinophil counts in the management of bronchial asthma. *N Engl J Med* 1975; **292**:1152-1155.
- Altman LC, Hill JS, Hairfield WM, Mullarkey MF. Effects of corticosteroids on eosinophil chemotaxis and adherence. *J Clin Invest* 1981; **67**:28-36.
- Koch-Weser J. Beta adrenergic blockade and circulating eosinophils. *Arch Intern Med* 1968; **121**:255-258.
- Weller PF. Parasitic pneumonias. [In] Pennington JE. *Respiratory Infections: Diagnosis and Management*. New York, Raven Press, 1983, pp 439-453.
- Cooper JAD, White DA, Matthey RA. Drug-induced pulmonary disease. *Am Rev Respir Dis* 1986; **133**:488-505.
- Cooper JAD, White DA, Matthey RA. Drug-induced pulmonary disease. *Am Rev Respir Dis* 1986; **133**:321-340.
- Nader DA, Schillaci RF. Pulmonary infiltrates with eosinophilia due to naproxen. *Chest* 1983; **83**:280-282.
- Yousem SA, Lifson JD, Colby TV. Chemotherapy-induced eosinophilic pneumonia. *Chest* 1985; **88**:103-106.
- Wang KK, Bowyer BA, Fleming CR, Schroeder KW. Pulmonary infiltrates and eosinophilia associated with sulfasalazine. *Mayo Clin Proc* 1984; **59**:343-346.
- Carrington CB, Addington WW, Goff AM, et al. Chronic eosinophilic pneumonia. *N Engl J Med* 1969; **280**:787-798.
- Pearson DJ, Rosenow EC III. Chronic eosinophilic pneumonia (Carrington's): a followup study. *Mayo Clin Proc* 1978; **53**:73-78.
- Fox B, Seed WA. Chronic eosinophilic pneumonia. *Thorax* 1980; **35**:570-580.
- Ivanick MJ, Donohue JF. Chronic eosinophilic pneumonia: a cause of adult respiratory distress syndrome. *South Med J* 1986; **79**:686-690.
- Grantham JG, Meadows JA, Gleich GJ. Chronic eosinophilic pneumonia, evidence for eosinophil degranulation and release of major basic protein. *Am J Med* 1986; **80**:89-94.
- Gonzalez EB, Swedo JL, Rajaraman S, Daniels JC, Grant JA.

- Ultrastructural and immunohistochemical evidence for release of eosinophilic granules in vivo: cytotoxic potential in chronic eosinophilic pneumonia. *J Allergy Clin Immunol* 1986; **79**:755-762.
39. Gaensler EA, Carrington CB. Peripheral opacities in chronic eosinophilic pneumonia: the photographic negative of pulmonary edema. *AJR* 1977; **128**:1-13.
  40. Onitsuka H, Onitsuka S-i, Yokomizo Y, Matsuura K. Computed tomography of chronic eosinophilic pneumonia. *J Comput Assist Tomogr* 1983; **7**:1092-1094.
  41. Epler GR, McLoud TC, Gaensler EA, Mikus JP, Carrington CB: Normal chest roentgenograms in chronic diffuse infiltrative lung disease. *N Engl J Med* 1978; **99**:934, 1978.
  42. Dejaegher P, Derveaux L, Dubois P, Demedts M. Eosinophilic pneumonia without radiographic pulmonary infiltrates. *Chest* 1983; **84**:637-638.
  43. Quinonez GE, Simon GT, Kay JM. Electron microscopy of chronic eosinophilic pneumonia. *Clin Invest Med* 1986; **9**:238-243.
  44. Reynolds HY. Bronchoalveolar lavage. [In] Murray JF, Nadel JA, eds. *Textbook of Respiratory Medicine*. Philadelphia, W.B. Saunders, 1988, pp 597-610.
  45. Dejaegher P, Demedts M. Bronchoalveolar lavage in eosinophilic pneumonia before and during corticosteroid therapy. *Am Rev Respir Dis* 1984; **129**:631-632.
  46. Ogushi F, Ozaki T, Kawano T, Yasuoka S. PGE<sub>2</sub> and PGE<sub>2α</sub> content in bronchoalveolar lavage fluid obtained from patients with eosinophilic pneumonia. *Chest* 1987; **91**:204-206.
  47. Dines DE. Chronic eosinophilic pneumonia: a roentgenographic diagnosis (editorial). *Mayo Clin Proc* 1978; **53**:129-130.
  48. Marnocha KE, Maglinte DDT, Kelvin FM, McCune M, Weiser DC, Strate R. Eosinophilic enteritis associated with chronic eosinophilic pneumonia. *Am J Gastroenterol* 1986; **81**:1205-1208.
  49. Fauci AS, Harley JB, Roberts WC, Ferrans VJ, Gralnick HR, Bjornson BH. The idiopathic hypereosinophilic syndrome. *Ann Intern Med* 1982; **97**:78-92.
  50. Wynn SR, Sachs MI, Keating MU, et al. Idiopathic hypereosinophilic syndrome in a 5 1/2-month-old infant. *J Pediatr* 1987; **111**:94-97.
  51. Alfaham MA, Ferguson SD, Sihra B, Davies J. The idiopathic hypereosinophilic syndrome. *Arch Dis Child* 1987; **62**:601-613.
  52. Parrillo JE, Borer JS, Henry WL, Wolff SM, Fauci AS. The cardiovascular manifestations of the hypereosinophilic syndrome. *Am J Med* 1979; **67**:572-582.
  53. Chusid MJ, Dale DC, West BC, Wolff SM. The hypereosinophilic syndrome: analysis of fourteen cases with review of the literature. *Medicine* 1975; **54**:1-27.
  54. O'Shea JJ, Jaffe ES, Lane HC, MacDermott RP, Fauci AS. Peripheral T cell lymphoma presenting as hypereosinophilia with vasculitis. *Am J Med* 1987; **82**:539-545.
  55. Parrillo JE, Fauci AS, Wolff SM. Therapy of the hypereosinophilic syndrome. *Ann Intern Med* 1978; **89**:167-172.
  56. Szeffler SJ, Brenner M, Jusko WJ, Spector SL, Flesher KA, Ellis EF. Dose- and time-related effect of troleandomycin on methylprednisolone elimination. *Clin Pharmacol Ther* 1982; **32**:166-171.
  57. Edwards D, Wald JA, Dobozin BS, Kirkpatrick CH. Troleandomycin and methylprednisolone for treatment of the hypereosinophilic syndrome (letter). *N Engl J Med* 1987; **317**:573-574.
  58. Hinson KFW, Moon AJ, Plummer MS. Bronchopulmonary aspergillosis. *Thorax* 1952; **7**:317-333.
  59. Greenberger PA, Patterson R. Diagnosis and management of allergic bronchopulmonary aspergillosis. *Ann Allergy* 1986; **56**:444-448.
  60. Rosenberg M, Patterson R, Mintzer R, Cooper BJ, Roberts M, Harris KE. Clinical and immunologic criteria for the diagnosis of allergic bronchopulmonary aspergillosis. *Ann Intern Med* 1977; **86**:405-414.
  61. Ricketti AJ, Greenberger PA, Mintzer RA, Patterson R. Allergic bronchopulmonary aspergillosis. *Chest* 1984; **86**:773-778.
  62. Patterson R, Greenberger PA, Halwig JM, Liotta JL, Roberts M. Allergic bronchopulmonary aspergillosis. *Arch Intern Med* 1986; **146**:916-918.
  63. Mendelson EB, Fisher MR, Mintzer RA, Halwig JM, Greenberger PA. Roentgenographic and clinical staging of allergic bronchopulmonary aspergillosis. *Chest* 1985; **87**:334-339.
  64. Slavin RG. Allergic bronchopulmonary aspergillosis. *Clin Rev Allergy* 1985; **3**:167-182.
  65. Glancy JJ, Elder JL, McAleer R. Allergic bronchopulmonary fungal disease without clinical asthma. *Thorax* 1981; **36**:345-349.
  66. Wang JLF, Patterson R, Rosenberg M, Roberts M, Cooper BJ. Serum IgE and IgG antibody activity against *Aspergillus fumigatus* as a diagnostic aid in allergic bronchopulmonary aspergillosis. *Am Rev Resp Dis* 1978; **117**:917-927.
  67. Patterson R, Greenberger PA, Ricketti AJ, Roberts M. A radioimmunoassay index for allergic bronchopulmonary aspergillosis. *Ann Intern Med* 1983; **99**:18-22.
  68. Akiyama K, Takizawa H, Suzuki M, Miyachi S, Ichinohe M, Yanagihara Y. Allergic bronchopulmonary aspergillosis due to *Aspergillus oryzae*. *Chest* 1987; **91**:285-286.
  69. Brummund W, Resnick A, Fink JN, Kurpup VP. *Aspergillus fumigatus*-specific antibodies in allergic bronchopulmonary aspergillosis and aspergilloma: evidence for a polyclonal antibody response. *J Clin Microbiol* 1987; **25**:5-9.
  70. Gutt L, Greenberger PA, Liotta JL. Serum IgA antibodies to *Aspergillus fumigatus* in various stages of allergic bronchopulmonary aspergillosis. *J Allergy Clin Immunol* 1986; **78**:98-101.
  71. Ricketti AJ, Greenberger PA, Pruzansky JJ, Patterson R. Hyperreactivity of mediator-releasing cells from patients with allergic bronchopulmonary aspergillosis as evidenced by basophil histamine release. *J Allergy Clin Immunol* 1983; **72**:386-392.
  72. Slavin RG, Hutcheson PS, Knutsen AP. Participation of cell-mediated immunity in allergic bronchopulmonary aspergillosis. *Int Arch Allergy Appl Immunol* 1987; **83**:337-340.
  73. Patterson R, Greenberger PA, Radin RC, Roberts M. Allergic bronchopulmonary aspergillosis: staging as an aid to management. *Ann Intern Med* 1982; **96**:286-291.
  74. Ricketti AJ, Greenberger PA, Patterson R. Serum IgE as an important aid in management of allergic bronchopulmonary aspergillosis. *J Allergy Clin Immunol* 1984; **74**:68-71.
  75. Shale DJ, Faux JA, Lane DJ. Trial of ketoconazole in non-invasive pulmonary aspergillosis. *Thorax* 1987; **42**:26-31.
  76. Patterson R, Greenberger PA, Lee TM, et al. Prolonged evaluation of patients with corticosteroid-dependent asthma stage of allergic bronchopulmonary aspergillosis. *J Allergy Clin Immunol* 1987; **80**:663-668.
  77. Lee TM, Greenberger PA, Patterson R, Roberts M, Liotta JL. Stage V (fibrotic) allergic bronchopulmonary aspergillosis. *Arch Intern Med* 1987; **147**:319-323.
  78. Churg J, Strauss L. Allergic granulomatosis, allergic angiitis, and periarteritis nodosa. *Am J Pathol* 1951; **27**:277-301.
  79. Fauci AS. Vasculitis. *J Allergy Clin Immunol* 1983; **72**:211-223.
  80. Lanham JG, Elkon KB, Pusey CD, Hughes GR. Systemic vasculitis with asthma and eosinophilia: a clinical approach to the Churg-Strauss syndrome. *Medicine* 1984; **63**:65-81.
  81. Chumbley LC, Harrison EG Jr, DeRemee RA. Allergic granulomatosis and angiitis (Churg-Strauss syndrome). *Mayo Clin Proc* 1977; **52**:477-484.
  82. Koss MN, Antonovych T, Hochholzer L. Allergic granulomatosis (Churg-Strauss syndrome). *Am J Surg Pathol* 1981; **5**:21-28.
  83. Lie JT. The classification of vasculitis and a reappraisal of allergic granulomatosis and angiitis (Churg-Strauss syndrome). *M Sinai J Med (NY)* 1986; **53**:429-439.
  84. Leavitt RY, Fauci AS. Pulmonary vasculitis. *Am Rev Respir Dis* 1986; **134**:149-166.
  85. Sale S, Patterson R. Recurrent Churg-Strauss vasculitis with exophthalmos, hearing loss, nasal obstruction, amyloid deposits, hyperimmunoglobulinemia E, and circulating immune complexes. *Arch Intern Med* 1981; **141**:1363-1365.
  86. Cogen FC, Mayock RL, Zweiman B. Chronic eosinophilic pneumonia followed by polyarteritis nodosa complicating the course of bronchial asthma: report of a case. *J Allergy Clin Immunol* 1977; **60**:377-382.
  87. Stephens M, Reynolds S, Gibbs AR, Davies B. Allergic bronchopulmonary aspergillosis progressing to allergic granulomatosis and angiitis (Churg-Strauss syndrome). *Am Rev Respir Dis* 1988; **137**:1226-1228.
  88. MacFadyen R, Tron V, Keshmiri M, Road JD. Allergic angiitis of



- Churg and Strauss syndrome: response to pulse methylprednisolone. *Chest* 1987; **91**:629-631.
89. Ottesen EA, Neva FA, Paranjape RS, Tripathy SP, Thiruvengadam KV, Beaven MA. Specific allergic sensitisation to filarial antigens in tropical eosinophilia syndrome. *Lancet* 1979; **1**:1158-1161.
90. Hussain R, Ottesen EA. IgE responses in human filariasis. IV. Parallel antigen recognition by IgE and IgG4 subclass antibodies. *J Immunol* 1986; **135**:1859-1863.
91. Spry CJF, Kumaraswami V. Tropical eosinophilic. *Sem Hematol* 1982; **19**:107-115.
92. Jain VK, Beniwal OP. Unusual presentation of tropical pulmonary eosinophilia. *Thorax* 1984; **39**:634-635.
93. Chhabra SK, Gaur SN. Airway hyperreactivity in tropical pulmonary eosinophilia. *Chest* 1988; **93**:1105-1106.
94. Neva FA, Ottesen EA. Tropical (filarial) eosinophilia. *N Engl J Med* 1978; **298**:1129-1131.
95. Pinkston P, Vijayan VK, Nutman TB, et al. Acute tropical pulmonary eosinophilia: characterization of the lower respiratory tract inflammation and its response to therapy. *J Clin Invest* 1987; **80**:216-225.

