



# Annular pancreas and intermittent duodenal obstruction in an alcoholic adult

JAMES C. SPERRAZZA, BS; RICHARD A. FLANAGAN, Jr, MD; MARK R. KATLIC, MD

■ Annular pancreas is a congenital anomaly which, though present at birth, may cause few symptoms until adulthood. A case of annular pancreas with intermittent duodenal obstruction is described in a 49-year-old alcoholic man. Few other entities cause such obstruction. In similar cases, clinical suspicion of annular pancreas may lead to prompt diagnosis and treatment.

□ INDEX TERMS: PANCREAS; ABNORMALITIES; PANCREATITIS; ALCOHOLISM □ CLEVE CLIN J MED 1992; 59:208-210

**A**NNULAR PANCREAS is an anatomically distinct congenital anomaly in which pancreatic tissue encircles the middle portion of the duodenum. The exact incidence of this variant is unknown. Half of the patients who develop symptoms attributed to pancreatic division are neonates; the other half are adults, usually in their 30s or 40s.<sup>1</sup> Pain, nausea, and vomiting are the most common symptoms; gastrointestinal bleeding and jaundice occur less frequently. Occasionally, these symptoms may be intermittent, and in the absence of clinical suspicion of annular pancreas they may persist for months or years.<sup>2-4</sup>

We present a case of annular pancreas in a middle-aged man. The intermittent nature of his symptoms, which were associated clinically with pancreatitis, allowed successful diagnosis and treatment of this rare condition.

## CASE REPORT

A 49-year-old man presented to the emergency room complaining of severe epigastric pain, nausea, and vomiting of 2 weeks' duration. He admitted to being

From the Department of Surgery, Nesbitt Memorial Hospital, Kingston, Pennsylvania.

Address reprint requests to M.R.K., 200 South River Street, Wilkes-Barre, PA 18705.

alcoholic, consuming about two fifths of whiskey each day. He was taking an oral hypoglycemic drug for maintenance therapy of hyperglycemia which was presumed to be secondary to diabetes mellitus. Physical examination showed evidence of dehydration. Epigastric tenderness and succussion splash were noted.

Laboratory studies revealed the following values: amylase, 845 U/dL (normal, 50-200); lipase, 730 U/L (normal, 0-110); BUN > 100 mg/dL; creatinine, 5.9 mg/dL; and calcium, 9.4 mg/dL. Upper gastrointestinal (UGI) series demonstrated an "apple core" constriction of the second portion of the duodenum (*Figure*), and after 24 hours very little contrast material had left the stomach. Computed tomography (CT) of the abdomen showed diffuse pancreatic enlargement, and biliary ultrasound detected no biliary calculi or common bile duct dilatation.

Treatment for pancreatitis, including gastric decompression, was initiated. Gastroscopy performed 10 days later showed retention of food in the stomach and duodenum. The second portion of the duodenum was concentrically and smoothly narrowed to a lumen of several millimeters; biopsies of the visible duodenum were unremarkable. Two weeks later the amylase level had normalized, and the obstruction had clinically resolved. The patient was discharged; follow-up gastroscopy was planned, but the patient refused this study.

Two months later, the patient returned with abdominal pain but no vomiting. CT again showed dif-

fuse pancreatic enlargement. Repeat gastroscopy now showed no retained food and no duodenal narrowing; the ampulla of Vater was normal. He was discharged in 10 days.

One month later he returned with pain, nausea, and vomiting after drinking alcohol. Amylase was 600 U/dL; lipase, 820 U/L; and BUN, 62 mg/dL. UGI series again showed high-grade narrowing of the second portion of the duodenum, and CT showed diffuse pancreas enlargement. Ultrasound showed no gallstones or ductal dilatation.

Surgical consultation was ordered and a clinical diagnosis of annular pancreas was made; the patient began parenteral hyperalimentation. Two weeks later he underwent laparotomy, whereupon a band of grossly normal pancreatic tissue was found encircling the duodenum. The gallbladder was normal. Vagotomy and gastrojejunostomy were performed, and the patient was discharged 10 days later.

The patient ceased to consume alcohol and has had no further obstructive symptoms or episodes of pancreatitis. Four years later, an elective cholecystectomy was performed by the same surgeon for chronic cholecystitis. At that time, a preoperative UGI series demonstrated a widely patent gastrojejunostomy, but with preferential emptying through the duodenum. The patient remains well.

#### DISCUSSION

The mechanism of duodenal obstruction from annular pancreas in the neonate is conceptually simple: a tight mechanical band of pancreatic tissue causes intrinsic duodenal stenosis.<sup>5</sup> But what leads to the onset of symptoms in the adult, and why are these symptoms sometimes intermittent?

Annular pancreas in the adult may cause symptoms such as pain, nausea, vomiting, hematemesis, or melena, which result from chronic partial duodenal obstruction, peptic ulcer disease, and pancreatitis. Patients with annular pancreas are predisposed to all of these conditions.

Chronic subtotal obstruction probably occurs frequently and is only occasionally symptomatic. A number of reports have described adult patients with annular pancreas who had reported vomiting between ages 6 and 10, with barium studies at that time showing only a "non-specific" abnormality of the second portion of the duodenum or no abnormality at all.<sup>3,6</sup>

Peptic ulcer disease may be the cause of symptoms in a large percentage of adult patients with annular

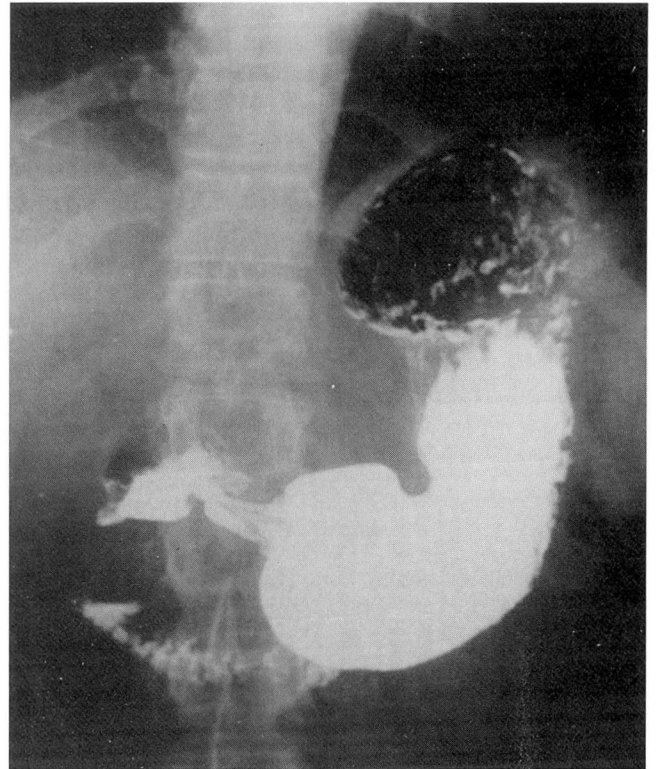


FIGURE. Constriction of the second portion of duodenum by an edematous annular pancreas.

pancreas. A review by Kiernan<sup>1</sup> found gastric or duodenal ulcer in 24 of 126 adults (19%), and a report from Japan<sup>4</sup> described peptic ulcer in 26 of 105 adult patients (24.8%). In these cases, duodenal obstruction may lead to antral distension and increased gastric secretion; also, stenosis at or above the papilla of Vater may prevent passage of alkaline secretions from the duodenum.<sup>4</sup>

Chronic pancreatitis is present in 15% to 25% of adult patients with annular pancreas. It is nearly always confined to the annulus and adjoining pancreatic head, though acute pancreatitis can also occur.<sup>7,8</sup> The pathogenesis of pancreatitis in these patients is felt to be based on ductal obstruction. Endoscopic retrograde cholangiopancreatography has shown that the annulus may be served by a branch of the main duct, by the main duct itself encircling the duodenum, or by a separate duct of Santorini.<sup>4</sup> The obstruction is due either to relative intrinsic narrowing of the annular duct or to impedance of flow by the associated duodenal stenosis. In this patient, pancreatic edema resulted from alcohol binges.



In normal patients, duodenal obstruction may be secondary to peptic ulcer disease, Crohn's disease, or tuberculosis. All of these etiologies may bear common symptoms of weight loss,<sup>9</sup> emesis of partially digested food, and epigastric pain. While episodic exacerbations of peptic ulcer disease may result in intermittent duodenal obstruction, the characteristic radiographic findings of this case, coupled with the patient's history of alcohol-related pancreatitis, suggested the diagnosis of annular pancreas instead.

The surgical treatment of choice for duodenal obstruction secondary to annular pancreas is bypass of the duodenal obstruction. In infants, duodenojejunostomy is most commonly performed. In adults, this may

be performed as a Roux-en-Y procedure. Other applicable procedures include duodenoduodenostomy around the annulus, or gastrojejunostomy, as was performed in this case. Vagotomy is often added to protect the gastrojejunostomy in patients who have had a history of peptic ulcer disease.<sup>8</sup>

In summary, our patient's intermittent duodenal obstruction resulted from edema provoked by alcohol abuse in a congenitally abnormal gland which was predisposed to pancreatitis. Recognition of symptom pattern and application of commonly available investigations (UGI series, CT scan, and endoscopy) led to the diagnosis, and gastrojejunostomy provided safe and effective relief of the duodenal obstruction.

#### REFERENCES

1. Kiernan PD, ReMine SC, Kiernan PC, ReMine WH. Annular pancreas—Mayo Clinic experience from 1957 to 1976 with review of the literature. *Arch Surg* 1980; **115**:46–50.
2. Brandow KR, Neville R, Fielding LP. Clinical relevance of an exploratory laparotomy: general principles derived from a singular instance of annular pancreas. *Current Surgery* 1987; **44**:98–101.
3. Dowsett J, Rode J, Russell R. Annular pancreas: a clinical, endoscopic, immunohistochemical study. *Gut* 1989; **30**:130–135.
4. Yogi Y, Shibue T, Hashimoto S. Annular pancreas detected in adults, diagnosed by endoscopic retrograde cholangiopancreatography: report of four cases. *Gastroenterol Jpn* 1987; **22**:92–99.
5. Salonen IS. Congenital duodenal obstruction—a review of the literature and a clinical study of 66 patients, including a histopathological study of annular pancreas and a follow-up of 36 survivors. *Acta Paediatr Scand* 1978; **272** [Suppl]:1–87.
6. Inamoto K, Ishikawa Y, Itoh N. CT demonstration of annular pancreas: case report. *Gastrointest Radiol* 1983; **8**:143–144.
7. Gilinsky NH, Lewis JW, Flueck JA, Fried AM. Annular pancreas associated with diffuse chronic pancreatitis. *Am J Gastroenterol* 1987; **82**:681–684.
8. Chevillotte G, Sahel J, Raillat A, Sarles H. Annular pancreas—report of one case associated with acute pancreatitis and diagnosed by endoscopic retrograde pancreatography. *Dig Dis Sci* 1984; **29**:75–77.
9. Hermann RE. *Manual of surgery of the gallbladder, bile ducts, and exocrine pancreas*. New York: Springer-Verlag NY Inc, 1979.

