



# Acute noncardiogenic pulmonary edema due to polymer fume fever

MITCHELL J. SILVER, DO, AND DAVID K. YOUNG, DO

- **BACKGROUND** Certain fluorocarbon polymers can produce a clinical syndrome called polymer fume fever when the products of pyrolysis are inhaled.
- **SUMMARY** A previously healthy 21-year-old white man presented with severe chest tightness, difficulty in breathing, pyrexia, nausea, vomiting, and a dry irritating cough. These symptoms occurred suddenly while smoking a cigarette 2 hours after leaving his place of work, where he is a plastics machinist. A chest roentgenogram revealed a bilateral patchy alveolar air space filling pattern involving the mid and lower lung fields. The diagnosis of polymer fume fever was established on the basis of the symptom complex, the association with cigarette smoking, and the occupational exposure to micronized polytetrafluoroethylene.
- **CONCLUSIONS** A thorough occupational and smoking history is necessary to recognize polymer fume disease, which may resemble influenza.

■ **INDEX TERMS:** PULMONARY EDEMA; POLYTETRAFLUOROETHYLENE; SMOKING; OCCUPATIONAL EXPOSURE ■ CLEVE CLIN J MED 1993; 60:479-482

From the Department of Internal Medicine (M.J.S.), The Cleveland Clinic Foundation, and the Sleep Disorder Center (D.K.Y.), Lansing General Hospital, Lansing, Michigan.

Address reprint requests to M.J.S., Department of Cardiology, F25, The Cleveland Clinic Foundation, 9500 Euclid Avenue, Cleveland, OH 44195.

**T**HE SYNDROME of polymer fume fever is characterized by chills, fever, dyspnea, dry cough, headache, and myalgia occurring a few hours after exposure to the pyrolytic products of polytetrafluoroethylene (PTFE, Teflon).<sup>1-3</sup> Severe cases may be accompanied by transient noncardiogenic pulmonary edema.<sup>4</sup> Exposure vehicles described have included the smoking of cigarettes contaminated with soluble PTFE in textile and electronics workers. We describe an otherwise healthy man who presented with noncardiogenic pulmonary edema, and review the salient features and implications of the disorder.

## CASE HISTORY

A 21-year-old man presented to the emergency department with complaints of severe dyspnea, chills, nausea, vomiting, and a non-productive cough. He had been in his usual state of good health until a few hours before his presentation. He denied myalgia, cephalgia, sore throat, and chest pain. He denied using intravenous drugs, engaging in homosexual activity, or receiving blood transfusions. There was no

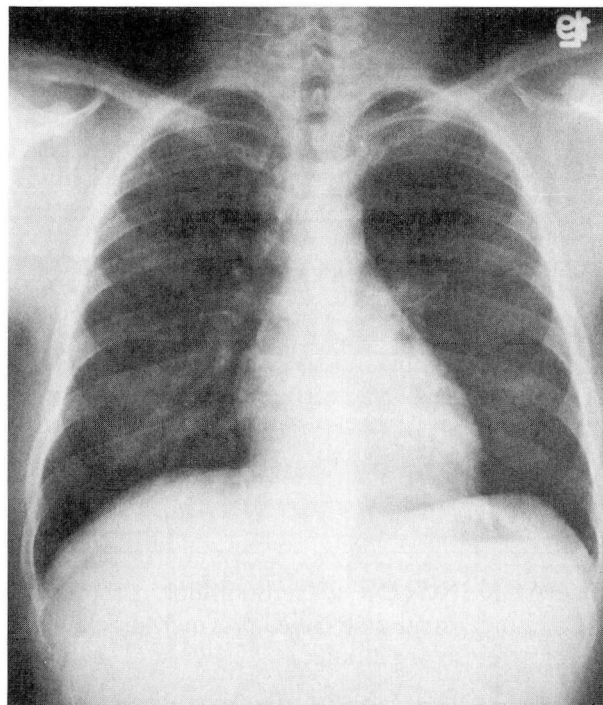
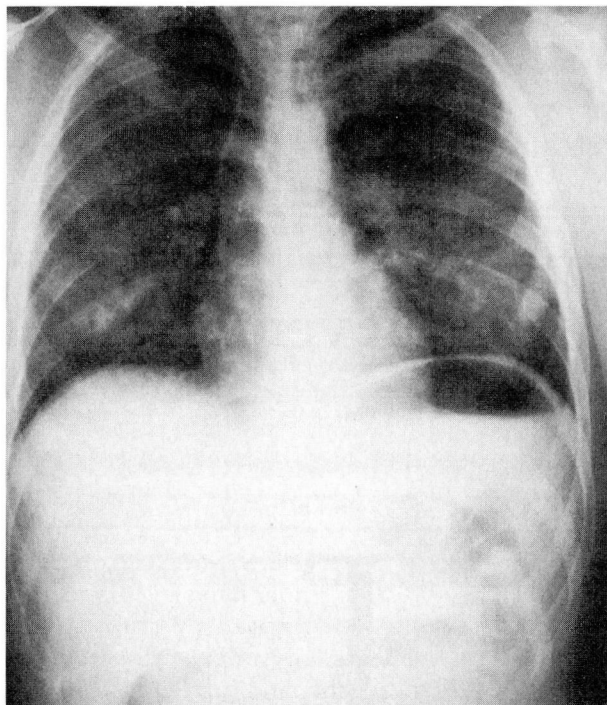


FIGURE. Chest roentgenogram on admission (left) demonstrating bilateral alveolar infiltrates, which cleared within 24 hours (right).

recent exposure to domestic or farm animals, and he had no recent history of foreign travel. He denied using any medications including illicit drugs and over-the-counter products. His past medical history was unremarkable. He drank six beers most weekends and smoked one pack of cigarettes per day. The patient had worked for the past 2 years at a manufacturing plant where he machined PTFE-coated products. He used protective eye wear while at work, but used no type of protective mask over his nose or mouth. He admitted to smoking at work and to carrying his cigarettes in the work area. He had smoked several cigarettes the day of his illness. The patient did admit to a similar illness characterized by transient dyspnea, nausea, and cough approximately 1 year ago after leaving the workplace. He could not state with certainty whether any of his coworkers had ever reported a similar illness. The remainder of the history was unremarkable.

Physical exam revealed a white man in moderate respiratory distress without cyanosis. His oral temperature was 37.9°C, blood pressure 154/90 mm Hg, pulse 124 beats per minute, and respiratory rate 28 breaths per minute. The skin, head, eyes, ears, nose,

and throat were normal. Examination of the heart revealed a regular tachycardia without murmur, rub, or third heart sound. Lung auscultation revealed inspiratory crackles in the left base greater than the right base. The remainder of the physical examination was normal.

The white cell count was 10 200/mm<sup>3</sup> with 76% neutrophils, 6% band forms, 14% lymphocytes, and 4% monocytes. The hemoglobin level was 16.1 g/dL and the platelet count was 240 000/mm<sup>3</sup>. Urinalysis results and electrolyte levels were normal. Measurement of arterial blood gases while the patient was breathing room air revealed a pH of 7.50, PaCO<sub>2</sub> 32 mm Hg, and PaO<sub>2</sub> 94 mm Hg. Blood cultures did not grow any organisms. A chest roentgenogram done in the emergency department demonstrated bilateral alveolar infiltrates involving both lower lobes, the lingula, and the middle lobe, with findings worse on the left side (*Figure*).

The patient was admitted to the hospital and was given supportive care with intravenous fluids. Erythromycin was given empirically. Twenty-four hours after admission a second chest roentgenogram demonstrated clearing of the infiltrates (*Figure*); the pa-

tient was afebrile and asymptomatic and the lung examination was normal. *Mycoplasma* and *Legionella* titers drawn on admission were reported to be normal.

On further questioning, the patient stated he smoked one of his fellow worker's cigarettes which "tasted bad" and made him nauseous. The pack had been opened and was lying next to his work station. Given the occupational exposure to micronized PTFE, the association with cigarette smoking, and the constellation of symptoms on presentation, the diagnosis of polymer fume fever was made clinically, and the antibiotic was discontinued. The patient was discharged with instructions to stop smoking (he was offered smoking-cessation counseling, which he refused). If he continued to smoke, he was not to carry his cigarettes at his work station, not to smoke inside the plant, and to smoke only after carefully washing his hands and face. The patient was seen in follow-up at 1 and 3 months, has had no further episodes, and remains asymptomatic.

#### DISCUSSION

Certain fluorocarbon polymers, notably PTFE and polyvinyl chloride, can produce a clinical syndrome called polymer fume fever when the products of pyrolysis are inhaled. PTFE is widely used to coat cookware, chemical vessels, wire, gaskets, bearings, and surgical prostheses.<sup>5</sup> Although these polymers are extremely inert, sufficient heating provides for their decomposition, and their decomposition products can cause clinical illness.

Many of the cases reported are due to smoking cigarettes contaminated with PTFE.<sup>6</sup> The temperature in the combustion zone of cigarettes is approximately 875°C.<sup>7</sup> Sherwood<sup>8</sup> calculated that a 1-mm diameter particle of fluorocarbon polymer burnt on a cigarette exposes the smoker to the same dose that one would receive breathing a concentration of 0.4 mg/m<sup>3</sup> for 8 hours, and it has been demonstrated using human volunteers that this is sufficient to induce an attack of polymer fume fever.<sup>3</sup> A recent Morbidity and Mortality Weekly Report<sup>9</sup> described an example of an acute respiratory illness linked to use of an aerosol leather conditioner containing fluoroalkyl polymers which resulted in an acute chemical pneumonitis involving approximately 550 individuals. At least three exhibited signs of pulmonary infiltrates on radiographic examination.

TABLE  
CLINICAL FINDINGS IN POLYMER FUME FEVER\*

	Number of patients	%
Symptoms		
Myalgia	62/65	95
Chest tightness	101/108	94
Chills	94/109	86
Dyspnea	93/109	85
Malaise	40/47	85
Cough	90/111	81
Cephalgia	27/40	68
Sore throat	11/42	26
Sputum production	1/41	2
Signs		
Tachypnea	5/6	83
Fever	96/117	82
Crackles	4/7	57
Laboratory findings		
Leukocytosis	6/8	75

\*Data from reference 1

The mechanism for polymer fume fever is not understood. It has been suggested that the freshly formed sublimate is responsible, either by itself or in combination with other absorbed toxicants, causing degranulation of leukocytes with the release of endogenous pyrogens.<sup>10</sup> A similar syndrome, metal fume fever, is felt to involve the actions of interleukin-1 and tumor necrosis factor because these two cytokines are associated with fever and flu-like symptoms, can be synthesized and released by cells residing in the lung, and induce a marked pulmonary cellular inflammatory response.<sup>11</sup>

The presenting features of polymer fume fever are nonspecific (Table). Over 80% of patients present with complaints of chest tightness, dyspnea, chills, myalgia, and malaise. A nonproductive cough is also frequently present. Other common symptoms are cephalgia, sore throat, and nausea. On physical examination most patients are febrile and tachypneic with few abnormal physical findings in the lungs. Laboratory studies are generally not helpful, although leukocytosis may be seen.

Interestingly, our patient had an abnormal chest roentgenogram that revealed bilateral alveolar infiltrates. Two previous reports describe abnormal chest roentgenograms that demonstrated pulmonary edema in association with inhalation of the pyrolytic products of micronized PTFE.<sup>4,12</sup> This is in contrast to the characteristically normal radiographic pattern reported by several others.<sup>13</sup> The alveolar infiltrates in our patient cleared in 24 hours.

Clinically, polymer fume fever resembles influenza, and this diagnosis needs to be excluded by taking a thorough occupational history. Also, repeated episodes would be very unusual for influenza, which typically occurs in winter or early spring. Since recovery from polymer fume fever is relatively rapid and usually complete, the patient may assume

that he or she has had influenza or a heavy cold and not report the incident. Failure to recognize polymer fume fever could lead to repetitive attacks, which have been implicated in causing diffuse interstitial pulmonary fibrosis.<sup>13</sup> This complication certainly underscores the importance of a thorough occupational history.

---

REFERENCES

---

1. **Harris DK.** Polymer fume fever. *Lancet* 1951; **2**:1001-1011.
2. **Adams WG.** Polymer fume fever due to inhalation of fumes from polytetrafluoroethylene. *Trans Assoc Ind Med Off* 1963; **13**:20-21.
3. **Williams N, Smith FK.** Polymer fume fever. An elusive diagnosis. *JAMA* 1972; **12**:1587-1589.
4. **Evans EA.** Pulmonary edema after inhalation of fumes from polytetrafluoroethylene (PTFE). *J Occup Med* 1973; **15**:599-601.
5. **Clayton JW.** The toxicity of fluorocarbons with special reference to chemical constitution. *J Occup Med* 1962; **4**:262-273.
6. **Wegman DH, Peters JM.** Polymer fume fever and cigarette smoking. *Ann Intern Med* 1974; **81**:55-57.
7. **Touey GP, Mumpower RC.** Measurement of the combustion zone temperature of cigarettes. *Tobacco* 1957; **44**:18-22.
8. **Sherwood RJ.** The hazards of fluon. *Trans Assoc Ind Med Off* 1955; **5**:10-12.
9. **Smilkstein MJ, Burton BT, Keene W, et al.** Acute respiratory illness linked to use of aerosol leather conditioner. *MMWR* 1993; **41**:965-967.
10. **Cavagna G, Finulli M, Vigliani EC.** Experimental study on the pathogenesis of fevers caused by inhalation of Teflon (polytetrafluoroethylene) fumes. *Med Lav* 1961; **52**:251-261.
11. **Blanc P, Wong H, Bernstein M, Boushey HA.** An experimental human model of metal fume fever. *Ann Intern Med* 1991; **114**:930-936.
12. **Robbins JJ, Ware RL.** Pulmonary edema from Teflon\* fumes. *N Engl J Med* 1964; **271**:360-361.
13. **Williams M, Atkinson GW, Patchefsky S.** Polymer fume fever: not so benign. *J Occup Med* 1974; **16**:519-522.

