

ILONA S. SZER, MD

Clinical Professor of Pediatrics, University of California-San Diego School of Medicine, Director, Pediatric Rheumatology, Children's Hospital, San Diego

Gastrointestinal and renal involvement in vasculitis: Management strategies in Henoch-Schönlein purpura

■ ABSTRACT

The joint pain, inflammation, and painful cutaneous edema of Henoch-Schönlein purpura (HSP) are effectively treated with analgesics, nonsteroidal anti-inflammatory agents, and corticosteroids, but the optimal management of HSP-associated gastrointestinal and renal involvement has not yet been determined. The results of mostly anecdotal and uncontrolled studies favor a short course of oral corticosteroids for severe abdominal pain and aggressive immunosuppressive therapy for patients with progressive HSP nephritis.

■ KEY POINTS

HSP in adults tends to be chronic, and the prognosis depends on the extent and nature of renal involvement.

HSP tends to be more common in fall, winter, and spring and is preceded in half of patients by an upper respiratory tract infection.

Corticosteroids may be associated with a reduction and more rapid resolution of abdominal pain, melena, and intestinal hemorrhage.

Renal disease may not be present during the initial episode of HSP and may develop up to 3 months into the course of illness.

Transient hematuria is the most common renal manifestation of HSP, described in 90% of patients. Recurrent hematuria occurs in 5% of patients.

THE JOINT PAIN, inflammation, and painful cutaneous edema of Henoch-Schönlein purpura (HSP) are effectively treated with analgesics, nonsteroidal anti-inflammatory agents, and corticosteroids. But the optimal management of gastrointestinal and renal involvement remains unclear. Reports in the literature favor a short course of oral corticosteroids for severe abdominal pain and aggressive immunosuppressive therapy for patients with progressive HSP nephritis, but these reports are mostly based on anecdotal and uncontrolled studies.

In the following discussion, I wish to provide perspective on how to manage patients with HSP-associated gastrointestinal and renal involvement in the face of limited data from the literature. A brief overview of HSP is provided in “Clinical features of Henoch-Schönlein purpura.”

■ GASTROINTESTINAL INVOLVEMENT

Gastrointestinal involvement is manifested primarily by bleeding, with hematemesis seen in 30% of patients, melena in 50%, and massive hemorrhage in 2%.¹ Intussusception has been described in 2% of children who have abdominal pain, and importantly, the site of involvement differs from “idiopathic” intussusception; 65% of children with HSP have ileoileal intussusception, while only 35% have the typical ileocolic intussusception seen in the majority of children without HSP. Intussusception is seen much less frequently in adults.²

Endoscopy shows hemorrhagic, erosive duodenitis, and radiography documents thick-

ening of the bowel wall, edema, and scalloping (bleeding into the wall). Mucosal biopsy yields a histologic picture identical to that of skin biopsy—ie, leukocytoclastic vasculitis of capillaries and postcapillary venules. Patients with HSP-associated abdominal pain are typically distressed and in need of fast relief by the time they see the clinician.

Should steroids be used to treat abdominal pain of HSP?

Because of the lack of controlled trials to gauge the effectiveness of steroids in treating HSP-related abdominal symptoms, the value of steroid treatment remains unknown.

In a retrospective analysis, Rosenblum et al³ evaluated the effect of corticosteroids on the duration of abdominal pain in 43 children with HSP. Twenty-five patients received oral prednisone at a dose of 2 mg/kg/day, and 18 served as controls. During the first 24 hours, abdominal pain resolved in 44% of those who received steroids, compared with spontaneous resolution in only 14% of those not treated ($P = .02$). Over the next 24 hours, 65% vs 45%, respectively, no longer had abdominal pain. After 72 hours, 75% of patients in both groups were well.

Similar observations by Allen¹ included the finding that painful edema and arthritis resolved with or without steroids within 24 to 48 hours after onset, and that steroids had no effect on either purpura or renal disease. Of note, none of the patients with abdominal pain who received steroids ($N = 37$) developed intussusception, whereas 4 (4%) of 94 untreated patients developed this complication. One patient in this series died of complications of intussusception.

It is this experience, in addition to hastening improvement of abdominal pain during the first 24 hours in 44% vs 14% of patients, that has influenced many physicians to treat abdominal pain with corticosteroids.

Additional observations by Glasier et al⁴ agreed with those of Rosenblum and Allen; 20 (91%) of 22 children with various gastrointestinal symptoms recovered with or without steroids. Case reports suggest that corticosteroids are associated with a reduction and more rapid resolution of abdominal pain,

melena, and intestinal hemorrhage. This is supported by anecdotal reports of successful treatment of children with corticosteroids for severe abdominal pain.

Despite reports of successful treatment, no placebo-controlled study to date has defined the risk-benefit properties of corticosteroid therapy. In addition, the etiology of abdominal pain is not well understood. Some patients may improve after receiving steroids because the source of pain is secondary to edema of the bowel wall that is likely to resolve with steroids. Similarly, patients with bleeding into the intestinal wall may be more resistant to corticosteroids. Still, a single short course of steroids at 1 to 2 mg/kg/day for a week is certainly not associated with side effects significant enough to preclude such a therapeutic trial.

Shortcomings in trial design preclude any broad conclusions about optimal management. Still, the results of largely anecdotal and uncontrolled studies of HSP favor the use of a short course of oral corticosteroids for severe abdominal pain.

RENAL INVOLVEMENT

Renal involvement in HSP is more common in adults than in children,⁵ and one study⁶ noted that the outcome of HSP in adults depends on the extent of nephropathy, with renal insufficiency predicting a poor outcome.

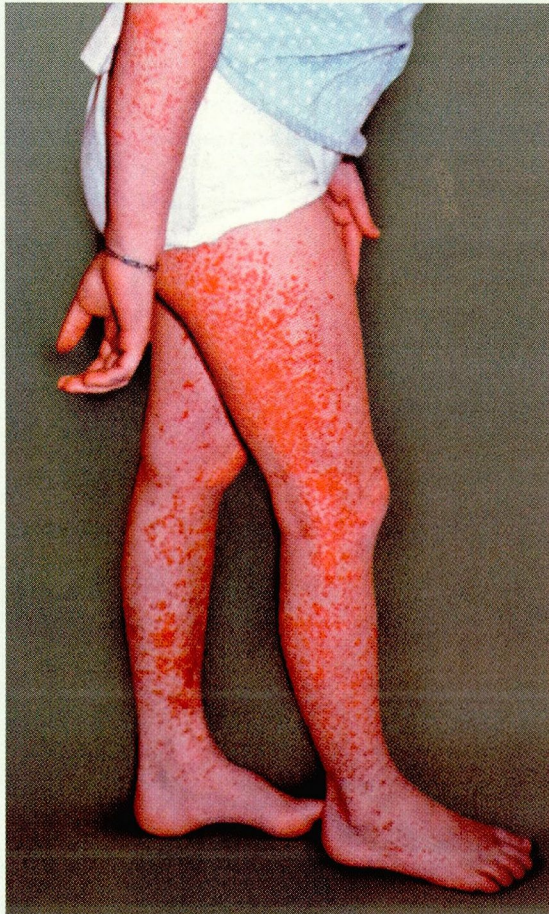Transient hematuria is the most common renal manifestation of HSP, described in 90% of patients, and recurrent hematuria occurs in 5% of patients. Hematuria together with proteinuria has been seen in 3% of patients. In a small minority of children, HSP is a cause of renal insufficiency (< 2%) and renal failure (< 1%).¹

Histologic features

Renal biopsy findings reveal a spectrum of abnormalities, from minimal change to severe crescentic glomerulonephritis.¹ Electron microscopy documents immune complex deposits localized primarily to the mesangium. However, in patients with significant renal injury, the deposits are seen in the subendothelial and subepithelial space. As it does in other affected tissues, immunofluorescence

Renal involvement may be more common and more severe in adults

Clinical features of Henoch-Schönlein purpura



HENOCH-SCHÖNLEIN PURPURA (HSP), a systemic vasculitis of unknown cause, is well described in adults,⁵⁻⁷ though it is much more common in children. Although the general features of HSP are similar in children and adults (FIGURE 1), important differences in the presentation and course of illness have been observed. For example, HSP in adults tends to be chronic and the prognosis depends on the extent and nature of renal involvement, whereas in children HSP is usually an acute illness.

In a retrospective analysis of 162 patients (including 42 adults), Blanco et al⁵ observed that in both children and adults HSP is often preceded by antibiotic or analgesic drug treatment or upper respiratory tract infection. Symptoms are similar for children and adults and include palpable purpura, abdominal pain, melena, joint symptoms, and renal involvement (eg, hematuria, nephropathy, and renal insufficiency).

Blanco observed the following differences:

- Joint symptoms were more common in adults

FIGURE 1. Fever, painful cutaneous edema, and palpable purpura, predominantly in the extremities, are often the first signs of HSP in both adults and children.

shows IgA, C3, fibrin, and properdin, and to a lesser extent both IgG and IgM deposition.

Do corticosteroids prevent delayed HSP nephritis?

Renal disease may not be present during the initial episode of HSP and may develop up to 3 months into the course of illness. In an effort to prevent the expression of renal manifestations in patients who may have delayed onset of renal disease, some physicians advocate prophylactic administration of corticosteroids.

To answer this question, Buchanec et al¹² summarized the course of HSP in 32 children who had no evidence of renal involvement at the time of presentation. Twenty-three

patients received corticosteroids at a dosage of 2 mg/kg/day, and 10 did not. Of those treated, only 1 (5%) developed nephritis, while in the untreated group 5 patients (50%) developed renal manifestations. The investigators concluded that immediate treatment with steroids prevented renal disease in a significant proportion of patients.

Mollica et al¹³ continued these observations in a modified (ie, open, nonrandomized) prospective trial in which 84 children received corticosteroids and 84 children did not receive any intervention. At 2 years' follow-up, treated patients showed no renal involvement, while 10 of 84 children in the nonintervention group developed hematuria ($P < .001$). Four of the nonintervention group



- Renal involvement was more common and more severe in adults
- Previous upper respiratory tract infection was more frequent among children
- Abdominal pain was more common in children.

DIAGNOSTIC CRITERIA IN ADULTS AND CHILDREN

While in children the diagnosis of HSP is based only on the presence of purpura with a normal platelet count, in adults the diagnosis requires the presence of two of the following four criteria:

- Palpable purpura
- Age 20 years or younger at onset
- Diffuse abdominal pain
- Biopsy showing granulocytes in the walls of arterioles and venules.

The presence of at least two of these criteria is enough to differentiate HSP from other forms of vasculitis with 87% sensitivity and 87% specificity.⁸

Most children have the classic HSP triad of purpura, colicky abdominal pain, and arthritis, but up to 50% may present with additional symptoms, including testicular swelling (which must be differentiated from torsion).

In general, renal disease is seen less in children under age 2 years, whereas subcutaneous

edema is more common in this age group than in children over age 2 years.¹

HSP tends to be more common in fall, winter, and spring and is preceded in 50% of patients by an upper respiratory tract infection. Males and females are affected equally, and the median age of onset is 4 years.⁹

HISTOLOGIC FEATURES

HSP is a vasculitis of the small vessels, believed to be mediated by immune complexes deposited in various organs, including the stomach, ileum, and kidneys.

Serologic studies document elevated levels of immunoglobulin A (IgA) in 50% of patients, in addition to activation of the complement system through the alternative pathway. C3 and C4 complement components remain at normal levels.

Histopathologic study of the skin and other affected organs reveals polymorphonuclear cells in vessel walls with IgA, C3, and immune complexes seen in venules, arterioles, and capillaries.¹⁰

DISEASE COURSE

The onset of HSP is acute, but the course varies. In 80% of patients, HSP is limited to a single episode resolving in 4 to 6 weeks. HSP recurs in 10% to 20% of patients and becomes chronic in less than 5%.¹¹

had persistent hematuria 12 months later, and 2 developed renal insufficiency 18 months after onset.

This study was immediately followed by a retrospective study¹⁴ that compared outcomes in patients without renal disease, among which 20 were treated with corticosteroids and 30 were not. Both groups showed a 20% frequency of subsequent renal involvement within 3 months of initial presentation, suggesting that pretreatment with steroids did not prevent the delayed onset of nephritis.

Conflicting observations. The seemingly conflicting data regarding prevention of delayed onset of renal disease are difficult to interpret. One explanation may be flawed study design: none of the studies was placebo-

controlled or randomized, and two were retrospective observations. Inconsistencies in the timing of corticosteroid administration from study to study make interpreting the results difficult. Furthermore, patients with delayed onset of renal manifestations are apparently not at high risk for renal impairment,¹⁵ and thus the indication for any intervention is questionable.

Who is at highest risk for progressive renal insufficiency?

The controversy regarding management of HSP nephritis is centered on patients at high risk for renal insufficiency, renal failure, or both. For the majority of children with HSP, renal involvement is transient and incons-

quential. However, 1% to 5% of children develop chronic renal disease, and in up to 1% this may progress to renal failure. Because renal failure is a rare outcome of HSP, interventional prospective studies of the subset of patients with renal failure may not be feasible. Therefore, the ideal treatment for such patients is still unknown.

The outcome in adults with HSP nephritis differs from the childhood experience. The natural history of this complication carries a high risk of renal insufficiency and an increased potential for renal failure.

Allen¹ retrospectively studied 74 children, of whom 40 had no renal findings at presentation, 24 had hematuria only, and 10 had hematuria and proteinuria. One year later, 80% of the children with no renal involvement at presentation and 71% of mildly affected children remained well. In contrast, only 40% of those who presented with severe involvement (nephrosis, renal insufficiency, or both) were free of renal findings.

In a similar study by Niaudet et al,¹⁵ none of the children with mild initial renal findings (hematuria only or proteinuria of less than 1 g/day) had renal disease more than 1 year later. However, of the patients who presented with nephrotic syndrome, renal insufficiency, or renal failure, a significant number went on to chronic renal failure. The same investigators then correlated biopsy findings with clinical renal manifestations and found a significant association of proliferative glomerulonephritis with at least 50% crescents with the development of future renal failure.

Niaudet et al also concluded that the presence of hematuria with nephrotic-range proteinuria confers a 15% risk of renal failure, whereas nephrosis with renal insufficiency and crescentic glomerulonephritis (crescentic cells observed in more than 50% of glomeruli) may lead to renal failure in up to half of patients with HSP-associated renal involvement after a 10-year course. Aggressive treatment should therefore be attempted to prevent late sequelae. Patients with nephrotic-range proteinuria, nephrotic syndrome, and signs of renal insufficiency should undergo renal biopsy to determine the extent of renal involvement.¹⁵


What is the optimal treatment for severe HSP nephritis?

Studies recommend various treatments for severe renal involvement in patients with HSP. These include pulsed or oral corticosteroids (alone or in combination with immunosuppressive agents such as azathioprine, cyclophosphamide, or cyclosporine), plasmapheresis, high-dose and low-dose intravenous IgG, danazol, and fish oil.¹¹

However, these studies suffer from small numbers of subjects, retrospective analysis of data, and lack of placebo control. Renal biopsy findings are inconsistently available, and interventions are given at different times in the course of the illness. Therefore, it is difficult to draw meaningful conclusions from these reports.

Nonetheless, a recent uncontrolled study¹⁶ suggests that the natural history of severe HSP nephritis may be changed favorably: 12 children with HSP and biopsy-proven rapidly progressive crescentic glomerulonephritis were treated with a combination of methylprednisolone at 30 mg/kg/day for 3 consecutive days, followed by oral corticosteroids at 2 mg/kg/day, cyclophosphamide at 2 mg/kg/day for 2 months, and dipyridamole at 5 mg/kg/day for 6 months. Rapidly progressive crescentic glomerulonephritis was characterized histologically by the presence of extensive crescent formation (over 60%) in the renal biopsy specimen, and clinically by a sudden progressive decline in renal function (50% or greater decline in the glomerular filtration rate within 6 weeks), together with nephrotic-range urine sediment and proteinuria (> 40 mg/m²/hour). At the 3-month evaluation, the glomerular filtration rate normalized in 11 of 12 patients, nephrosis resolved in 8 of 12, and hematuria was no longer detectable in 9 of 12. Furthermore, at 30 months after the treatment, only 1 patient had persistent nephrotic syndrome, and 1 developed renal failure.

Clinical recommendations based on data

Although ideally designed studies have not been performed to resolve the controversies surrounding treatment of progressive HSP nephritis, available data favor aggressive immunosuppressive therapy. 

Data favor aggressive immunosuppressive therapy for progressive HSP nephritis



■ REFERENCES

1. Allen DM, Diamond LK, Howell DA. Anaphylactoid purpura in children (Henoch-Schönlein syndrome). *Am J Dis Child* 1960; 99:147-168.
2. Schönlein-Henoch in adults (editorial). *Lancet* 1971; i:436-437.
3. Rosenblum ND, Winter HS. Steroid effects on the course of abdominal pain in children with HSP. *Pediatrics* 1987; 79:1018-1021.
4. Glasier CM, Siegel MJ, McAlister WH, et al. Henoch-Schönlein syndrome in children: gastrointestinal manifestations. *Am J Roentgenol* 1981; 136:1081-1085.
5. Blanco R, Martínez-Taboada VM, Rodríguez-Valverde V, García-Fuentes M, González-Gay MA. Henoch-Schönlein purpura in adulthood and childhood: two different expressions of the same syndrome. *Arthritis Rheum* 1997; 40:859-864.
6. Lasseur C, Rispal P, Combe C, et al. Purpura rhumatoïde de l'adulte: à propos de 40 observations. *Revue Méd Interne* 1996; 17:381-389.
7. Cream JJ, Gumpel JM, Peachey RDG. Schönlein-Henoch purpura in the adult: a study of 77 adults with anaphylactoid or Schönlein-Henoch purpura. *QJ Med* 1970; 39(156):461-481.
8. Calabrese LH, Michel BA, Bloch DA, et al. The ACR 1990 criteria for the classification of hypersensitivity vasculitis. *Arthritis Rheum* 1990; 33:1108-1113.
9. Robson WLM, Leung AKC. Henoch-Schönlein purpura. *Adv Pediatr* 1994; 41:163-194.
10. Szer IS. Henoch-Schönlein purpura. *Current Science. Curr Opin Rheumatol* 1994; 6:25-31.
11. Szer IS. Henoch-Schönlein purpura: when to treat and how? *J Rheumatol* 1996; 23:1661-1665.
12. Buchanec J, Galanda V, Belakova S, Minarik M, Zibolen M. Incidence of renal complications in Schönlein-Henoch purpura syndrome in dependence of early administration of steroids. *Int Urol Nephrol* 1988; 20:409-412.
13. Mollica F, Li Volti S, Garozzo R, Russo G. Effectiveness of early prednisone treatment in preventing the development of nephropathy in anaphylactoid purpura. *Eur J Pediatr* 1982; 151:140-144.
14. Saulsbury FT. Corticosteroid therapy does not prevent nephritis in Henoch-Schönlein purpura. *Pediatr Nephrol* 1993; 7:69-71.
15. Niaudet P, Murcia I, Beaufils H, Broyer M, Habib R. Primary IgA nephropathies in children: prognosis and treatment. *Adv Nephrol Necker Hosp* 1993; 2:121-140.
16. Oner A, Tinaztepe K, Erdogan O. The effect of triple therapy on rapidly progressive type of Henoch-Schönlein nephritis. *Pediatr Nephrol* 1995; 9:6-10.

.....
ADDRESS: Ilona S. Szer, MD, Director, Pediatric Rheumatology Children's Hospital San Diego, 3030 Children's Way, San Diego, CA 92123-4282, e-mail: Iszer@CHSD.org.

*We have a new, shorter
e-mail address:
ccjm@ccf.org*



THE CLEVELAND CLINIC FOUNDATION

SUMMIT ON CHOLESTEROL AND CORONARY DISEASE

September 1-3, 1999

Disney's Yacht
and
Beach Club Resorts

Lake Buena Vista, Florida

For further information please contact:

The Cleveland Clinic Educational Foundation
Department of Continuing Medical Education
9500 Euclid Avenue, TT-31
Cleveland, OH 44195
216-444-5695 (Local)
800-762-8173 (Toll Free)
216-445-9406 (FAX)