

**DAVID Z. CHANG, MD, PHD**Department of Internal Medicine,
Cleveland Clinic**PARVINDER KHURANA, MD**Department of Internal Medicine,
Cleveland Clinic**ALAN J. TAEGE, MD**Department of Infectious Disease,
Cleveland Clinic**NATALIE G. CORREIA, DO**Department of General Internal Medicine,
Cleveland Clinic**RALPH J. TUTHILL, MD**Department of Anatomic Pathology,
Cleveland Clinic

A 35-year-old man with recurrent aseptic meningitis

A 35-YEAR-OLD, previously healthy white man presented to the emergency department because of severe headache, nausea, vomiting, photophobia, neck stiffness, and fever (temperature 104°F—40°C), which had begun 1 day previously. He stated that he had not experienced visual changes, rash, or trauma. In addition, he had not recently traveled or come into contact with anyone known to have tuberculosis, and he had no known risk factors for human immunodeficiency virus.

The patient had experienced two similar episodes during the preceding 12 months. He was treated both times with a brief course of intravenous antibiotics pending cerebrospinal fluid cultures and thereafter for symptom relief. After each episode, he recovered without residual neurologic deficits or other sequelae. Routine bacterial cultures of the cerebrospinal fluid and a culture for enterovirus were performed, but no specific cause was ever found.

PHYSICAL EXAMINATION

The patient has the room darkened, saying he has a headache and cannot stand the light. His vital signs are:

- Temperature 37.8°C (100.0°F)
- Pulse 64
- Blood pressure 131/58 mm Hg.

On examination, the patient has nuchal rigidity, and any movement of his neck worsens the pain. There are no cranial nerve deficits. The motor and sensory examinations are unremarkable. Deep tendon reflexes are 2+ and symmetric without evidence of the Babinski sign. The Kernig and Brudzinski signs are not present. There are no petechial

or purpuric lesions. The chest, heart, lungs, and abdomen are within normal limits.

Diagnostic tests

Cerebrospinal fluid analysis. A lumbar puncture was performed in the emergency room. The cerebrospinal fluid was turbid with the following values:

- Red blood cells 68/μL (normal 0–1)
- White blood cells 385/μL (normal 0–3); lymphocytes 68%, monocytes 27%, neutrophils 1%
- Gram stain: no organisms found
- Protein 164 mg/dL (normal 20–50)
- Glucose 45 mg/dL (normal 50–75)
- Tests for infective organisms: all negative, including the following: herpes simplex virus type 1 and type 2 DNA polymerase chain reaction, cryptococcal antigen, fungal serology, Lyme disease serology, culture for acid-fast bacilli, rapid plasma reagin test for syphilis, and HIV screening.

Magnetic resonance imaging of the brain with and without gadolinium contrast was consistent with acute and chronic sinusitis but was otherwise negative.

Another spontaneous resolution

The patient was initially treated with a course of intravenous ceftriaxone pending cerebrospinal fluid culture results. The antibiotics were discontinued on the fourth hospital day when the results showed only *Staphylococcus epidermidis*, which was thought to be a contaminant on the basis of the clinical picture. The persistent headache was treated symptomatically. The nuchal rigidity gradually resolved and the patient was subsequently discharged. During a follow-up evaluation, there was no evidence of neurologic sequelae.

Tests for infectious organisms were negative

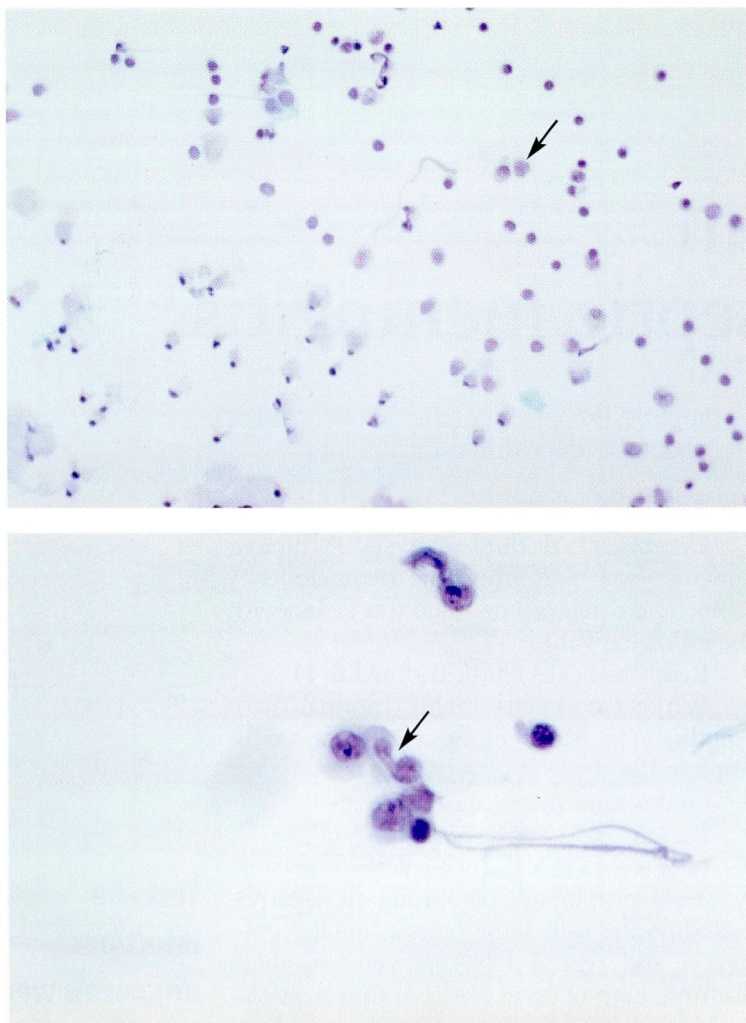


FIGURE 1. ThinPrep slides of the patient's cerebrospinal fluid. **Top**, numerous monocytoid Mollaret cells with delicate attenuated cytoplasm are present. Papanicolaou stain, $\times 200$. **Bottom**, Mollaret cells have irregularly shaped nuclei. The nuclear diameter is often narrow at one end and wide at the opposite end. Papanicolaou stain, $\times 400$.

■ DIFFERENTIAL DIAGNOSIS

1 What is the most likely cause of this patient's symptoms?

- Aseptic viral meningitis
- Fungal infection
- Mollaret meningitis
- Sarcoidosis
- Behçet syndrome

The differential diagnosis includes causes of culture-negative meningitis.

Although **Behçet syndrome** and **sarcoidosis** are associated with aseptic meningitis, they rarely involve the central nervous system without also causing systemic signs and symptoms. Both require careful evaluation, including an ophthalmologic examination, for evidence of systemic disease.

Fungal infections are more likely to produce chronic rather than intermittent symptoms. Fungal cultures and stains are frequently negative, making serology more useful.

Aseptic viral meningitis and **Mollaret meningitis** (also called benign recurrent aseptic meningitis) are possible causes. Mollaret meningitis is difficult to differentiate from viral meningitides. However, the former is characterized by recurrent episodes of meningitis with symptom-free intervals, which is consistent with the patient's history. Thus, it is the most likely cause.

■ A CLOSER LOOK AT A RARE DISEASE

Mollaret meningitis is a rare syndrome with characteristic features first described by Mollaret in 1944.¹ A 1972 literature review reported fewer than 30 cases worldwide.² Since then, several additional cases have been reported.³⁻¹³

Signs and symptoms

Sudden onset of meningeal signs and symptoms and rapid resolution without neurologic sequelae characterize Mollaret meningitis. Patients present with recurrent attacks of meningismus that are sudden in onset and last from 1 to 7 days. Fever is generally present, although several patients were afebrile in reported cases.⁴

Malaise, arthralgia, myalgia, nausea, and vomiting are common. Approximately 50% of patients have transient signs and symptoms related to the attack on the central nervous system.⁸ These include seizures, hallucinations, coma, vertigo, syncope, speech abnormalities, anisocoria, seventh nerve palsy, decreased deep tendon reflexes, Babinski sign, and paresis. All signs and symptoms disappear within 24 to 96 hours, and the patient feels entirely well until the next episode. The disease never leaves any residual neurologic or systemic signs or symptoms.

The attacks occur irregularly, and the



symptom-free intervals last from weeks to years. It is not possible to predict which attack will be the last: the disorder generally persists for 3 to 5 years but has been reported to persist as long as 20 years, during which the patient may experience 30 or more separate attacks of aseptic meningitis.

Cerebrospinal fluid features

During attacks, the cerebrospinal fluid is under increased pressure and has an elevated white blood cell count, increased protein content, and a glucose level usually in the low-to-normal range with occasional hypoglycorrhachia.

Mollaret cells. The most distinctive feature of the cerebrospinal fluid is the presence of numerous large monocytoïd cells called Mollaret cells. These have a prominent cytoplasm and large irregular nuclei (FIGURE 1). The cytoplasm is delicate and easily distorted when placed on a slide for microscopy. The nuclei are characteristically broad at one end and narrow at the opposite end. (On air-dried preparations, the broad end may exhibit toe-like projections. This latter change is not seen on fluid ThinPrep slides.) Mollaret cells readily degenerate and disappear from the cerebrospinal fluid and are rarely seen 18 to 24 hours after the onset of an attack, most likely because the cytoplasm is so delicate.

Mollaret initially considered the cells to be derived from endothelium and called them "endothelial leukocytes." However, they are now considered to be blood-derived monocytes. If the diagnosis is suspected, cerebrospinal fluid cytology should be ordered and the reviewing pathologist should be informed.

Diagnosis

The diagnosis of Mollaret meningitis requires exclusion of other conditions that may have similar clinical presentations (TABLE 1).

In our patient, the diagnosis of Mollaret meningitis was based on several factors:

- The characteristic clinical presentation was consistent with viral meningitis
- No pathogen could be identified
- There was no evidence to support the diagnosis of other conditions that might produce a similar clinical picture
- Examination of the cerebrospinal fluid

TABLE 1

Differential diagnosis of Mollaret meningitis

Infections

Idiopathic recurrent bacterial meningitis
Brain, spinal, or cranial epidural abscess
Viral meningitis
Cryptococcosis and other fungal infections
Brucellosis
Leptospirosis
Tuberculosis
Cerebral hydatid cyst

Defective immune mechanisms

Hypogammaglobulinemia
Sickle cell anemia
Chronic lymphocytic leukemia
Multiple myeloma
Lymphocytic lymphosarcoma
Lupus erythematosus
Splenectomy

Intracranial and intraspinal tumors

Cerebral hemangioma
Ependymoma
Craniopharyngioma
Glioblastoma
Intraspinal tumors
Intracranial epidermoid tumor

Congenital conditions

Myelomeningocele
Midline cranial or spinal dermal sinus
Petrous fistula
Neurenteric cysts

Other

Sarcoidosis
Behçet syndrome
Vogt-Koyanagi syndrome
Harada syndrome
Familial Mediterranean fever
Whipple disease

ADAPTED FROM HERMANS PE, GOLDSTEIN NP, WELLMAN WE. MOLLARET'S MENINGITIS AND DIFFERENTIAL DIAGNOSIS OF RECURRENT MENINGITIS: REPORT OF CASE, WITH REVIEW OF THE LITERATURE. AM J MED 1970; 52:128-140.

In Mollaret meningitis, symptom-free intervals last weeks to years

revealed Mollaret cells
Bryun et al¹⁴ established the following diagnostic criteria for Mollaret meningitis:

- Recurrent attacks of fever associated with signs and symptoms of meningeal irritation



- Attacks separated by symptom-free intervals lasting for weeks to months
- Cerebrospinal fluid pleocytosis of mixed type including endothelial cells, leukocytes, and lymphocytes during attacks
- Periods of remission without residual signs
- No causative organism detectable.

Goldi⁵ suggested the following amendments to Bryun's original criteria:

- Fever may be absent
- Approximately 50% of patients have transient neurologic symptoms or signs in addition to meningeal irritation
- The symptom-free intervals may vary from a few days to years
- There may be increased gamma globulin fraction in the cerebrospinal fluid.

Possible causes of Mollaret meningitis

Mollaret meningitis has generally been considered a disease of unknown cause. In some reports, epidermoid tumors leaked contents that were capable of inducing an inflammatory response, suggesting that this might be a cause of Mollaret meningitis.^{3,15,16} Viral causation has also been considered since the original characterization of Mollaret meningitis. Mollaret himself isolated an "ultravirus" in a case he reported.¹⁷

Nordbring and Gertzen¹⁸ postulated that herpes simplex virus is a cause of the syndrome; others have come to a similar conclusion.^{7,11,13,19} There have been numerous reports of antibody confirmation, tissue culture growth, or positive polymerase chain reaction for herpes simplex virus in patients with Mollaret meningitis.^{6-12,19-24} Current opinion supports herpes simplex virus as the likely cause.

Observations of increased peripheral eosinophil counts and elevated serum IgM levels in several patients also suggest a proposed allergic origin of this disorder.

THERAPY

2 What is the treatment for Mollaret meningitis?

- Antibiotics
- Antihistamines
- Corticosteroids


- Colchicine
- Treatment of symptoms
- None of the above

There is no specific therapy for this disease. Various antibiotics and antihistamines have been tried but did not alter the natural course of the disorder. Colchicine has been tried because of the similarity between Mollaret meningitis and familial Mediterranean fever and because it has been reported to decrease the severity and frequency of attacks.

More recently, it has been suggested that patients with frequent attacks may benefit from prophylactic acyclovir, which is effective in preventing clinically apparent recurrent bouts of herpes simplex virus infection.¹³ In one reported case the number of episodes decreased after corticosteroid treatment.⁴

We started our patient on acyclovir 400 mg twice daily. He has been followed by the infectious disease clinic for 18 months, and has been doing well without further episodes of meningitis at the time of this writing. We plan to continue acyclovir for 2 years, though this plan is not based on specific data.

PROGNOSIS

Although acute episodes can cause disabling symptoms, the long-term prognosis for patients with Mollaret meningitis is excellent. It is important that physicians be aware of this disorder because once it is identified, the patient may be spared multiple hospitalizations, extensive diagnostic evaluations, and unnecessary treatments. 

REFERENCES

1. Mollaret P. Meningitis endothelioleucocytaire multi-recurrente benigne: syndrome nouveau ou maladie nouvelle? *Rec Neurol* 1944; 76:57-76.
2. Hermans PE, Goldstein NP, Wellman WE. Mollaret's meningitis and differential diagnosis of recurrent meningitis: report of case, with review of the literature. *Am J Med* 1970; 52:128-140.
3. Chadarevian JP, Becker WJ. Mollaret's recurrent aseptic meningitis: relationship to epidermoid cysts. Light microscopic and ultrastructural cytological studies of the cerebrospinal fluid. *J Neuropath Exp Neurol* 1980; 39:661-669.
4. Coleman W, Lischner H, Grover W. Recurrent aseptic meningitis without sequelae. *J Ped* 1975; 87:89-91.
5. Goldi AP. Benign recurrent aseptic meningitis (Mollaret's meningitis): Case report and clinical review. *Arch Neurol* 1979; 36:657-658.
6. Haynes BF, Wright R, McCracken JP. Mollaret's meningitis.

Long-term prognosis: excellent



Dear Doctor:

As editors, we'd like you to look into every issue, every page of the *Cleveland Clinic Journal of Medicine*. We'd like to know...

1 How many issues do you look into?

Here's our goal:

All Most Half Few

2 How do you read the average issue?

Here's our goal:

Cover-to-cover
 Most articles
 Selected articles


**We put it in writing...
 please put it in writing for us.**
 We want to hear from you.

CLEVELAND CLINIC JOURNAL OF MEDICINE
 The Cleveland Clinic Foundation
 9500 Euclid Avenue, NA32
 Cleveland, Ohio 44195

PHONE 216.444.2661

FAX 216.444.9385

E-MAIL ccjm@ccf.org



- A report of three cases. *JAMA* 1976; 236:1967-1969.
7. **Jensenius M, Myrvang B, Storvold G, Bucher A, Hellum KB, Bruu AL.** Herpes simplex virus type 2 DNA detected in cerebrospinal fluid of 9 patients with Mollaret's meningitis. *Acta Neurol Scand* 1998; 98:209-212.
 8. **Mascia RA, Smith CW.** Mollaret's meningitis: an unusual disease with a characteristic presentation. *Am J Med Sci* 1984; 287:52-53.
 9. **Monteyne P, Sindic CJM, Laterre EC.** Recurrent meningitis and encephalitis associated with Herpes simplex type 2: demonstration by polymerase chain reaction. *Eur Neurol* 1996; 36:176-177.
 10. **Steel JG, Dix RD, Baringer JR.** Isolation of herpes simplex virus type 1 in recurrent (Mollaret) meningitis. *Ann Neurol* 1981; 11:17-21.
 11. **Teddar DG, Ashley R, Tyler KL, Levin MJ.** Herpes simplex virus infection as a cause of benign recurrent lymphocytic meningitis. *Ann Intern Med* 1994; 121:334-338.
 12. **Wolontis S, Jeannson S.** Herpes type 2 meningitis following herpes progenitalis. *West J Med* 1975; 123:490-491.
 13. **Yamamoto LJ, Tedder DG, Ashley R, Levin MJ.** Herpes simplex virus type 1 DNA in cerebrospinal fluid of a patient with Mollaret's meningitis. *N Engl J Med* 1991; 325:1082-1085.
 14. **Bryun GW, Straathof J, Raymakers G.** Mollaret's meningitis: differential diagnosis and diagnostic pitfalls. *Neurology* 1962; 12:745-753.
 15. **Cantu RC, Wright RL.** Aseptic meningitic syndrome with cauda equina epidermoid tumor. *J Pediatr* 1968; 73:114-116.
 16. **Schwartz JF, Balentine JD.** Recurrent meningitis due to an intracranial epidermoid. *Neurology* 1978; 28:124-129.
 17. **Mollaret P.** Benign recurrent pleocytic meningitis and its presumed causative virus. *J Nerv Ment Dis* 1952; 116:1072-1080.
 18. **Nordbring F, Gertzen O.** Case report: benign recurrent aseptic meningitis (Mollaret's meningitis). *Scan J Infect Dis* 1971; 3:75-78.
 19. **Gignoux L, Rylvlin P, Najjoulah F, Mauguire F.** *Meningite multirecurrente de Mollaret d'origine herpetique.* [Recurrent Mollaret meningitis of herpetic origin.] *Presse Med* 1998; 27:1470-1472.
 20. **Iivanainen M.** Benign recurrent aseptic meningitis of unknown etiology. *Acta Neurol Scand* 1973; 40:265-276.
 21. **Stalder H, Oxman MN, Dawson DM.** Herpes simplex meningitis: isolation of herpes simplex virus type 2 from cerebrospinal fluid. *N Engl J Med* 1973; 289:1296-1298.
 22. **Fodor PA, Levin MJ, Weinberg A, Sandberg E, Sylman J, Tyler KL.** Atypical herpes simplex virus encephalitis diagnosed by PCR amplification of viral DNA from CSF. *Neurology* 1998; 51:554-560.
 23. **Zunt JR, Marra CM.** Cerebrospinal fluid testing for the diagnosis of central nervous system infection. *Neurol Clin* 1999; 17(4):675-689.
 24. **Pruitt A.** Infections of the nervous system. *Neurol Clin* 1998; 16:419-448.

ADDRESS: Natalie G. Correia, Department of General Internal Medicine, E13, The Cleveland Clinic Foundation, 9500 Euclid Avenue, Cleveland, OH 44195; e-mail correin@ccf.org.

Visit our web site at
<http://www.ccjm.org>

Contact us by e-mail at
ccjm@ccf.org