

LAURENCE-MOON-BIEDL SYNDROME

A Report of Four Cases in One Family

E. Perry McCullagh, M.D., and E. J. Ryan, M.D.

The Laurence-Moon-Biedl syndrome was first described by Laurence and Moon in the *British Journal of Ophthalmology* in 1866. Further reports by Bardet¹ in 1920 and by Biedl² in 1922 resulted in the application of the terms Biedl-Bardet syndrome and Laurence-Biedl syndrome in some instances. The condition is uncommon, only 129 cases having been reported until the middle of 1940, according to Schwartz and Boudreau³.

The following features are characteristic of the condition: (1) Mental retardation, (2) pigmentary degeneration of the retina, (3) adiposogenital dystrophy, (4) familial occurrence, and (5) polydactylism or syndactylism. The presence of all of these characteristics is not a fundamental necessity in the establishment of the diagnosis, but when one or more is absent, a familial occurrence would appear to be a reasonable requirement, as mentioned by Molitch, et al.⁴ Of the 77 cases (including 4 of their own) in the world literature until 1932, reviewed by Reilly and Lisser⁵, only 25 presented all of the typical findings. Other anomalies have been reported by various observers, and include nystagmus, night blindness, atresia ani, various additional skeletal abnormalities, and deafness, among others.

The pathogenesis of the disorder is incompletely understood. The familial occurrence is significant. Numerous reports are available in which are recorded the finding of one or more characteristics of the condition in antecedents of affected individuals. There have been no instances reported indicating inheritance of the entire complex, although, as mentioned by Sorsby, Avery and Cockayne⁶, there have been case records which indicate that patients with this syndrome may not necessarily be sterile. Biedl² considered the disorder to be due to a diencephalic lesion. Raab⁷ suggested that a high or massive dorsum sellae might cause pressure on the infundibular stalk, thus disturbing the passage of secretion from the posterior lobe of the hypophysis to the floor of the third ventricle. This theory is no longer tenable. Ornstein⁸ stated: "The frequent association of the first three elements of the syndrome (adiposogenital dystrophy, retinitis pigmentosa, and mental deficiency) is explained on the basis of a developmental defect of the ectopic zone of the prosencephalon, for the embryological reason that the hypothalamus (infundibulum) and the optic chiasm take origin from the ventral segment of the ectopic zone of Schulte. The other developmental anomalies appear because of the coupling of

somatic genotypic defect characters with the cerebral unit characters mentioned above". Cockayne, Krestin, and Sorsby⁹ and Jenkins and Poncher¹⁰ suggested that the syndrome is due to a linkage of two or more genes bearing unit characters. These genes may bear simple recessives but cannot carry simple dominants. Cockayne, et al.⁹ give priority in this opinion to Rieger and Trauner¹¹, who felt that the parts of the syndrome based on mesoblastic and epiblastic defects are recessive and result from mutations of 2 genes in the same chromosome. Macklin¹² stated that the complete syndrome, "may be dependent upon two factors, both of which are necessary before the disease becomes evident, one of which is dominant and autosomal, and the other sex-linked recessive". Marmor and Lambert¹³ feel that the weight of evidence points to the fact that the pigmentary retinal degeneration in the Laurence-Moon-Biedl syndrome is a congenital anomaly dependent upon an inherited chromosomal factor, and they state further that this points toward the congenital nature of the usual form of retinitis pigmentosa. Hecker and Warren¹⁴ believe that the mental deficiency is of primary importance, a result of defective germ plasm in the antecedents, and that the other changes are secondary through involvement of the hypothalamus and indirectly the hypophysis. The polydactylism or other skeletal defect is considered to be another manifestation of defective germ plasm.

Complete pathologic study by Griffiths¹⁵, including careful examination of the endocrine system and serial sections of the brain from the anterior part of the chiasm to the midbrain, showed no lesion which could be considered causative.

The treatment for this condition has been widely variable, and numerous endocrine preparations have been used. On the whole, the results, for obvious reasons, have not been very satisfactory. The persistent use of thyroid extract has seemed most beneficial. Weight reduction might profitably be encouraged by a fixed low calorie diet.

Because of the relatively uncommon occurrence of the condition, we wish to report four cases which occurred in one family. A few such occurrences have been reported previously.

The parents in these cases are native born Italians who have lived in this country for thirty-six years. The mother is the first cousin of the father. As nearly as could be determined, there had been no other intermarriages, and there was no history of blindness or obesity in previous generations. The father was well developed and was healthy except for arterial hypertension, the blood pressure being 185 mm. systolic and 120 mm. diastolic. The mother was an obese, healthy woman, 35 years of age. A sister of the mother was normal. Of the five children, all male, in the family, only one was normal. The normal sibling was the second son (Fig. 1, B).

LAURENCE-MOON-BIEDL SYNDROME

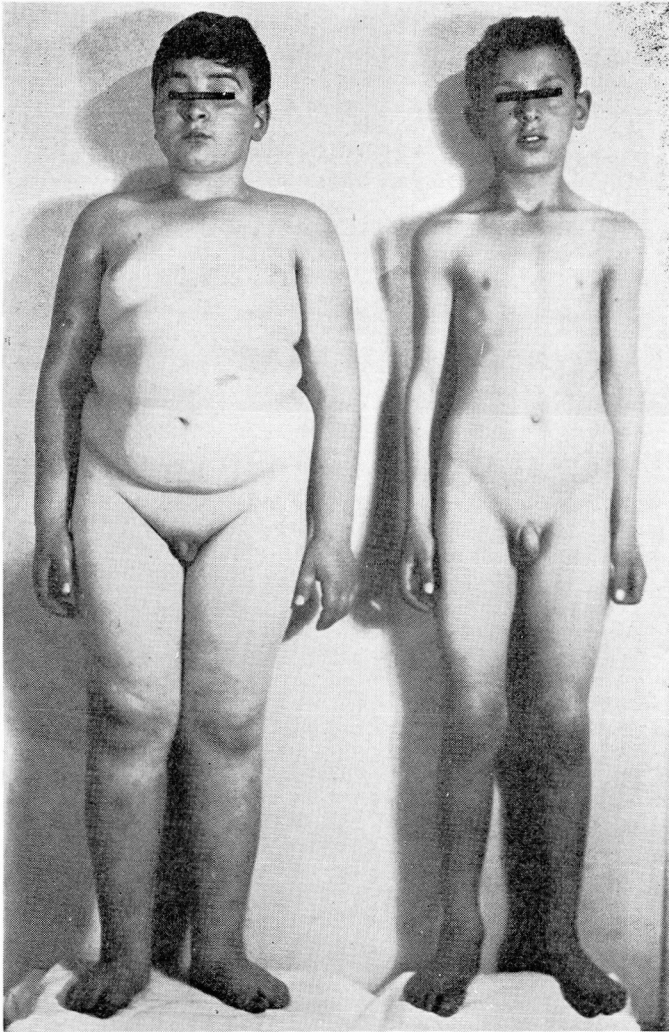


FIGURE 1: A. Case 1. B. Normal brother.

Case 1 (Fig. 1, A): The first patient was a boy, 6 years of age, who was seen first in 1926, complaining of "loss of vision" which had been progressive since infancy. He was the first child, was delivered by instruments, and weighed 7 pounds (3.2 Kg.) at birth. At the age of 4 months he had had a severe furunculosis which lasted about a month. He first walked at 19 months of age. The age at which he first talked could not be determined. When one year old he weighed 22 pounds (10 Kg.). When the patient was 5 months old, the mother noticed that he passed a larger amount of urine than did the other children at the same age. When 3 years old he had a diurnal somnolence, and an associated insomnia. From the age of 4 to 6 years, he frequently complained of headaches, and his mother noticed for the first time that he was gaining weight rapidly, although the exact amount could not be determined.

Physical examination revealed a 6 year old boy who weighed 73 pounds (33.8 Kg.), and was 44 inches (111.8 cm.) tall. No abnormalities were noted about the head and neck. The thyroid gland was not enlarged. The heart and lungs were normal, as was the abdomen, except for the obesity. The genitalia were thought to be normal, although the penis appeared small because of prominence of the mons pubis. The skin was dry. The hands were chubby and obese, with very definite tapering of the fingers. There was no polydactylism or syndactylism. Vertical and rotary nystagmus were present in both the right and the left eyes. A completely satisfactory examination of the retina could not be made because of the nystagmus, but diffuse pigmentary degeneration of the retina with optic atrophy was demonstrated. Both patellar and Achilles reflexes were absent. A roentgenogram of the skull showed a normal sella turcica. Five grains of whole pituitary gland three times a day were prescribed, but apparently the medication was not taken.

The family was not seen again until four years later. At that time the patient's pupils were found to be dilated, and a considerable degree of nystagmoid movement was present in both the vertical and the horizontal axis. The retina had a salt and pepper appearance. Although there was no red spot in the macula, there was definite central macular disturbance. There was an appearance as of diffuse chorioretinitis and a secondary optic atrophy. A roentgenogram of the skull was repeated and the sella turcica again was reported to be normal. The basal metabolic rate was minus 29 per cent. The glucose tolerance was normal and the Wassermann test of the blood gave a negative reaction.

The family was not seen again until December, 1933, three years after the second examination. Efforts to have them return for complete studies and treatment had been fruitless, so a journey was made to their home, where the entire family was seen. This examination revealed that the disease had progressed considerably in the three years. The patient was a large, heavy, mentally dull boy 12 years of age. He slept most of the time. He complained of occasional vertical headaches. There was no polydipsia or polyuria. His appetite was excessive, but he did not eat between meals, although he did manifest an increased desire for sweets. It was quite obvious that he was even more mentally subnormal than could be due to the handicap of blindness. He was reticent about talking, but when he talked his words were poorly formed and incomplete.

At the time of this examination the patient weighed 160 pounds (72.7 Kg.). His height was $58\frac{1}{4}$ inches (148 cm.), and his span was $61\frac{3}{8}$ inches (155.9 cm.). The blood pressure was very unstable. When first taken it varied from 134 mm. systolic and 100 mm. diastolic, to 140 mm. systolic and 90 mm. diastolic. The pulse rate was not elevated. The body contours showed feminine characteristics. The obesity was generalized, but there was a preponderance of the girdle and mammary distribution. The skin was very dry, especially over the arms and legs where it was scaly and almost ichthyotic. The hair of the scalp was short, coarse, and straight. There was a marked malar flush. The eyes showed vertical and rotary nystagmus so that retinal examination was not entirely satisfactory. In addition to the changes noted three years previously, there was some pigmentary degeneration about the nerve head. The teeth were in good condition. There was some spacing of the upper and lower teeth. The tonsils had been removed, but small tags remained on both sides. There was no lymphadenopathy in the cervical, axillary, epitrochlear, or inguinal regions. The thyroid gland was barely palpable. The chest was short and thick. The breasts, which were chiefly fat, were the size of those of a 16 year old girl. The areolae were larger than those of the average male. Stimulation of the areola or nipple produced erection and wrinkling. The lungs were normal to percussion and auscultation. The cardiac outline was normal. The second aortic sound was accentuated but there were no murmurs. The peripheral vessels were soft. The abdomen was obese and pendulous. It measured 44 inches (111.8 cm.) around the largest diameter. There was a flat, pigmented nevus of the vascular type about 5 x 3 cm. in area on the lower left abdominal quadrant. No abnormal organs or masses were palpable. The distance from the top of the symphysis pubis to the tip of the penis measured 3 inches (7.6 cm.), although the penis did not appear to be more than one inch in length because of the overlying fat. The testes were in the scrotum and felt quite normal. The hands were short, pudgy and thick, with marked tapering of the fingers. The legs were of the

LAURENCE-MOON-BIEDL SYNDROME

barrel type with large ankles. The deep tendon reflexes of the upper extremities were very sluggish. The patellar and Achilles reflexes could not be obtained.

A concentrated morning specimen of urine was obtained, and a Friedman test was done. This showed no excess of gonadotropic substance.

In 1932, when the patient's chronologic age was 11 years, his mental acuity had been studied in anticipation of entering Braille classes, and his mental age was estimated to be 5 years.

Case 2 (Fig. 2): Cases 2 and 3 are twins. This patient was first seen in 1930 at the age of 6 years. The complaints were blindness and obesity. His birth weight was not known. He was delivered by instruments and was a normal baby. Development was apparently normal until the age of one year, when the patient began to gain weight rapidly. No complaint of headache was made. Impairment of vision was noted during the first year of life. Polyphagia had been observed, but there had been no polyuria, polydipsia or somnolence.

Physical examination revealed marked obesity, and the body configuration was feminine. The skin was dry, especially over the anterior parts of the legs. The hair was of normal texture. The thyroid gland was not palpable. The genitalia were developed normally for the age. The fingers tapered slightly. Examination of the eyes revealed findings similar to those in the first case, except that there was a more marked, diffuse chorioretinitis in the left eye, and there was a dark, pigmented area about the macula. There was neither polydactylism nor syndactylism. A roentgenogram revealed the sella turcica to be small, but normal.

When the patient was next seen three years later, in December, 1933, he was an active, alert boy, but of less than average mentality. There was some polyphagia and an increased liking for sweets, but no polydipsia or polyuria. He complained of occasional vertical headaches. His speech was broken and jerky. The words were very poorly formed and it was difficult to understand him. All of the affected boys demonstrated this same faulty enunciation which could be attributed in some degree to the fact that Italian was the only language spoken in the household, and English had been learned only during a year and a half of tutoring in Braille. Their speech was not the dysarthric type.

At the time of the examination in 1933, when 9 years of age, the patient was $58\frac{1}{4}$ inches (148 cm.) tall, weighed 124 pounds (56.4 Kg.), and had a span of $59\frac{3}{8}$ inches (150.8 cm.). Abnormal fat deposits were present about the trochanteric and mammary areas, although there was a generalized obesity. The skin was very dry all over the body. There was a malar flush. The condition of the eyes was essentially the same as in 1930, but there was some increase in pigmentary degeneration. A vertical and horizontal nystagmus was present. The upper teeth were slightly spaced. One molar had erupted bilaterally and a second molar was partially erupted on the right and fully erupted on the left side. The tonsils had been removed. The thyroid gland was barely palpable. There was no lymphadenopathy. The chest measured 32 inches (76.2 cm.) at rest. The heart and lungs were normal. The second aortic sound was accentuated. The blood pressure was 124 mm. systolic and 95 mm. diastolic. The abdomen was obese and measured 37 inches (94 cm.) at its greatest circumference. There were no abnormal masses or organs. Measurement from the pubis to the floor was $30\frac{1}{2}$ inches (77.5 cm.); from the tip of the penis to the edge of the symphysis pubis was $2\frac{1}{8}$ inches (5.4 cm.). The penis appeared normal. The testes were small and lay in the scrotum. There was a scant beginning of pubic hair. No axillary hair was seen. The patient had the same type of thick hand with tapering fingers as did the other affected members of the family. The legs were of the barrel type. The reflexes were all present and normal. Urinary prolan was not increased as judged by the Friedman test. The mental age of this boy at the age of 8 was estimated to be 5 years.

Case 3 (Fig. 3): This patient was first seen in 1930 when he was 6 years of age. His birth had been by instrument delivery and the birth weight was not known. His development had been the same as that of his twin brother (Case 2). At the age of 5 years, he accidentally shot himself with a 32 caliber revolver. The bullet entered the left orbit, de-

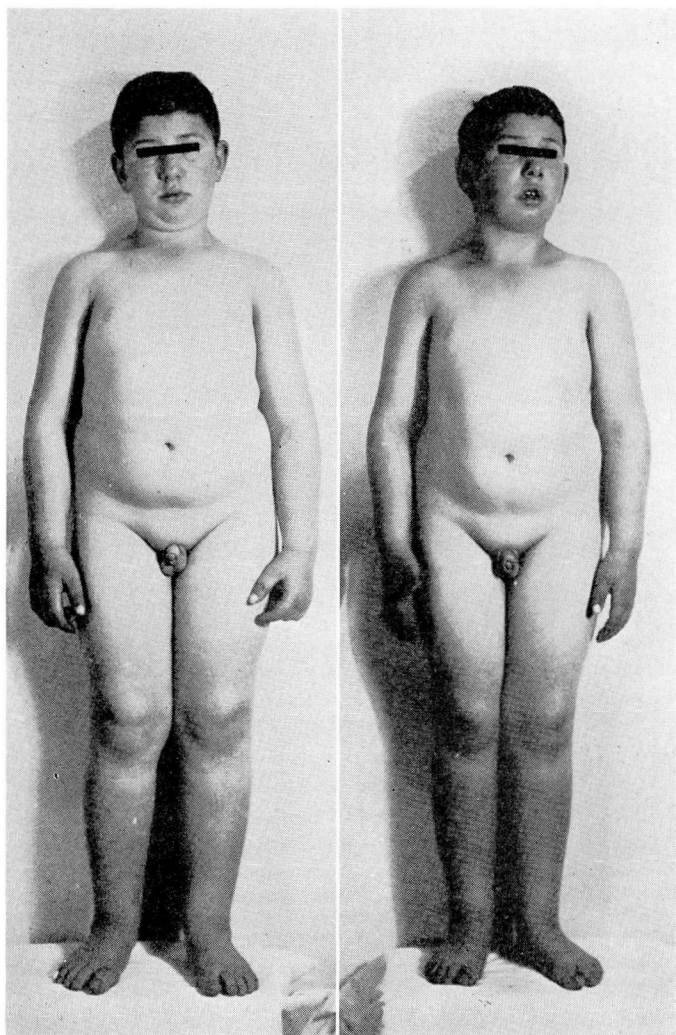


FIGURE 2: Case 2.

FIGURE 3: Case 3.

stroyed the iris, and was reputed to have lodged in his skull, but a roentgenogram of the skull did not reveal it and no operative procedure had been performed.

The height was 48 inches (122 cm.). His body contour was essentially the same as that of his twin except that he was somewhat smaller. The fat deposits were of the female distribution. The thyroid gland was not palpable. The skin was normal. No secondary growth of hair was present. There was considerable degree of redness of the macular area of the right eye which was more marked than that of Case 1. In the left eye was a traumatic cataract. Neither polydactylism nor syndactylism was present. The basal metabolic rate was minus 25 per cent.

When the patient was seen in 1933, at the age of 9 years, he was alert and active, although there was some evidence of decreased mental capacity. There was a slight polyphagia and craving for sweets, but there was no polydipsia or polyuria. He com-

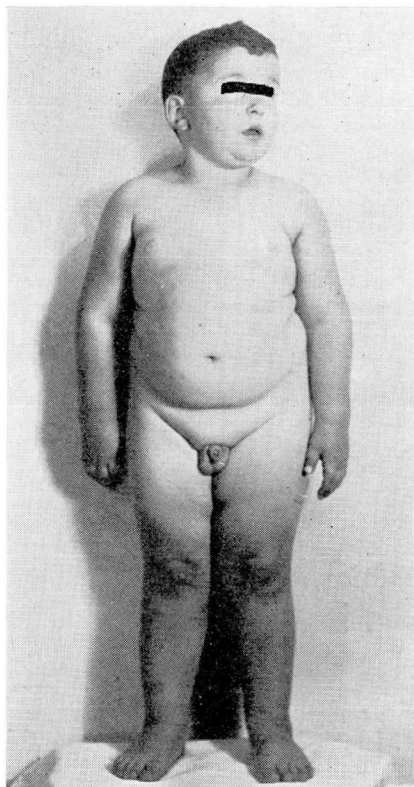


FIGURE 4: Case 4.

plained of occasional vertical headaches. He was 57 inches (144.8 cm.) tall, weighed 126 pounds (57.3 Kg.) and his span was $57\frac{3}{4}$ inches (146.7 cm.). The skin was very dry. The malar flush was prominent. There was a vertical and rotary nystagmus. The macular hyperemia was not noted at this time, but there was an increase of pigmentation about the nerve head. The tonsils had been removed. The teeth looked sound, although the first and second lower premolars were not completely erupted. The upper teeth were only partially erupted and all were spaced. There were no upper second molars. The thyroid gland was not palpable. The chest was short and thick. The nipples were not enlarged. The areolae were of normal male type. There were no significant abnormalities of the lungs or heart, although the second aortic sound was accentuated. The blood pressure was 134 mm. systolic and 96 mm. diastolic. The abdomen was obese and the mons pubis was prominent. The greatest circumference of the abdomen was $36\frac{1}{2}$ inches (93.7 cm.). No abnormal masses or organs were present. The genitalia appeared normal. From the pubis to the floor measured $30\frac{1}{4}$ inches (76.8 cm.). From the inferior border of the pubis to the tip of the penis measured $2\frac{1}{2}$ inches (6.4 cm.). The testes were small and lay in the scrotum. The reflexes were sluggish. There was an early growth of pubic hair but no axillary hair was present. The hands and feet were similar to those of the brothers. Urinary prolan was not increased according to the Friedman test. When his chronologic age was 8 years, he had attained an age of 6 years by mentality tests.

Case 4 (Fig. 4): This patient was 5 years old when seen in 1930. He was delivered by instruments and was a normal infant. There was no history of childhood convulsions or

injuries. He did not complain of headaches. Blindness had been progressive since the age of one year. Examination revealed a marked obesity which gradually had increased since the age of 2 years. It was particularly noticeable about the abdomen and the mammary and trochanteric areas. The skin was very fine, and was relatively but not entirely hairless. The head hair was normal. There was no somnolence, polyphagia, polydipsia or polyuria. The teeth were not spaced. The thyroid gland was palpable. The genital development was normal and the testes were in the scrotum. The hands were very short with tapered fingers. Examination of the eyes showed diffuse chorioretinitis, disc changes as seen in the other boys, and changes of a secondary type in the retinas. Polydactylism and syndactylism were absent. The sella turcica was of the normal size and shape.

When the patient was seen three years later, when 8 years old, he presented the same body build, malar flush, and dry skin that his brothers did, but to a lesser degree. He was the most alert and inquisitive of the group. He had the same speech difficulty and mental deficiency that the others exhibited. He weighed 100 pounds (45.5 Kg.) and was 50 $\frac{1}{4}$ inches (127.6 cm.) tall. The scalp hair was the same coarse, straight type. The upper teeth were spaced. Both lower second premolars were carious. The first lower, right premolar had been extracted and the second molars had not erupted. All the upper teeth except the central incisors were incompletely erupted or at least very short. The tonsils were present and were not diseased. The chest was small. The nipples and areolae were not enlarged. The heart and lungs were normal. The blood pressure was 134 mm. systolic and 90 mm. diastolic. The abdomen was obese and there were no palpable abnormal masses or organs. The genitalia were small. From the anterior border of the symphysis pubis to the tip of the penis measured approximately 1 $\frac{1}{5}$ inches (3.8 cm.). From the pubis to the floor measured 25 $\frac{1}{2}$ inches (64.8 cm.). The hands and legs were the same as seen in the other brothers. The reflexes were all present and active. There was vertical and rotary nystagmus. The fundi were pale. The nerve head was pale and covered with, or had the appearance of, a black granular pigment. Urinary prolan was not increased, as judged by the Friedman test.

DISCUSSION AND SUMMARY

Four cases of the Laurence-Moon-Biedl syndrome are presented; first, because of the relative rarity of the condition; and second, because of the still less frequent occurrence of the syndrome in four members of the same family. The diagnosis has been well established by the presence of four of the five cardinal symptoms in each case, the only one lacking being the polydactylism. This was excluded by roentgenologic study, as well as by clinical examination. It might also be mentioned that in these, as in other reported cases, a deficiency in development of the genitalia in the presence of marked obesity, may often be more apparent than real, and that a diagnosis of hypogonadism often is exceedingly difficult before the age of puberty. Parental consanguinity, as reported here, is frequent in the Laurence-Moon-Biedl syndrome.

REFERENCES

1. Bardet, G.: Thèse de Paris, 107,470, 1920.
2. Biedl, A., Deutsche med. Wehnsehr., 48:1630, 1922.
3. Schwartz, R. C., and Boudreau, E. M.: Laurence-Moon-Biedl syndrome without polydactylism but with syndactylism; Report of a case, Arch. Ped., 57:520-524, (August) 1940.

LAURENCE-MOON-BIEDL SYNDROME

4. Molitch, M., Gladen, R. G., and Pigott, A. W.: Laurence-Moon-Biedl syndrome, Report of three cases, *Endocrinol.* 19:682-688, (November-December) 1935.
5. Reilly, W. A., and Lisser, H.: Laurence-Moon-Biedl syndrome, *Endocrinol.* 16:337-357, (July-August) 1932.
6. Sorsby, A., Avery, H., and Cockayne, E. A.: Obesity, hypogenitalism, mental retardation, polydactyly, and retinal pigmentation. The Laurence-Moon-Biedl syndrome, *Quart. J. Med.*, 8:51-68, (January) 1939.
7. Raab, W.: Klinische und röntgenologische Beiträge zur hypophysären und zerebralen Fettsucht und Genitolatrophie, *Wien. Arch. f. inn. Med.*, 7:443-530, 1924.
8. Ornsteen, A. M.: A contribution to the pathogenesis and heredity of the Laurence-Biedl syndrome (dystrophia adiposogenitalis, retinitis pigmentosa, mental deficiency, and polydactyly), *Am. J. M. Sc.*, 183:256-268, (February) 1932.
9. Cockayne, E. A., Krestin, D., and Sorsby, A.: Obesity, hypogenitalism, mental retardation, polydactyly, and retinal pigmentation, The Laurence-Moon-Biedl Syndrome, *Quart. J. Med.*, 4:93-120, (April) 1935.
10. Jenkins, R. L., and Poncher, H. G.: Pathogenesis of the Laurence-Biedl syndrome, *Am. J. Dis. Child.* 50:178-186, (July) 1935.
11. Rieger H., Trauner, R.: Ueber einen Fall von Biedl—Bardet—schem Syndrom und die Erblichkeitsverhältnisse dieses Zustandes, *Ztschr. f. Augenh.*, 68:235-243, (July) 1929.
12. Macklin, M. T.: Laurence-Moon-Biedl syndrome: Genetic Study, *J. Hered.*, 27:97-104, (March) 1936.
13. Marmor, J., and Lambert, R. K.: Laurence-Moon-Biedl syndrome. Its relation to general problem of retinitis pigmentosa, *Arch. Int. Med.*, 61:523-536, (April), 1938.
14. Hecker, A. O. and Warren, V. C.: Girdle type adiposity among mentally deficient males, *Am. J. Dis. Child.* 54:1257-1271, (December) 1937.
15. Griffiths, G. M.: Laurence-Moon-Biedl syndrome, A pathological report, *J. Neurol & Psychiat.*, 1:1-4, (January) 1938.