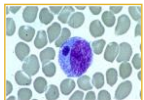


<p>S l i d e 1</p>	<p style="text-align: center;">Ehrlichiosis</p> <p style="text-align: center;"><small>Canine Monocytic Ehrlichiosis, Canine Rickettsiosis, Canine Hemorrhagic Fever, Tropical Canine Pancytopenia, Tracker Dog Disease, Canine Tick Typhus, Nairobi Bleeding Disorder, Canine Granulocytic Ehrlichiosis, Equine Monocytic Ehrlichiosis, Potomac Horse Fever, Equine Granulocytic Ehrlichiosis, Tick-borne Fever, Human Monocytic Ehrlichiosis, Human Granulocytic Ehrlichiosis, Sennetsu Fever, Glandular Fever</small></p>	<p>Ehrlichiosis is a group of diseases, usually named according to the host species and the type of white blood cell most often infected.</p>
<p>S l i d e 2</p>	<p style="text-align: center;">Overview</p> <ul style="list-style-type: none"> • Organism • History • Epidemiology • Transmission • Disease in Humans • Disease in Animals • Prevention and Control 	<p>In today’s presentation we will cover information regarding the organisms that cause ehrlichiosis and their epidemiology. We will also talk about the history of the disease, how it is transmitted, species that it affects (including humans), and clinical and necropsy signs observed. Finally, we will address prevention and control measures, as well as actions to take if ehrlichiosis is suspected.</p>
<p>S l i d e 3</p>	<p style="text-align: center;">THE ORGANISM</p>	
<p>S l i d e 4</p>	<p style="text-align: center;">The Organism(s)</p> <ul style="list-style-type: none"> • Coccobacilli <ul style="list-style-type: none"> – Small, pleomorphic – Gram negative – Obligate intracellular • Three intracytoplasmic forms <ul style="list-style-type: none"> – Initial body – Elementary body – Morula 	<p>Ehrlichiosis is a broad term used for a group of diseases that are usually named according to the host species and the type of white blood cell infected. The organisms that cause ehrlichiosis are small pleomorphic gram-negative obligate intracellular coccobacilli. There are three intracytoplasmic forms: initial body, elementary body, morula (a vacuole-bound cluster of organisms that appears as a basophilic inclusion in monocytes or granulocytes). In blood smears, the morula is diagnostic for ehrlichiosis.</p> <p>[Photo: Morulae detected in a monocyte on a peripheral blood smear, associated with <i>E. chaffeensis</i> infection. Source: CDC]</p>
<p>S l i d e 5</p>	<p style="text-align: center;">Zoonotic Species</p> <ul style="list-style-type: none"> • <i>Ehrlichia chaffeensis</i> • <i>Ehrlichia ewingii</i> • <i>Anaplasma phagocytophilum</i> • <i>Neorickettsia sennetsu</i> • <i>Ehrlichia canis</i> (possibly) 	<p>The zoonotic species are <i>Ehrlichia chaffeensis</i>, <i>Ehrlichia ewingii</i>, <i>Anaplasma phagocytophilum</i>, <i>Neorickettsia sennetsu</i>. <i>Ehrlichia canis</i> may also be zoonotic but this remains to be confirmed. An organism that appears to be a strain of <i>E. canis</i> was recently isolated from a chronically infected, asymptomatic human in Venezuela. The same strain was isolated from local dogs.</p>

S
I
d
e
6

Non-zoonotic Species	
•	<i>Ehrlichia bovis</i>
•	<i>Ehrlichia muris</i>
•	<i>Ehrlichia ondiri</i>
•	<i>Ehrlichia ovina</i>
•	<i>Ehrlichia ruminantium</i>
•	<i>Anaplasma platys</i>
•	<i>Neorickettsia risticii</i>

Ehrlichia not currently thought to be zoonotic include *Ehrlichia bovis*, which causes bovine petechial fever in cattle in the Middle East, Africa and Sri Lanka; *Ehrlichia muris*, found in rodents in Japan and not currently associated with any disease; *Ehrlichia ondiri*, found in cattle and wild ruminants in Africa; *Ehrlichia ovina*, isolated from sheep in the Middle East; *Ehrlichia ruminantium* (formerly *Cowdria ruminantium*), which causes heartwater in ruminants. This organism has also been found in dogs with symptoms suggestive of canine ehrlichiosis; *Anaplasma platys* (formerly *Ehrlichia platys*), which causes cyclic canine thrombocytopenia. It has been found in dogs in the United States, Taiwan, Greece and Israel; *Neorickettsia risticii*, which causes Potomac horse fever/ equine monocytic ehrlichiosis in the U.S. This organism has also been identified in dogs with the symptoms of ehrlichiosis.

S
I
d
e
7

Ehrlichial Diseases	
Disease	Causative Agent
Canine monocytic ehrlichiosis	<i>Ehrlichia canis</i> <i>Ehrlichia chaffeensis</i>
Canine granulocytic ehrlichiosis	<i>Anaplasma phagocytophilum</i> <i>Ehrlichia ewingii</i>
Equine monocytic ehrlichiosis (Potomac horse fever)	<i>Neorickettsia risticii</i>
Equine granulocytic ehrlichiosis	<i>Anaplasma phagocytophilum</i>
Tick-borne fever	<i>Anaplasma phagocytophilum</i>
Human monocytic ehrlichiosis	<i>Ehrlichia chaffeensis</i> <i>Ehrlichia ewingii</i>
Human granulocytic ehrlichiosis	<i>Anaplasma phagocytophilum</i>
Sennetsu fever	<i>Neorickettsia sennetsu</i>

Canine monocytic ehrlichiosis is caused by *Ehrlichia canis* and, occasionally, *E. chaffeensis*. Canine granulocytic ehrlichiosis is caused by *Anaplasma phagocytophilum* and *Ehrlichia ewingii*. Equine monocytic ehrlichiosis/Potomac horse fever is caused by *Neorickettsia risticii* (formerly *Ehrlichia risticii*). Equine granulocytic ehrlichiosis is caused by *Anaplasma phagocytophilum*. Tick-borne fever, a disease of ruminants, is caused by *Anaplasma phagocytophilum*. Human monocytic ehrlichiosis is caused by *Ehrlichia chaffeensis* and *E. ewingii*. Human granulocytic ehrlichiosis is caused by *Anaplasma phagocytophilum*. Sennetsu fever is caused by *Neorickettsia sennetsu* (formerly *Ehrlichia sennetsu*).

S
I
d
e
8

HISTORY	

S
I
d
e
9

History	
•	1950s
–	Human infections with <i>Neorickettsia sennetsu</i> reported
•	1980s
–	New species recognized in humans
•	<i>Ehrlichia chaffeensis</i>
•	<i>E. ewingii</i>
•	<i>Anaplasma phagocytophilum</i>

Human infections with *Neorickettsia sennetsu* have been reported since the 1950s, but *Ehrlichia chaffeensis*, *E. ewingii* and *Anaplasma phagocytophilum* were first found to infect humans in the 1980s; the prevalence and full of extent of the disease are, in many cases, still unknown. *E. canis* has, to date, only been isolated from one asymptotically infected human.

S
l
i
d
e

1
0

EPIDEMIOLOGY

S
l
i
d
e

1
1

Geographic Distribution

- Worldwide
 - *E. chaffeensis*, *E. canis*, *A. phagocytophilum*
- Southeast/south central U.S.
 - *E. ewingii*
- Japan, Malaysia
 - *E. sennetsu*


E. chaffeensis, *E. canis* and *Anaplasma phagocytophilum* are found worldwide. *E. ewingii* has been described, to date, only in the southeastern and south central United States. *E. sennetsu* has been reported mainly in Japan and Malaysia, but may exist in other parts of Asia. In some cases, disease syndromes are not reported from the organism’s entire geographic range. Although *Anaplasma phagocytophilum* is found worldwide, tickborne fever (or a similar syndrome) has been reported only in ruminants in Europe, India and South Africa.

S
l
i
d
e

1
2

Seasonality

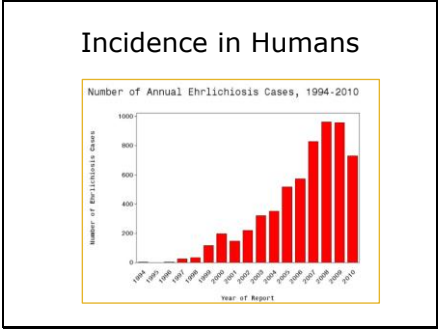
- Dogs
 - No seasonal variation
 - Disease occurs throughout the year
- Horses
 - Late fall, winter, spring
 - California
- Cattle (tick-borne fever)
 - Spring, early summer



In dogs, ehrlichiosis is reported throughout the year, due to the prolonged clinical course and the ability of its tick vector (*Rhipicephalus appendiculatus*) to survive indoors. In the U.S., equine granulocytic ehrlichiosis is most common in California, with sporadic cases reported in other states. Most cases are seen in late fall, winter and spring. In cattle, tick-borne fever usually occurs as a spring and early summer epidemic when dairy cattle are turned out to pasture. In sheep, symptoms are usually seen in young lambs born in tick-infested areas and older sheep introduced to such areas. [Photos: (Top) Dog. Source: Marilyn Peddle/Wikimedia Commons; (Middle) Horse. Source: Steve Hillebrand/US Fish and Wildlife Service; (Bottom) Cattle in field. Source: USDA NRCS]

S
l
i
d
e

1
3



Data Table for Number of Annual Ehrlichiosis Cases, 1994 – 2010
 The graph displays the number of human cases of ehrlichiosis cases reported to CDC annually from 1994 through 2010. Cases of ehrlichiosis have increased steadily from 200 cases in 2000, when the disease became nationally notifiable, to 961 cases in 2008. Cases decreased significantly in 2010 from 944 reported in 2009 to 740 reported in 2010. [Source: Centers for Disease Control and Prevention at <http://www.cdc.gov/ehrlichiosis/stats/>]

S
l
i
d
e

1
4

TRANSMISSION

S
I
d
e
1
5

Transmission

- Ticks (family Ixodidae)
 - *Ehrlichia canis*
 - *Rhipicephalus sanguineus*
 - Brown dog tick
 - *Dermacentor variabilis*
 - American dog tick
 - *E. chaffeensis*
 - *Amblyomma americanum*
 - Lone Star tick
 - *E. ewingii*
 - *Amblyomma americanum*
 - *Dermacentor variabilis*
 - *Rhipicephalus sanguineus*



Ehrlichiae are transmitted by ticks in the family Ixodidae. *Ehrlichia canis* is transmitted by the brown dog-tick *Rhipicephalus sanguineus*. Recently it was also shown to be experimentally transmitted by *Dermacentor variabilis*, the American dog tick. *E. chaffeensis* is mainly transmitted by *Amblyomma americanum*, the Lone Star tick. *Amblyomma americanum* is also thought to be the primary vector for *E. ewingii*. In addition, evidence of infection has been found in *Dermacentor variabilis* and *Rhipicephalus sanguineus*.

[Photo: (Top) *Rhipicephalus sanguineus*, brown dog tick; (Bottom) *Amblyomma americanum*, the Lone Star tick. Source: CDC Public Health Image Library]

S
I
d
e
1
6

Transmission

- *Anaplasma phagocytophilum*
 - *Ixodes scapularis*
 - Black-legged tick
 - *I. pacificus*
 - *I. ricinus*
- *Neorickettsia sennetsu*
 - Unknown
- *Ehrlichia* spp. also transmitted by blood transfusions, biting insects



Anaplasma phagocytophilum is transmitted by species of *Ixodes*. In the U.S., the vectors include *Ixodes scapularis* (the black-legged tick) and *I. pacificus*. *I. ricinus* transmits this organism in Europe. The vector for *Neorickettsia sennetsu* is unknown. It may be a tick or a helminth. Transovarial transmission is not known to occur; the ticks seem to first become infected as larvae or nymphs. Transstadial transmission has been proven for some species, including *E. canis* in *Rhipicephalus sanguineus* and *E. chaffeensis* in *Amblyomma americanum*. Infections can also be transmitted by blood transfusions, and mechanical transmission by biting insects has been suggested as a possible means of spread. [Photo: *Ixodes scapularis*, black-legged tick. Source: Scott Bauer/U.S. Department of Agriculture]

S
I
d
e
1
7

DISEASE IN HUMANS

S
I
d
e
1
8

Disease in Humans

- Wide spectrum of disease
 - Human monocytic ehrlichiosis
 - Human granulocytic ehrlichiosis
- Symptoms often non-specific
 - Headache, fever, malaise
 - Gastrointestinal signs
 - Rash on trunk, legs, arms, face
- Severe if immunocompromised

In humans, ehrlichiosis varies from a mild or asymptomatic infection to a severe, possibly fatal disease. Human monocytic and granulocytic ehrlichiosis are clinically similar, particularly during the early stages. The early symptoms are nonspecific. A headache, fever, malaise, chills and muscle aches are common presenting signs. Gastrointestinal signs including nausea, vomiting, diarrhea and abdominal pain are fairly common. Other symptoms may include anorexia, photophobia, conjunctivitis, joint pains, coughing and confusion. A rash is occasionally seen, particularly in children infected with *E. chaffeensis*. The rash can involve the trunk, legs, arm and face but typically spares the hands and feet and has been described variously as macular, papular, reticular, maculopapular and petechial. Severe symptoms, seen particularly in immunocompromised patients, may include a prolonged fever, renal failure, opportunistic infections, respiratory distress, hemorrhages from disseminated intravascular coagulopathy, cardiomyopathy, multiorgan failure, meningoenzephalitis, seizures or coma. Complications are more common in human granulocytic ehrlichiosis.

S
I
D
E
1
9

Disease in Humans

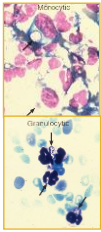
- Sennetsu fever
 - Mild disease
 - Resembles mononucleosis
- *Ehrlichia ewingii*
 - Reported in immunocompromised
- *E. canis*
 - May rarely be zoonotic

Sennetsu fever is a relatively mild infection that resembles infectious mononucleosis. It is characterized by fever, malaise, anorexia, lymphadenopathy and hepatosplenomegaly. Fatigue, chills, headache, backache and myalgias have also been reported. Increased circulating mononuclear cells and atypical lymphocytes are often found. A rash is rare, but generalized erythematous reactions or localized petechiae have been described. Antibodies to *Neorickettsia sennetsu* have also been found in some cases of fever of unknown origin in Asia. Deaths have not been reported. Clinical disease caused by *E. ewingii* has been reported only in a few patients, and many of these patients were immunosuppressed. The full role of this organism in human disease is under investigation. *E. canis* may rarely be zoonotic. Recently, a strain of this organism was isolated from a chronically infected, asymptomatic human in Venezuela. This strain was identical to those found in local dogs. The zoonotic potential of *E. canis* remains to be confirmed.

S
I
D
E
2
0

Diagnosis

- Initial diagnosis
 - History, clinical signs
 - Hematologic abnormalities
 - Serum chemistry
- Definitive diagnosis
 - IFA
 - ELISA
 - PCR
 - Culture



The initial diagnosis is usually based on the history, clinical signs, hematologic abnormalities and changes in serum chemistry. Serology is used for confirmation. Human monocytic or granulocytic ehrlichiosis is usually diagnosed with an indirect immunofluorescence assay (IFA). ELISAs are also in development. The serologic tests for Sennetsu fever include an IFA and complement fixation. Cross-reactions can occur. Morulae can occasionally be found in neutrophils or mononuclear cells. Only a small percentage of cells are infected. Polymerase chain reaction testing can also detect ehrlichiae. Immunohistochemistry and *in situ* hybridization have been described on spleen and lymph node samples. Culture of the organism is difficult and time-consuming, and may not be practical in clinical cases. *Anaplasma phagocytophilum* and *E. chaffeensis* have been isolated from the blood of acutely ill patients, using various cell lines such as canine DH82 and human HL-60 cells. *E. chaffeensis* is usually found after 7 to 36 days, and *A. phagocytophilum* in 7 to 12 days. Species can be identified by the sequencing and analysis of 16S rRNA.

[Photos: Photomicrographs of human white blood cells infected with the agent of human granulocytic ehrlichiosis (not specified) and the agent of human monocytic ehrlichiosis (*Ehrlichia chaffeensis*). Source: CDC Public Health Image Library]

S
I
D
E
2
1

Treatment

- Antibiotics
 - Tetracyclines
 - Doxycycline
 - Early treatment critical
 - Prolonged therapy may be necessary in severe or complicated cases

Ehrlichiosis in humans is usually treated with tetracyclines; doxycycline is currently the drug of choice. Other antibiotics may be used in some circumstances. Early treatment is critical; uncomplicated cases usually respond promptly, but prolonged treatment may be necessary for severe or complicated disease.

S
I
d
e

2
2


DISEASE IN ANIMALS

S
I
d
e

2
3

Species Affected

- *E. chaffeensis*
 - Dogs, coyotes, red foxes, goats, deer (reservoir)
- *E. ewingii*
 - Dogs (reservoir)
- *E. canis*
 - Dogs, wolves, jackals (reservoir)



E. chaffeensis can infect dogs, coyotes, red foxes, deer, goats and lemurs. Disease has been documented in dogs and lemurs. The primary reservoir hosts are deer. *E. ewingii* causes disease in dogs, which may also be the reservoir host. *E. canis* can infect dogs, wolves and jackals, which are also the reservoir hosts.

[Photo: Dog in field. Source: Adam Ziaja/Wikimedia Commons]

S
I
d
e

2
4

Species Affected

- *A. phagocytophilum*
 - Dogs, horses, llamas, cats, cattle
 - Deer, elk, rodents (reservoirs)
- *E. sennetsu*
 - Dogs


A. phagocytophilum can cause disease in dogs, horses, llamas, cats, cattle, sheep, goats and non-human primates. It can also infect deer, bison, elk and rodents. Deer, elk and rodents are likely to be reservoir hosts. *E. sennetsu* can cause mild symptoms in experimentally infected dogs. Ehrlichiae can establish persistent infections in their vertebrate hosts.

S
I
d
e

2
5

Canine Monocytic Ehrlichiosis

- Caused by *E. canis*, *E. chaffeensis*
- Early signs often non-specific
- May cause:
 - Bleeding disorders
 - Ocular signs
 - Renal failure
 - Reproductive disorders
 - Neurological disease
 - Death



Most cases of canine monocytic ehrlichiosis are caused by *E. canis*, and infections with this organism are better understood than infections with *E. chaffeensis*. In experimentally infected dogs, three stages of disease – acute, subclinical and chronic – have been described. These stages may not be easy to distinguish in naturally infected dogs. A wide variety of clinical signs, from mild to severe, have been reported in the acute stage of *E. canis* infections. Some dogs present with nonspecific signs such as fever, lethargy, anorexia, lymphadenopathy, splenomegaly and weight loss. Vomiting, diarrhea, lameness, edema in the hind legs, coughing, dyspnea, and a serous to purulent oculonasal discharge may also be seen. Symptoms of bleeding disorders including anemia, mild epistaxis, petechiae and ecchymoses have been reported. Ocular signs can include anterior uveitis, corneal opacity, hyphema and tortuous retinal vessels. Focal chorioretinal lesions, consisting of central pigmented spots with surrounding areas of hyperreflectivity, may be seen. Subretinal hemorrhages can cause retinal detachment and blindness. The acute phase typically lasts for 1 to 4 weeks, and the symptoms usually resolve spontaneously. Some dogs that recover clinically from the acute phase remain subclinically infected for months or years. During the subclinical stage, an infected dog can clear the parasite, remain infected but asymptomatic, or develop chronic disease. There may also be progressive deterioration in the hematologic values during this stage.

The conditions leading to the development of the chronic phase are unknown. In the chronic phase, common symptoms include chronic weight loss, weakness, depression, fever, anorexia, and edema of the limbs, tail and scrotum. Bleeding disorders occur frequently, and may result in pale mucous membranes, petechiae, ecchymoses, epistaxis, hematuria or melena. Pancytopenia can occur, and may lead to secondary infections. Anterior uveitis, retinal disease and blindness have been reported. Chronically infected dogs may also develop arthritis, renal failure, interstitial pneumonia or polymyositis. Reproductive disorders have been reported, including prolonged bleeding during estrus, inability to conceive, abortion and neonatal death. Death can occur as a consequence of hemorrhages or secondary infections. Neurological signs can be seen either during the acute or the chronic stage. They may include depression, ataxia, vestibular dysfunction, generalized or localized hyperesthesia, intention tremors of the head, paraparesis or tetraparesis, cranial nerve deficits, seizures, and coma. *E. chaffeensis* infections, clinically indistinguishable from *E. canis*, have been reported in naturally infected dogs. [Photo: There are multiple petechiae and ecchymoses on the gingival and buccal mucosa of this dog due to *Ehrlichia canis*. Photo from Armed Forces Institute of Pathology/CFSPH]

S I d e 2 6	<p style="text-align: center;">Canine Granulocytic Ehrlichiosis</p> <ul style="list-style-type: none"> • Caused by: <ul style="list-style-type: none"> - <i>Anaplasma phagocytophilum</i> - <i>Ehrlichia ewingii</i> • Resembles monocytic ehrlichiosis • But, often includes polyarthritis 	<p>Canine granulocytic ehrlichiosis is caused by <i>Anaplasma phagocytophilum</i> and <i>Ehrlichia ewingii</i>. It resembles monocytic ehrlichiosis. Polyarthritis, which is uncommon in monocytic ehrlichiosis, is often seen in dogs with granulocytic ehrlichiosis. A chronic syndrome of moderate to severe anemia has also been reported.</p>
--------------------------------	--	--

S I d e 2 7	<p style="text-align: center;">Sennetsu Fever</p> <ul style="list-style-type: none"> • Caused by: <ul style="list-style-type: none"> - <i>Neorickettsia sennetsu</i> • Experimental infections <ul style="list-style-type: none"> - Dogs <ul style="list-style-type: none"> • Transient fever - Mice <ul style="list-style-type: none"> • Diarrhea, weakness, lymphadenopathy, death 	<p>Sennetsu fever is caused by <i>Neorickettsia sennetsu</i>. Dogs experimentally infected developed a transient fever, but no other clinical signs. The organism could be isolated from the blood. Diarrhea, weakness, lymphadenopathy and death have been reported in experimentally infected mice.</p>
--------------------------------	--	---

S I d e 2 8	<p style="text-align: center;">Equine Granulocytic Ehrlichiosis</p> <ul style="list-style-type: none"> • Caused by: <ul style="list-style-type: none"> - <i>Anaplasma phagocytophilum</i> • Wide spectrum of disease <ul style="list-style-type: none"> - Often begins as non-specific illness - Signs increase in severity - May include icterus, petechiation, reluctance to move, distal limb edema 	<p>Equine granulocytic ehrlichiosis is caused by <i>Anaplasma phagocytophilum</i>. Disease varies from a mild infection, with fever the only symptom, to severe disease. Typical symptoms, which increase in severity over several days, include fever, decreased appetite, ataxia, depression, icterus, petechiation, reluctance to move and distal limb edema. Transient ventricular arrhythmias can be seen on rare occasions, and concurrent infections may be exacerbated. The symptoms may be milder in young animals.</p>
--------------------------------	---	--

S
I
d
e
2
9

Tick-borne Fever

- Caused by:
 - *Anaplasma phagocytophilum*
- Affects domestic and wild ruminants
- Occurs in tick-infested areas
 - Newly introduced animals affected
- Clinical signs variable
 - Fever, abortion (sheep)
 - Reduced milk yield, respiratory (cattle)

Tick-borne fever is caused by *Anaplasma phagocytophilum*. It occurs in domestic and wild ruminants, particularly sheep and cattle. In sheep, disease is mainly seen in young lambs born in tick-infested areas and newly introduced older sheep. The primary symptom is a sudden fever that lasts for 4 to 10 days. Other signs are generally mild and may include weight loss, listlessness, coughing, and increased respiratory and pulse rates. Abortions can occur in pregnant ewes introduced onto infected pastures during the last stages of gestation; abortions are usually seen 2 to 8 days after the onset of the fever. Semen quality can be significantly reduced in rams. In cattle, tick-borne fever usually occurs in dairy animals recently turned out to pasture. The two most prominent syndromes are abortions with a drop in milk yield, and respiratory disease. Most ruminants recover within two weeks, but relapses can occur after splenectomy, other injuries or infectious diseases. Both sheep and cattle become more susceptible to concurrent infections, due to impaired immunity. Hemorrhagic syndromes have occasionally been reported. Infections can persist for up to two years after clinical recovery. Deaths are rare except in aborting ewes.

S
I
d
e
3
0

Ehrlichiosis in Other Species


- Cats
 - Documented cases rare
 - Under-reporting?
 - Cats less susceptible to disease?
 - Granulocytic form reported
- Non-human primates
 - Natural infections reported in lemurs
 - Experimental infection
 - Rhesus macaques

There is evidence that cats are susceptible to ehrlichiosis, but documented cases are rare. It is not known whether this disease is under-reported, cats are less susceptible to clinical disease, or cats simply remove ticks during self-grooming and thus are infected less often. Granulocytic ehrlichiosis was recently reported in a cat infected with *A. phagocytophilum* in Sweden. The symptoms included fever, anorexia, lethargy, dehydration and tachypnea. Possible ehrlichiosis has also been diagnosed in three cats with fever, anemia, anorexia and loss of condition. A naturally occurring outbreak of ehrlichiosis, caused by *E. chaffeensis*, was recently reported in captive ring-tailed and red ruffed lemurs. The symptoms included anorexia, fever, lethargy and lymphadenopathy. Rhesus macaques and baboons experimentally infected with *Anaplasma phagocytophilum* developed fever and anemia in one study, and fever, lethargy, anemia, thrombocytopenia and neutropenia in another. Severe disease was seen after experimental inoculation of rhesus macaques with *E. canis*.

S
I
d
e
3
1

Post Mortem Lesions

- Canine ehrlichiosis
 - Splenomegaly
 - Lymphadenopathy
 - Heavy, discolored lungs
 - Hemorrhages
- Equine granulocytic ehrlichiosis
 - Hemorrhages
 - Interstitial pneumonia



In the acute stage of canine ehrlichiosis, the gross lesions are usually nonspecific. Common findings include splenomegaly, lymphadenopathy and heavy, discolored lungs. Severe cases of canine monocytic ehrlichiosis may be characterized by emaciation, pale mucous membranes, splenomegaly, and hemorrhages throughout the gastrointestinal tract, heart, bladder, lungs, subcutaneous tissues and eyes. The lymph nodes, particularly the mesenteric nodes, may be enlarged, with red and brown discoloration on cut surface. There may be edema in the legs, as well as ascites and hydropericardium. The characteristic signs of equine granulocytic ehrlichiosis are petechiae, ecchymoses and edema in the subcutaneous tissues and fascia of the legs. Interstitial pneumonitis has been reported.

[Photo: There are multiple coalescing hemorrhages on the pleural surface of this dog's lungs; the right middle lobe is also edematous. Photo from Armed Forces Institute of Pathology/CFSPH]

S
I
d
e
3
2

Diagnosis	
• Serology	
- IFA	• Equine granulocytic ehrlichiosis
	• Canine ehrlichiosis, tick-borne fever
- ELISA	
• Blood smears	
• Hematologic abnormalities	- Thrombocytopenia
• Changes in serum chemistry	

Ehrlichiosis can be diagnosed by serology or detection of the organism. Diagnosis is complicated, particularly in dogs, by the possibility of co-infection with more than one organism, and by cross-reactions in serologic tests. The indirect immunofluorescent antibody (IFA) test is the most commonly used serologic test for equine granulocytic ehrlichiosis, canine ehrlichiosis and tick-borne fever. ELISA tests have also been developed for canine ehrlichiosis. Immunoblotting (Western blotting) is mainly used in research. A rising titer is diagnostic. In dogs, a single positive titer is also considered to be evidence of exposure. Antibodies may not be found in the terminal stages of canine ehrlichiosis if the bone marrow is exhausted. Ehrlichiosis can sometimes be confirmed by finding morulae in peripheral blood smears or impression smears from fresh tissues. Depending on the form of the disease, the morulae are mainly seen in monocytes or granulocytes. The organisms can be stained with Giemsa or by immunofluorescence. This technique is useful for equine granulocytic ehrlichiosis, but is relatively insensitive for the diagnosis of canine ehrlichiosis, as the organisms are found in only a minority of cases. Polymerase chain reaction (PCR) assays can detect antigens in the blood; these tests are useful for equine ehrlichiosis and may be available for canine ehrlichiosis. Culture is generally impractical, as *Ehrlichia* can be difficult to culture and also take 14 to 33 days to grow. Hematologic abnormalities and changes in serum chemistry can help support the diagnosis. Thrombocytopenia is the most common abnormality in dogs. Many dogs also have anemia and leukopenia, although it may be mild in the acute phase. A response to treatment also supports the diagnosis.

S
I
d
e
3
3

Treatment	
• Antibiotics	
- Tetracyclines	
- Chloramphenicol	
• Early treatment critical for dogs	
• Persistent infections may occur	
- <i>Ehrlichia canis</i>	
- <i>E. chaffeensis</i>	

Ehrlichiosis is usually treated with the tetracycline antibiotics. In dogs, chloramphenicol and other drugs are also used occasionally. In cases of equine granulocytic ehrlichiosis or tickborne fever, treatment is usually very effective. Early treatment is critical for canine ehrlichiosis; uncomplicated cases in the acute or subclinical stage usually respond promptly, but antibiotics may be less effective in dogs with neurologic signs, and treatment of the chronic severe form is difficult. One report described the successful treatment of a dog with severe chronic canine monocytic ehrlichiosis, using a combination of hematopoietic growth factors, low dose vincristine, doxycycline and glucocorticoids. There is little information on post-treatment follow-up of dogs. Some authors suggest that persistent infections are common, particularly in dogs infected with *E. canis* or *E. chaffeensis*. Others note that recent studies suggest many infected dogs clear *E. canis* infections after treatment. Hematologic values remain abnormal in some dogs for several months, despite clinical improvement. It is uncertain whether persistent post-treatment antibody titers and/or PCR amplicons correlates with a persistent infection.

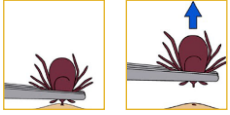
S
I
d
e
3
4

PREVENTION AND CONTROL

S
I
d
e
3
5

Prevention and Control

- Prevent tick bites
 - Wear protective footwear, clothing
 - Use insect repellents
 - Remove ticks as soon as possible



The risk of infection can be decreased by preventing tick bites. Protective footwear, clothing and insect repellents should be used in tick habitats. Ticks may be more visible on light-colored clothing. People who enter tick habitats should check frequently for ticks and remove them as soon as possible, using fine-tipped tweezers or gloved hands. Bare hands should not be used to remove ticks, due to the risk of exposure to the tick’s fluids or feces; various tick-transmitted disease organisms can enter the body through cuts in the skin or mucous membranes. If gloves are not available, the fingers should be shielded with a tissue or paper towel. The tick should not be squeezed, crushed or punctured. The CDC warns that tick removal techniques such as the use of hot matches or petroleum jelly may stimulate the tick to release additional saliva and increase the risk of infection. Tick bites should be thoroughly disinfected after removal of the tick, and the hands should be washed with soap and water. The tick can be frozen in a plastic bag, for identification in case of illness. Ticks should also be removed from pets, both to prevent dogs from becoming ill and to prevent ticks from entering the home. Acaricides, biological controls and control of tick habitats can decrease the populations of tick vectors in a community. There is no vaccine for ehrlichiosis.

[Images: Proper tick removal. Source: Centers for Disease Control and Prevention]

S
I
d
e
3
6

Prevention and Control

- Control tick vectors
 - Remove ticks from pets
 - Acaricides
 - Pets, livestock, environment
- Manage tick habitats
- No vaccine available
 - Canine ehrlichiosis
 - Equine granulocytic ehrlichiosis
 - Tick-borne fever

Ehrlichiosis can be prevented by controlling the tick vectors. Pets should be inspected frequently for ticks, which should be removed promptly with fine-tipped tweezers or gloved hands. Acaricides can be used on companion animals and livestock, and may be used to treat barns and kennels. Biological controls and the control of tick habitats can also decrease tick populations. Tick-borne fever in ruminants can be prevented by grazing animals on relatively tick-free pastures. Ewes and lambs should be kept in tick-free pastures until the lamb is approximately 6 weeks old. Acaricides may be used before the lambs are moved to hill pastures. No vaccines are available for canine ehrlichiosis, equine granulocytic ehrlichiosis or tick-borne fever. Prophylactic treatment with antibiotics is sometimes used to prevent tickborne fever in ruminants.

S
I
j
d
e

3
7

Additional Resources

- Center for Food Security and Public Health
– www.cfsph.iastate.edu
- CDC: Ehrlichiosis
– <http://www.cdc.gov/ehrlichiosis/>

S
I
j
d
e

3
8

Acknowledgments

Development of this presentation was made possible through grants provided to the Center for Food Security and Public Health at Iowa State University, College of Veterinary Medicine from the Centers for Disease Control and Prevention, the U.S. Department of Agriculture, the Iowa Homeland Security and Emergency Management Division, and the Multi-State Partnership for Security in Agriculture.

Authors: Kerry Leedom Larson, DVM, MPH, PhD, DACVPM; Anna Rovid Spickler, DVM, PhD
Reviewers: Glenda Dvorak, DVM, MPH, DACVPM

Last reviewed: January 2013