



Venomous Fishes – They Sting!!!

Inside this issue:

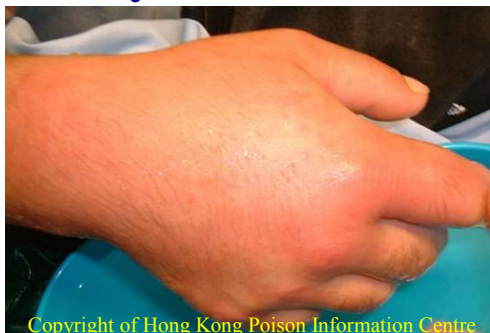Introduction	1
Common Venomous Fishes in Hong Kong	2
Epidemiology of Fish Sting Injuries in Hong Kong - July 2005 to June 2007	3
A Case of Lionfish (<i>Pterois volitans</i>) Sting	4
Clinical Features of Fish Sting Envenomation	4
Management of Fish Sting Envenomation—Toxicology, Investigation and Treatment	5
Advice to The Public and Patients - Dos and Don'ts for Prevention of Venomous Fish Sting	6
References	6

Introduction

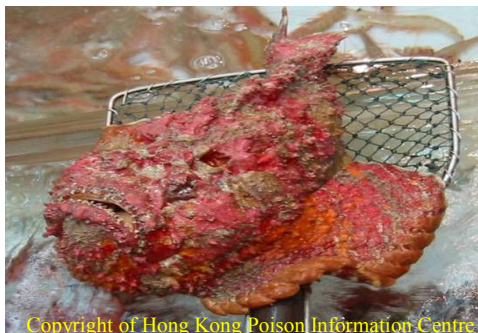In Hong Kong, there are ample opportunities to encounter a wide variety of marine fish. While some are delicious foods for gourmets, others are attractive sea creatures with recreational value. Increasingly, diving with the aim to appreciate the beauty of the underwater is becoming a popular pastime.

However, examining the scene from a public health angle, there is no lack of chances of exposure to health hazards posed by marine fish. Indeed, fish sting cases – whether occupational or recreational are not rare. Fortunately, most of the incidents were trivial and required no medical attention. However, for fish stings in which poisons are involved, serious and sometimes fatal outcomes may occur if they are not being managed properly.

This article reports on cases of venomous fish stings encountered in accident and emergency departments (AED) of some of the major hospitals in Hong Kong. The characteristics of venomous fishes and clinical features of corresponding fish stings are described. Management procedures for patients suffering from venomous fish sting are reviewed. Advice to the public and patients on the prevention of venomous fish sting are presented towards the end.



Copyright of Hong Kong Poison Information Centre



Copyright of Hong Kong Poison Information Centre

Editorial Team

Dr Gloria TAM, Dr Henry NG, Dr Chris CHAU, Prof. Thomas CHAN, Dr Albert CHAN, Dr Tony MAK, Dr FL LAU, Dr ML TSE, Ms Teresa NGAN, Mr Ivan WONG

This publication is produced by the Hong Kong Poison Control Network

C/O: Toxicovigilance Section, Surveillance and Epidemiological Branch, Centre for Health Protection, Department of Health, 18/F Wu Chung House, 213 Queen's Road East, Wan Chai, Hong Kong SAR



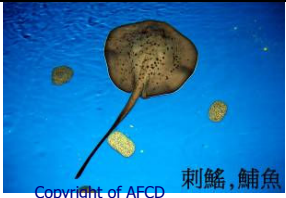
For enquiries on Poisoning.Comm, please send your e-mail to pharm_toxi@dh.gov.hk




ALL RIGHTS RESERVED

Common Venomous Fishes In Hong Kong

Courtesy of Agriculture, Fisheries and Conservation Department (AFCD), HK SAR

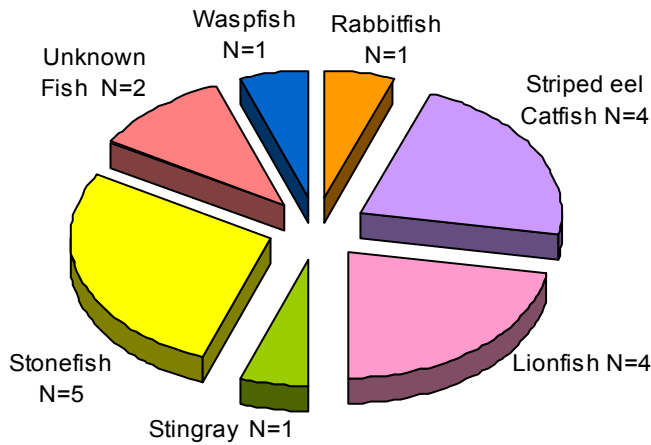
According to the AFCD, there are different types of fish associated with venomous stings. The habitats and mechanisms of envenomation of those commonly encountered in HK's major public AEDs are summarized in the following tables-

Type	Lionfish (獅子魚)	Rabbitfish (泥鯔)	Stingray (刺鯊, 魷魚)
Scientific name	<i>Pterois volitans</i>	<i>Siganus canaliculatus</i>	<i>Taeniura meyeni</i>
Appearance	 Copyright of AFCD 獅子魚	 Copyright of AFCD 泥鯔	 Copyright of AFCD 刺鯊, 魷魚
Habitat	<ul style="list-style-type: none"> coral reef 	<ul style="list-style-type: none"> around rocks in coastal waters some are schooling some live among coral 	<ul style="list-style-type: none"> about 15 species commonly found in Hong Kong water mostly in Sai Kung reef-associated
Setting in which fish sting occurred	<ul style="list-style-type: none"> at home while cleansing aquarium 	<ul style="list-style-type: none"> at home while preparing food 	<ul style="list-style-type: none"> during fishing
Mechanism of Envenomation	<ul style="list-style-type: none"> venom is released from the dorsal spine when the integumentary sheath is ruptured 	<ul style="list-style-type: none"> venom is released from the glands of the spines 	<ul style="list-style-type: none"> venom is released from the tip of the tail spine and barbs which pierce the integumentary sheath and lacerate the skin of a victim

Type	Stonefish (石頭魚)	Striped eel catfish (坑鯪)	Waspfish (老虎魚)
Scientific name	<i>Synanceia verrucosa</i>	<i>Plotosus lineatus</i>	<i>Hypodytes rubripinnis</i>
Appearance	 Copyright of AFCD 石頭魚	 Copyright of AFCD 鰻鯪, 坑鯪	 Copyright of AFCD 老虎魚
Habitat	<ul style="list-style-type: none"> coral reef, muddy or sandy areas reef-associated non-migratory 	<ul style="list-style-type: none"> marine or estuarine habitat reef-associated 	<ul style="list-style-type: none"> shallow waters shallow rocky reefs
Setting in which fish sting occurred	<ul style="list-style-type: none"> at work 	<ul style="list-style-type: none"> during fishing at home while preparing food 	<ul style="list-style-type: none"> during fishing
Mechanism of Envenomation	<ul style="list-style-type: none"> a stream of venom will enter into the victim's tissues from the spine 	<ul style="list-style-type: none"> venom is released from the highly venomous serrate spine of the first dorsal and each of the pectoral fins. Envenomation can be fatal in rare cases 	<ul style="list-style-type: none"> venom is released from the dorsal spine

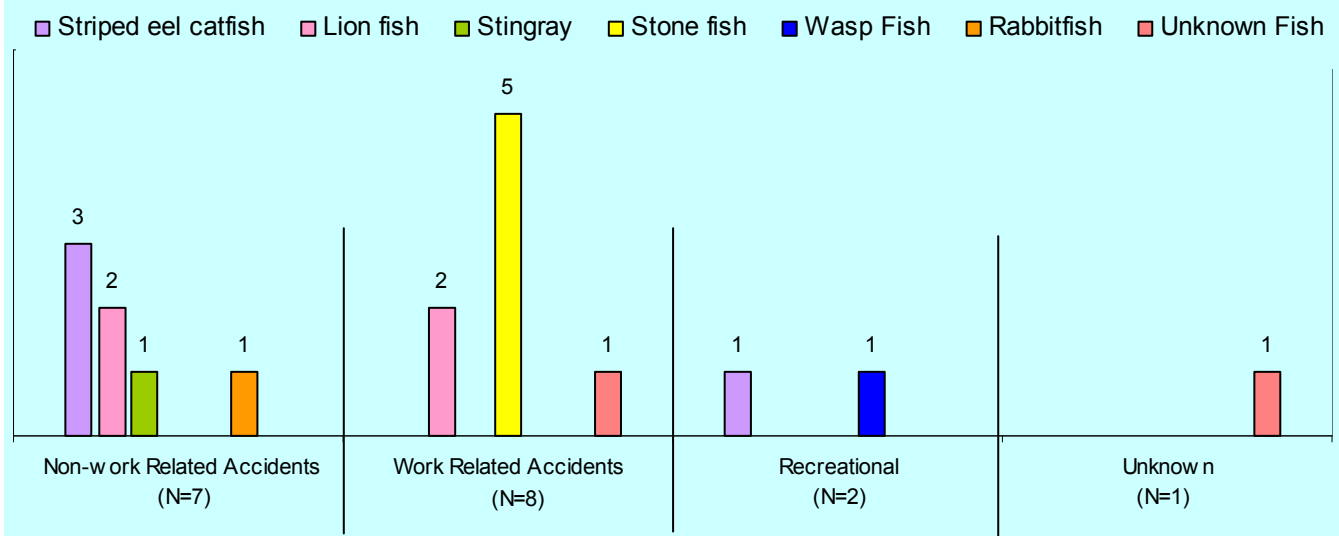
Epidemiology of Fish Sting Injuries in Hong Kong from July 2005 to June 2007

Types of Fish Causing Venomous Sting Injuries (N=18)



Records of AED of six regional hospitals, namely Pamela Youde Nethersole Eastern, Prince of Wales, Princess Margaret, Queen Mary, Tuen Mun and United Christian showed that between July 2006 to June 2007, there were 18 patients reported to have suffered from venomous fish sting. Thirteen were males while 5 were females and their age ranged from 20 years to 69 years (median = 41.5 years). Most cases were caused by **stonefish (n=5)**, followed by **striped eel catfish (n=4)** & **lionfish (n=4)**. Fourteen of the collection of cases were treated in AED and discharged, while the remaining four cases required hospital care. All cases made recovery uneventfully.

Type of Fish and Corresponding Activities (N=18)



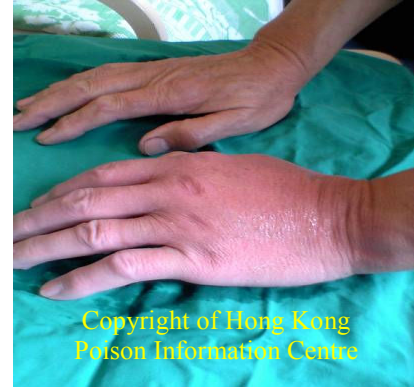Nearly half (44%) of the cases had fish sting whilst at work. This was followed by domestic injuries and those resulting from recreational activities. For non-work related cases, most of them occurred at home and were stung by **striped eel catfish (n=3)** and **lionfish (n=2)**. Two cases were hurt by venomous fish during attending recreational sea activities. Most of the work-related cases were stung by **stonefish (n=5)**.

A Case of Lionfish (*Pterois volitans*) Sting

Dr. M.L. Tse¹ and Prof. Thomas Y.K. Chan²

¹Hong Kong Poison Information Centre and ²Prince of Wales Hospital Poison Treatment Centre

A 62-year-old man presented to the A&ED 30 minutes after being stung on the dorsum of his hand by a lionfish (*Pterois volitans*) while cleaning his aquarium. Pain and local paraesthesiae developed, followed by erythema and swelling of the wounds. On examination at the hospital, his blood pressure was 175/107 mmHg and pulse rate 71 beats/minute. He was afebrile. Two tiny, puncture wounds were seen over his left hand, with surrounding erythema and oedema. No broken spines were present in the wounds. The patient's left hand was immersed in hot water (43-45°C) for 60 minutes till there was improvement in pain relief. He was given antitetanus and antibiotics prophylaxis. X-ray of the left hand was normal. He was discharged five hours after there was improvement in wound pain. The man was reviewed in the Clinical Toxicology Clinic six days later. The patient was then pain-free and the wounds were healing well.



Clinical Features of Fish Sting Envenomation

Fish venoms mostly act directly on muscular tissues although they may have occasional effects on the nervous or coagulation systems. The clinical presentations of some of the common venomous fish stings are summarized in the following table -

	Local symptoms	Systemic toxicity
Lionfish (獅子魚)	<ul style="list-style-type: none"> immediate sharp burning pain and swelling 	<ul style="list-style-type: none"> rare
Rabbitfish (泥鯔)	<ul style="list-style-type: none"> intense pain locally no swelling or redness foreign body and infection is the main concern 	<ul style="list-style-type: none"> not reported
Stingray (刺鯊, 魷魚)	<ul style="list-style-type: none"> deep wounds and lacerations bluish or grayish discoloration around the wound disproportional pain wound may become inflamed and necrotic 	<ul style="list-style-type: none"> muscle cramp, weakness, seizure, hypotension, cardiovascular collapse death reported after deep thoracic injury
Stonefish (石頭魚)	<ul style="list-style-type: none"> extreme pain which increases over hours local bruising and regional lymphadenopathy 	<ul style="list-style-type: none"> nausea, vomiting, syncope, diaphoresis, hypotension cardiac arrhythmia pulmonary oedema and death in severe cases
Striped eel catfish (坑鯪)	<ul style="list-style-type: none"> severe local pain numbness which spreads proximally as it intensifies swelling and redness may be minimal 	<ul style="list-style-type: none"> not reported
Waspfish (老虎魚)	<ul style="list-style-type: none"> severe pain that increases over hours swelling and erythema 	<ul style="list-style-type: none"> rare

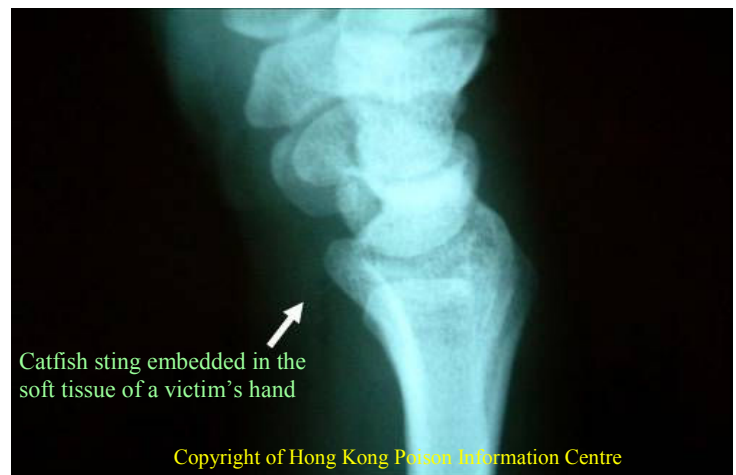Management of Fish Sting Envenomation

Toxicology

Fish venoms are usually mixtures of high molecular weight proteins and low molecular weight amines. The former can cause systemic toxic reactions while the latter can mount inflammatory reactions. The components which are responsible for pain and poisoning of the sting tend to be large, unstable proteins that are rapidly destroyed by heating. Therefore, **the primary treatment of poisonous fish sting ought to be by immersing injured body parts in water as hot as patients can bear for some 30-90 minutes.** Fish venoms usually act directly on muscle tissue and have little, if any, effect on the nervous system or on the coagulation profile.

Investigations

- X-rays of the injured body part(s) for all fish stings. Ultrasound and even MRI may be indicated
- complete blood picture, ECG and chest X- ray for stingray thoracic injury
- culture of wounds, with special request for marine micro-organisms for infected wounds



Treatment

- ✓ **hot immersion of injured parts - as hot as patients can bear, for between 30-90 minutes**
- ✓ **thorough wound cleansing and foreign body removal**
- ✓ **tetanus prophylaxis**
- ✓ **analgesic**
- ✓ prophylactic antibiotics may be considered, especially with coverage of *vibrios* species
- ✓ stonefish anti-venom comes in 2000 units / vial. Recommended dosage is as follows -

1-2 punctures	1 vial	2000 units
3-4 punctures	2 vials	4000 units
5 or more punctures	3 vials	6000 units

The dosage is the same for adults or children.

Beware of anaphylactic reactions like urticaria, bronchospasm and shock. Also watch out for delayed serum sickness if large volume of antivenom used.

- ✓ prolonged infection may need surgical intervention and culture for atypical infective organisms.

Advice to The Public and Patients on Prevention of Venomous Fish Sting

Dos

- * be aware of the venomous and dangerous fish.
- * always wear thick-soled shoes or heavy-duty boots for wading in seashores or intertidal reefs. Sometimes, fish spines can penetrate thin shoes.
- * wear proper gloves when handling venomous fish.
- * be alert and pay attention to the surroundings during swimming, snorkelling and diving
- * **seek immediate medical care if stung by venomous fish**

Don'ts

- * never reach for a submerged rocks with bare hands or feet
- * do not search by bare hand into hidden crevices
- * do not touch any un-familiar fish, especially if it -
 - * is brightly-coloured; or
 - * has sharp or pointed spine; or
 - * has sharp teeth
- * avoid carrying out activities in turbid waters

References

1. Ajmal N., Nanney L.B., Wolfort S.E., Catfish Spine Envenomation: A Case of Delayed Presentation. *Wilderness and Environmental Medicine*, 2003 (14): 101-105
2. Atkinsin P.R.T., Boyle A., Hartin D., McAuley D., Is hot water immersion an effective treatment for marine envenomation?. *Emerg Med J*, 2006 (23): 503-508
3. Fenner P., Marine envenomation: An update – A presentation on the current status of marine envenomation first aid and medical treatments. *Emergency Medicine*, 2000 (12): 295-302.
4. Kizer K.W., McKinney H.E., Auerbach P.S., Scorpaenidae Envenomation – A Five-Year Poison Center Experience. *JAMA*, 1985 253(6): 807-810.
5. Shepherd S., Thomas S.H., Keith C., Case Report – Catfish envenomation. *Journal of Wilderness Medicine*, 1994 (5): 67-70
6. Utah Poison Control Center, Marine Envenomations. *Utox Update*, 2000 3(2) :1-4
7. Vetrano SJ, Lebowitz JB, Marcus S., Lionfish Envenomation. *The Journal of Emergency Medicine*, 2002 23(4): 379-382

Acknowledgement

The editorial team would like to thank Dr WW CHENG, Fisheries Officer (Aquaculture Management) of AFCD who has provided expertise advice on fish classification, as well as related photos .