

Surgical corrections of long ureteral defects (initial experience)

Zhaksylyk Doskaliyev¹, Talgat Kurmanov², Ulanbek Zhanbyrbekuly³, Adilbek Mukazhanov¹, Dauren Mustafinov², Aigerim Bekenova⁴

¹Department of Surgery, National Research Oncology Center, Nur-Sultan, Kazakhstan

²Department of Urology, National Research Oncology Center, Nur-Sultan, Kazakhstan

³Department of Urology and Andrology, Astana Medical University, Nur-Sultan, Kazakhstan

⁴Department of General Surgery, School of Medicine, Nazarbayev University, Nur-Sultan, Kazakhstan

Received: 2022-04-07.

Accepted: 2022-08-09



This work is licensed under a
Creative Commons Attribution 4.0
International License

J Clin Med Kaz 2022; 19(4):64-68

Corresponding author:

Aigerim Bekenova.

E-mail: abekenova@nu.edu.kz

Abstract

Introduction: Restoration of patency of ureters with long defects is one of the major problems in urology. There are cases when it is impossible to perform plastic surgery of ureter with own tissues or bladder; in these situations, appendicoureteroplasty or kidney autotransplantation can be promising solutions.

Material and methods: 4 patients underwent surgical corrections of ureter strictures: two underwent appendicoureteroplasty and two – kidney autotransplantation. To verify the diagnosis of long ureteral defects, standard research methods were used: ante- and retrograde pyeloureterography.

Results and discussion: In the early postoperative period, all patients underwent dynamic ultrasonography of the abdominal cavity and retroperitoneal space; in addition, hemodynamics parameters as well as clinical and biochemical laboratory blood parameters were monitored. The early postoperative period in three patients proceeded with no incidents and did not require serious additional studies. In one patient after appendicoureteroplasty dynamic intestinal obstruction developed on the third day post-op, which was resolved conservatively. In the late postoperative period the condition of the patients was satisfactory. There are few articles describing surgical interventions that can treat long ureteral defects, with appendiculoplasty and kidney autotransplantation being the most effective. However, each procedure has own advantages and disadvantages, as well as risks.

Conclusion: In our study, we performed these two methods with two patients for each method. Results are promising, but for a better statistical analysis and more thorough follow-up we need more patients for both appendiculoplasty and kidney autotransplantation.

Key words: ureter stricture, appendix, cecum, urodynamics, autotransplantation, kidney transplantation

Introduction

Restoration of ureteral patency in patients with long defects is one of the most difficult problems of modern urology [1,2]. According to literature, the causes of ureteral stricture include: ischemia, trauma, inflammatory diseases (including tuberculosis), periureteral fibrosis, endometriosis, prolonged exposure to a foreign body (calculus, stent, etc.), congenital developmental anomalies. More than 80% of cases of stricture are formed because of iatrogenic damage to the ureter, including burns after radiation therapy [3].

In recent years, the growth of post-radiation

strictures and iatrogenic injuries of the ureters during surgical interventions on pelvis and abdominal cavity organs can be noted. In cases of impossibility of plastic surgery of the ureter with the help of own tissues or the bladder, the use of the small intestine, appendix or large intestine is the most promising. These organs have a good mucous layer and a similar structure of the muscular and serous layers of the wall, and are also functionally capable of passage due to contractile activity [4,5]. Ureteroplasty by the appendix is still a rarely performed operation. No more than a few dozen cases of using the appendix to replace long ureteral

strictures have been described in the world literature [6,7]. The development of living donor kidney transplantation has opened the possibility of kidney autotransplantation (AT), especially in patients with extended ureteral stricture with preserved kidney function. According to the literature, autotransplantation is defined as a highly effective surgical intervention for preserving an organ in various kidney pathologies [8]. Until 2013, 7 kidney autotransplantations were performed in Kazakhstan [9].

All of the above indicates that with extended defects of the ureter, there is a difficulty in resolving the issue of its surgical treatment. The main goal here is to preserve the kidney with an adequate passage of urine. The search for various solutions to this issue determines the relevance of the problem.

Aim of study: To analyze the results of the first various variants of surgical correction of long ureteral defects using the appendix and kidney autotransplantation.

Materials and methods

The results of surgical treatments performed on 4 patients for long ureteral defects were analyzed. In two cases, the appendix was used as a plastic material. In one patient, surgery of the right ureter was performed, and in the other - the left one. In two cases, patients underwent autotransplantation of the left kidneys to the right iliac vessels with the imposition of an antireflux anastomosis with the bladder.

Indications for surgery in all cases were extended strictures of the ureters, with a disturbance of the urine passage and the development of hydronephrosis. In order to resolve hydronephrosis all patients underwent percutaneous nephrostomy under ultrasound guidance. Other options of surgical treatment were not applicable in these cases, because all strictures were prolonged.

To verify the diagnosis of long ureteral defects, standard research methods were used. The main ones were ante- and retrograde pyeloureterography. To visualize kidney vessels to decide the issue of autotransplantation, computed tomography was performed in a two-vessel angio mode. Along with this, the function of the kidney and the content of pathological impurities in the urine were studied.

Figure 1 - Antegrade urography: long right ureteral stricture

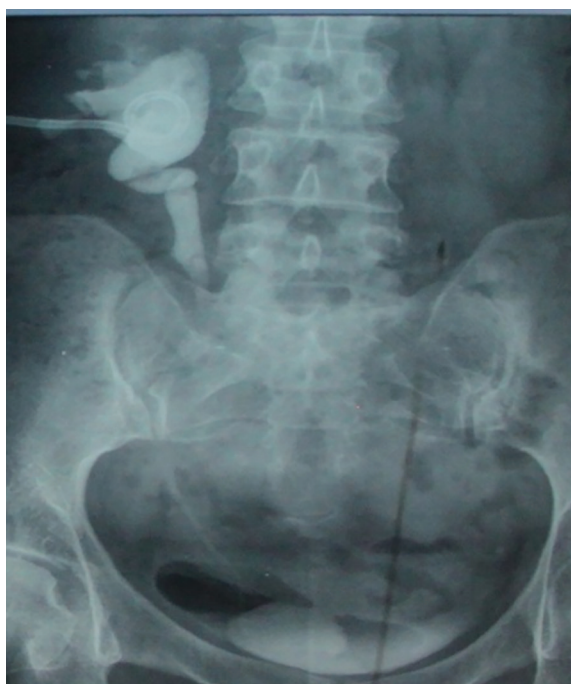

Figure 2 - CT with 3D modeling: inferior to middle-third ureter cannot be identified

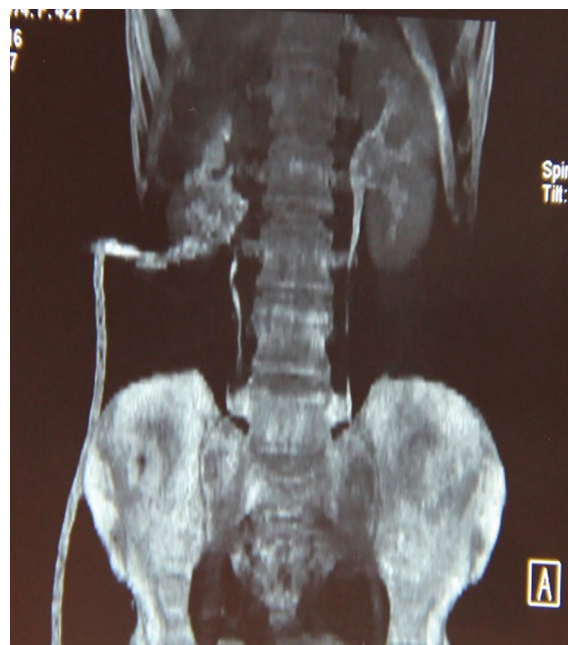
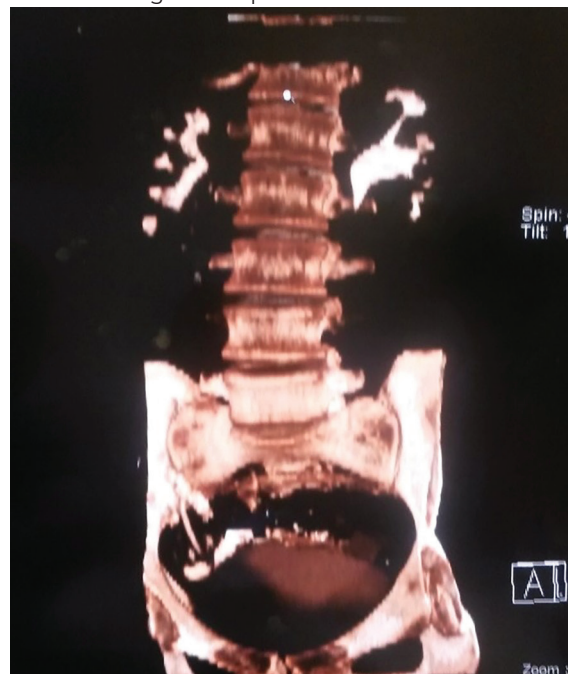
Figure 3 - CT 4 months after appendicoureteroplasty. Normalization of right renal pelvis size. Anastomosis is functional



Surgical interventions

Appendicoureteroplasty

Both patients underwent mid-lower laparotomy for appendicoureteroplasty. In the first case, the right ureter was identified by dissection of the parietal peritoneum from the right side and mobilization of the cecum and ascending colon. The ureter was isolated with technical difficulties to the ureterovesical junction. On assessing the patency of the ureter, the length of the stricture (complete obliteration) was 11 centimeters. When assessing the appendix, the latter was macroscopically without signs of inflammation, the length was 13 and the width was 1 cm. The mesentery of the appendix was mobile with diaphanoscopy, the vessels of the main type, the pulsation of the appendicular artery without pathologic features. Taken into consideration a good condition and blood supply of appendix, it was decided to perform appendicoureteroplasty. The stenotic part of the ureter

Figure 4 - CT 4 months after appendicoureteroplasty. Normalization of right renal pelvis size. Anastomosis is functional

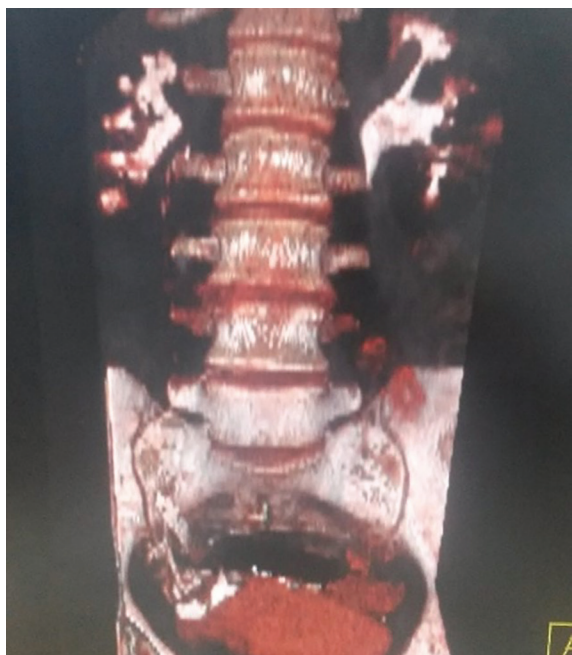

Figure 6 - Antegrade pyeloureterography: long left ureteral defect

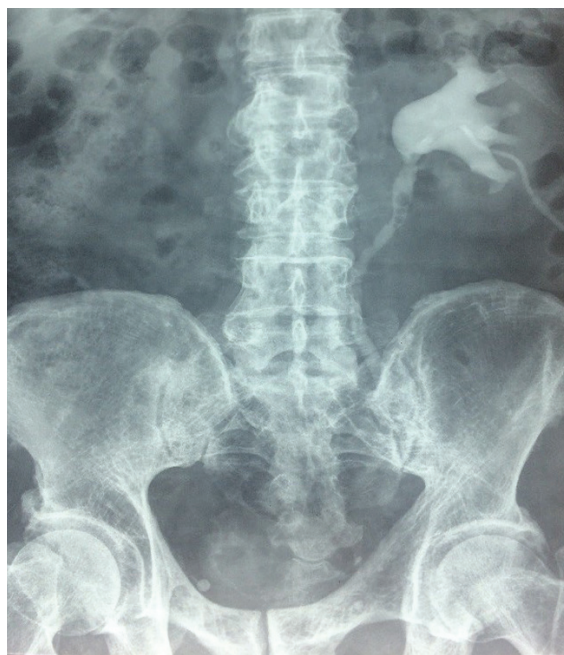

Figure 5 - Urography

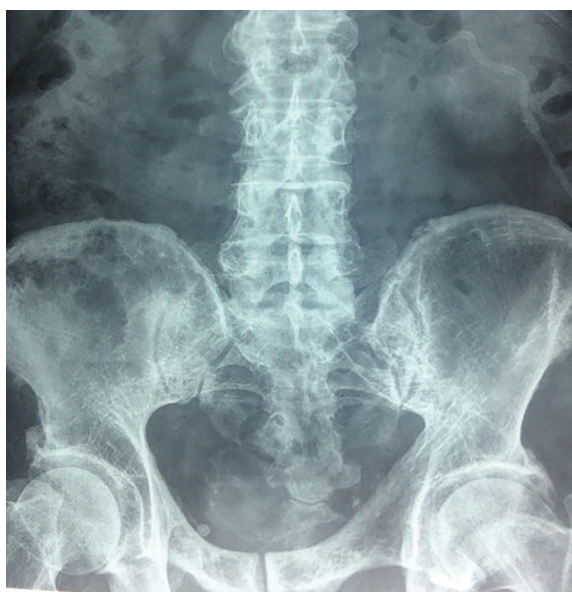
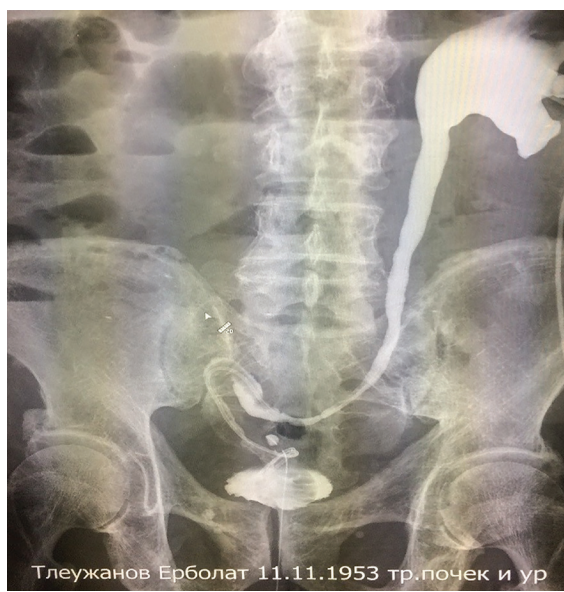
Figure 7 - Antegrade left pyeloureterography



was resected, with suturing of the distal end. Appendectomy was performed with double-row sutures on the wall of the cecum. Further, a cannula with a syringe was placed on the proximal end of the appendix, and the tip of the appendix was cut obliquely at an angle of 45 degrees. Sparing hemostasis with bipolar coagulator was performed. Then the lumen of the appendix was washed with dioxidine solution. When the appendix was replaced into the retroperitoneal space and an attempt was made to install it to replace the ureteral defect, tension was found in the mesentery and its vessels. To resolve this issue, the appendix was located anti-peristaltically, and ischemia of the organ was not observed. Appendicoureteroplasty was performed. Anastomoses were formed with interrupted sutures with the ureteral stent. The tip of the stent was inserted into the bladder. The abdominal cavity and retroperitoneal space were drained with elastic silicone drains. The wound healed by primary closure, the nephrostomy was removed on the 12th day after ultrasound control, the stent catheter was removed from the bladder on the 22nd day.

The second patient had a long ureteral defect on the left side. The technical peculiarity of the surgery was that during the revision of the abdominal organs, a medial dystopia of the caecum was found, and the vessels of the appendix derived from the branches of the lower mesenteric artery. It let us perform appendicoureteroplasty in the isoperistaltic position. Due to anatomic variation of appendix it was decided to perform appendicoureteroplasty instead of ileoureteroplasty. The ureteral defect was 9 centimeters. The appendix was 11 long and 1.1 cm wide. The distal part was anastomosed with the proximal end of the ureter on the stent, and an anastomosis between the fundus of the bladder and the base of the appendix was formed with the stent immersed in bladder cavity. After 7 days, antegrade pyeloureterography was performed (Figure 7). The stent catheter was removed on an outpatient basis on the 24th day, and the nephrostomy was removed on the 28th day.

Kidney autotransplantation

Both patients for kidney autotransplantation had long defects of left ureters. Both patients had a history of multiple surgical interventions to treat ureteral strictures, all of them were unsuccessful. That is why it was decided to perform kidney transplantation as a last resort of treatment. Pararectal incision on the left was performed in both cases with laparotomy. The parietal peritoneum along the ascending colon was dissected and the ureter was identified in the retroperitoneal space, taken on a tourniquet. With technical difficulties, it was ligated up to the wall of the bladder and transected. Both patients had nephrostomies placed before surgery, which were removed during the intervention. Next, a standard sparing nephrectomy with separate ligation of the vessels was performed. Short-term conservation of the kidney was carried out extraorganically with Custadiol solution at a temperature of + 4 degrees of Celsius until the blood cells were completely washed out (Figure 9A).

Figure 8 - Antegrade left pyelography

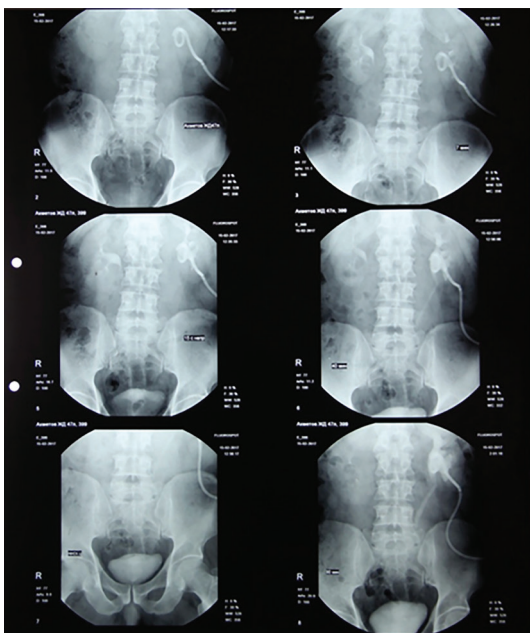
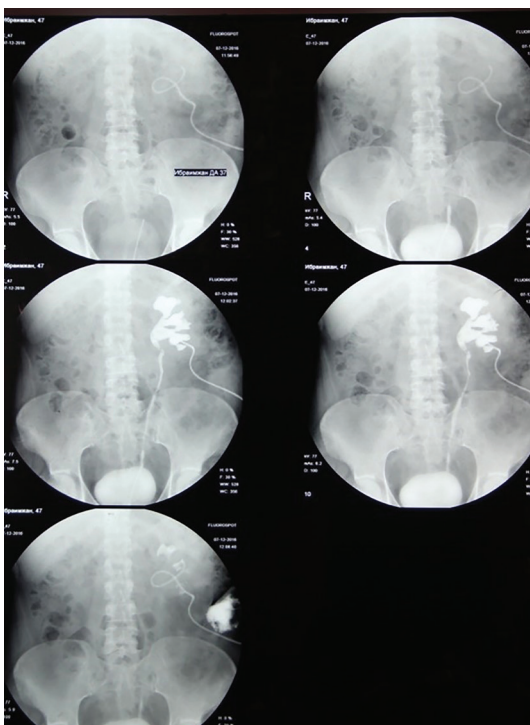


Figure 9 - Antegrade left pyelography



Heparin solution diluted to 1:100 ml of saline solution was used as a direct anticoagulant. After conservation, condition of the ureter was assessed and resected within the healthy part: 8 cm in the first case and 11 in the second. This data correlated with preoperative findings of ante- and retrograde pyeloureterography (Figure 8 A and 8 B). After that, the kidney was transplanted with vascularization from the external iliac vessels on the right (Figure 9B). The kidney was launched into the bloodstream by standard method. In both cases, the renal blood flow was adequate, urine appeared after 5-8 minutes. After that, a stent catheter was placed up to the pelvis of kidney, and the distal end was placed into the bladder cavity through a separate incision, and an antireflux ureterocystoanastomosis formed on it. The operation was completed by draining of retroperitoneal space with two elastic silicone drains and tight suturing the abdominal cavity.

Figure 10 - Extracorporeal preparation of kidney

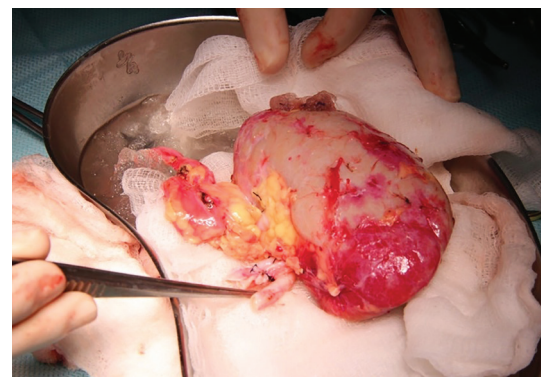
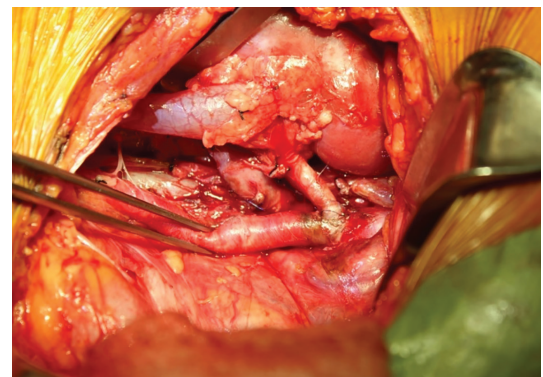

Figure 11 - Arterial and venous anastomosis formation



Results and discussion

In the early postoperative period, all patients underwent dynamic ultrasonography of the abdominal cavity and retroperitoneal space; in addition, hemodynamics parameters as well as clinical and biochemical laboratory blood parameters were monitored. Considering the specifics of the intervention, condition of the urine: gross hematuria, microhematuria, specific gravity, quantity (polyuria after kidney autotransplantation), bacterioscopy and microscopy – was of great importance.

The results of the surgical interventions performed were studied in the long-term period from 4.5 to 5 years. In addition to the general condition of patients using laboratory and instrumental methods of follow up, the condition and function of the kidneys as well as the passage of urine in patients after appendicoureteroplasty were studied.

The early postoperative period in three patients proceeded with no incidents and did not require serious additional studies. Only in one patient after appendicoureteroplasty dynamic

intestinal obstruction developed on the third day post-op, which was resolved conservatively.

In the late postoperative period, during the first two years patients underwent dynamic monitoring of the urinary functions of operated organs every 6 months and annually in subsequent years. The condition of the patients was satisfactory. Kidney function and urine passage through the newly formed ureters were without features.

The problem of ureteroplasty remains controversial nowadays due to different treatment options with no clear recommendation regarding this issue. There are few articles describing surgical interventions that can treat long ureteral defects, with appendiculoplasty and kidney autotransplantation being the most effective. However, each procedure has own advantages and disadvantages, as well as risks. For example, for appendiculoplasty the appendix should reach a ureteral defect without tension of mesentery, which is not always the case. In this situation, kidney autotransplantation can be a solution since it does not require immune suppression. The disadvantage of this method is that it requires two large incisions, and there is a risk of anastomotic leakages from vessels.

In our study, we performed these two methods with two patients for each method. Results are promising, but for a better statistical analysis and more thorough follow-up we need more patients for both appendiculoplasty and kidney autotransplantation.

References

1. Chung BI, Hamawy KJ, Zinman LN, Eibertino JA. The use of bowel for ureteral replacement for complex ureteral reconstruction: long-term result. *J Urol.* 2006; 175(1):179-183. [https://doi.org/10.1016/S0022-5347\(05\)00061-3](https://doi.org/10.1016/S0022-5347(05)00061-3)
2. Spirin BA, Mitryayev VA, Ponukalin AN. Iatrogenic trauma of ureters [in Russian]. *X Rossijskij s'ezd urologov.* 2002; 612-613.
3. Elliott SP, McAninch JW. Ureteral injuries: external and iatrogenic. *Urologic Clinics of North America.* 2006; 33(1):55-66. <https://doi.org/10.1016/j.ucl.2005.11.005>
4. Novikov AI. Restoration of the urinary tract by various parts of the gastrointestinal tract [in Russian]. 2006; 37.
5. Komyakov BK, Guliyev BG, Dorofeyev SY, Burlaka OO. A new way to replace the ureter with a appendix [in Russian]. *Trudy gorodskoj mnogoprofil'noj bol'nicy №2.* 2006;137-143.
6. De Geeter P, Jost N, Persson-Junemann Ch, Melchior H. Appendix interposition for repair of the right ureter: report- of 2 cases. *Eur. Urol.* 2000; 37(2):54.
7. Pettersson S, Brynger H, Henriksson C, Johansson SL, Nilson AE, Ranch T. Treatment of urothelial tumors of the upper urinary tract by nephroureterectomy, renal autotransplantation, and pyelocystostomy. *Cancer.* 1984; 54(3):379-386. [https://doi.org/10.1002/1097-0142\(19840801\)54:3<379::AID-CNCR2820540302>3.0.CO;2-U](https://doi.org/10.1002/1097-0142(19840801)54:3<379::AID-CNCR2820540302>3.0.CO;2-U)
8. Djakovich N, Plas E, Martinez-Pineiro L, Lynch T, Mor Y, Santucci RA, Serafetinidis E, Turkeri LN, Hohenfellner M. Traumatic injuries of the urinary system organs [in Russian]. *Vestnik evropejskoj asociacii urologov.* 2011; 35-36.
9. Trinchieri A, Montanari E, Salvini P, Berardinelli L, Pisani E. Renal autotransplantation for complete ureteral avulsion following lumbar disk surgery. *The Journal of urology.* 2011; 165(4):1210-1211. [https://doi.org/10.1016/S0022-5347\(05\)66480-4](https://doi.org/10.1016/S0022-5347(05)66480-4)

Conclusion

Our first results on the correction of long ureteral defects using the formation of appendicoureteroplasty may be the method of choice for this pathology. The use of the appendix on its mesentery makes it possible to replace both part of the right and pelvic sections of the left ureter and effectively restore the urodynamics of the urinary tract. The advantage of this intervention is that the risk of stricture in the area of appendicocystoanastomosis is lower due to the formation of a wide anastomosis.

Kidney autotransplantation in case of extensive strictures of the ureter requires good practical training of the surgeon and assistants, as well as inclusion in the transplant team. The advantage of this operation is that a direct antireflux ureterocystoanastomosis is applied [7]. Therefore, this intervention is a good alternative to known methods like ureterocystoanastomosis according to Boari or Psoas hitch [7].

Disclosures: There is no conflict of interest for all authors.

Acknowledgements: None.

Funding: None.