



Contents lists available at ScienceDirect

## AACE Clinical Case Reports

journal homepage: [www.aaceclinicalcasereports.com](http://www.aaceclinicalcasereports.com)

## Case Report

## Vanishing Bone Disease of the Thoracic Cage: Challenges in the Management of a Rare Entity

Kripa Elizabeth Cherian, MD, DM, DNB, Nitin Kapoor, MD, DM, PhD,  
Thomas V. Paul, MD, DNB, PhD\*

Department of Endocrinology, Diabetes and Metabolism, Christian Medical College and Hospital, Vellore, Tamil Nadu, India

## ARTICLE INFO

## Article history:

Received 13 April 2021

Received in revised form

22 August 2021

Accepted 10 September 2021

Available online 20 September 2021

## Key words:

bisphosphonates

Gorham-Stout syndrome

interferon alfa-2b

thoracic cage

vanishing bone disease

## ABSTRACT

**Background/Objective:** Vanishing bone disease (VBD) is a rare entity, characterized by massive osteolysis and lymphovascular proliferation. Our objective was to report the case of a 22-year-old man who presented with VBD of the ribs and the challenges involved with its management in this location.

**Case Report:** A 22-year-old man presented with left-sided chest and back pain. An x-ray revealed that the fourth to sixth ribs on the left side of the chest were missing. The erythrocyte sedimentation rate was normal (5 mm/h; normal value, <10 mm/h), ruling out overt infectious and inflammatory pathology. A positron emission tomography-computed tomography scan excluded an underlying malignancy. Findings of serum protein electrophoresis did not show an M band. Normal levels of calcium (9.0 mg/dL; normal range, 8.3–10.4 mg/dL) and parathyroid hormone (38 pg/mL; normal range, 8–74 pg/mL) excluded primary hyperparathyroidism as a cause for osteolysis. A computed tomography scan of the chest revealed only lytic destruction and resorption of the fourth to sixth ribs on the left side. A diagnosis of VBD was made. A biopsy was deferred owing to the location of the disease involving the thoracic cage that could cause permanent lymphatic leakage. He was administered parenteral zoledronate 4 mg monthly for 3 months and subsequently once every 3 months for the next 2 years with subcutaneous interferon alfa-2b 6 MIU thrice weekly initially, then twice a week, and subsequently tapered to once every 10 days. On the follow-up at 3 years, he remained stable, with no further osteolysis or radiographic progression of the disease.

**Discussion/Conclusion:** VBD may present diagnostic and therapeutic challenges; the abovementioned patient was diagnosed with VBD after excluding secondary causes of osteolysis. Although a high index of suspicion is required to diagnose VBD, it also mandates close monitoring and follow-up.

© 2021 AACE. Published by Elsevier Inc. This is an open access article under the CC BY-NC-ND license (<http://creativecommons.org/licenses/by-nc-nd/4.0/>).

## Introduction

Vanishing bone disease (VBD), eponymously known as Gorham-Stout syndrome, is a rare disease of the bone that is characterized by massive osteolysis of the osseous matrix and lymphovascular proliferation, eventually resulting in destruction and absorption of the bone. Typically, it involves the bones of the maxillofacial region, extremities, ribs, and pelvic girdle.<sup>1</sup> Rarely, it may present with

life-threatening complications, such as pleural effusion, chylothorax, hemangiomas of the skin, pericardial effusion, osteomyelitis with septic shock, increased intracranial pressure, meningitis, cerebrospinal fluid leakage, spinal cord involvement, and paraplegia by vertebral involvement, depending on the site of involvement. Severe complications mandate that a multimodal approach to treatment is considered that includes medications, surgery, and radiation therapy.<sup>2</sup>

## Case Report

A 22-year-old man presented to the endocrinology outpatient clinic with a 2-year history of dull, aching pain in the left side of the upper portion of the back. He had been provisionally diagnosed to have VBD and was referred to our clinic for the second opinion and

**Abbreviations:** CT, computed tomography; IFN, interferon; VBD, vanishing bone disease.

\* Address correspondence to Dr Thomas V. Paul, Department of Endocrinology, Diabetes and Metabolism, Christian Medical College and Hospital, Ida Scudder Road, Vellore 632004, Tamil Nadu, India.

E-mail address: [thomasvpaul@yahoo.com](mailto:thomasvpaul@yahoo.com) (T.V. Paul).

<https://doi.org/10.1016/j.aace.2021.09.002>

2376-0605/© 2021 AACE. Published by Elsevier Inc. This is an open access article under the CC BY-NC-ND license (<http://creativecommons.org/licenses/by-nc-nd/4.0/>).

further management. Clinical examination revealed that he was tall statured, with a height of 183 cm, with significant hollowing of the left paraspinal area. Vital signs and findings of the rest of the physical examination were otherwise normal.

The initial symptom of pain occurred following sudden and unaccustomed activity and was worse with deep breathing and lying in the left lateral position. He received a traditional body massage treatment for these aches. There was no relief of symptoms, and on one occasion, approximately 5 to 6 months later, he experienced intense pain with a “cracking sensation” in the left side of the chest. A chest x-ray performed at this time revealed that he was missing the fourth to sixth ribs on the left side of the chest (Fig. 1). The erythrocyte sedimentation rate was 5 mm/h (normal value, <10 mm/h), thus ruling out overt infectious and inflammatory pathology. A positron emission tomography-computed tomography (CT) scan did not show the presence of an underlying malignancy. Bone densitometry was performed. The z scores at the lumbar spine (L1-L4) and neck of the femur were  $-0.3$  and  $-0.1$ , respectively. Findings of serum protein electrophoresis were normal and did not reveal the presence of an M band. Normal levels of calcium (9.0 mg/dL; normal range, 8.3–10.4 mg/dL) and parathyroid hormone (38 pg/mL; normal range, 8–74 pg/mL) also excluded primary hyperparathyroidism as a cause for the osteolysis. Cross-sectional imaging of the chest using CT only revealed lytic destruction and resorption of the fourth to sixth ribs on the left side with no involvement of the surrounding soft tissue and no underlying masses. An axial CT scan of the chest showed variable lytic destruction of the fourth to sixth ribs on the left side (Fig. 2). A provisional diagnosis of VBD was made. He was initiated on parenteral bisphosphonates with zoledronate, which was administered once a month for 3 months, followed by once every 3 months for the next 2 years. He was also administered subcutaneous interferon (IFN) alfa-2b 6 MIU thrice weekly, followed by twice weekly, and gradually tapered to once every 10 days. He presented to our clinic for further follow-up and management.

Laboratory evaluation showed his hemoglobin level to be 15 g/dL (normal range, 12–16 g/dL). Findings of the examination of bone biochemical parameters, including corrected calcium, phosphate, alkaline phosphatase, and parathyroid hormone levels, were normal. Bone turnover markers showed (C-terminal telopeptide of type 1 collagen, 55.1 pg/mL [normal range, 142–584 pg/mL]; pro-collagen type 1 N-terminal propeptide, 50 ng/mL [normal range, 16.8–65.5 ng/mL]) marked suppression of the antiresorption marker (Table). He was advised to continue yearly zoledronate and IFN alfa every 10 days with calcium and vitamin D replacement. On the yearly follow-up over the next 3 years, he remained stable, with mild dull, aching pain in the involved site. Findings of the examination of bone biochemical parameters were normal, bone turnover markers continued to be suppressed, and there was no radiographic progression of the disease on repeat chest x-ray (Fig. 3).

## Discussion

Herein, we present the case of an adult man who presented with the symptomatology and clinical features of VBD, the diagnosis in this case being made after excluding other secondary causes of osteolysis. VBD is a rare bone disease of uncertain etiology and is characterized by extensive monostotic or polyostotic spontaneous bone resorption. Exact figures on the incidence and prevalence of this condition are hitherto unknown. It is characterized by the proliferation of lymphatic and vascular channels that results in massive osteolysis of the involved bones, and histopathology reveals the presence of fibrous tissue with blood vessels, with the marrow replaced with fibrovascular tissue or abundant vascular

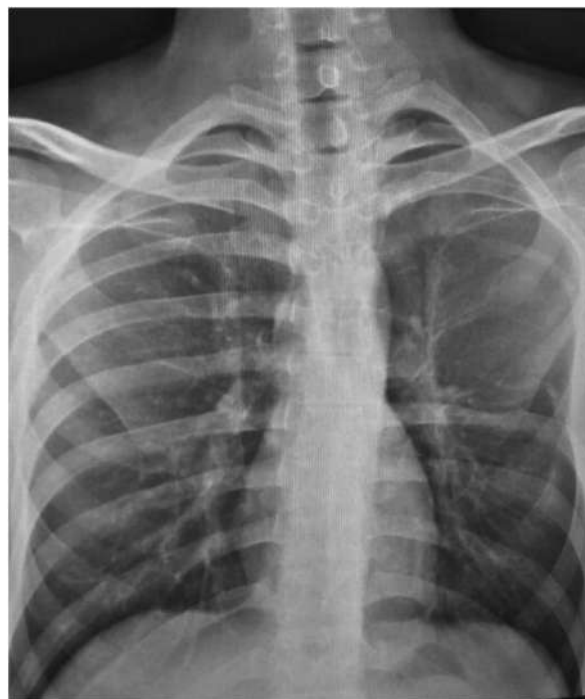

Fig. 1. Chest x-ray showed that the fourth to sixth ribs were missing in the left hemithorax.

channels.<sup>3</sup> Idiopathic osteolysis is classified into 5 types as follows: (1) type 1, hereditary multicentric osteolysis with dominant transmission, (2) type 2, hereditary multicentric osteolysis with recessive transmission, (3) type 3, nonhereditary multicentric osteolysis with nephropathy, (4) type 4, Gorham massive osteolysis, and (5) type 5, Winchester syndrome characterized by carpotarsal osteolysis with the onset in childhood, with an autosomal recessive inheritance, and without nephropathy.<sup>4</sup>

VBD may present at any age, although children and young adults are most susceptible. This congenital disease is commonly encountered in the second to third decades of life, with no definite geographic or gender predilection, although the reported prevalence is slightly higher in men. Common symptoms at presentation include localized pain, pathologic fracture, swelling, and functional impairment of the limbs or, in rare cases, it may be asymptomatic. The disease process commonly affects the maxilla, mandible, clavicle, ribs, cervical vertebrae, pelvis, and femur. A single bone or contiguous areas of multiple bones may be involved. Osteolytic areas appear as radiolucent foci that gradually coalesce till the entire bone is resorbed. Tubular bones may undergo concentric resorption leading to a “sucked candy” appearance.<sup>5</sup> The disease may rarely have an unpredictable outcome that may also be fatal, particularly if the disease involves the thorax, leading to pleural effusion and quadriplegia.<sup>6</sup> Spontaneous resolution has also been reported.<sup>7</sup> Owing to its rarity, the diagnosis of the disease is challenging and requires the exclusion of more common infectious, inflammatory, neoplastic, and endocrine causes of local osteolysis.<sup>6</sup> Most case reports in the literature have excluded secondary causes using appropriate tests. The diagnostic criteria proposed by Hefez et al<sup>8</sup> include the following: (1) positive biopsy findings in terms of angiomatous tissue presence, (2) absence of cellular atypia, (3) minimal or no osteoclastic response and the absence of dystrophic calcifications, (4) evidence of progressive local bone resorption, (5) nonexpansive, nonulcerative lesion, (6) absence of visceral involvement, (7) osteolytic radiographic pattern, and (8) negative

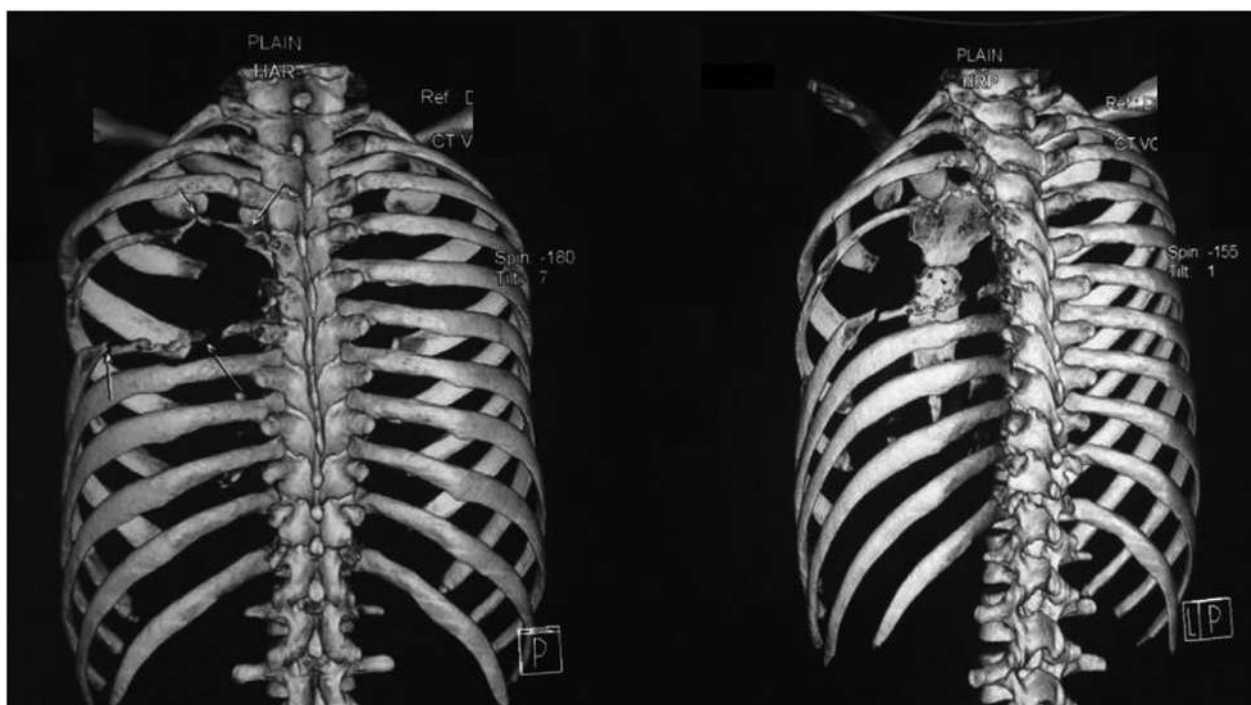


Fig. 2. A reconstructed computed tomography scan showed lytic destruction of the fourth to sixth ribs in the left hemithorax.

**Table**  
Investigations at Presentation and Follow-up

Parameter (normal range), units	Initial evaluation (elsewhere)	At presentation	Follow-up year 1	Follow-up year 2	Follow-up year 3
Hemoglobin (12–16), g/dL	15.5	15.1	...	16.9	...
ESR, mm/h	5	...	...	...	...
Electrophoresis	M band absent	...	...	...	...
Corrected calcium (8.3–10.4), mg/dL	9.0	8.8	...	9.9	9.5
Phosphate (2.5–4.5), mg/dL	4.3	3.6	...	3.9	3.9
Creatinine (0.5–1.4), mg/dL	0.8	0.6	...	...	0.5
Alkaline phosphatase (40–125), U/L	76	74	64	53	49
Parathyroid hormone (8–74), pg/mL	38	45.1	...	...	...
25-hydroxy vitamin D (30–75), ng/mL	10.4	26.1	...	...	17.2
P1NP (16.8–65.5), ng/mL	...	50	16.1	21	23
CTX (142–584), pg/mL	...	55.1	78.1	134	189

Abbreviations: CTX = C-terminal telopeptide of type 1 collagen; ESR = erythrocyte sedimentation rate; P1NP = procollagen type 1 N-terminal propeptide.

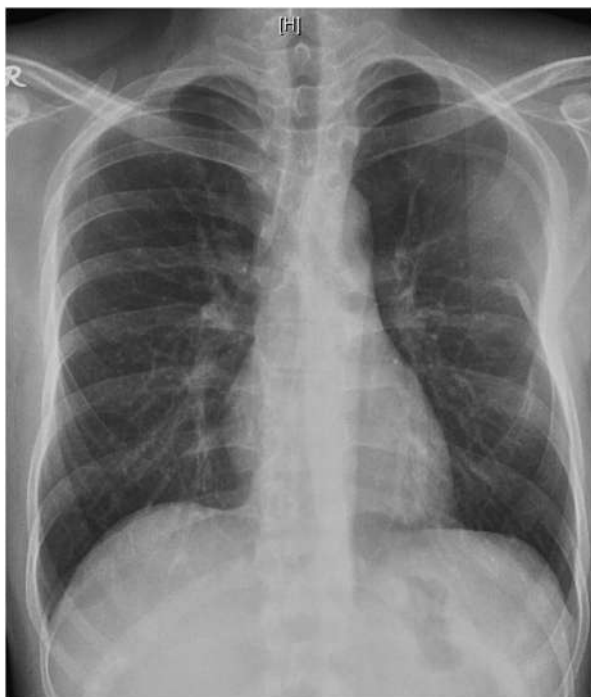hereditary, metabolic, neoplastic, immunologic, and infectious etiology findings.

The exact pathophysiology of VBD is uncertain. It is proposed that sluggish blood flow in osteolytic areas may cause local hypoxia, which may lower tissue pH and favor the activity of hydrolytic enzymes. Also, there is uncontrolled lymphangiogenesis driven by members of the vascular endothelial growth factor family, which may promote osteolysis by compressing the bone or elaborating factors that influence osteoclasts and osteoblasts.<sup>5</sup> Genetic factors that may be involved in the pathogenesis of the disease have not yet been identified. The clinical course of the disease is unpredictable. Some studies have shown that the levels of VEGF-A and interleukin 6 may be elevated in the course of the disease, with a decline in their levels following therapy. Additionally, other biomarkers that are being evaluated in the prognosis of this condition include VEGF-C, PDGF-BB, sRANKL, and osteoprotegerin.

Various therapeutic strategies used in VBD include surgery, radiotherapy, and pharmacologic agents. Surgery performed to prevent fluid accumulation in the pleural cavity includes pleurectomy, pleurodesis, thoracic duct embolization, and ligations.

Surgery may also be performed to stabilize the bone once the disease process has halted. Radiotherapy is administered when surgery is precluded or in combination with surgery. A total dosage of 36 Gy to 45 Gy administered in 2-Gy portions is found to offer the maximum therapeutic benefit. Pharmacologic agents used include bisphosphonates, IFN alfa-2b, steroids, bevacizumab, propranolol, and heparin. The pathophysiology of VBD involves the proliferation of vascular structures with increased interleukin 6–stimulated osteoclastic activity, which is responsible for the osteolysis seen in this condition.<sup>9</sup> The rationale for using IFN is to exploit its antiangiogenic action.<sup>10</sup> Various case reports have mentioned the use of IFN in a dosage ranging from 1.5 MIU to 6 MIU to treat VBD.<sup>10–12</sup> Thus, a combination of bisphosphonates and IFN works synergistically to mediate antiosteoclastic and antiangiogenic activities.

As far as other cases in the literature are concerned, cases involving the rib cage are limited. Srivastava et al<sup>13</sup> reported the case of a patient presenting with VBD of the ribs on the right side and spine. He presented with flattening of the chest on the right side and thoracic kyphoscoliosis, which was surgically corrected.<sup>13</sup> Kakhaki et al<sup>14</sup> reported the case of a 48-year-old man who



**Fig. 3.** Chest x-ray showed no radiographic progression of the disease.

presented with dyspnea and recurrent episodes of pleural effusion following a blunt trauma of the chest who was later diagnosed to have VBD with massive osteolysis of the ribs. He required treatment with local radiotherapy with monthly infusions of pamidronate with thalidomide. His condition remained stable after 7 years of medical therapy with mild pleural thickening and fibrosis.<sup>14</sup>

In the abovementioned case, the diagnosis of VBD was confirmed using a CT scan of the chest that showed variable lytic resorption of the fourth to sixth ribs on the left side after excluding secondary causes of osteolysis. The patient's erythrocyte sedimentation rate was 5 mm/h (normal value, <10 mm/h), thus ruling out overt infectious and inflammatory pathology. A positron emission tomography-CT scan excluded an underlying malignancy. Normal findings of serum protein electrophoresis ruled out a monoclonal gammopathy. There was no evidence of parathyroid hormone-dependent hypercalcemia to suggest primary hyperparathyroidism as a cause for osteolysis. Additionally, a biopsy from the involved site would have confirmed the diagnosis. On biopsy, the presence of fibrous tissue with blood vessels, with the marrow replaced with fibrovascular tissue or abundant vascular channels, is usually noted. However, this was not performed owing to the precarious location of the bony disease involving the thoracic cage, and the potential for the development of permanent lymphatic leakage. The patient was initiated on specific treatment for symptomatic relief. On repeated doses of zoledronate and IFN therapy, the disease remained stable, with considerable improvement in symptomatology and no evidence of progression. Other options

that may be explored in case of worsening of the disease include radiotherapy, with the continuation of medical management, and surgical attempts to halt the development of chylothorax, should this complication occur.

### Conclusion

VBD is a rare disease with only approximately 300 cases reported in the literature. The etiology of the condition remains speculative, and its prognosis is uncertain, with little knowledge about definite therapy. A high index of suspicion needs to be maintained in considering this diagnosis, after excluding more common infectious, inflammatory, neoplastic, and endocrine causes for osteolysis. A combined approach involving surgery, radiotherapy, and pharmacotherapy with bisphosphonates and IFN alfa-2b with close monitoring and follow-up of the patient appears to be promising in stabilizing the disease condition.

### Disclosure

The authors have no multiplicity of interest to disclose.

### References

1. Yokoi H, Chakravarthy V, Whiting B, Kilpatrick SE, Chen T, Krishnaney A. Gorham-Stout disease of the spine presenting with intracranial hypotension and cerebrospinal fluid leak: a case report and review of the literature. *Surg Neurol Int.* 2020;11:466.
2. Esper A, Alhoulaiy S, Emran A, Youssef S, Alshehabi Z. Gorham Stout disease: a case report from Syria. *Oxf Med Case Rep.* 2021;2021(1):omaa121.
3. Brance ML, Castiglioni A, Cocco N, Palatnik M. Two cases of Gorham-Stout disease with good response to zoledronic acid treatment. *Clin Cases Miner Bone Metab.* 2017;14(2):250–253.
4. Hardegger F, Simpson LA, Segmueller G. The syndrome of idiopathic osteolysis. Classification, review, and case report. *J Bone Joint Surg Br.* 1985;67(1):88–93.
5. Dellinger MT, Garg N, Olsen BR. Viewpoints on vessels and vanishing bones in Gorham-Stout disease. *Bone.* 2014;63:47–52.
6. Stevens J, Flower H, Patton JT. What does vanishing bone disease look like? *BMJ Case Rep.* 2018;2018. bcr2017224061.
7. Nikolaou VS, Chytas D, Korres D, Efstathopoulos N. Vanishing bone disease (Gorham-Stout syndrome): a review of a rare entity. *World J Orthop.* 2014;5(5):694–698.
8. Heffez L, Doku HC, Carter BL, Feeney JE. Perspectives on massive osteolysis. Report of a case and review of the literature. *Oral Surg Oral Med Oral Pathol.* 1983;55(4):331–343.
9. Elera-Fitzcarrald C, Ugarte-Gil MF. Gorham-Stout syndrome: a phantom bone disease treated with bisphosphonates. *J Clin Rheumatol.* 2020;26(5):e135–e136.
10. Kose M, Pekcan S, Dogru D, et al. Gorham-Stout syndrome with chylothorax: successful remission by interferon alpha-2b. *Pediatr Pulmonol.* 2009;44(6):613–615.
11. Takahashi A, Ogawa C, Kanazawa T, et al. Remission induced by interferon alfa in a patient with massive osteolysis and extension of lymph-hemangiomas: a severe case of Gorham-Stout syndrome. *J Pediatr Surg.* 2005;40(3):E47–E50.
12. Escande C, Schouman T, Françoise G, et al. Histological features and management of a mandibular Gorham disease: a case report and review of maxillo-facial cases in the literature. *Oral Surg Oral Med Oral Pathol Oral Radiol Endod.* 2008;106(3):e30–e37.
13. Srivastava SK, Aggarwal RA, Nemade PS, Bhoale SK. Vanishing bone disease of chest wall and spine with kyphoscoliosis and neurological deficit: a case report and review of literature. *Indian J Orthop.* 2017;51(1):107–114.
14. Kakhaki AD, Khodadad K, Pejhan S, et al. Gorham's disease with chest wall involvement: a case report and a review of the literature. *Iran Red Crescent Med J.* 2014;16(11), e12180.