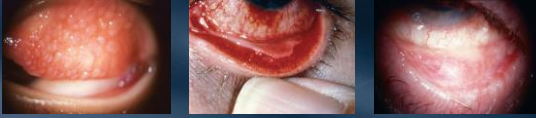

## Chronic Conjunctivitis



COA Monterey Symposium 2017



Nicholas Colatrella, OD, FFAO, Dipl AAO, ABO, ABCMO  
Jeffrey R. Varanelli, OD, FFAO, Dipl ABO, ABCMO

Text NICHOLASCOLA090 to 22333 to join Live Text Poll

## Disclosures

- Allergan Pharmaceuticals Speaker's Bureau
- Bio-Tissue
- BioDLogics, LLC
- Katena/IOP
- Seed Biotech
- Johnson and Johnson Vision Care, Inc.
- Shire Pharmaceuticals

## Live Survey

- Text NICHOLASCOLA090 to 22333 once to join
- Then text A, B, C, D, E or write in your answer
  - Live
  - Immediate
  - Accurate

• Nicholas Colatrella, OD, FFAO, Dipl AAO, ABO, ABCMO

• Jeffrey Varanelli, OD, FFAO, Dipl ABO, ABCMO

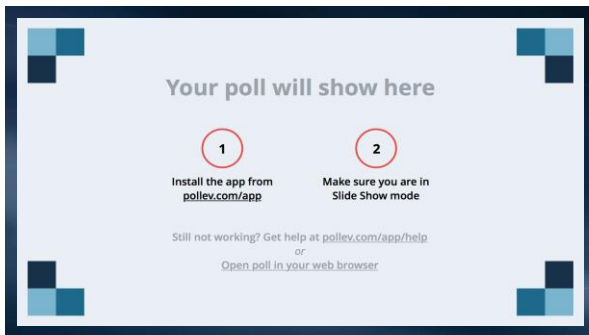


## Introduction

- Chronic conjunctivitis is one of the most frustrating reasons that patients present to the office
  - Often times patients will seek multiple providers searching for a solution
- The chronicity of their symptoms is extremely frustrating to the patient and treating physician alike
- Some conditions can seriously affect vision and create ocular morbidity
- Many of these diseases do not respond to commonly used topical antibiotics, topical steroids, artificial tears, and other treatments for external ocular disease
- Our hope during this one-hour lecture is to present a process to help aid in the diagnosis of chronic conjunctivitis
  - help you determine the most likely etiology

## Classify Conjunctivitis into 4 Categories

- (1) Time course
- (2) Morphology
- (3) Localization of disease process
- (4) Type of discharge or exudate



## Classification: Time Course

- Three weeks is the dividing point as it is the upper limit for cases of viral infection and most bacterial infections to resolve without treatment.
  - Acute Conjunctivitis
    - Conjunctivitis that has been present for less than 3 weeks
    - Adenoviral
    - Herpes Simplex
    - Inclusion (chlamydial) – if caught early
    - Newcastle disease (poultry handlers or veterinarians)
    - Enterovirus
    - Cat-Scratch Fever
  - Chronic Conjunctivitis
    - Conjunctivitis that has been present for greater than 3 weeks

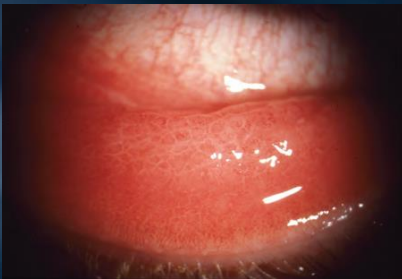## Classification: Morphology

- Morphologic classification can be broken down into five categories:
  - (1) Papillary
  - (2) Giant papillary
  - (3) Follicular
  - (4) Membranous/pseudomembranous
  - (5) Cicatrizing

## Papillary

- All forms of conjunctivitis will have some form of Papillary hypertrophy
- Papillae are described as elevations of the conjunctiva with a central core blood vessel
- As the conjunctiva becomes thickened by infiltration with inflammatory cells, the individual papillae are created by septae that are fibrous connections of the epithelium to the underlying substantia propria
- Each papilla is then seen as a red dot, which represents the core blood vessel viewed on end
- Normally, visualization of individual papillae is difficult.
  - In papillary hypertrophy, the normal vascular pattern becomes obscured, and in extreme cases obliterated, by the inflammatory process

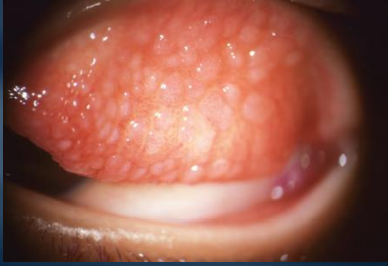## Papillary



## Giant Papillary

- When the individual septae separating papillae break down, multiple individual papillae merge to form a giant papilla
- Giant papillae are conjunctival elevations that are greater than 1 mm in size
- Most commonly occur on the upper tarsal conjunctiva, but in some cases can be seen on the lower tarsal conjunctiva
- They usually have flat tops and seem to fit together like cobblestones, hence the descriptive term "cobblestone papillae"

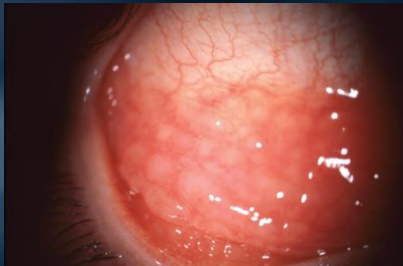
### Giant Papillary



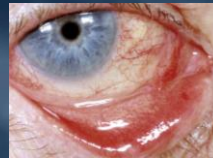### Follicular

- Dome-shaped conjunctival elevations with a circumferential blood vessel and clear center
- Histopathologically, follicles are aggregations of mononuclear inflammatory cells that are organized similarly to follicles within lymph nodes
- In children, follicles are sometimes seen in the absence of other disease, a condition sometimes termed folliculosis
- When follicles are present in conjunction with papillary hypertrophy, there is a follicular conjunctivitis

### Follicular

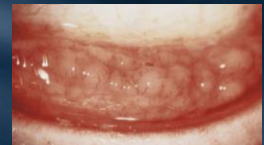

#### • Papillae



Note the fibrovascular core in which the blood vessels arborize on reaching the surface.

#### • Follicle

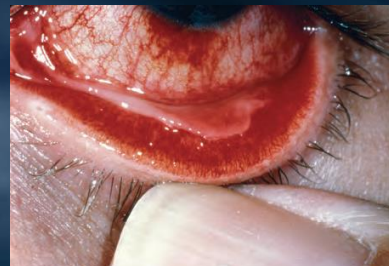

Note the large follicles with blood vessels sweeping up from the base over the convexity

### Membranous/Pseudomembranous

- Membranes and pseudomembranes are sheets composed of a network of fibrin and inflammatory cells that form a layer over the surface of the conjunctiva
- True membranes have a growth of capillaries from the conjunctiva into the membrane, while pseudomembranes are avascular
- Either type of membrane is a sign of severe inflammation where the conjunctiva is very friable, and stripping either type of membrane causes bleeding

### Membranous/Pseudomembranous



## Cicatrizing

Some forms of conjunctivitis lead to progressive conjunctival scarring, or cicatrization

Findings associated with cicatrization include:

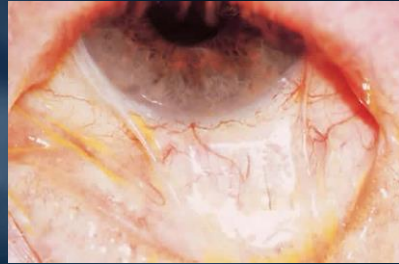
- stellate or linear subconjunctival scars
- shortening of the conjunctival fornices
- formation of symblepharon
- Eventually ankyloblepharon
- cicatricial entropion

loss of conjunctival goblet cells leading to conjunctival and corneal keratinization

Patients with pre-existent scarring are not immune to the causes of acute conjunctivitis

Concurrence of scarring and inflammation is not enough to confirm a diagnosis of cicatrizing conjunctivitis; this diagnosis is made when chronic conjunctival inflammation is associated with progressive cicatrization

## Cicatrizing



## Classification: Anatomic Localization

- Different forms of conjunctivitis tend to affect different areas of the external eye
- Determining the predominant area of inflammation can contribute to making an accurate diagnosis
- Some conditions have significant involvement of the eyelids as well as the conjunctiva
  - Chronic blepharitis
  - Molluscum contagiosum
  - Atopic Keratoconjunctivitis
- Some primarily affect the upper palpebral conjunctiva
  - Vernal keratoconjunctivitis (VKC)
  - Trachoma
  - Superior limbic keratoconjunctivitis (SLK)

## Classification: Anatomic Localization

- Some primarily affect the lower palpebral conjunctiva
  - Inclusion conjunctivitis
  - Toxic conjunctivitis
- Other entities involve the bulbar conjunctiva
  - keratoconjunctivitis sicca
- Many forms of chronic conjunctivitis have significant corneal involvement, termed Keratoconjunctivitis
- Most forms of chronic conjunctivitis are bilateral, although often asymmetric
- Some are unilateral
  - Lacrimal drainage infections
  - Ocular surface tumors

## Classification: Discharge / Exudate

As part of the inflammatory process, blood vessels have increased permeability, leading to leakage of serum, proteins, and inflammatory cells, creating an exudate

Exudates can take different forms:

Grossly purulent exudates are seen in hyperacute conjunctivitis.

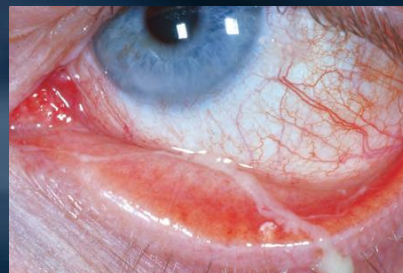
These are always acute diseases.

Watery exudates are seen in viral infections

Always acute diseases.

The most common type of exudate is mucopurulent (or catarrhal), representing a mixture of mucous and pus

In some allergic conditions such as VKC, there can be a mucoid exudate, a thick, tenacious discharge that can be peeled intact off the conjunctival surface, often revealing a cast of the morphology of the conjunctival surface



## Chronic Follicular Conjunctivitis

### Chronic Follicular Conjunctivitis

- The major causes of chronic follicular conjunctivitis are:
  - Chlamydial infection
  - Toxic conjunctivitis from topical medications
  - Molluscum contagiosum
- Thoroughly examine the eyelids for molluscum lesions
- Take a detailed history of topical medication use that could lead to follicular conjunctivitis
- If none of above identified, there is a presumptive diagnosis of chlamydial infection
  - confirmed with laboratory studies
  - or a therapeutic trial of an appropriate systemic antichlamydial antibiotic

### Chlamydial Infection

- The most common cause of chronic follicular conjunctivitis is infection with the organism *Chlamydiae trachomatis*
- This infection takes two clinical forms:
  - Trachoma
  - Inclusion conjunctivitis

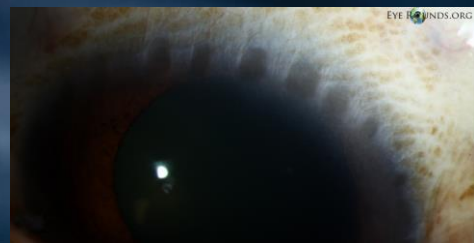
### Trachoma

- Trachoma is the leading cause of corneal blindness in the world It is highly endemic in many developing areas of the world
- Prevalence of the disease related to poor sanitation
  - Flies are believed to be an important vector for the spread of the disease
- High level of morbidity is likely related to multiple recurrences of infection, as well as frequent concurrent bacterial superinfections
- Trachoma causes a follicular conjunctivitis where the follicular response is predominant in the superior conjunctiva

### Trachoma

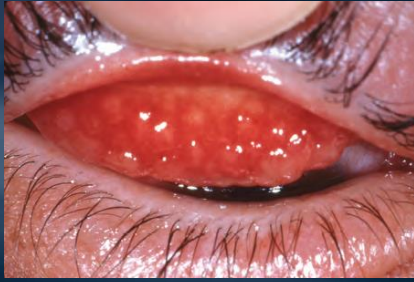- Superior pretarsal follicles can become as large as those seen in the conjunctival fornix, in which case they are termed "mature"
- Follicles can also occur at the limbus; necrosis of limbal follicles leads to depressed limbal scars called "Herbert's pits", a finding that is pathognomonic for trachoma
- A vascular pannus most marked along the superior limbus is frequently seen. With progression of the disease, trachoma is a cicatrizing as well as a follicular conjunctivitis, with development of linear subepithelial scarring affecting the pretarsal conjunctiva
- A dense linear scar superior to the upper lid margin is called an "Arlt's line"
- Conjunctival scarring causes cicatricial entropion and trichiasis, which leads to the corneal scarring that can result in blindness

### Trachoma

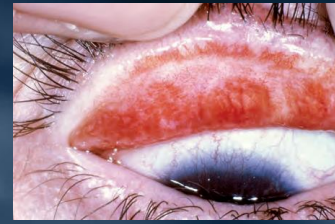



## Trachoma



## Trachoma



- WHO's GET 2020 / SAFE Strategy

## Inclusion Conjunctivitis

- Inclusion conjunctivitis is the most common form of ocular chlamydial infection in the developed world
- It is a sexually transmitted disease
- C trachomatis is the most prevalent cause of nonspecific urethritis in men and cervicitis in women and reaches the eye by genital-ocular transmission
- While inclusion conjunctivitis can sometimes be diagnosed during the acute stage (<3 weeks duration), non-treated or inadequately treated infections will persist well longer than 3 weeks
- Symptoms include redness of the eye and a mucopurulent discharge
- Clinical findings are those of a follicular conjunctivitis, with the lower palpebral conjunctiva being most severely affected on exam (the upper forniceal conjunctiva is likewise affected, but is not visible on examination without double-eversion of the upper eyelid)

## Treatment of Chlamydial infections

- Diagnosis of trachoma and inclusion conjunctivitis is usually made based on clinical findings
- Inclusion conjunctivitis gets its name from the basophilic inclusions capping the epithelial cell nucleus seen on Giemsa-stained conjunctival scrapings
- Chlamydial infection is the only form of chronic follicular conjunctivitis where PMNs predominate
- The diagnosis can be confirmed by chlamydial culture, direct fluorescent antibody staining, or PCR techniques.

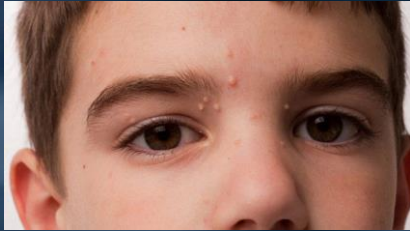## Treatment of Chlamydial infections

- Neither form of adult chlamydial infection responds to topical antibiotics.
- Inclusion conjunctivitis is a systemic disease and the genital infection must be treated as well
  - Azithromycin 1 gram single dose
  - doxycycline 100 mg bid for 7 days - 3 weeks
  - tetracycline 250 mg qid for 7 days - 3 weeks
  - Erythromycin 500 mg qid for 7 days - 3 weeks
- Treatment of regular sexual contacts is important to prevent recurrent infection
- Periodic mass administration of antichlamydial antibiotics in endemic areas can reduce the overall morbidity of trachoma in treated communities

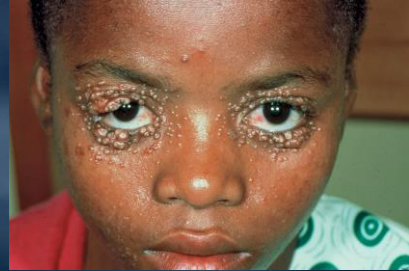## Molluscum Contagiosum

- Caused by the molluscum contagiosum virus
- Lesions are waxy, elevated cutaneous nodules that frequently have an umbilicated centers
- Often found on or near the eyelid margin
  - Creating a chronic follicular conjunctivitis
  - Presumably related to the toxic effect of viral particles spilling onto the conjunctiva
    - In HIV-infected patients they can be numerous and diffuse
- Lesions does not respond to topical medications
- Definitive treatment is removal of the offending lesion(s), either by excision or curettage

## Molluscum Contagiosum



## Molluscum Contagiosum



## Toxic Follicular Conjunctivitis

- Chronic follicular conjunctivitis can be the result of a toxic reaction to a wide variety of topical medications
- Symptoms and physical findings are identical to inclusion conjunctivitis
- Laboratory studies, however, are negative for chlamydial organisms
- In contrast to chlamydial infection, where polymorphonuclear leukocytes (PMNs) are the predominant inflammatory cell, conjunctival scrapings predominantly reveal lymphocytes
- This diagnosis is made by having a high index of suspicion, in identifying a medication that is the likely cause, and observing resolution of the conjunctivitis after discontinuing the medication

## Toxic Follicular Conjunctivitis

- Medications Causing Toxic Follicular Conjunctivitis:
  - Antiviral: idoxuridine, vidarabine, trifluridine
  - Glaucoma: pilocarpine, carbachol, echothiophate, epinephrine, dipivefrin, apraclonidine, latanoprost
  - Antibiotics: gentamicin, neomycin, sulfonamides, amphotericin b
  - Other: neostigmine, physostigmine, atropine, scopolamine
- Various cosmetics can cause toxic follicular conjunctivitis

## Giant Papillary Conjunctivitis

Your poll will show here

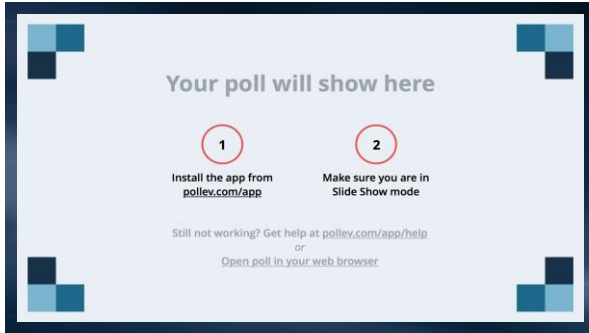
1

Install the app from  
[pollev.com/app](http://pollev.com/app)

2

Make sure you are in  
Slide Show mode

Still not working? Get help at [pollev.com/app/help](http://pollev.com/app/help)  
or  
Open poll in your web browser



## Giant Papillary Conjunctivitis

- Giant papillary conjunctivitis (GPC) occurs in primary and secondary forms
- All forms of GPC are at least partially caused by chronic ocular allergy
- Primary forms of GPC include
  - Vernal keratoconjunctivitis (VKC)
  - Atopic keratoconjunctivitis (AKC)
- Secondary GPC include
  - Contact lenses
  - Ocular prostheses
  - Exposed sutures

## Giant Papillary Conjunctivitis

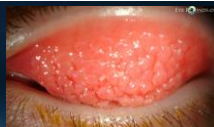- Diagnosis is made by identification of characteristic clinical findings, in the absence of any cause for secondary GPC
- Conjunctival scrapings from actively inflamed eyes invariably demonstrate eosinophils
- Patients with AKC may have high circulating IgE levels
- Patients with atopic eczema frequently have skin colonization with *Staphylococcus aureus*, which can contribute to the keratitis when the eyelids are involved

## Vernal Keratoconjunctivitis

- VKC is a chronic allergic conjunctivitis affecting children and young adults, generally between the ages of 6 and 18
  - Male > Female
- Patients often have concurrent allergic diseases such as seasonal allergies and asthma
- The predominant symptom is ocular itching, as well as redness, mild photophobia, and a thick mucoid discharge
- There is often a seasonal variation in symptoms with the spring and early summer being the worst period, hence the name "vernal" (springtime) keratoconjunctivitis

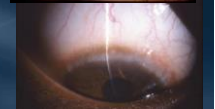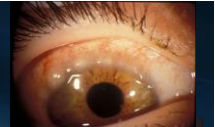
## Vernal Keratoconjunctivitis

- Palpebral form
  - Most common
- Predominant finding is giant papillary hypertrophy primarily affecting the upper tarsal conjunctiva
- The lower palpebral conjunctiva demonstrates a fine papillary response
- The entire conjunctiva has a pale "milky" infiltrate that gives the conjunctiva a pink color, rather than the deep red seen in acute forms of conjunctivitis
- A thick, tenacious mucoid discharge is often present
  - Maxwell Lyon Sign



## Vernal Keratoconjunctivitis

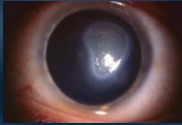
- Limbal form
  - Fine milky papillary response without formation of giant papillae
- Gelatinous limbal papillae associated with epithelial infiltrates called Horner-Trantas dots, which are focal collections of eosinophils
- More prevalent in African American children





## Vernal Keratoconjunctivitis

- In either form:
  - There is commonly a superior punctate keratopathy
- Punctate lesions can coalesce into a sterile shield-shaped ulcer (“vernal ulcer”) centered at the junction of the middle and upper third of the cornea



## Atopic Keratoconjunctivitis

- AKC has different demographic characteristics
  - patients suffer from atopic eczema from early childhood, but are free of ocular symptoms until early adulthood
    - Male > Female
    - Mid 30's
  - Generally have eczema affecting the eyelids as well as other areas of the body
- Ocular symptoms include itching, redness, and a mucoid discharge
- Conjunctival involvement is characterized by papillary hypertrophy ranging from fine to giant papillae
- While the upper tarsal conjunctiva is involved, the lower palpebral conjunctiva is more affected than in VKC
- Giant papillae can sometimes be seen in the inferior conjunctiva, which never occurs in VKC

## Atopic Keratoconjunctivitis

- Thickening of the limbal conjunctiva is common
- Conjunctival scarring often occurs from prolonged inflammation, resulting in symblepharon formation
- Due to longer duration of the disease, corneal involvement is more common in AKC than VKC, characterized by a superficial epitheliopathy eventually leading to vascularization and scarring
- AKC patients are prone to early development of cataracts, have a higher incidence of retinal detachment, and often suffer more severe corneal infection with herpes simplex virus
- Cicatricial ectropion may also occur due to prolonged eczematous skin changes

## VKC / AKC Treatment

- Histamine release from mast cells plays a major role in the pathogenesis of both diseases
- Topical mast cell stabilizers are mainstay of Tx
  - Cromolyn sodium
  - Lodoxamide
- Topical antihistamines and “antihistamines with mast cell stabilizing properties” are generally too weak for these diseases
- Topical steroids are highly effective for short bursts only
  - Supratarsal injections of triamcinolone acetonide (Kenalog) are effective for acute flares of the disease
- Topical cyclosporine has also proven to be effective for long-term treatment in recalcitrant cases
- Dermatologic preparation of tacrolimus (Protopic) also effective
- Amniotic membrane therapy
- Where staphylococcal exotoxin contributes to the punctate keratopathy, periodic local treatment with antistaphylococcal antibiotics are useful

## Secondary Forms of GPC



- Symptoms include redness, heaviness and swelling of the lids, and a mucopurulent discharge
- Decreasing lens tolerance in CL wear is usually the initial symptom
- This diagnosis is made by observing giant papillae on the upper pretarsal conjunctiva
  - Not as large as those seen in primary forms of GPC

## Secondary Forms of GPC

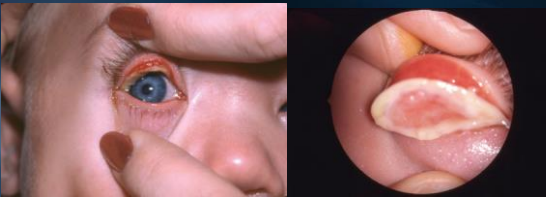- Prosthesis-related GPC often responds to more frequent removal, cleaning, and polishing of the prosthesis
- Chronic treatment with mast cell inhibitors can suppress the disease for the long term
- Contact lens-related GPC responds to:
  - a period of stopping lens wear, followed by re-institution of lenses using a different lens material
  - more frequent removal and cleaning
  - increasing the frequency of lens replacement (daily disposable lenses are extremely useful for this indication)
  - suppressive treatment with mast cell stabilizers

## Chronic Membranous Conjunctivitis

## Chronic Membranous Conjunctivitis

- Membranes and pseudomembranes are usually signs of severe, acute inflammation
  - Chronic forms of membranous conjunctivitis are rare
  - Ligneous conjunctivitis is the only chronic membranous conjunctivitis
- The disease is characterized by thick membranes, sometimes called ligneous lesions
  - Referring to the "woody" texture of the membranes
- Affects individuals of all ages (infancy to elder years)
  - median between 3 and 5 years
  - slight female preponderance
- It can affect one or both eyes and any area of the conjunctiva
  - palpebral conjunctiva most commonly involved
- Believed to be a manifestation of type I hypoplasminogenemia
  - membranes can be found in tympanic membrane, upper and lower respiratory tract, renal collecting system, and female genital tract

## Chronic Membranous Conjunctivitis

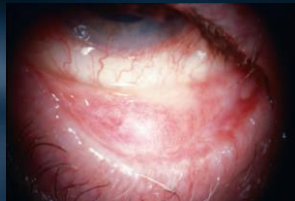


- Surgical removal of the lesions followed by intense treatment with topical heparin, corticosteroids, alpha-chymotrypsin.
- Topical treatment has been reported using concentrated plasminogen derived from fresh frozen plasma

## Chronic Cicatrizing Conjunctivitis

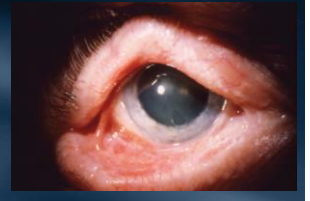
## Chronic Cicatrizing Conjunctivitis

- Some forms of chronic conjunctivitis lead to progressive scarring
  - Cicatrizing conjunctivitis
- Symptoms include
  - redness, irritation, foreign body sensation, and a discharge
- In addition to a papillary response, signs of conjunctival scarring are observed.
- The earliest finding is shortening of the conjunctival fornices
  - more easily observed with a penlight exam



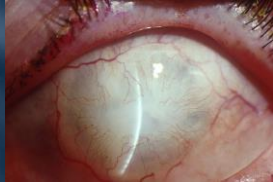## Chronic Cicatrizing Conjunctivitis

- Stellate and linear subepithelial scarring can be seen involving the palpebral conjunctiva
- With more advance disease, symblephara develop that can lead to ankyloblepharon
- Conjunctival scarring can cause cicatricial entropion and trichiasis



## Chronic Cicatrizing Conjunctivitis

- Corneal involvement includes vascularization, epithelial staining, persistent epithelial defects, and scarring as the result of loss of limbal stem cells
- All forms of cicatrizing conjunctivitis cause a mucin-deficient dry eye, characterized by rapid break-up of the tear film.
- Treatment of the underlying disease is the most effective form of treatment
  - Most commonly using anti-inflammatory
  - Immunosuppressive agents



## Unilateral Chronic Papillary Conjunctivitis

## Unilateral Chronic Papillary Conjunctivitis

A small number of conditions cause chronic papillary conjunctivitis (CPC) that is more typically unilateral than bilateral. These include:

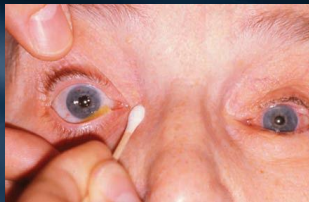- Lacrimal drainage infections
  - Chronic dacryocystitis
  - Canaliculitis
- Giant fornix syndrome
- Masquerade syndrome due to a tumor
  - most commonly sebaceous carcinoma
- Factitious conjunctivitis

## Lacrimal Drainage Infections

- Patients who present with a unilateral chronic or recurrent conjunctivitis, limited to one eye, should first have a thorough exploration of their lacrimal drainage system
- Symptoms of chronic epiphora, a larger-than-normal tear meniscus, and prolonged retention of fluorescein dye strongly suggest lacrimal drainage obstruction
- Swelling of the canalicular region of the eyelid along with the appearance of a "pouting punctum" suggest canaliculitis

## Lacrimal Drainage Infections

- In nasolacrimal duct obstruction and chronic dacryocystitis, digital massage over the lacrimal sac, or lacrimal irrigation, will usually produce reflux of fluid along with purulent discharge



## Chronic Dacryocystitis

- Presents as a chronic or recurrent conjunctivitis
  - Usually limited to one eye, although bilateral cases do occur
- Complain of:
  - Epiphora
  - chronic mucopurulent discharge
  - redness of the eye
  - sticking together of the lashes in the morning
- Diffuse papillary response and mucopurulent discharge
- Swelling of the medial canthal region overlying the lacrimal sac
  - Not tender or acutely inflamed
- Some patients will give a history of chronic sinus disease or facial trauma
  - elderly women, have progressive essential dacryostenosis

## Chronic Dacryocystitis

- Intermittent obstruction can be caused by a dacryolith
- Chronic infection in the lacrimal sac occurs as the result of stagnation of tears that cannot progress past the obstruction
- Retrograde drainage of purulent material into the eye causes the conjunctivitis. A definitive diagnosis is made when purulent material refluxes into the eye with pressure over the lacrimal sac, or with reflux of saline and pus on attempted nasolacrimal irrigation

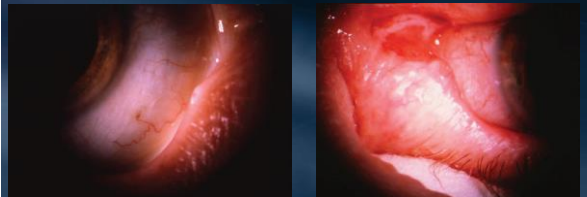
## Chronic Dacryocystitis

- Gram-positive organisms including *Staphylococcus aureus*, coagulase-negative staphylococci, and *Streptococcus pneumoniae* are found in approximately two-thirds of cases
- Gram-negative bacteria, most commonly *Pseudomonas aeruginosa*, are found in approximately 25%
- While topical or systemic antibiotic treatment may provide temporary relief of symptoms, without relief of the obstruction, the infection always recurs
- A dacryocystorhinostomy is curative

## Canaliculitis

- This condition occurs because of a diverticulum of the canaliculus
  - with stasis of fluid within the diverticulum leading to secondary infection
- No epiphora
- No delay of fluorescein drainage
- No elevated tear meniscus
- Patients complain of symptoms similar to bacterial conjunctivitis and demonstrate papillary conjunctivitis with a catarrhal discharge
- The disease should be suspected when there is inflammation and swelling along the lid margin medial to the punctum
  - Use the normal opposite side for comparison
- The diagnosis is confirmed by *expression of the canaliculus*
  - After the eye has been anesthetized the area of swelling is squeezed between two cotton-tipped applicators
  - Roll both are toward the punctum
  - Delivery of a granular, cheesy material from the punctum establishes the diagnosis
    - Canalicular concretions are found in more than 70% of patients.

## Canaliculitis

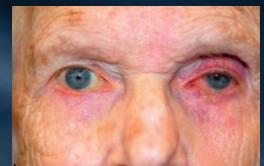

## Canaliculitis

- Caused by a variety of organisms
  - Streptococci
  - Staphylococci
  - *Actinomyces species*
    - Anaerobic filamentous bacteria
- Complete expression followed by irrigation with penicillin or another antibiotic solution can be curative
- In recalcitrant cases, the diverticulum must be obliterated to achieve a cure

## Giant Fornix Syndrome

- Chronic or recurrent mucopurulent conjunctivitis
  - Deeper-than-normal superior conjunctival fornices
  - Related to upper lid ptosis from dehiscence of the levator aponeurosis
  - Elderly in their eighth to tenth decade
  - Majority are female
  - Typically unilateral
  - Consistent finding is a coagulum of mucopurulent material in the recesses of a large upper fornix
    - *S aureus* positive
    - Concomitant nasolacrimal duct obstruction and chronic dacryocystitis
- Diagnosis often delayed
  - Average duration of symptoms of 2 years





## Giant Fornix Syndrome

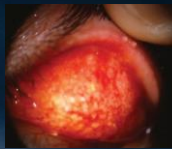
- Corneal complications, including punctate epitheliopathy, vascularization, scarring, persistent epithelial defects, chronic corneal ulceration, and perforation, are common
- Short course topical antibiotics only give temporary improvement
- Treatment strategies include the prolonged use of systemic anti-staphylococcal antibiotics, and intensive topical antibiotics and corticosteroids
- Supratarsal injections of antibiotics and steroids, along with irrigation and sweeping of the fornix with povidone-iodine solution, have been advocated
- Conjunctival cultures helpful to rule out MRSA and direct treatment
- Surgical correction of the ptosis may play a role in management

## Masquerade Syndrome

- Chronic unilateral conjunctivitis caused by a malignant tumor involving the conjunctiva
- The most common is sebaceous carcinoma of the eyelid
  - Sebaceous carcinoma usually arises in the meibomian gland
  - Can also arise in the glands of Zeis or from sebaceous tissue in the caruncle.
  - Occurs more commonly in women
  - Upper lid is involved more frequently than the lower lid
  - Peak age is the fifth to eighth decade

## Masquerade Syndrome

- The primary lid tumor can be occult
- The tumor has a predilection for intraepithelial spread through the conjunctiva
  - “Pagetoid spread”
  - Mimics inflamed conjunctival tissue or causes secondary inflammation
- In cases of unexplained chronic unilateral conjunctivitis
  - Focal areas of conjunctival thickening or nodularity should be biopsied
  - If the lesion is found to be malignant, appropriate treatment, whether surgical, radiation, or chemotherapy, is necessary to cure the conjunctivitis



## Factitious Conjunctivitis

- Result of self-inflicted disease
  - Occurs when individuals gain some psychological benefit
  - A more tangible gain
    - *Malingering*
- While factitious disease can be bilateral, as much secondary gain can usually be derived from unilateral disease, so there is usually little reason for the patient to involve the second eye
- Making a diagnosis of factitious conjunctivitis requires a very high index of suspicion
- Affected individuals tend to be very good at denying their role in the disease and hiding their method of producing conjunctival inflammation


## Factitious Conjunctivitis

- “Red flags” that might indicate the possibility of factitious conjunctivitis include
  - Unrealistic history
  - Noncompliance with medication regimens
  - Seeming indifference to the severity of the disease
  - Failure to respond to what should be effective treatment
  - Focal, rather than diffuse disease
  - Unusual patterns of conjunctival staining
    - Infero-nasal quadrant is most commonly involved, presumably because this is the easiest location for the patient to access
- Ultimately, treatment is psychiatric, but requires identifying the nature of the problem and confronting the patient with the diagnosis

## Factitious Conjunctivitis

- *Mucus fishing syndrome*
  - Have an underlying cause for chronic ocular surface inflammation, most commonly keratoconjunctivitis sicca, chronic blepharitis, or ocular allergy, causing a chronic ocular discharge
  - Affected patients try to mechanically remove the discharge, either with their fingers or a cotton applicator, causing conjunctival trauma
  - The resulting traumatic conjunctivitis further increases the amount of discharge, creating a vicious cycle
  - An almost universal finding is conjunctival staining in the inferonasal quadrant of the bulbar conjunctiva, presumably because that is the easiest site to try to remove the discharge from the eye
  - These patients readily admit the problem when they are advised of the likely pathogenesis
  - Treatment is directed at the underlying condition, with the admonition to avoid manipulation of the eye

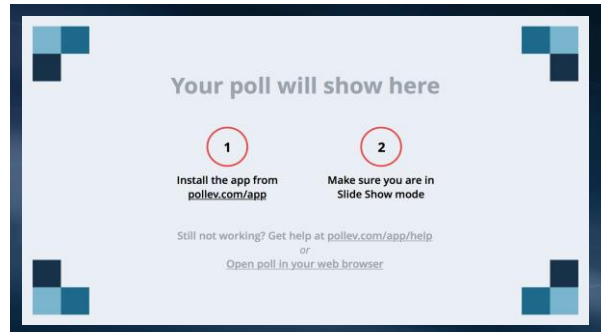




## Chronic Papillary Conjunctivitis Primarily Affecting the Upper Eyelid

### CPC Primarily Affecting the Upper Eyelid

- A number of causes of chronic conjunctivitis predominantly affect the upper tarsal conjunctiva and upper fornix
  - Floppy eyelid syndrome
  - Superior limbic keratoconjunctivitis (SLK)
  - Occult foreign body
  - Masquerade syndromes caused by sebaceous carcinoma more commonly occur on the upper lid

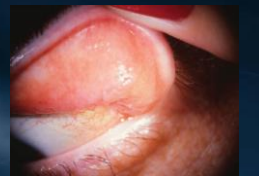

### Floppy Eyelid Syndrome

- Floppy eyelid syndrome is a disease that primarily affects middle-aged obese men
- A papillary reaction is seen on the upper tarsal conjunctiva, and there can be a mucopurulent discharge
- Generally a punctate keratopathy
- The unique feature of this disease is a hyperelastic, malleable tarsal plate
- The tarsus is easily folded, and the lid is easily everted by gentle traction on the lid in a superior and lateral direction
- Eyelash ptosis should alert clinician to investigate further

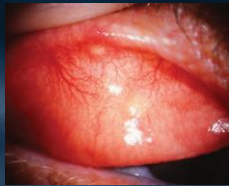
### Floppy Eyelid Syndrome

- Chronic exposure when the lid spontaneously everts during sleep
  - Usually asymmetric, with the more affected side being the side on which the patient preferentially sleeps
- One-third patients also have keratoconus
  - Eye rubbing may play a role in both diseases
- Strong association with OSA
- The diagnosis is made on clinical grounds
- Treatment directed at preventing nighttime eversion of the eyelid
  - Patching or shielding
- Permanent surgical approach to tighten the upper eyelid



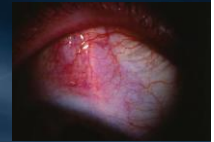## Superior Limbic Keratoconjunctivitis

- Chronic conjunctivitis that has unique characteristics
  - middle-age
  - Women > Men
  - Unilateral or bilateral (asymmetric)
- Symptoms include chronic redness, foreign body sensation, photophobia, and a scant discharge
- One-third of affected patients have a history of thyroid disease
  - Hyperthyroidism
- 25% have dry eye
- Fine, "velvety" papillary response on the upper tarsal conjunctiva, with the lower conjunctiva spared



## Superior Limbic Keratoconjunctivitis

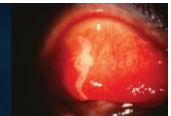
- Upper bulbar conjunctiva is hyperemic, with a leash of engorged blood vessels extending from the upper fornix to the limbus
- The superior bulbar conjunctiva usually appears redundant with folds
- Generally a band, 2 mm to 4 mm wide, just above the limbus that stains confluent with rose bengal or lissamine green dyes, and there is often a keratinized ridge at the upper limbus
- Usually a superior punctate or filamentary keratitis
- The diagnosis of SLK is based on the clinical findings
  - no laboratory tests to support the diagnosis



## Superior Limbic Keratoconjunctivitis

- Unknown etiology
  - Theory is the chronic trauma of the upper lid blinking over the redundant bulbar conjunctiva
- Treatment with local cautery and conjunctival resection, both of which lead a tight adhesion of the conjunctiva to the underlying sclera, support this theory
- Wide variety of topical treatments used w inconsistent degrees of success:
  - 0.5% to 1.0% silver nitrate solution to the upper tarsal and bulbar conjunctiva
  - Topical steroids
  - Lubricants
  - Punctal occlusion
  - Cyclosporine
  - Cromolyn sodium
  - NSAID's

## Occult Foreign Body



Ocular surface foreign bodies sometimes become sequestered in the upper conjunctival fornix

Because of the depth of the fornix and the fact that this area is not easily seen on examination, without double eversion of the eyelid, these foreign bodies can escape detection and persist, in some cases, for years

A number of different foreign bodies have been implicated in causing a variety of forms of inflammation, including conjunctival mass lesions, granulomas, and follicular conjunctivitis

## Bilateral Chronic Papillary Conjunctivitis

## Bilateral CPC

- The common causes of bilateral CPC are:
  - Blepharoconjunctivitis
    - Anterior Blepharitis
    - Posterior Blepharitis
  - Keratoconjunctivitis Sicca
  - Conjunctivochalasis
- These diseases commonly coexist and can have an interrelated pathogenesis leading to patient symptoms



## Case Report

- Treatment
  - Stop Latanoprost (continued TXE), Add lotemax BID
  - RTO 2 weeks
- Pt reports minimal improvement noted
  - Still 1-2+ inj with follicles
  - IOP 14, 15
  - Plan
  - Stop TXE and increase Lotemax Q2h
  - RTO 1 week, wrote Rx for Zioptan, but hold on starting
- Reports eyes finally feeling much better, and not as bothersome
  - Less injection and less papillary rxn
  - IOP 22, 26 (off all glc meds)
  - Start Zioptan, RTO 2 weeks
- Feeling beset yet, back to normal
  - Conj quiet
  - IOP 17, 18
  - Cont Zioptan QHS OU , eventually started Timoptic in Ocusose

## Conclusion

- By accurately identifying physical findings and categorizing cases of chronic conjunctivitis
- Remember Classification System
  - (1) Time course
  - (2) Morphology
    - Papillae
    - Large Papillae
    - Follicle
    - Membranous
    - Cicatrizing
  - (3) Localization of disease process
  - (4) Type of discharge or exudate
- Individual cases can be analyzed within a limited differential diagnosis
- Once an accurate diagnosis is made, treatment is generally straightforward and successful



Thank you



Please feel free to contact us:

Nicholas Colatrella, OD, FAAO, Dipl AAO, ABO, ABCMO  
 NColatrella@pineconevisioncenter.com

Jeffrey Varanelli, OD, FAAO, Dipl ABO, ABCMO  
 SECRVOD@gmail.com