

An Atlas of Lumps and Bumps: Part 20

Alexander K.C. Leung, MD^{1,2} —Series Editor • Benjamin Barankin, MD³ • Joseph M. Lam, MD⁴ • Amy A.M. Leung, MD⁵ • Kin Fon Leong, MD⁶

Syringomas

The word "syringoma" is derived from the Greek word "syrinx" meaning tube or pipe.¹ Syringomas are common, benign, sweat gland tumors that originate from the straight intradermal portion of the eccrine sweat duct.^{2,3} Histologically, multiple small and dilated eccrine ducts within a dense fibrous stroma are characteristic features.⁴

Syringomas usually present during puberty or the third and fourth decades of life.^{3,5} The reported prevalence ranges from 0.6% to 1% of the population.^{1,6} The prevalence is higher in Asians and Africans.⁷ The female-to-male ratio is approximately 2:1 in most studies.³ Most cases occur sporadically, although familial cases have been described.⁸ Familial cases may have an autosomal-dominant mode of inheritance.^{8,9} The condition is more common in patients with Down syndrome,

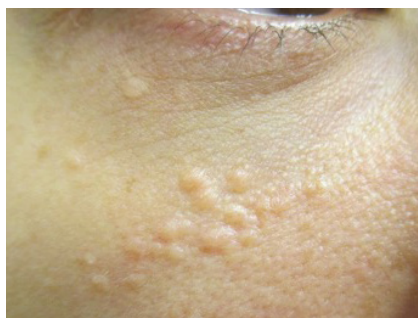

Figure 1. Syringomas present as small, soft, skin-colored to slightly yellowish papules.

Ehlers-Danlos syndrome, Costello syndrome, Marfan syndrome, Nicolau-Balus (syringomas, milia, and atrophoderma vermiculata) syndrome, alopecia (cicatricial alopecia and rarely alopecia areata), and type 2 diabetes.^{10,11}

Typically, syringomas present as small, soft, skin-colored to slightly yellowish papules (**Figures 1 and 2**).^{5,12} The papules

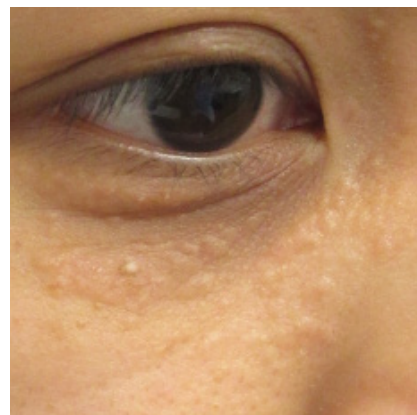


Figure 2. Syringomas are usually 1 to 3 mm in diameter, asymptomatic, and symmetrically distributed.

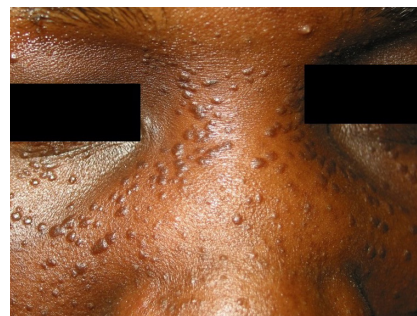

Figure 3. Generalized syringomas can present on the face but are more common on the neck and trunk.

are usually 1 to 3 mm in diameter, asymptomatic, and symmetrically distributed.³ The lesions may be solitary or, most often, multiple. The distribution may be localized or generalized. Localized syringomas are the most common clinical variant, and the lesions are typically observed in the periorbital region, especially infraorbitally (**Figures 1 and 2**).^{13,14} Generalized syringomas are found mainly on the neck and trunk, followed by the forearms (**Figures 3 and 4**).⁵ However, syringomas may appear on other body areas such as the penis,

AFFILIATIONS:

¹Department of Pediatrics, University of Calgary, Calgary, Alberta, Canada

²Alberta Children's Hospital, Calgary, Alberta, Canada

³Toronto Dermatology Centre, Toronto, Ontario, Canada

⁴Department of Pediatrics and Department of Dermatology and Skin Sciences, University of British Columbia, Vancouver, British Columbia, Canada

⁵Medical staff, Asian Medical Clinic, an affiliate with the University of Calgary Medical Clinic, Calgary, Alberta, Canada

⁶Pediatric Institute, Kuala Lumpur General Hospital, Kuala Lumpur, Malaysia

CITATION:

Leung AKC, Barankin B, Lam JM, Leong KF. An atlas of lumps and bumps, part 20. *Consultant*. 2022;62(9):e29-e32. doi:10.25270/con.2022.07.000013

DISCLOSURES:

Dr Leung is the series editor. He was not involved with the handling of this paper, which was sent out for independent external peer review.

CORRESPONDENCE:

Alexander K. C. Leung, MD, #200, 233 16th Ave NW, Calgary, AB T2M 0H5, Canada (aleung@ucalgary.ca)

EDITOR'S NOTE:

This article is part of a series describing and differentiating dermatologic lumps and bumps. To access previously published articles in the series, visit <https://www.consultant360.com/resource-center/atlas-lumps-and-bumps>.

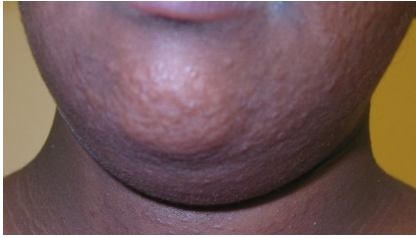


Figure 4. Generalized syringomas are found mainly on the neck and trunk, followed by the forearms.

vulva, axillae, and buttocks.^{13,15-17} Generally, patients with generalized syringomas are younger than those with localized syringomas.⁵

Eruptive syringoma is a rare variant that typically presents as multiple skin-colored, pink, or yellow-brown papules and appear in successive crops on the anterior parts of the neck, chest, abdomen, axillae, upper extremities, and genital areas in addition to the usual site on the face.^{2,5,14,18,19} In contrast to classic syringomas, eruptive syringomas occur most frequently before or around puberty, especially after an inflammatory condition, and may be associated with pruritus.^{2,6,18} Some authors categorize eruptive syringomas as a hyperplastic response to an inflammatory reaction rather than a true adnexal neoplasm.²⁰ Other rare variants include plaque-like, urticaria pigmentosa-like, lichen planus-like, milia-like, and unilateral linear nevoidal-like syringomas.^{11,21,22}

Milia

Milia are benign, transient, superficial keratinous cysts.²³ They present as asymptomatic, small (generally less than 3 mm), firm, white to yellow, smooth, dome-shaped papules.²⁴ Histologically, they appear as small infundibular cysts that are lined with stratified squamous epithelium with a granular cell layer.²⁵ The cyst contains laminated layers of keratin. Milia may arise spontaneously without a known cause (primary milia) or secondary to various processes (secondary milia). Primary milia may be congenital (congenital primary milia) or have an onset later in life (benign primary milia of children and adults).

Congenital primary milia are present in

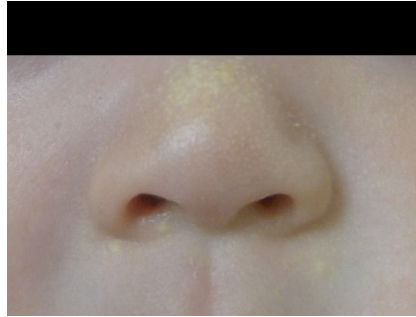

Figure 5. Congenital primary milia favor the nose.

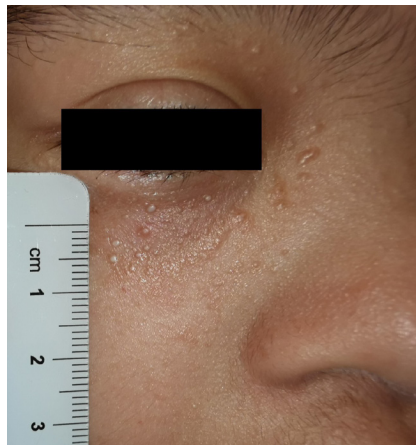


Figure 6. Benign primary milia of children favor the eyelids.

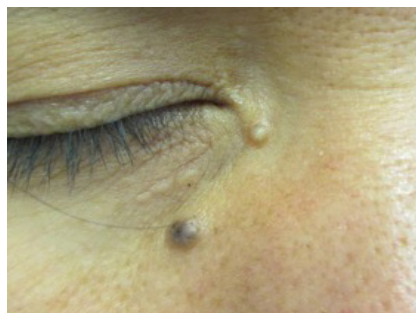

Figure 7. Benign primary milia of adults favor the eyelids and periorcular areas.

40 to 50% of newborn infants with no sex predilection.²⁶ The condition is less common in premature infants.^{23,25} Its onset in premature infants could be delayed by several weeks.²³ While congenital primary milia favor the nose (**Figure 5**), benign primary milia of children and adults favor the eyelids, periorcular areas, cheeks, and forehead (**Figures 6 to 8**).^{23,24} Other unusual sites of involvement include the nasal crease, trunk, extremities, vulva, glans

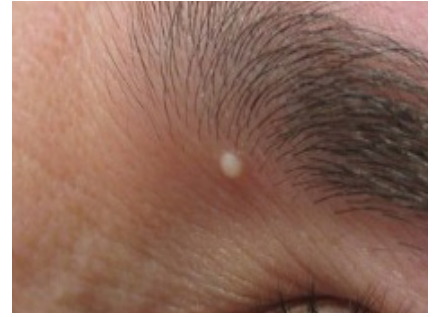

Figure 8. Benign primary milia of adults favor the eyelids and periorcular areas.

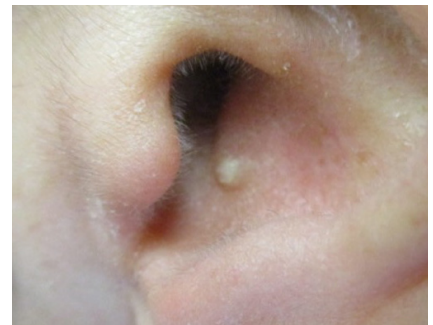

Figure 9. Benign primary milia of adults favor the eyelids and periorcular areas.

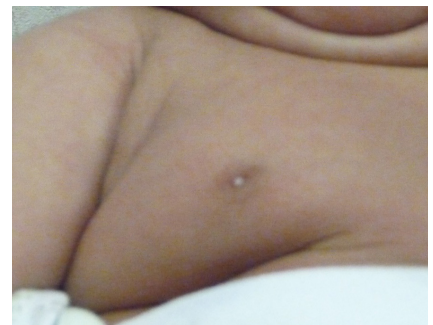

Figure 10. Unusual sites of involvement include the areola.

penis, auricle, and areola (**Figures 9 and 10**).^{23-25,27,28}

Primary milia may be a feature of trisomy 13, Gorlin-Goltz syndrome, Rombo syndrome, basal cell nevus syndrome, Bazex-Dupre-Christol syndrome, Basan syndrome, Brooke-Spiegler syndrome, Marie-Unna hypotrichosis (congenital hereditary trichodysplasia), Nicolau-Balus syndrome, pachyonychia congenita type 2 and oro-facial-digital syndrome type 1.^{23,25,29,30}

Multiple eruptive milia and milia en plaque are considered clinical variants of milia.^{31,32} Multiple eruptive milia are characterized by a sudden onset of multiple asymptomatic milia over a period of weeks to months, mainly on the head, neck, and trunk.³¹ Milia en plaque is characterized by numerous tiny milia on an erythematous plaque.³²⁻³⁴ The condition is asymptomatic and is most common in middle-aged individuals with a female predominance and no predilection for race.³² The periorcular area is most commonly affected.³³ Other sites of involvement include the postauricular area, nasal bridge, cheek, submandibular area, supraclavicular area, trunk, arms, and lower limbs.³²

Secondary milia usually occur in older children.²³ They may occur in association with systemic disease (eg, porphyria cutanea tarda, epidermolysis bullosa, lichen planus, discoid lupus erythematosus, bullous pemphigoid), medication use (eg, topical corticosteroids, oral cyclosporine, oral 5-fluorouracil, oral isotretinoin, oral dovitinib, oral vemurafenib, oral penicillamine), photodynamic therapy use, radiotherapy use, or trauma (chemical peels, dermabrasion, tattoos, burns, skin grafts).³⁵⁻⁴⁷

REFERENCES

1. Yaldiz M, Cosansu C, Erdem MT, Dikicier BS, Kahyaoglu Z. Familial eruptive syringoma. *Hong Kong Med J*. 2018;24(2):200-202. doi:10.12809/hkmj144415
2. Avhad G, Ghuge P, Jerajani HR. Generalized eruptive syringoma. *Indian J Dermatol*. 2015;60(2):214. doi:10.4103/0019-5154.152586
3. Nosrati N, Coleman NM, Hsu S. Axillary syringomas. *Dermatol Online J*. 2008;14(4):13. doi:10.5070/D34jt089ht
4. Kon Fessa C, Sharma R, Fernández-Peñas P. What is your diagnosis? Eruptive syringoma. *Cutis*. 2014;93(1):9-32.
5. Ghanadan A, Khosravi M. Cutaneous syringoma: a clinicopathologic study of 34 new cases and review of the literature. *Indian J Dermatol*. 2013;58(4):326. doi:10.4103/0019-5154.113956

6. Oztürk F, Ermertcan AT, Bilaç C, Temiz P. A case report of postpubertal eruptive syringoma triggered with antiepileptic drugs. *J Drugs Dermatol*. 2010;9(6):707-710.
7. Ong GC, Lim KS, Chian LY. Eruptive syringoma in a patient with trisomy 21. *Singapore Med J*. 2010;51(2):e46-e47.
8. Lau J, Haber RM. Familial eruptive syringomas: case report and review of the literature. *J Cutan Med Surg*. 2013;17(2):84-88. doi:10.2310/7750.2012.12027
9. Marzano AV, Fiorani R, Girgenti V, Crosti C, Alessi E. Familial syringoma: report of two cases with a published work review and the unique association with steatocystoma multiplex. *J Dermatol*. 2009;36(3):154-158. doi:10.1111/j.1346-8138.2009.00613.x
10. Garrido-Ruiz MC, Enguita AB, Navas R, Polo I, Rodríguez Peralto JL. Eruptive syringoma developed over a waxing skin area. *Am J Dermatopathol*. 2008;30(4):377-380. doi:10.1097/DAD.0b013e318172e4ad
11. Wallace JS, Bond JS, Seidel GD, Samie FH. An important mimicker: plaque-type syringoma mistakenly diagnosed as microcystic adnexal carcinoma. *Dermatol Surg*. 2014;40(7):810-812. doi:10.1111/DSU.0000000000000042
12. Gordon D, Barankin B. Question: can you identify this condition? *Can Fam Physician*. 2008;54(8):1114-1122.
13. Ozdemir O, Sari ME, Sen E, Ozcanli G, Atalay C. Vulvar syringoma in a postmenopausal woman: A case report. *J Reprod Med*. 2015;60(9-10):452-454.
14. Botsali A, Caliskan E, Coskun A, Tunca M. Eruptive syringoma: Two cases with dermoscopic features. *Skin Appendage Disord*. 2020;6(5):319-322. doi:10.1159/000508656
15. Cohen PR, Tschen JA, Rapini RP. Penile syringoma: reports and review of patients with syringoma located on the penis. *J Clin Aesthet Dermatol*. 2013;6(6):38-42.
16. Nibhoria S, Tiwana KK, Yadav A. Vulvar syringoma: a rare case report. *J Clin Diagn Res*. 2014;8(8):FD06. doi:10.7860/JCDR/2014/10125.4731
17. Núñez-Troconis J, Vilorio de Alvarado ME. Syringoma of vulva: an unusual presentation. Clinical, morphological and immunohistochemical aspects. *Invest Clin*. 2015;56(1):60-65.
18. Jha AK, Sinha R, Prasad S, Sinha R. Generalized eruptive syringoma: A clinical dilemma. *Indian Dermatol Online J*. 2016;7(2):127-128. doi:10.4103/2229-5178.178082
19. Singh S, Tewari R, Gupta S. An unusual case of generalised eruptive syringoma in an adult male. *Med J Armed Forces India*. 2014;70(4):389-391. doi:10.1016/j.mjafi.2012.04.022
20. Guitart J, Rosenbaum MM, Requena L. 'Eruptive syringoma': a misnomer for a reactive eccrine gland ductal proliferation? *J Cutan Pathol*. 2003;30(3):202-205. doi:10.1034/j.1600-0560.2003.00023.x
21. Lee JH, Lee JH, Lee JH, Kim GM, Kim SY. Linearly distributed syringoma: a case report. *J Dermatol*. 2013;40(8):666-667. doi:10.1111/1346-8138.12145
22. Mitkov M, Balagula Y, Taube JM, Lockshin B. Plaque-like syringoma with involvement of deep reticular dermis. *J Am Acad Dermatol*. 2014;71(5):e206-207. doi:10.1016/j.jaad.2014.04.005
23. Gallardo Avila PP, Mendez MD. Milia. In: *StatPearls*. StatPearls Publishing; March 15, 2022. <https://www.ncbi.nlm.nih.gov/books/NBK560481/>
24. Kansal NK, Agarwal S. Neonatal milia. *Indian Pediatr*. 2015;52(8):723-724.
25. Berk DR, Bayliss SJ. Milia: a review and classification. *J Am Acad Dermatol*. 2008;59(6):1050-1063. doi:10.1016/j.jaad.2008.07.034
26. Firouzi H, Jalalimehr I, Ostadi Z, Rahimi S. Cutaneous lesions in Iranian neonates and their relationships with maternal-neonatal factors: A prospective cross-sectional study. *Dermatol Res Pract*. Published online May 5, 2020. doi:10.1155/2020/8410165
27. Adotama P, Susa J, Glass DA 2nd. Primary milia localized to the vulva. *Dermatol Online J*. Published online April 16, 2014. doi:10.5070/D3204022339
28. Ferreira MG, Salgado MB. Congenital milium of the nipple. *Pediatr Dermatol*. 2017;34(1):e28-e29. doi:10.1111/pde.13010
29. Larsen AK, Mikkelsen DB, Hertz JM, Bygum A. Manifestations of Gorlin-Goltz syndrome. *Dan Med J*. 2014;61(5):A4829.
30. Sugimoto A, Kurokawa T, Kishi K, Yasuda E, Tamai H, Moriwaki S. Generalized milia in an infant with full trisomy 13. *J Derma-*

- tol. 2014;41(8):763-764. doi:10.1111/1346-8138.12550
31. Fett N, Nevas J. Multiple eruptive milia. *Cutis*. 2013;91(4):191-192.
 32. Zhang RZ, Zhu WY. Bilateral milia en plaque in a 6-year-old Chinese boy. *Pediatr Dermatol*. 2012;29(4):504-506. doi:10.1111/j.1525-1470.2011.01466.x
 33. Tian G, Liang Y, Wei Z, et al. Successful treatment of milia en plaque on the lip using microwave thermotherapy. *J Dermatol*. 2020;47(4):e128-e129. doi:10.1111/1346-8138.15249
 34. Zaouak A, Chamli A, Ben Jennet S, Hammami H, Fenniche S. Milia en plaque. *Presse Med*. 2019;48(12):1589-1590. doi:10.1016/j.lpm.2019.09.001
 35. Akasaka E, Nakano H, Takagi Y, Toyomaki Y, Sawamura D. Multiple milia as an isolated skin manifestation of dominant dystrophic epidermolysis bullosa: Evidence of phenotypic variability. *Pediatr Dermatol*. 2017;34(2):e106-e108. doi:10.1111/pde.13047
 36. Baek SW, Seo YJ, Lee HJ. Multiple milia associated with use of the tyrosine kinase inhibitor dovitinib. *Australas J Dermatol*. 2018;59(1):57-58. doi:10.1111/ajd.12620
 27. de Wet J, Jordaan HF, Visser WI. Bilateral malar milia en plaque as primary presentation of discoid lupus erythematosus. *JAAD Case Rep*. 2017;3(2):106-109. Published 2017 Mar 10. doi:10.1016/j.jdc.2017.01.010
 38. Farmer W, Cheng K, Marathe K. Eruptive milia during isotretinoin therapy. *Pediatr Dermatol*. 2017;34(6):728-729. doi:10.1111/pde.13270
 39. Flores-Climente V, Dalmau J, Puig L. Milia: An uncommon reaction to photodynamic therapy. *Actas Dermosifiliogr (Engl Ed)*. 2019;110(1):71-74. doi:10.1016/j.ad.2017.11.012
 40. Kimes K, Beasley K, Dalton SR. Eruptive milia and comedones during treatment with dovitinib. *Dermatol Online J*. 2015;21(9). doi:10.5070/D3219028692
 41. Kluger N. Eruptive milia and acneiform hyperkeratosis with comedones (pseudo-epidermal cysts) within tattoos. *Ann Dermatol Venereol*. 2019;146(12):801-806. doi:10.1016/j.annder.2019.01.026
 42. Kumudhini S, Rao R, Pai K, Shetty S, Pai S. Extensive milia formation in a young woman with bullous pemphigoid. *Indian J Dermatol Venereol Leprol*. 2018;84(2):248. doi:10.4103/ijdv.IJDVL_402_16
 43. Miller LM, Schwartz JT, Cho S. Milia: a unique reaction to tattoos. *Cutis*. 2011;87(4):195-196.
 44. Nguyen LH, Khamisa K. Porphyria cutanea tarda presenting as milia and blisters. *CMAJ*. 2018;190(20):E623. doi:10.1503/cmaj.180152
 45. Ross N, Farber M, Sahu J. Eruptive milia within a tattoo: A case report and review of the literature. *J Drugs Dermatol*. 2017;16(6):621-624. <https://jddonline.com/articles/eruptive-milia-within-a-tattoo-a-case-report-and-review-of-the-literature-S1545961617P0621X/>
 46. Sambrano BL, Riddel CE, Chon SY. Eruptive milia secondary to vemurafenib. *J Am Acad Dermatol*. 2013;69(5):e258-e260. doi:10.1016/j.jaad.2013.06.031
 47. Yeo L, Husain E, Hewitt J. Actinic lichen planus with milia. *Clin Exp Dermatol*. 2015;40(5):571-572. doi:10.1111/ced.12551