

Intravascular Papillary Endothelial Hyperplasia Involving the Hand: A Case Report of a Rare Entity

Review began 12/09/2023

Review ended 12/17/2023

Published 12/21/2023

© Copyright 2023

Albazali et al. This is an open access article distributed under the terms of the Creative Commons Attribution License CC-BY 4.0., which permits unrestricted use, distribution, and reproduction in any medium, provided the original author and source are credited.

Abeer Albazali ¹, Alsadat Mosbeh ^{2,1}, Yashpal Manchanda ¹, Adnan Ahmad ¹, Fatmah Altaweel ¹, Yasmeen Mandani ¹, Ashok K. Sharma ¹

1. Department of Dermatology, Farwaniya Hospital, Ministry of Health, Kuwait, KWT 2. Department of Dermatology/Dermatopathology, Faculty of Medicine, Al-Azhar University, Cairo, EGY

Corresponding author: Abeer Albazali, dr.abeer1112@gmail.com

Abstract

Masson's tumor, also named intravascular papillary endothelial hyperplasia (IPEH), is a rare, benign vascular tumor. Evaluation by clinical features can be confused with other soft tissue tumors. Therefore, the diagnosis should be confirmed by histopathological examination.

The patient reported here is 67 years old and came to us with a small painful lesion over the left thumb of about two months duration. Histopathological examination was consistent with Masson's tumor (IPEH) following excisional biopsy, with good functional outcomes.

To the best of our knowledge, this is the first report of this entity from Kuwait. Dermatologists and surgeons should know about this rare entity and its unusual presentation, to be able to distinguish it from similar presenting serious conditions, especially angiosarcoma. Through this report, we purport to facilitate recognition of this condition apart from some other conditions it may mimic.

Categories: Plastic Surgery, Dermatology, General Surgery

Keywords: thumb lesion, excision, intravascular papillary endothelial hyperplasia (ipeh), subcutaneous nodule of hand, masson's tumor

Introduction

Masson's tumor, a rare benign neoplasm, also known as intravascular papillary endothelial hyperplasia (IPEH), can present over any part of the body, however, usually the head, neck, and upper extremities are involved [1]. This uncommon condition was first described in 1923 by Pierre Masson [2]. Although widely accepted to have no pathognomonic features [3], it usually presents as a small red or blue slow-growing nodule [4]. Today, it is not considered a true tumor but is thought to be a reactive hyperplastic vascular endothelium growth [5-7]. Surgical excision is the desirable method of treatment [1,8]. To the best of our knowledge, this is the first report of this rare entity from Kuwait.

Case Presentation

A 67-year-old Kuwaiti female, a known case of gastroesophageal reflux disease (GERD), irritable bowel syndrome (IBS), and osteoporosis, presented to our dermatology outpatient department complaining of a single small painful bluish lump that appeared on the left thumb two months ago. The lump was limited to the palmar aspect of the left thumb. There were no changes in the surrounding skin noted by the patient. Additionally, the patient denied any itchiness, bleeding, or discharge from the lump. The lesion was causing the patient discomfort and affecting her daily life activities.

On physical examination, there was a 2-mm, firm, bluish nodule on the distal palmar aspect of the left thumb, which was tender on palpation. There were no bruise-like patches in the overlying or adjoining skin. The surface of the lesion was smooth with no changes in the surrounding skin (Figures 1, 2). The Tinel sign was negative, and there was no paresthesia across the distribution of the affected neighboring digital nerve. There were no other similar lesions on the patient's right and left hands.

How to cite this article

Albazali A, Mosbeh A, Manchanda Y, et al. (December 21, 2023) Intravascular Papillary Endothelial Hyperplasia Involving the Hand: A Case Report of a Rare Entity. Cureus 15(12): e50902. DOI 10.7759/cureus.50902



FIGURE 1: The lesion on the patient's left thumb

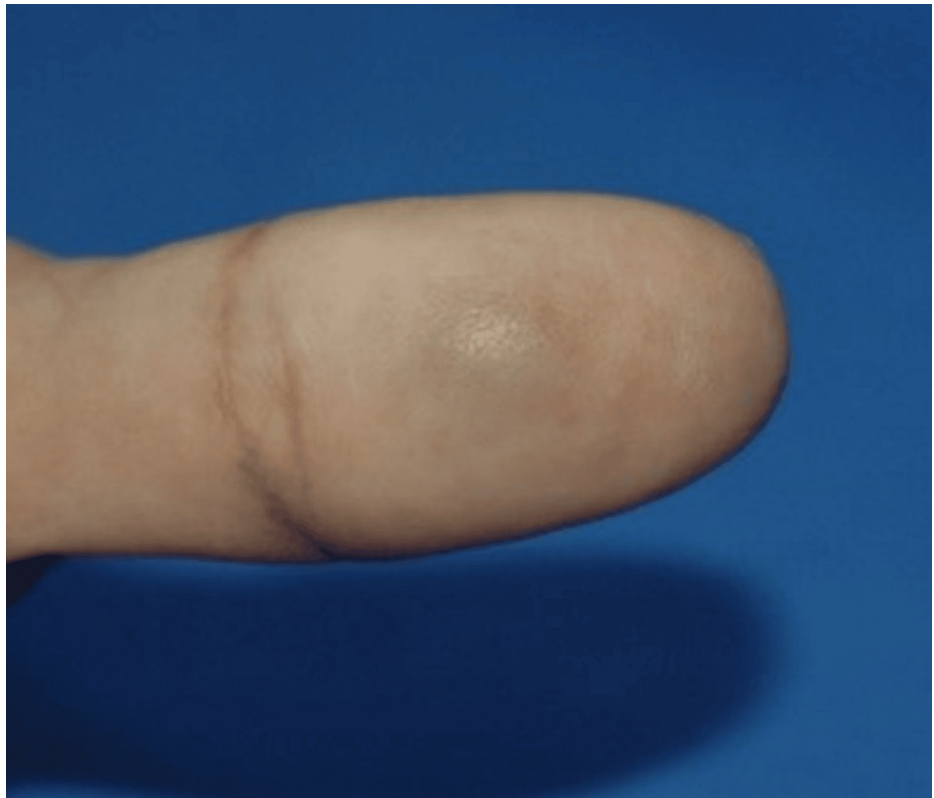


FIGURE 2: This is a close-up image of the lesion

The lesion was excised under local anesthesia (Figure 3).

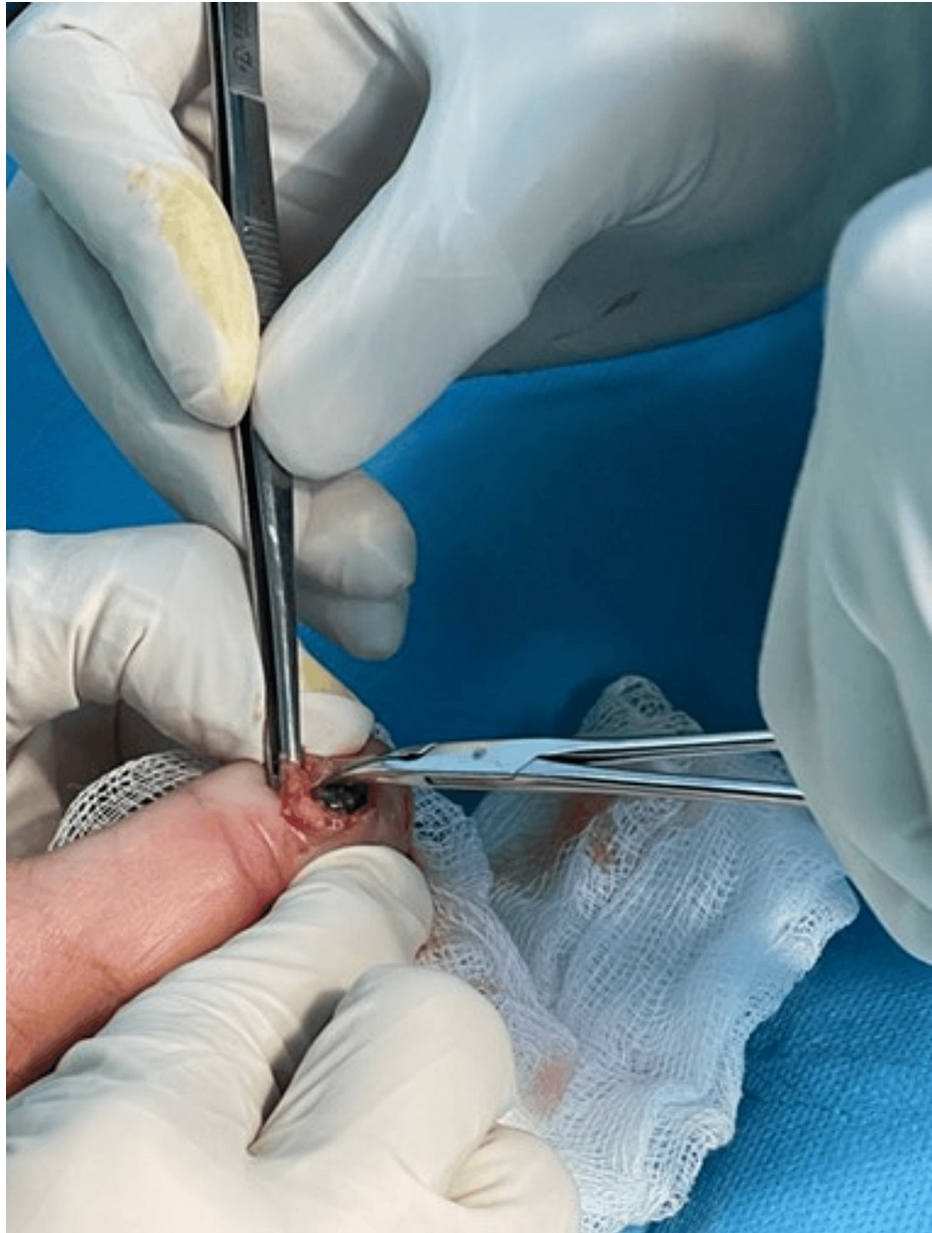

FIGURE 3: Intraoperative image of the lesion

The excised lesion was compassed, bluish, and rubber-like. The specimen was bisected and processed in one cassette (Figure 5). Histopathological examination (Figures 4, 5) revealed dilated vascular spaces with clotted blood and papillary endothelial proliferation inside the blood vessel's lumen. Papillae, composed of a single layer of endothelial cells with collagenized core were present. Anastomosing vascular channels lined with bland and plump endothelial cells were also found; the endothelial cells were positive for CD31 (Figure 6). The histological diagnosis was consistent with IPEH (Masson's tumor).

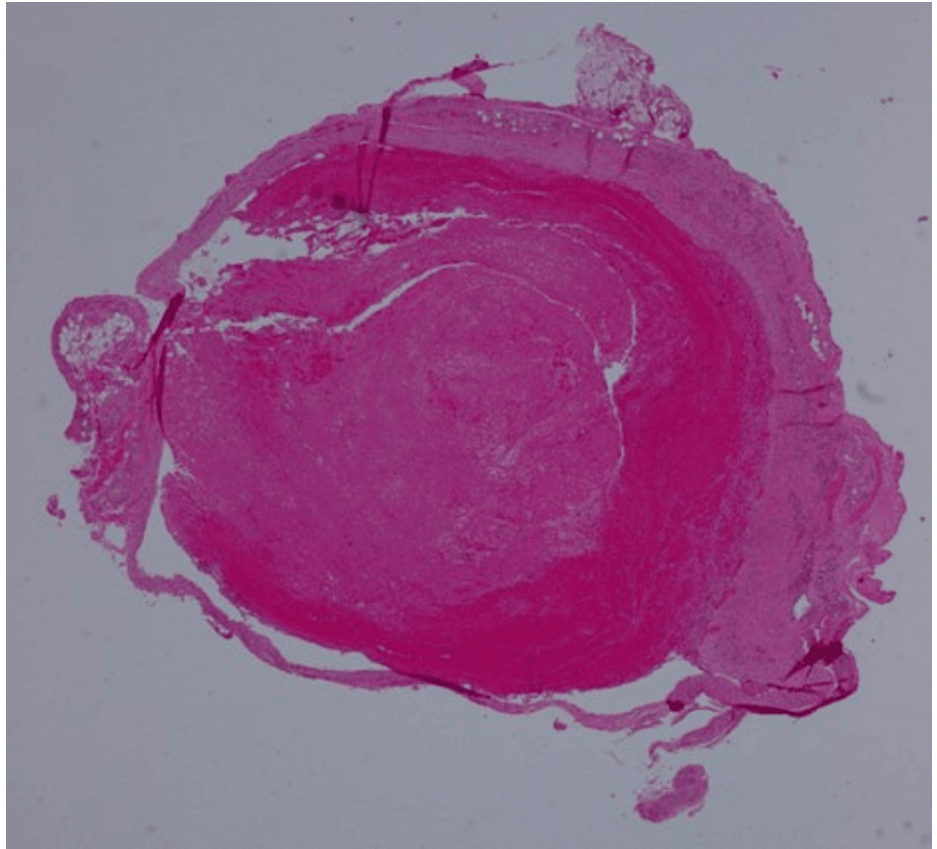


FIGURE 4: The vascular lesion showing intraluminal organizing thrombus (H&E, x20)

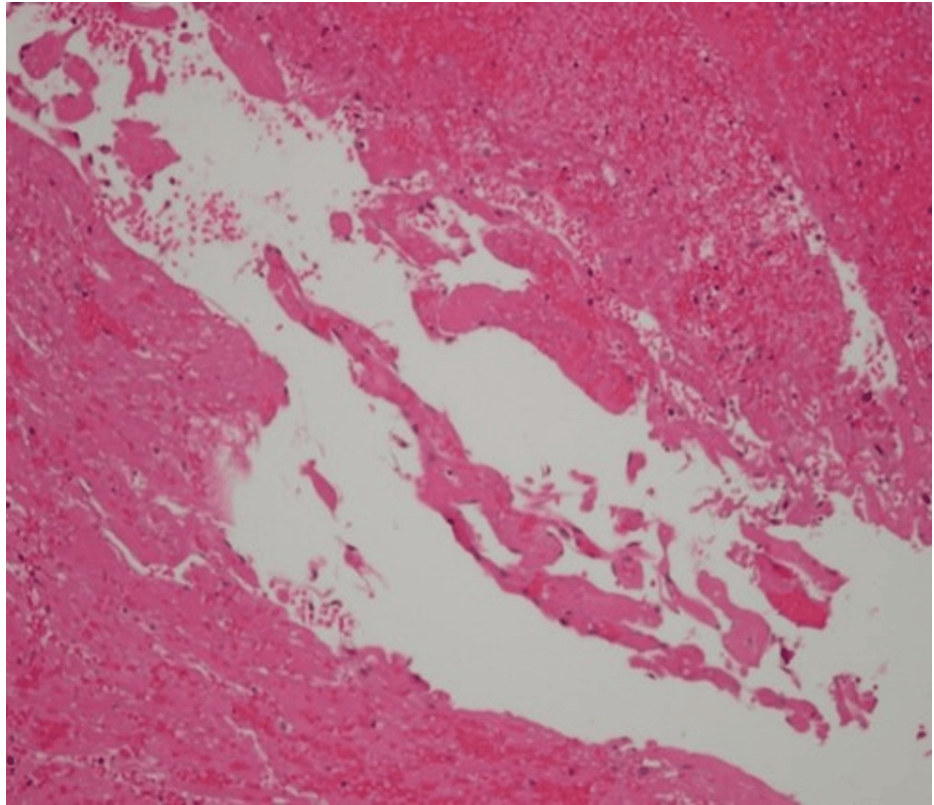


FIGURE 5: A focal intravascular papillary proliferation of plump endothelial cells with hyaline core (H&E, x40)

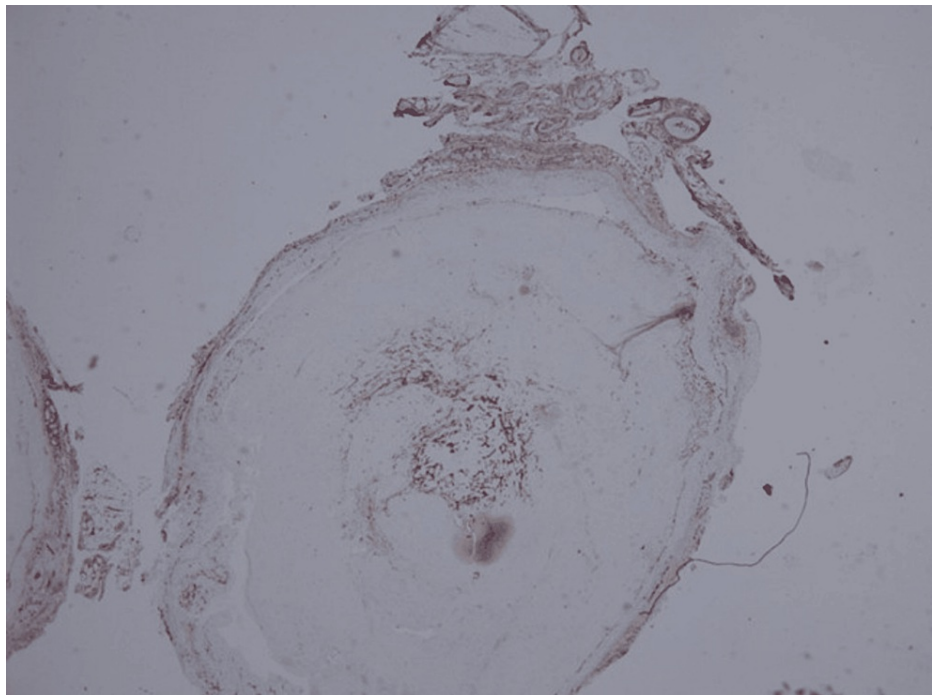


FIGURE 6: Endothelial cells positive for CD31 (x20)

CD31: cluster of differentiation 31

Subsequent follow-up of the patient showed that the area of excision healed with minimal post-inflammatory pigmentation (Figure 7). The patient expressed her satisfaction with the outcome of the

excisional surgical procedure.

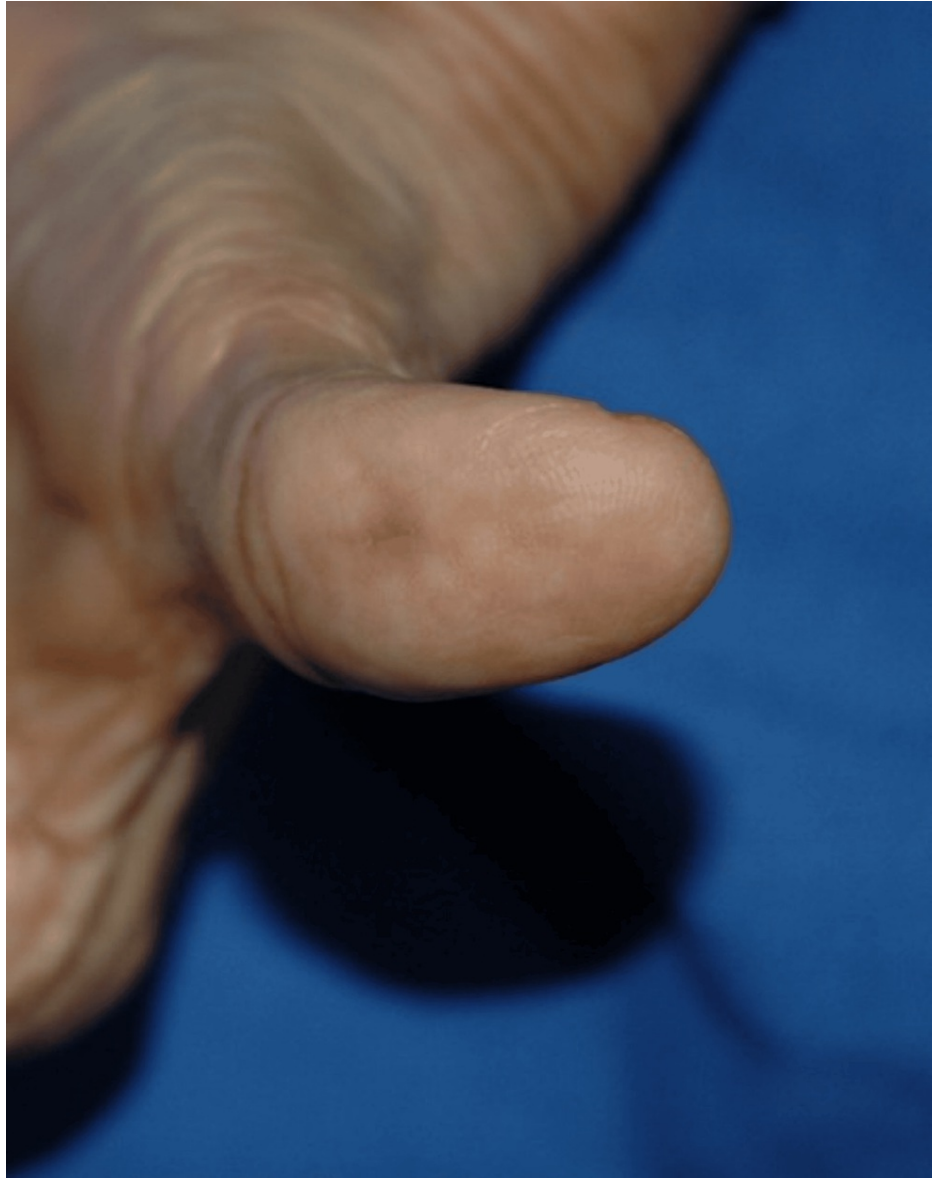

FIGURE 7: The wound three months following excision

Discussion

Papillary endothelial hyperplasia remains an uncommon benign vascular lesion that can occur in any vessel in the body. Approximately 2% of vascular tumors of the skin and soft tissues are caused by IPEH [9]. The pathophysiology of IPEH is not well understood, but the majority of current research suggests that it is caused by endothelial cells proliferating in blood vessels in response to post-traumatic thrombus formation, which is also linked to the organization and recanalization of thrombi. The order in which the disease advances is still debatable though; the primary process is either endothelial proliferation with subsequent thrombus development or the thrombus appears first and forges papillary proliferation [10].

The three differentiable IPEH subtypes are: (1) the primary type (56%) originates in dilated vascular spaces and presents with a small subcutaneous mass, frequently in fingers; (2) the secondary type (40%) develops in an antecedent vascular lesion like pyogenic granulomas, hemangiomas, or vascular malformations; and (3) the extravascular type (4%) evolves from a pre-existing hematoma, and these lesions are larger than the other-type lesions [10]. In our case, the lesion developed within a dilated vascular space, which is consistent with the primary subtype of IPEH.

The lesion frequently presents in the third and fourth decades of life with a predilection to females [10]. It often manifests as a small subcutaneous lump that may or may not be painful; the overlying skin may also

become blue or reddish in color [10]. However, our patient was in her seventh decade and her lesion was a painful bluish nodule.

Trauma frequently antecedes the development of this tumor; however, a clear history of trauma is elicitable in only 4% of the patients [11]. Any history of significant trauma was not forthcoming from our patient.

It is difficult to diagnose IPEH clinically, as there are no specific clinical findings, hence histopathological examination is the gold standard for diagnosing IPEH [12]. A significant histopathological feature of IPEH is the appearance of hyperplastic endothelial cells covering papillary structures, intravascularly. A close association with the organizing thrombus contributes to the diagnosis [10]. Our case showed features consistent with these. Ultrasound may help in differentiating IPEH from other soft tissue masses by detecting one or more vessels associated with the lesion [12].

Other benign and malignant vascular tumors, such as glomus tumor, glomerulovenous hemangioma, venous lake, blue nevus, neurogenic tumor, and angiosarcoma, should be distinguished from IPEH [10]. Despite IPEH's benign nature, it is important to have an accurate histopathological diagnosis based on its similarity with angiosarcoma, a tumor of the blood vessels. Angiosarcomas are usually not present within the blood vessel lumen, which is a key differentiating histopathological feature between angiosarcoma and IPEH. Moreover, IPEH endothelial cells are not necrotic but have prominent pleomorphism or major mitotic activity and uniformly formed sheets as opposed to angiosarcoma [10].

As IPEH does not advance to a malignant neoplasm and is not reported to recur after diligent surgical excision, the preferred treatment, with a favorable prognosis, is surgical excision [1,13]. The case that we are presenting here was treated with total surgical excision and there was no recurrence after six months of follow-up.

Conclusions

Masson's tumor or IPEH is an entity difficult to diagnose clinically. We report here an adult Kuwaiti female with a mass in the thumb histologically proven as IPEH, which was resected. There are no identifiable specific features to diagnose IPEH clinically. Therefore, histopathological examination is the gold standard for diagnosing IPEH. Also, a helpful aid in these cases could be a pre-operative ultrasound examination that may differentiate IPEH from other soft tissue masses. The message we would like to convey is that IPEH, a rare benign tumor composed of reactive endothelial cells and a thrombus within a vascular space, should be kept in mind when encountering a painful bluish skin lesion. Since Masson's tumor can mimic other skin lesions clinically, histopathology is a definitive technique for diagnosing IPEH. Surgical excision is the treatment of choice, and the prognosis is excellent with no recurrence if the excision is comprehensive.

Additional Information

Author Contributions

All authors have reviewed the final version to be published and agreed to be accountable for all aspects of the work.

Concept and design: Ashok K. Sharma, Abeer Albazali, Alsadat Mosbeh, Yashpal Manchanda

Acquisition, analysis, or interpretation of data: Ashok K. Sharma, Abeer Albazali, Alsadat Mosbeh, Yashpal Manchanda, Adnan Ahmad, Fatmah Altaweel, Yasmeen Mandani

Drafting of the manuscript: Ashok K. Sharma, Abeer Albazali, Adnan Ahmad, Fatmah Altaweel, Yasmeen Mandani

Critical review of the manuscript for important intellectual content: Ashok K. Sharma, Abeer Albazali, Alsadat Mosbeh, Yashpal Manchanda, Adnan Ahmad, Fatmah Altaweel, Yasmeen Mandani

Supervision: Ashok K. Sharma, Abeer Albazali, Alsadat Mosbeh, Yashpal Manchanda

Disclosures

Human subjects: Consent was obtained or waived by all participants in this study. **Conflicts of interest:** In compliance with the ICMJE uniform disclosure form, all authors declare the following: **Payment/services info:** All authors have declared that no financial support was received from any organization for the submitted work. **Financial relationships:** All authors have declared that they have no financial relationships at present or within the previous three years with any organizations that might have an interest in the submitted work. **Other relationships:** All authors have declared that there are no other relationships or activities that could appear to have influenced the submitted work.

References

1. Wagh VB, Kyprianou I, Burns J, Brown LJ, Vaidhyanath R, Sampath R: Periorbital Masson's tumor: a case series. *Ophthalmic Plast Reconstr Surg*. 2011, 27:e55-7. [10.1097/IOP.0b013e3181e978f4](https://doi.org/10.1097/IOP.0b013e3181e978f4)
2. Klonk I, Povoski SP, Tozbikian G, Hawley JR: Masson's tumor of the reconstructed breast. *Radiol Case Rep*. 2023, 18:1748-53. [10.1016/j.radcr.2023.01.081](https://doi.org/10.1016/j.radcr.2023.01.081)
3. Boukoulas S, Dillard R, Qiu S, Cole EL: Intravascular papillary endothelial hyperplasia (Masson's tumor): diagnosis the plastic surgeon should be aware of. *Plast Reconstr Surg Glob Open*. 2017, 5:e1122. [10.1097/GOX.0000000000001122](https://doi.org/10.1097/GOX.0000000000001122)
4. Branton PA, Lining R, Tavassoli FA: Papillary endothelial hyperplasia of the breast: the great impostor for angiosarcoma: a clinicopathologic review of 17 cases. *Int J Surg Pathol*. 2003, 11:83-7. [10.1177/106689690301100203](https://doi.org/10.1177/106689690301100203)
5. Hashimoto H, Daimaru Y, Enjoji M: Intravascular papillary endothelial hyperplasia. A clinicopathologic study of 91 cases. *Am J Dermatopathol*. 1983, 5:559-46. [10.1097/0000372-198312000-00004](https://doi.org/10.1097/0000372-198312000-00004)
6. Kuo T, Sayers CP, Rosai J: Masson's "vegetant intravascular hemangioendothelioma:" a lesion often mistaken for angiosarcoma: study of seventeen cases located in the skin and soft tissues. *Cancer*. 1976, 38:1227-36. [10.1002/1097-0142\(197609\)38:3<1227::aid-cnrcr2820380324>3.0.co;2-6](https://doi.org/10.1002/1097-0142(197609)38:3<1227::aid-cnrcr2820380324>3.0.co;2-6)
7. Pantanowitz L, Muc R, Spanger M, Sonnendecker H, McIntosh WA: Intravascular papillary endothelial hyperplasia (Masson's tumor) manifesting as a lateral neck mass. *Ear Nose Throat J*. 2000, 79:806, 809-10, 812 passim.
8. Font RL, Wheeler TM, Boniuk M: Intravascular papillary endothelial hyperplasia of the orbit and ocular adnexa. A report of five cases. *Arch Ophthalmol*. 1983, 101:1731-6. [10.1001/archophth.1983.01040020733014](https://doi.org/10.1001/archophth.1983.01040020733014)
9. Tedla M, Bežová M, Biró C, Tedlová E, Eng CY, Zeleník K: Intravascular papillary endothelial hyperplasia of larynx: case report and literature review of all head and neck cases. *Otolaryngol Pol*. 2014, 68:200-3. [10.1016/j.otpol.2014.03.002](https://doi.org/10.1016/j.otpol.2014.03.002)
10. Sung K, Jeong C, Lee S, Oh HY, Lee SY: Masson tumor of the heel fat pad. *Ann Plast Surg*. 2023, 90:636-9. [10.1097/SAP.0000000000000525](https://doi.org/10.1097/SAP.0000000000000525)
11. Wang CY, Hong CC, Huang ZY, Wang CH: Intravascular papillary endothelial hyperplasia along the intrinsic muscle after hand contusion injury: report of two cases. *Acta Orthop Traumatol Turc*. 2019, 53:154-6. [10.1016/j.aott.2018.07.003](https://doi.org/10.1016/j.aott.2018.07.003)
12. Almarghoub MA, Shah Mardan QN, Alotaibi AS, Ahmed NK, Alqahtani MS: Masson's tumor involving the hand: a case report. *Int J Surg Case Rep*. 2020, 70:223-6. [10.1016/j.ijscr.2020.04.069](https://doi.org/10.1016/j.ijscr.2020.04.069)
13. Dryden SC, Marsili S, Meador AG, Randall MB, Fowler B: Intravascular papillary endothelial hyperplasia of the orbit: a case of Masson's tumor. *Cureus*. 2019, 11:e6266. [10.7759/cureus.6266](https://doi.org/10.7759/cureus.6266)