

Ophthalmology Grand Rounds

Justin Gutman PL-2

July 21, 2011

Case Presentation

- ▣ 50 year old male who came to the KCH ED reporting 6 days of blurred vision in his left eye.
- ▣ He reports worse vision in the temporal half of his visual field
- ▣ Admits to some mild pain with eye mvmt.
- ▣ Denies any scalp pain, tenderness, jaw claudication.
- ▣ Denies flashing lights/floaters/curtains

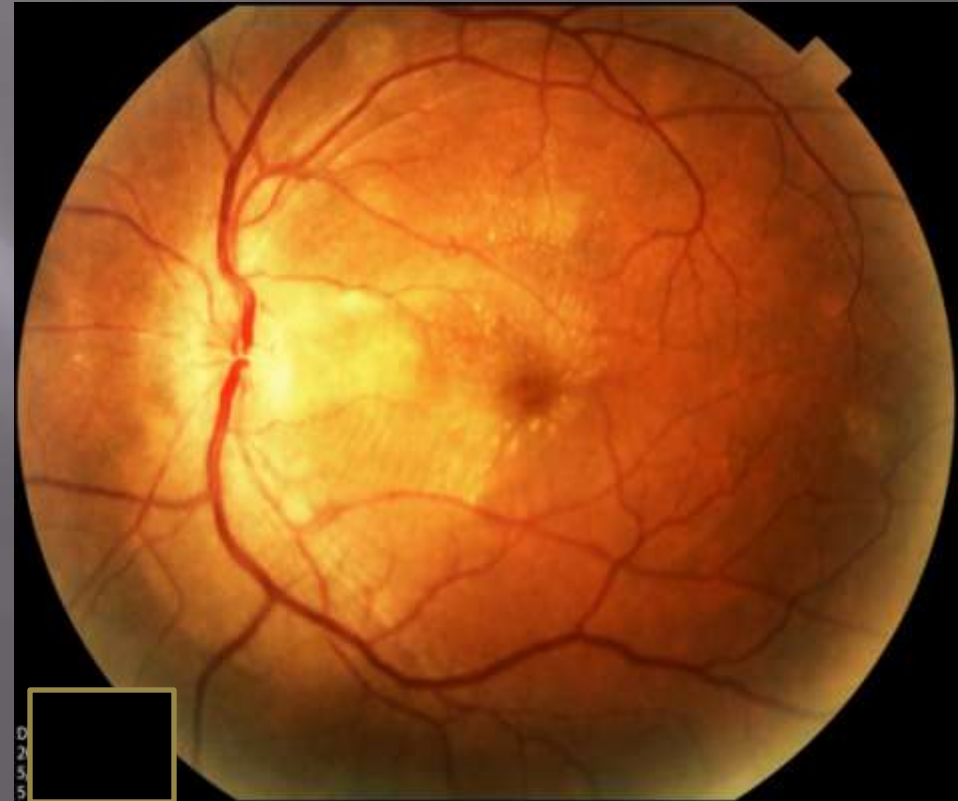
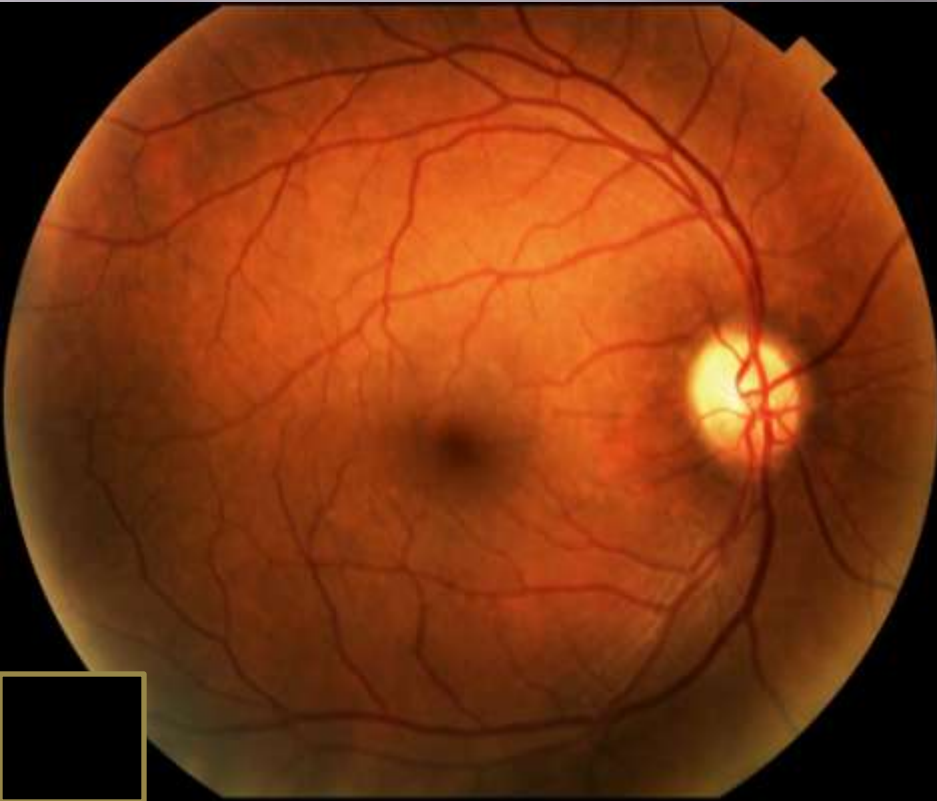
Case Presentation

- ▣ PMHx: No Diabetes or HTN.
- ▣ POHx: Refractive error. No trauma/surgery or prior similar episodes
- ▣ Meds: none
- ▣ FHx: no glaucoma or blindness
- ▣ Social: prior use of cocaine. Denies any IV drugs
- ▣ NKDA
- ▣ ROS: admits to occasional chills. Denies wt. loss or night sweats

Case Presentation

- ▣ Exam:
 - VAcc: 20/20, 20/150 PH NI
 - EOM: full ou. No diplopia
 - Pupils: 4-2 ou. NO APD
 - cVF: grossly full ou
 - Tapp: 11, 12
- ▣ SLE:
 - LLA: wnl ou
 - C/S: w and q ou
 - K: clear ou
 - A/C: d and q ou
 - P/I: r and r ou
 - L: NS ou

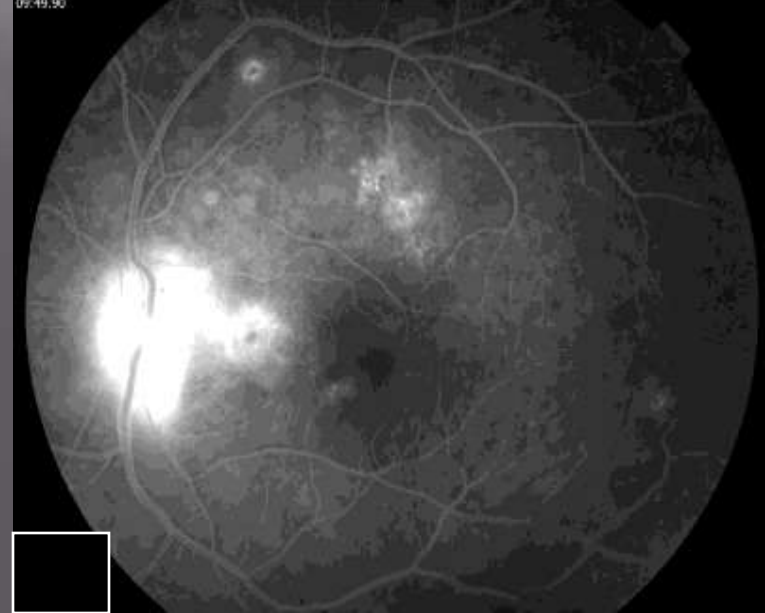
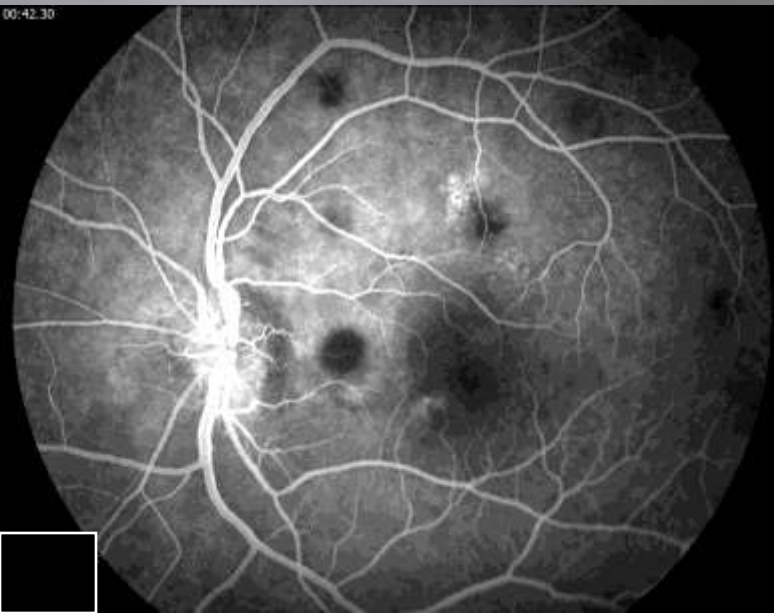
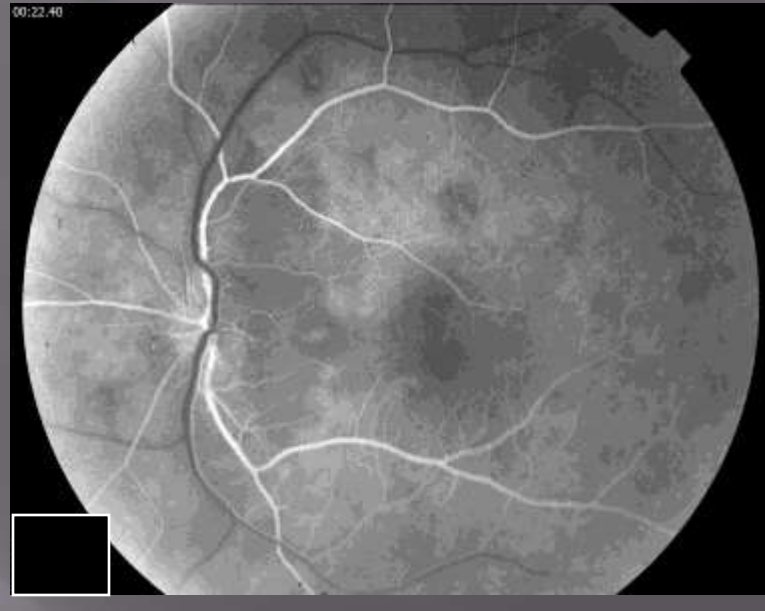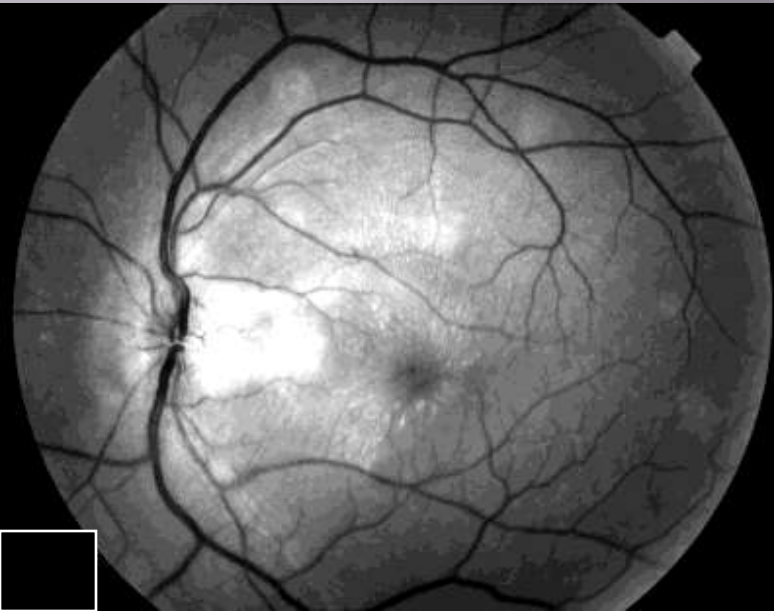
Dilated examination



Case presentation

- ▣ Dilated examination
 - V: clear ou. No evidence of vitritis ou
 - C/D:
 - ▣ OD: 0.4 pink and sharp.
 - ▣ OS: blurred disc margins with disc elevation and edema extending towards the macula
 - M: Flat od. Exudative detachment os with subretinal lesions near the disc and a stellate exudation surrounding the fovea
 - V/P: subretinal lesions seen along the superior arcade os

Flourescein Angiography

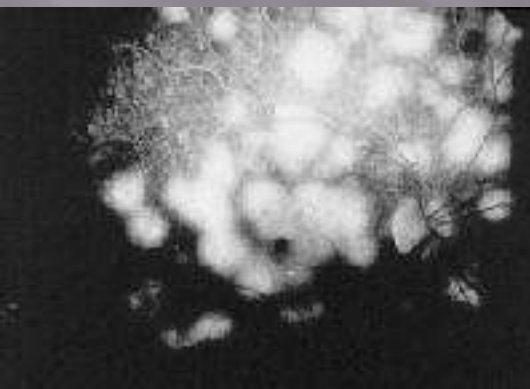
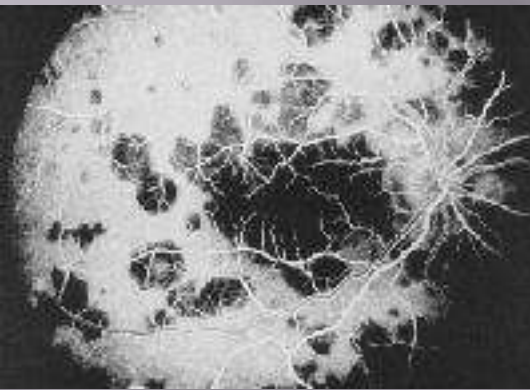
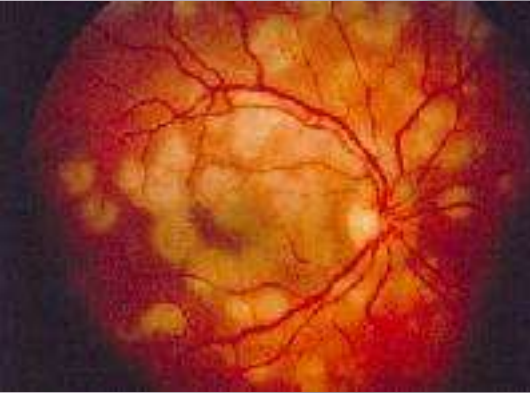

Patient care

Differential Diagnosis??


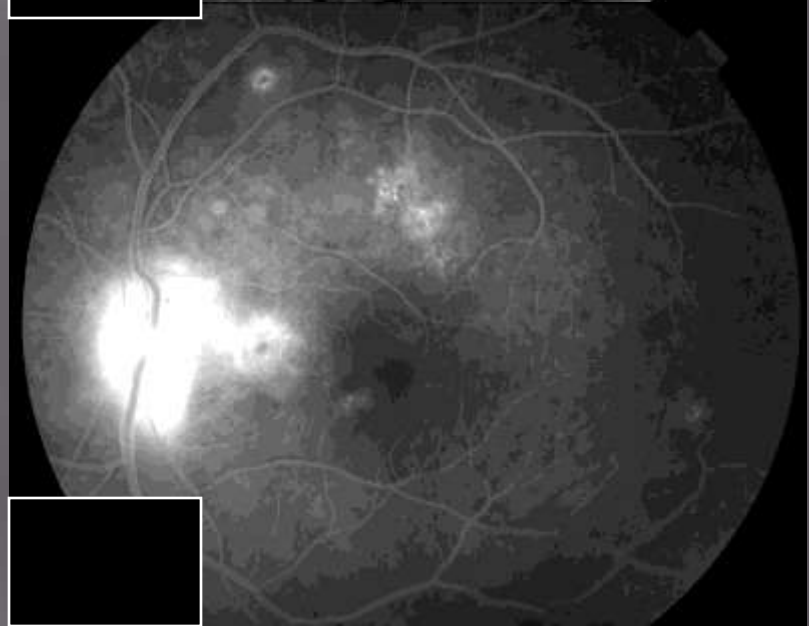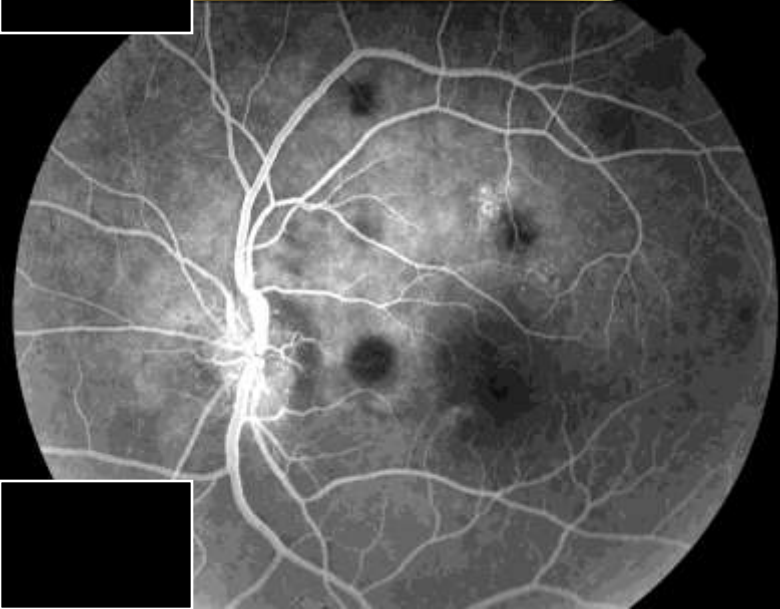

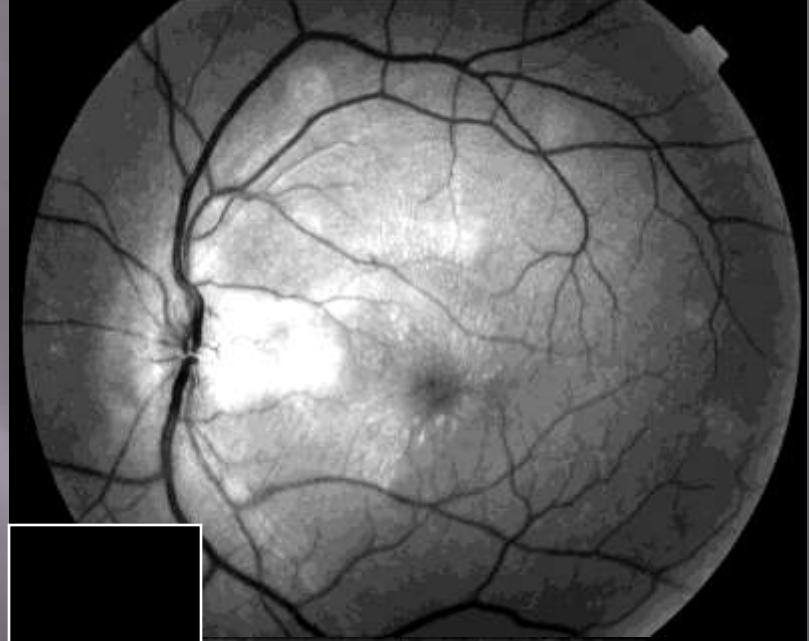

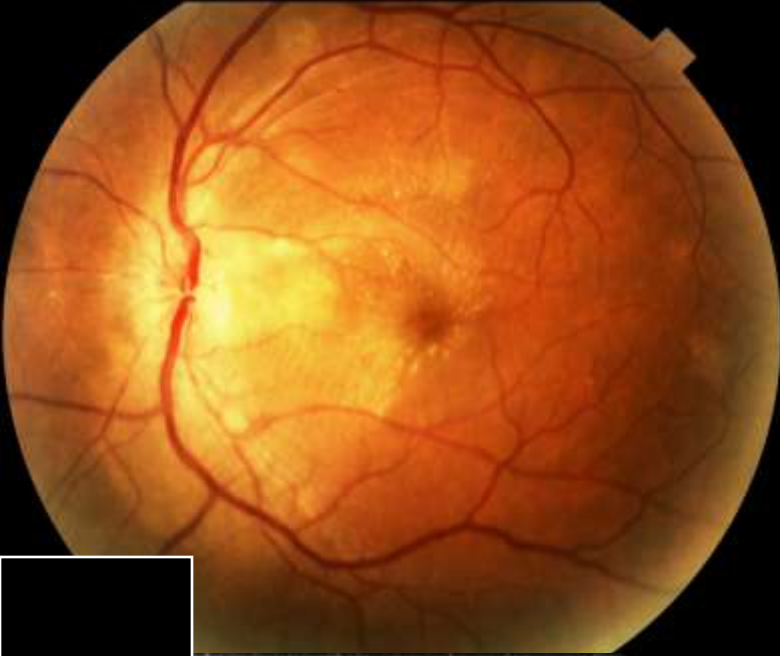
- ▣ Neuroretinitis
 - Diffuse Unilateral Subacute neuroretinitis(DUSN)
 - Cat Scratch Disease
 - TB
 - Lyme
 - Syphilis
 - Sarcoid
 - Leptospirosis
 - Toxocara canis
 - Lebers Idiopathic Stellate Neuroretinitis
 - Vogt-Koyanagi-Harada Disease
- ▣ Hypertension
- ▣ Diabetes
- ▣ APMPPE/Serpiginous...

Acute Posterior Multifocal Placoid Pigment Epitheliopathy

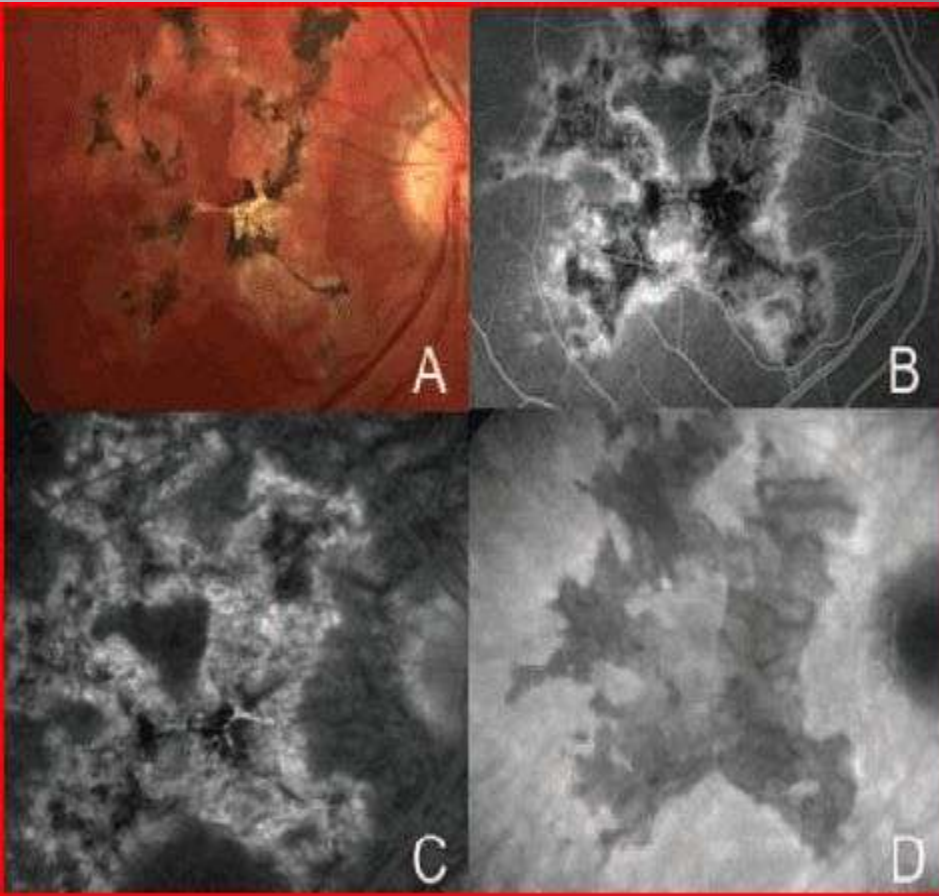


- Inflammatory disease, typically affecting the choriocapillaris, RPE, and outer retina in otherwise healthy adults
- Frequently occurs in young adults with an average age of onset of 27, affecting both men and women equally.
- Painless loss of vision (typically with absence of anterior or vitreous inflammation)
- Typically bilateral, but may be unilateral
- Dx by clinical presentation and FA (early hypofluorescence, later hyperfluorescence)
- Disease course:
Vision loss may be preceded by flu-like systemic symptoms
Placoid lesions can be observed in the posterior pole that will opacify over 2-3 weeks.
Visual function will then spontaneously improve, often to baseline
- Rarely, one may observe **optic disc edema** and an episcleritis.
- Systemically one might observe erythema nodosum as well as cerebral vasculitis
- ass with HLA DR2 and HLA B7 suggesting genetic predisposition

Case Presentation


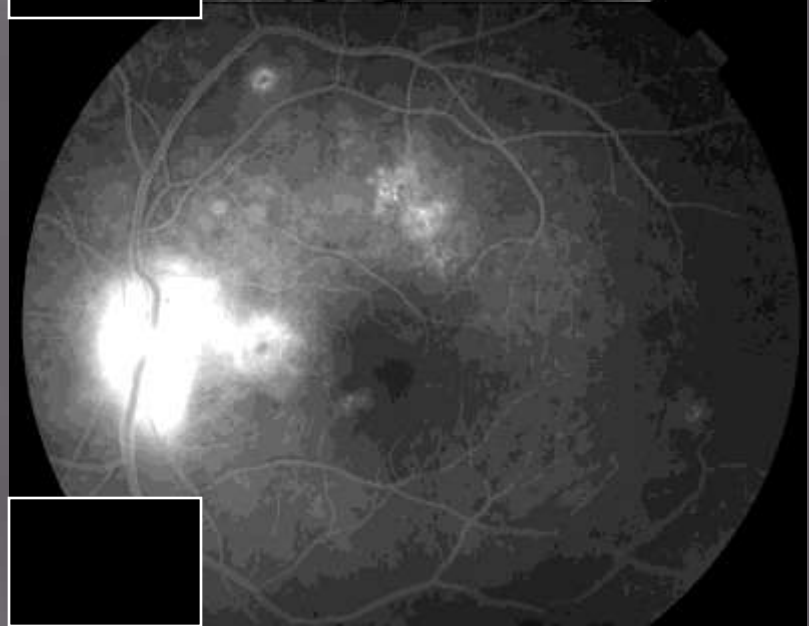

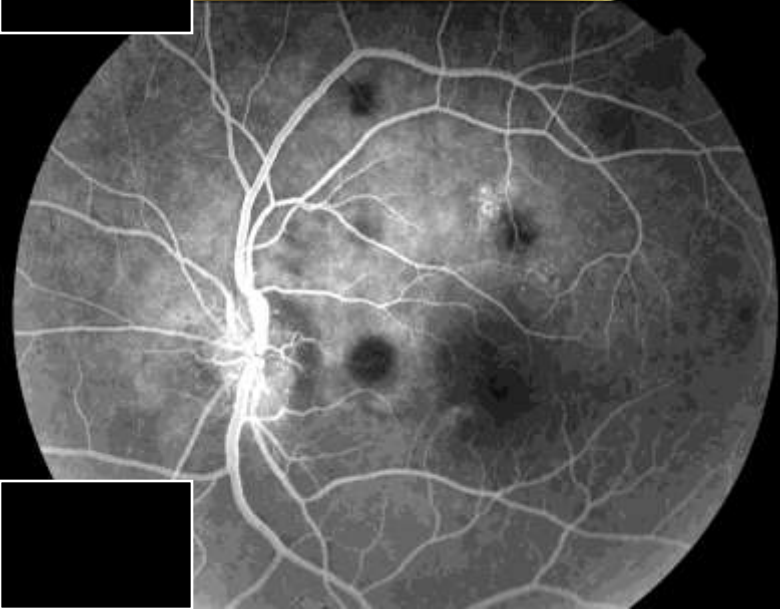

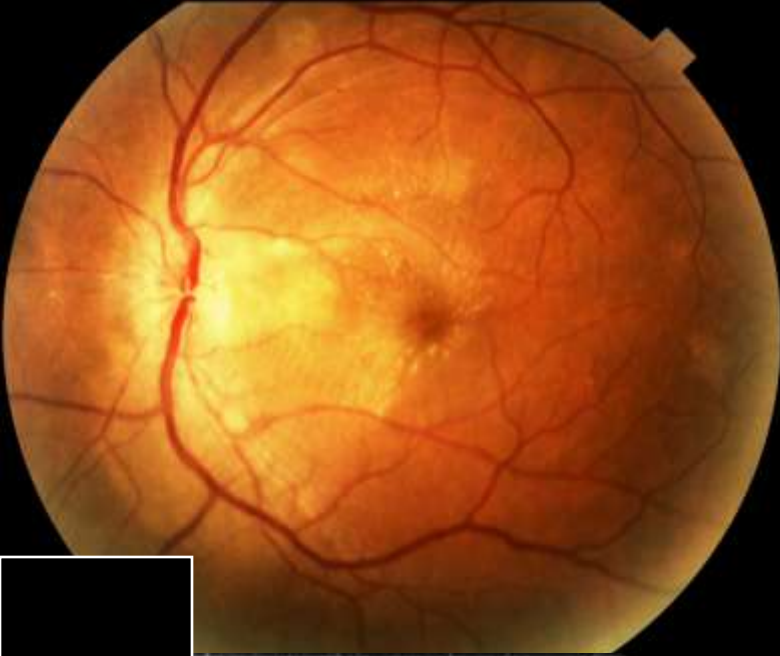


Serpiginous Choroiditis



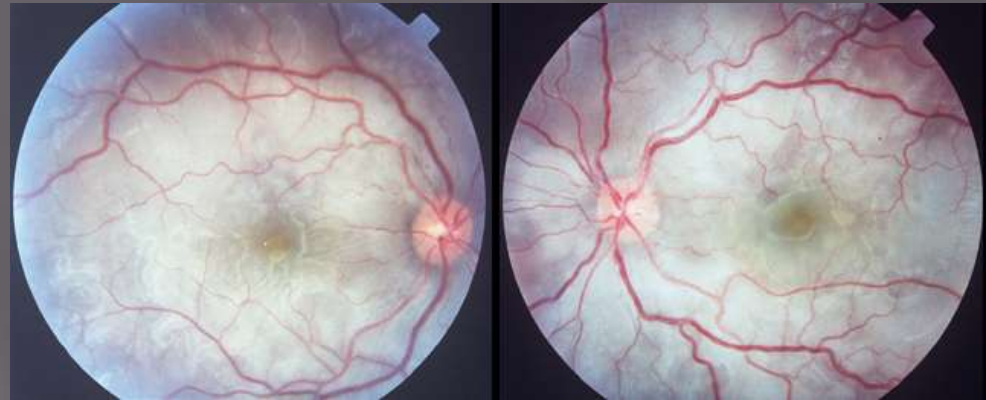- Most commonly affects middle aged males
- May be unilateral or bilateral
- Clinically, one will observe active lesions at the border of inactive lesions, spreading outward from the optic disc that frequently involves the macula
- 30% present with a mild vitritis
- Dx with clinical presentation and FA. Typically will observe hypofluorescence in the middle of the lesions, with hyperfluorescence at the periphery (B and C). ICG will have a “brushfire” appearance
- With involvement of the foveal center, treatment with immunosuppressive agents such as prednisone, azathioprine, or cyclosporine is recommended
- Poor prognosis with foveal involvement as scarring and atrophy result in poor visual recovery
- Frequently this disease is recurrent
- Beware choroidal NV as a further complicating factor- consider Photocoagulation of extrafoveal lesions

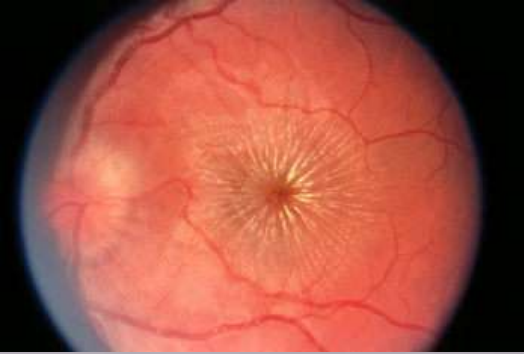
Case Presentation



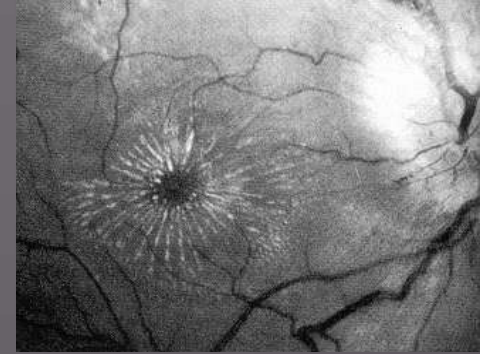
Vogt-Koyanagi-Harada

- Multi-system disorder with granulomatous panuveitis (often granulomatous with mutton fat KPs), and exudative RD
- loss of melanocytes from skin, ear, meninges, uvea-vitiligo, poliosis, hearing loss
- Often Asian, middle eastern, hispanic, native american population. In Japan, VKH accounts for up to 8% of uveitis
- Female > Male (2:1)
- Age 20-50
- Unclear mechanism of disease. Presents with fever, headache, meningismus, Nausea, vomiting, orbital pain, tinnitus, photophobia
- 70% with bilateral blurred vision within several days following prodrome and lasts for weeks
- Chronic stage- depigmentation of skin, dalen-fuchs nodules develop in midperipheral retina, vitiligo, poliosis of lashes, brows, hair. Chronic stage lasts from months to years without treatment
- Recurrence: often relapse with anterior uveitis or low grade choroidal inflammation. Rarely with serous RD
- HLA DR4, DR 53, DQ4
- Beware CNV

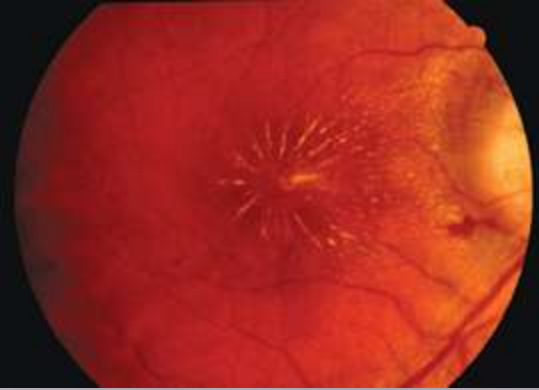




Neuroretinitis



- ▣ First described by the German ophthalmologist Theodore Leber in 1916 as a disorder of unilateral vision loss associated with optic disc edema and macular star formation.
- ▣ Leber distinguished this as a **self-limited, benign** condition which is separate from other secondary forms of **stellate retinopathy** such as HTN.

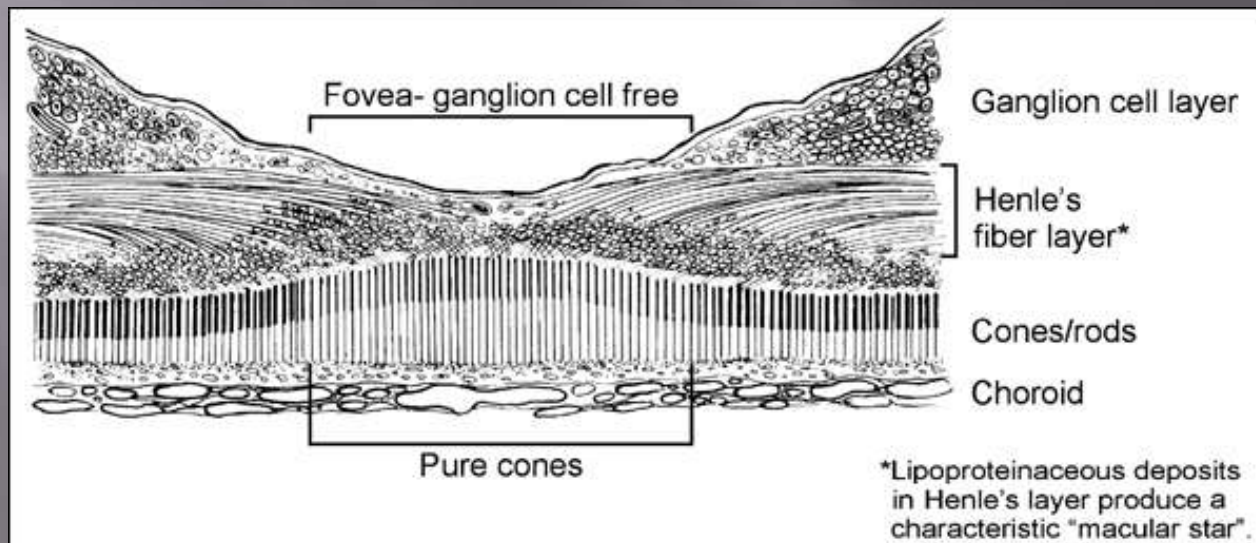


Neuroretinitis

- ▣ Frequently is a unilateral disease
- ▣ 50% may present with a viral prodrome
- ▣ Presentation: Decreased vision, patients report a washed out color vision, rarely patients may report retrobulbar pain or headache
- ▣ Clinical findings: Optic nerve swelling (or atrophy later), peripapillary NFL heme, serous RD adjacent to the disc, iritis, vitritis

Pathophysiology of the Macular star

- ▣ Gass: It has been determined that this is **not a maculopathy**, but instead it is a disease of the optic nerve and is due to optic disc capillary leakage.
- ▣ Exudates leak from disc and settle into henle's layer, which has a radial spoking pattern.



Neuroretinitis

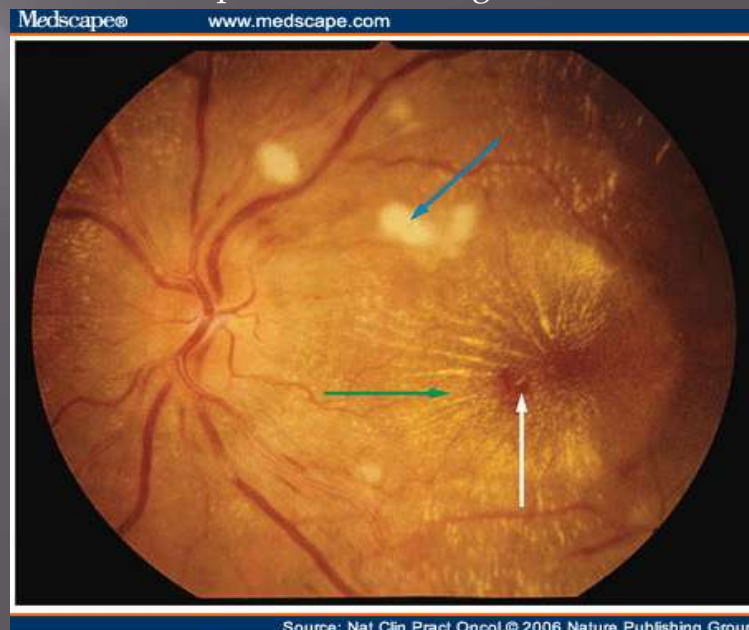
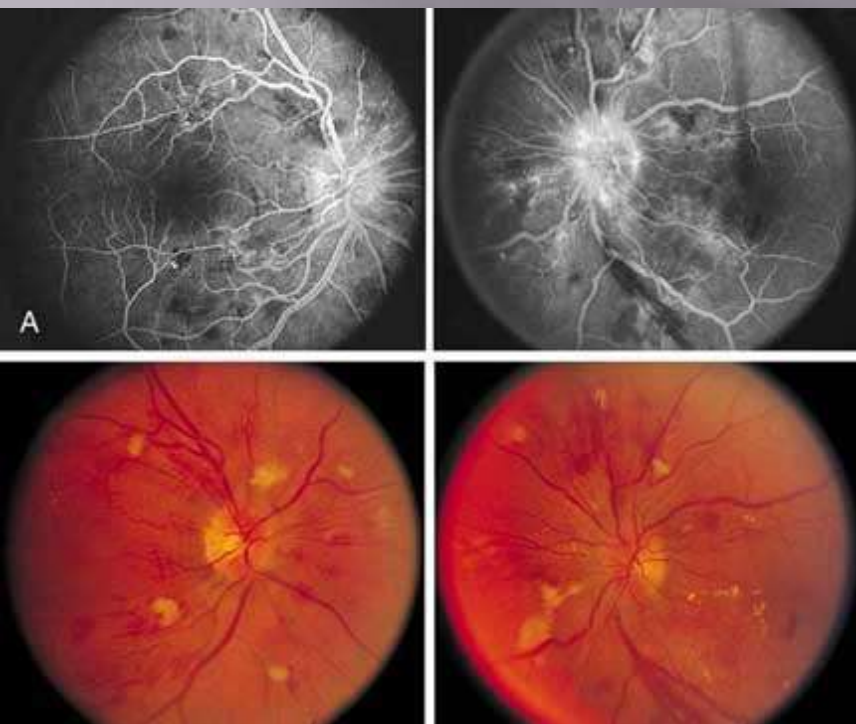- ▣ Non-infectious causes
 - Cerebral AV malformation, increased ICP(bilateral?), malignant HTN, ischemic optic neuropathy, polyarteritis nodosa, Leber's idiopathic stellate neuroretinitis (dx of exclusion)
- ▣ Infectious causes – (suspect infectious with multiple areas of retinitis)
 - Syphilis, lyme, viral (influenza A, mumps, coxsackie B, EBV), cat-scratch disease (Bartonella), TB, Salmonella typhi, toxocara, DUSN(ancylostoma caninum, baylisascaris procyonis), toxoplasma

Hypertensive retinopathy

- ▣ Localized or generalized narrowing of vessels - Copper wiring and silver wiring of arterioles as a result of arteriosclerosis
- ▣ Arteriovenous (AV) nicking
- ▣ Retinal hemorrhages
- ▣ Cotton wool spots
- ▣ Increased vascular tortuosity
- ▣ Remodeling changes due to capillary nonperfusion, such as shunt vessels and microaneurysms


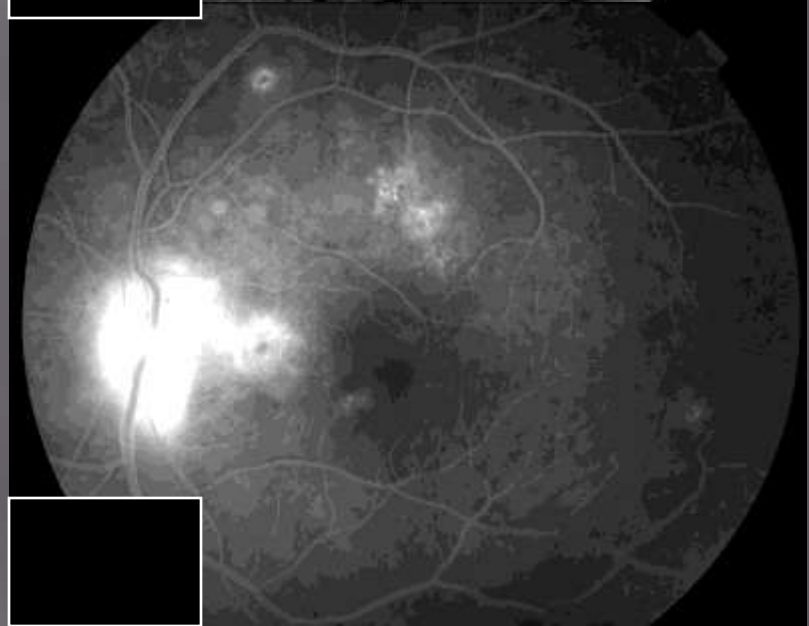

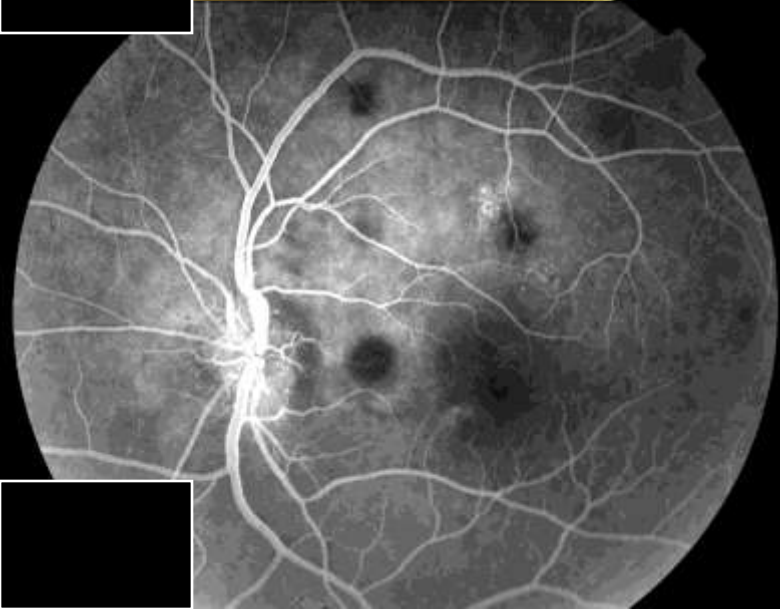


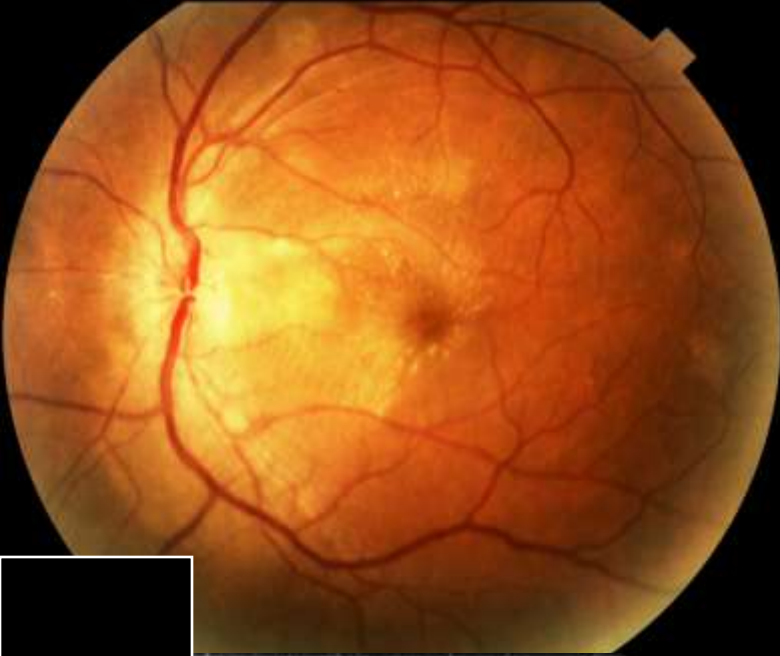
MODIFIED SHEIE CLASSIFICATION

- ▣ Grade 0 - No changes
- ▣ Grade 1 - Barely detectable arterial narrowing
- ▣ Grade 2 - Obvious arterial narrowing with focal irregularities
- ▣ Grade 3 - Grade 2 plus retinal hemorrhages and/or exudates
- ▣ Grade 4 - Grade 3 plus disc swelling



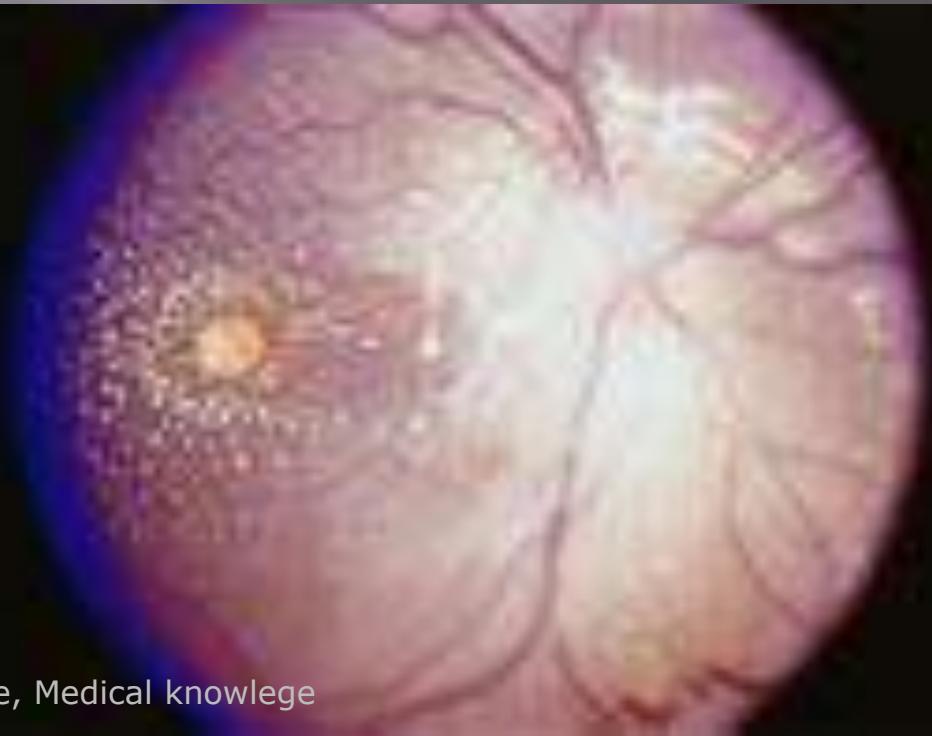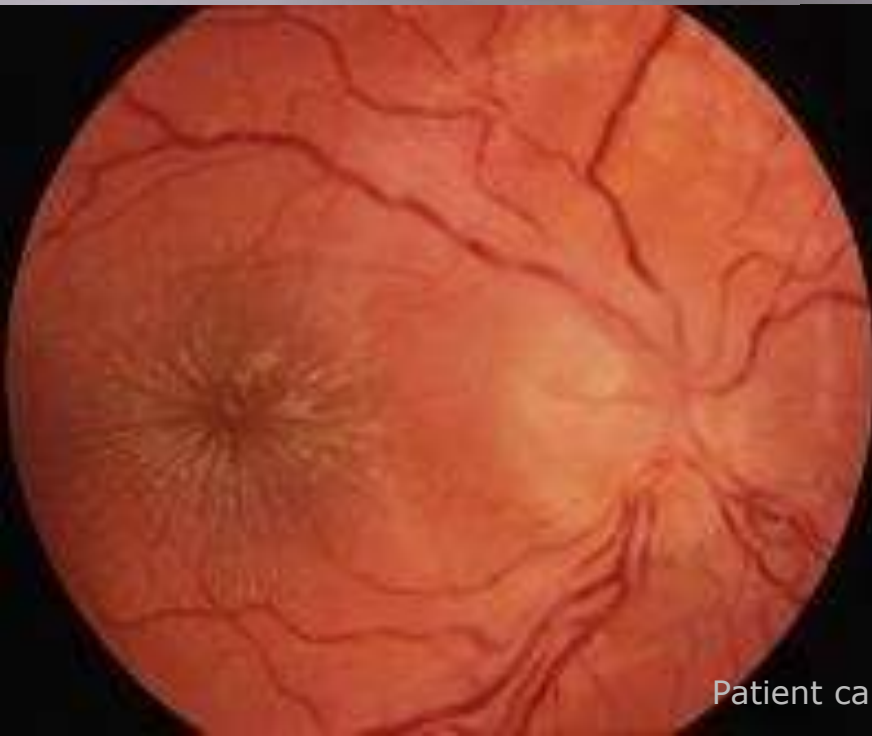
Source: Nat Clin Pract Oncol © 2006 Nature Publishing Group

Case Presentation


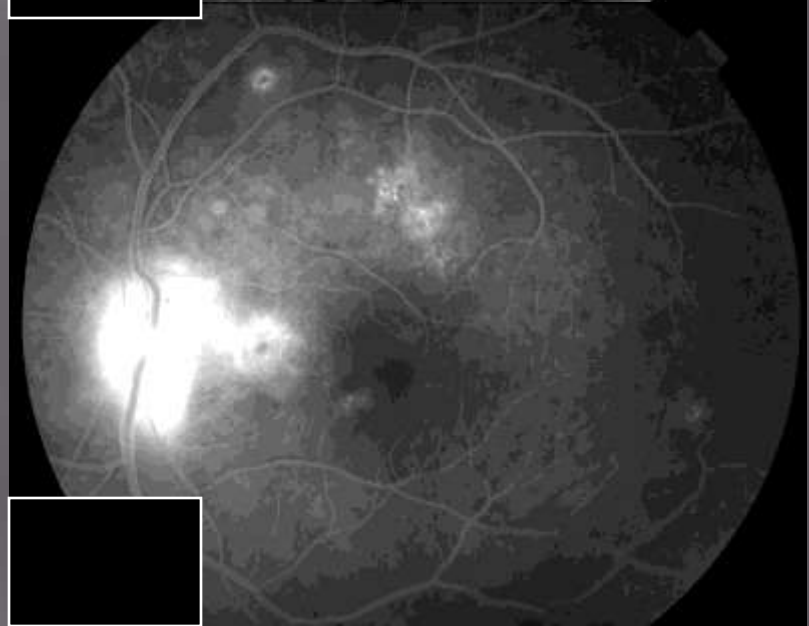

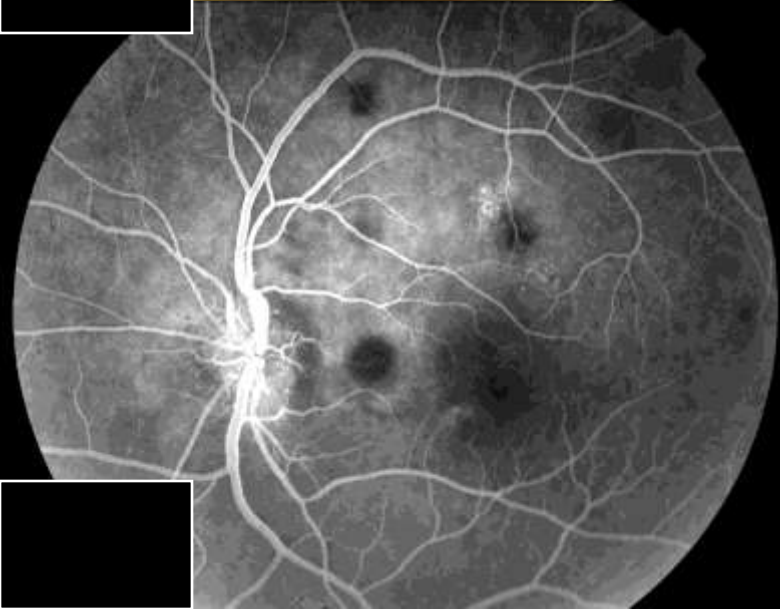


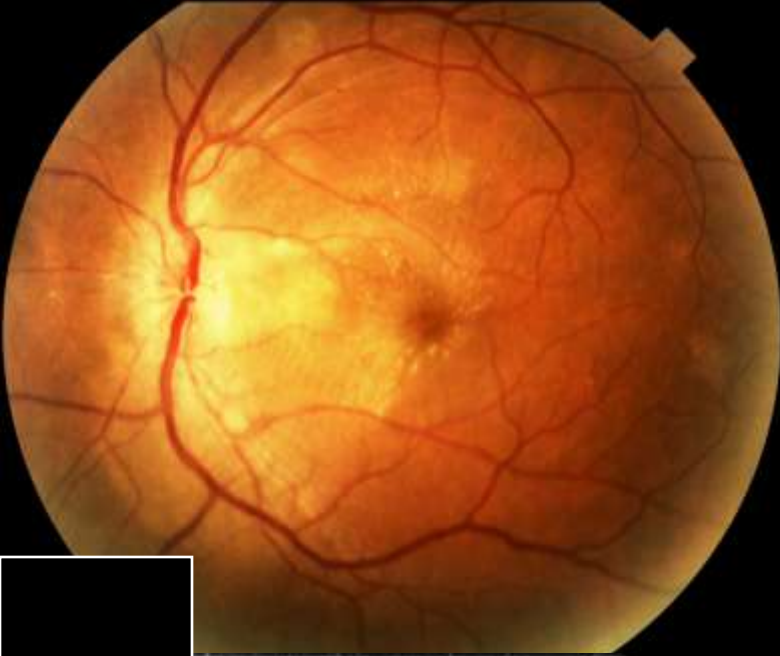


Leber's Idiopathic Stellate Neuroretinitis

- ▣ Affects those 50 years of age or younger: reports of patients ranging from 8-55
- ▣ Affects both sexes equally and 70% are unilateral
- ▣ Diagnosis of exclusion
- ▣ Spontaneously will resolve with return to baseline
- ▣ 75% with an APD (rarely long term with optic atrophy)
- ▣ Macular star develops 2 weeks after onset when disc edema is resolving
- ▣ Rarely can see chorioretinitis with elevated yellow/white spots in deep retina



Case Presentation

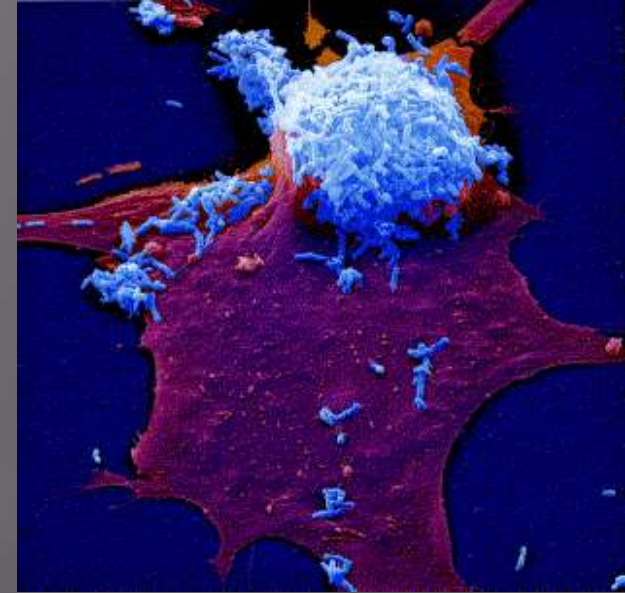


Infectious Neuroretinitis: Ocular Cat-Scratch Disease


- ▣ HISTORY-
- ▣ 1889:
 - First clinically recognized by Henri Parinaud
 - After several decades, the term “Parinaud’s oculoglandular syndrome” was introduced.
- ▣ 1970:
 - Sweeney and Drance first discussed a connection between CSD and neuroretinitis,
 - Later confirmed by Gass and many others
- ▣ 1994:
 - Serologic evidence is found to support the connection between Bartonella henselae and neuroretinitis.

Bartonella Henselae

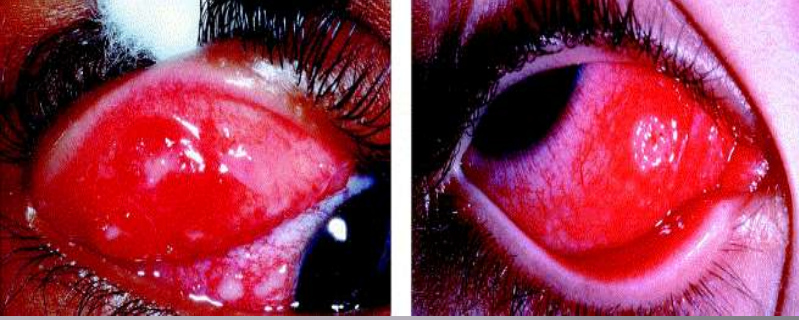
- ▣ Gram negative rod
- ▣ Cats are the natural reservoir
 - **Cats in the warmer and more humid portions of the United States have the highest incidence of Bartonellosis. Prevalence ranges from 30-50% of all cats in warm states to 5-7% in colder states. The high-prevalence areas are the same areas where cat fleas are most common ...**



Bartonella Henselae



- ▣ Also transmitted by fleas that are found on cats
 - flea bite
 - direct inoculation by flea feces into a wound, etc.
- ▣ Fleas spread this pathogen between cats and may even spread it to dogs as well
- ▣ Invades endothelial cells causing an acute inflammatory reaction and a pro-inflammatory cascade



Cat-Scratch Disease

The eye is the most commonly affected organ after the lymphatic system

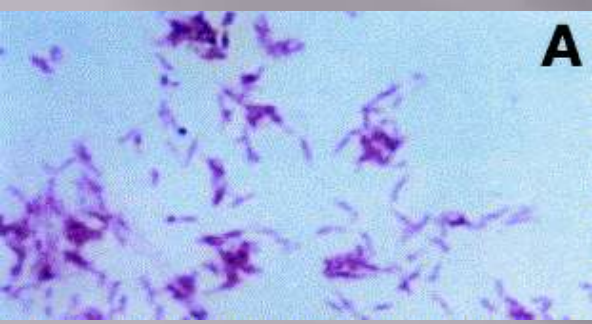
- Only 5% of patients with ocular symptoms
- **Parinaud's oculoglandular syndrome is the most common** ocular manifestation of CSD
 - Chronic fever, regional lymphadenopathy, and follicular conjunctivitis



Cat-Scratch Disease

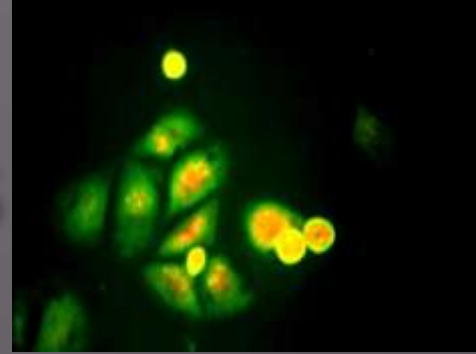


- ▣ Neuroretinitis
 - A rare manifestation of this illness seen in only **1-2%** of patients.
 - Nearly **two-thirds** of patients with neuroretinitis have serologic evidence of prior infection by **B. henselae**
 - Disc edema and sub-retinal peripapillary fluid often precede the macular star by 2-4 weeks



A

CSD Diagnosis



- ▣ Recently the criteria for diagnosis has become more heavily reliant on positive serology, **especially in cases with atypical clinical manifestations**
- ▣ Indirect fluorescent antibody (IFA) testing for *B. henselae* has an 88% sensitivity and 96% specificity
 - Lower sensitivities found using Enzyme-linked immunoassays due to many false negatives at labs other than the CDC
 - PCR shown to have high sensitivity and specificity but is not commercially available

CSD Treatment

- ▣ Traditionally not treated as it is a self limited disease, and whether to treat remains controversial. Symptomatic patients with painful lymphadenopathy or ocular symptoms should be treated.
- ▣ **In-vitro** studies: No sensitivity of this organism to any particular treatment
- ▣ **In-vivo** observation:
 - immunocompromised patients showed a **clear response and benefit** to treatment with either doxycycline or erythromycin.
...Based on this observation, all patients with severe ocular or systemic infections are treated
- Doxycycline has superior CNS and ocular penetration over erythromycin and is the preferred antibiotic by some:
 - Doxycycline 100mg BID
 - Rifampin 300mg BID can be added as well.

Back to our patient:

- ▣ After the initial presentation and consideration of this broad differential, blood work, ppd, and chest xray were sent prior to treatment....


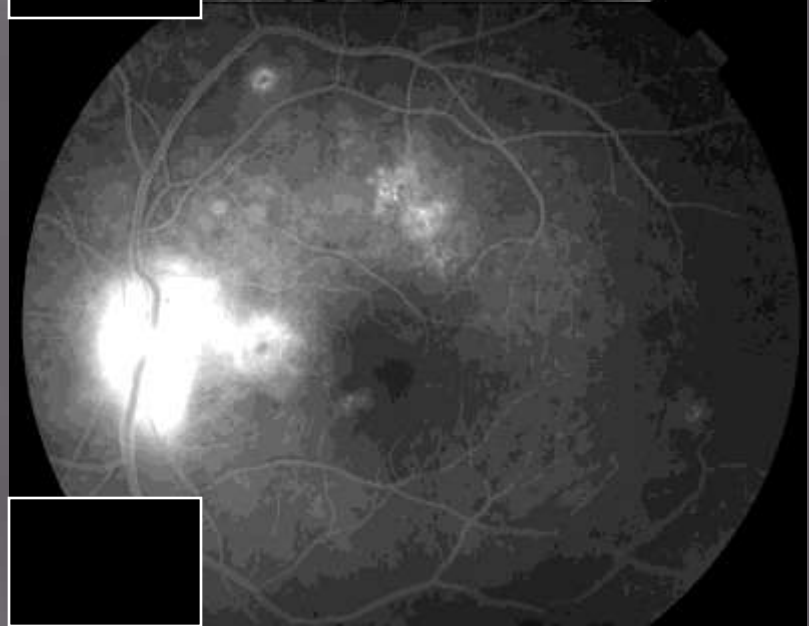

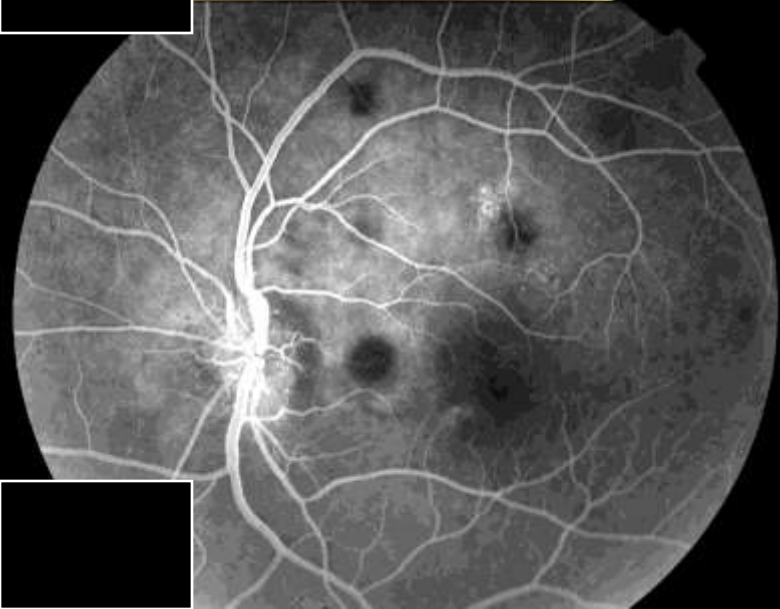

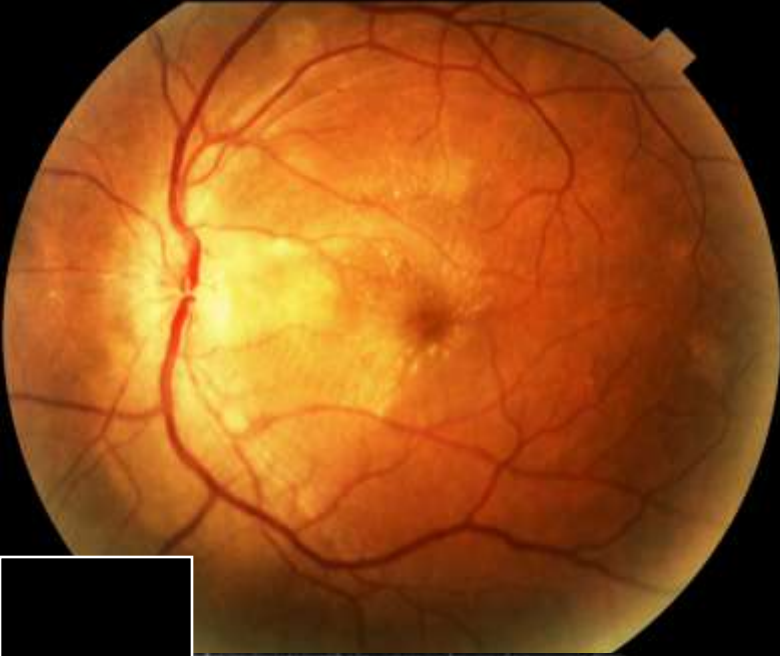
Our Patient's Additional work up:

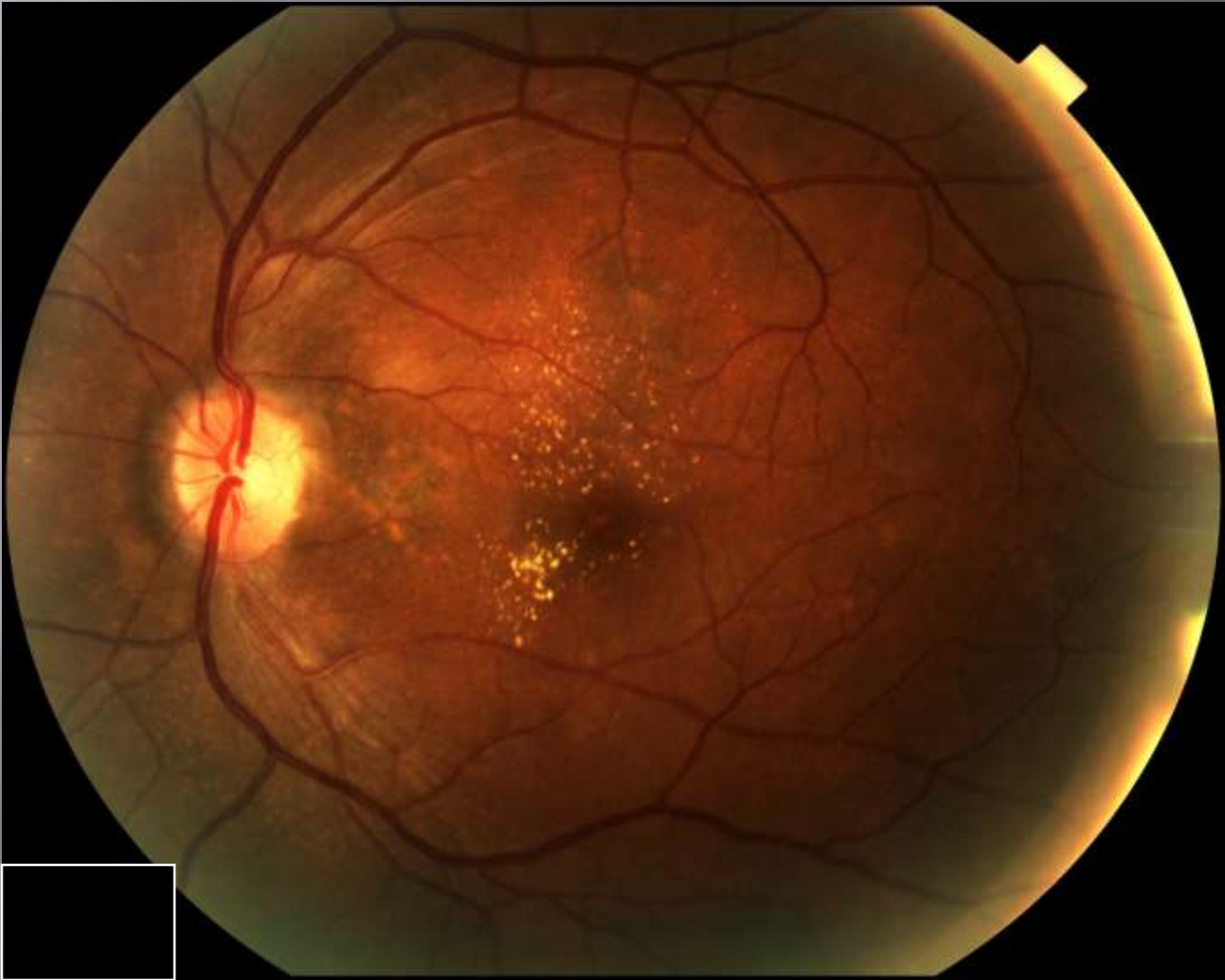
- ▣ Labs
 - Lyme Neg
 - ACE Neg
 - RPR Non-reactive
 - **Bartonella titers (pending)**
 - HIV negative
 - Histoplasmosis negative
 - ESR/CRP neg
 - ANCA negative
 - ACE negative
- ▣ BP: 128/80
- ▣ Finger stick: wnl
- ▣ Chest Xray: Negative
- ▣ PPD: **Positive**
- ▣ Referrals: Infectious disease

Our Patient's course:

- ❑ With a negative chest xray, we cautiously treated with 60mg prednisone PO, and gave the patient an urgent ID consult in the setting of a positive PPD.
- ❑ At his infectious disease appointment, a CT was ordered to follow up the +PPD and showed apical scarring of the lungs and atelectasis
- ❑ Sputum cultures were ordered and found to be negative x 3...
- ❑ He has been followed closely, tapered off of the steroids, and most recently has recovered to a vision of 20/30 in the effected left eye
- ❑ Considering the clinical history, labs, imaging, and visual recovery, the diagnosis remains uncertain. High on the differential are APMPE, Leber's idiopathic stellate neuroretinitis, or Cat Scratch Disease.
- ❑ TB is a possible diagnosis to be seriously considered. Although he has a lack of constitutional symptoms, he is now being treated empirically by ID with 6 months of INH. In addition, a quantiferon gold test and abdominal CT with contrast has been ordered for further evaluation.

Case Presentation





Reflective practice

- ▣ This is a case of an atypical presentation of neuroretinitis, with a broad differential diagnosis for the underlying etiology. Using evidence based medicine and a detailed literature search, I believe that the patient was treated timely and appropriately, and that the appropriate other services were incorporated into his care. He continues to be monitored closely and his visual recovery has been encouraging.

Core competencies

- **Patient Care:** We provided the appropriate, and effective care for patient in a compassionate manner, addressing and treating his health problems.
- **Medical Knowledge:** The literature was reviewed and a differential was formed based on the available data. Diagnostic testing and treatment were evidence based.
- **Practice-Based Learning and Improvement:** The literature was reviewed as well as the course of the patient's hospitalization, allowing for self-reflection to better serve patients in the future.
- **Interpersonal and Communication Skills:** We communicated closely with the patient and gave him careful follow up considering the possible underlying infections that he could have potentially been carrying. In addition, we were clear about the visual prognosis and importance of follow up.
- **Professionalism:** Ethical principles and sensitivity to the patient's condition were kept in mind at all times. Confidentiality was maintained and the patient's wishes respected.
- **Systems-Based Practice:** We showed awareness of the healthcare system, involving several different services as appropriate and communicated closely with those services as treatments were implemented.

Special Thank you to:

- ▣ Dr. Olumba
- ▣ Dr. Glatman
- ▣ Dr. Shrier
- ▣ And the rest of the KCH staff...

References

- ▣ Savino PJ, Weinberg RJ, Yassin JG, Pilkerton AR. Diverse manifestations of acute posterior multifocal placoid pigment epitheliopathy. *Am J Ophthalmol*. May 1974;77(5):659-62.
- ▣ Vedantham V, Ramasamy K. Atypical manifestations of acute posterior multifocal placoid pigment epitheliopathy. *Indian J Ophthalmol*. Mar 2006;54(1):49-52.
- ▣ Wright BE, Bird AC, Hamilton AM. Placoid pigment epitheliopathy and Harada's disease. *Br J Ophthalmol*. 1978;62:609-21.
- ▣ 8. Savino PJ, Weinberg RJ, Yassin JC, Pilkerton AR. Diverse manifestations of acute posterior multifocal placoid pigment epitheliopathy. *Am J Ophthalmol*. 1974;77:659-62.