

## RESEARCH ARTICLE

# Acetabular coverage analysis of the proximal femoral head accurately characterizes dysplastic acetabular morphology

Chadi Nahal<sup>1</sup> | Pablo A. Slullitel<sup>2</sup> | Tomoyuki Kamenaga<sup>3</sup> | Emma R. Payne<sup>3</sup>  | Jeffrey J. Nepple<sup>3</sup> | John C. Clohisy<sup>3</sup> | Cecilia Pascual-Garrido<sup>3</sup> 

<sup>1</sup>Department of Orthopedic Surgery, Saint Louis University School of Medicine, St. Louis, Missouri, USA

<sup>2</sup>Italian Hospital of Buenos Aires, Buenos Aires, Argentina

<sup>3</sup>Washington University School of Medicine, St. Louis, Missouri, USA

**Correspondence**

Cecilia Pascual-Garrido, Department of Orthopaedic Surgery, Washington University School of Medicine, 660S, Euclid Ave., MSC 8233-0004-5505, St. Louis, MO 63110, USA. Email: [cpascualgarrido@wustl.edu](mailto:cpascualgarrido@wustl.edu)

**Funding information**

National Center for Advancing Translational Science of the National Institutes of Health, Grant/Award Number: TL1TR002344; Jackie and Randy Baker Research Funds; Curing Hip Disease Fund

**Abstract**

This study aimed to (1) measure acetabular sector angle (ASA) from proximal to distal positions along the axial femoral head axis, (2) identify acetabular deficiency patterns, and (3) correlate ASA at different axial positions with other radiological measurements in acetabular dysplasia. We identified 30 hips with dysplasia (lateral center edge angle [LCEA] <20°) and 30 hips without dysplasia (LCEA >25°) from a retrospective cohort. Anterior and posterior ASA (AASA, PASA) were measured in the axial computed tomography plane through the femoral head center (equatorial) and two axial positions above the equatorial line (intermediate and proximal). Deficiency patterns were identified using ASA cut-off values determined from receiver operating characteristic curves. Pearson's coefficients were used for correlations. Compared to non-dysplastic hips, AASA in dysplastic hips was significantly smaller in all levels: equatorial (46.1 ± 7.3 vs. 54.9 ± 8.5,°  $p < 0.001$ ), intermediate (62.1 ± 11.2 vs. 69.0 ± 10.6,°  $p = 0.02$ ), and proximal (102.9 ± 14.2 vs. 128.3 ± 23.0,°  $p < 0.001$ ). According to proximal ASA (Pro-ASA) cut-off values in dysplastic hips, global deficiency was most prevalent (19/30, 63.3%), followed by anterior (6/30, 20%) and posterior (3/30, 10%) deficiency. There were strong correlations between acetabular anteversion and Eq-AASA ( $r = -0.74$ ,  $p < 0.001$ ) and LCEA and pro-PASA ( $r = 0.82$ ,  $p < 0.001$ ). Clinical significance: Acetabular sector angle provides insight into acetabular morphology and patterns of deficiency, providing essential information for precise acetabular reorientation.

**KEYWORDS**

3-dimensional, acetabular sector angle, diagnostic imaging, dysplasia, hip

## 1 | INTRODUCTION

Different patterns of acetabular dysplasia have been reported and classified into various categories based on the extent and location of acetabular coverage deficiency.<sup>1</sup> Radiographs are currently used to characterize acetabular morphology with specific parameters including crossover sign (with retroversion index), posterior wall sign, lateral

center-edge angle (LCEA), and Tönnis angle.<sup>2</sup> Three-dimensional (3D) computed tomography (CT) has allowed for a more comprehensive assessment of acetabular morphology using measurements such as acetabular sector angle (ASA), radial coverage, and acetabular anteversion (AA).<sup>3,4</sup> Previously, Nepple et al.<sup>4</sup> measured radial coverage at different acetabular clockface positions in 3D CT images of hips with mild to severe forms of dysplasia and illustrated

deficiency patterns categorized into global, anterosuperior, and posterosuperior subtypes, occurring with similar frequency. Using Anda et al.'s definition of anterior (AASA) and posterior acetabular sector angle (PASA) measurements at the equatorial femoral head level in a population with acetabular dysplasia, Goronzy et al.<sup>5</sup> further described these angles in coronal and axial planes rotated along clockwise positions using both CT and magnetic resonance imaging to characterize hips with femoroacetabular impingement.

Analysis of 3D CT images can also provide further insight into the relationship between acetabular morphology and other clinically relevant features of the hip. For instance, Fujii et al.<sup>3</sup> measured ASA at different clockface positions in 3D CT images of dysplastic hips and found correlations between those measurements and acetabular tilt and anteversion. They concluded that pelvic tilt was associated with specific patterns of deficiency in dysplastic hips. However, ASA directly quantifies acetabular coverage and provides more insight into morphology than solely pelvic tilt and AA.

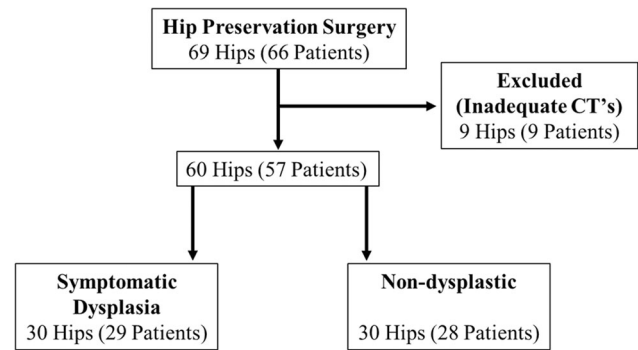
Understanding acetabular morphology is crucial for preoperative planning and precise execution of the periacetabular osteotomy (PAO). Identification of specific regions of deficiency in acetabular coverage would allow for a more individualized approach in surgical treatment, improving the efficacy and possible patient reported outcomes (PROs) following the PAO.<sup>6</sup> However, most acetabular coverage deficiency patterns have been defined qualitatively, using cut-off values calculated at a chosen standard deviation beyond the mean values of normative data, therefore lacking objectivity.<sup>3,4,7</sup>

Although ASA has been used to indicate deficiency patterns in dysplastic hips, the utility of this measurement in distinguishing amongst dysplastic from non-dysplastic hips still needs to be proven. Additionally, measuring ASAs at spatially separate positions along the axial axis may be useful to quantitatively characterize acetabular coverage (i.e., deficient vs. non-deficient), being a novel technique that has not been previously applied for this purpose. We hypothesized that ASA measured at different axial positions would be significantly different between dysplastic and non-dysplastic hips. Therefore, this study aimed to (1) measure ASA measured from proximal to distal positions along the axial axis of the femoral head, (2) identify specific patterns of acetabular deficiency, and (3) correlate ASA at different axial positions with other radiological measurements of the hip including AA, pelvic tilt, and LCEA in both dysplastic and non-dysplastic hips.

## 2 | PATIENTS AND METHODS

Using an established retrospective cohort from December 2011 to February 2020, we identified patients with hip disease who underwent hip preservation surgery (Figure 1). It is currently our standard to obtain low dose pelvic CT scans (0.75–1.25 mSv, equivalent to three to five AP pelvis radiographs) on all patients undergoing hip preservation surgery.

Radiographs were selected to include patients with hips with symptomatic acetabular dysplasia (LCEA  $<20^\circ$ ,  $n = 30$ ) and hips

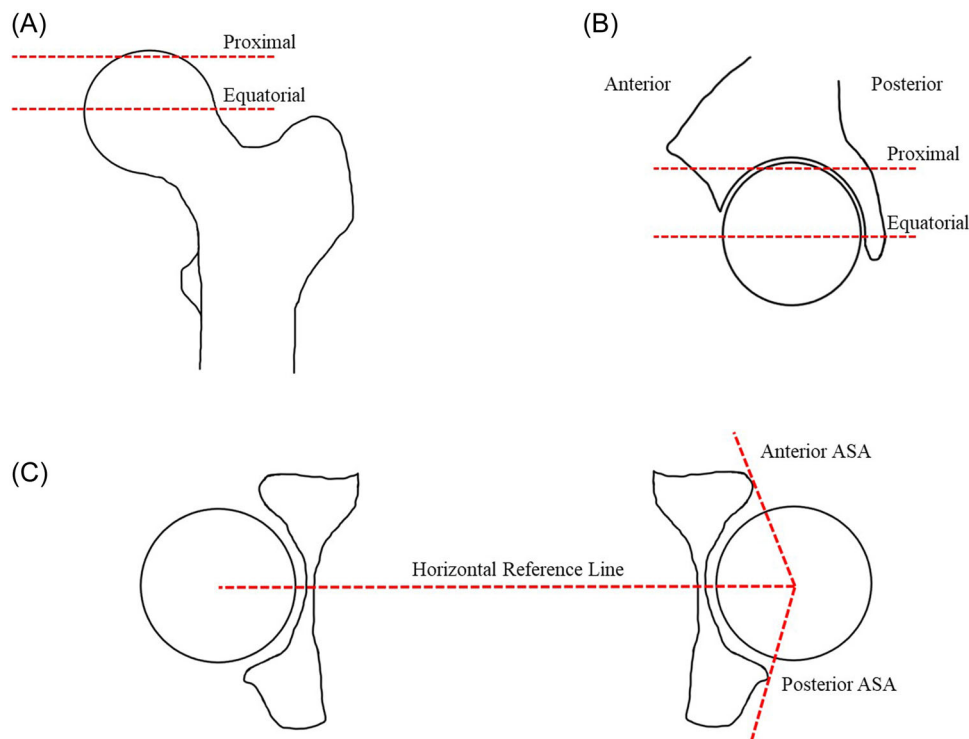


**FIGURE 1** As shown in this flow diagram, patients were excluded because of inadequate imaging. In both groups, some patients had bilateral hip disease. CT, computed tomography.

without acetabular dysplasia that underwent treatment for symptomatic femoroacetabular impingement (FAI) as comparison hips (LCEA  $>25^\circ$ ,  $n = 30$ ). Inclusion criteria consisted of patients older than 18 years old with adequate X-rays and CT scans obtained at axial intervals from the anterior superior iliac spine to the lesser trochanter in the supine position.<sup>8</sup> Sagittal and coronal reconstructions were produced using axial images. Exclusion criteria included history of spine surgery or other ipsilateral surgery, hips with inadequate 3D-CT scan reconstructions, or diagnosis of Perthes, slipped capital femoral epiphysis, or complex posttraumatic deformities.

Images were analyzed using ImageJ (version 1.53c). Pelvic tilt and LCEA were measured as previously described.<sup>9,10</sup> Pelvic tilt was measured using the maximum intensity projection of the reconstructed CT sagittal image slices as the inclination angle of the anterior pelvic plane, determined by both the anterior superior iliac spines and the pubic tubercles, relative to the CT table plane. Anterior tilt relative to the CT table plane was considered to be a positive pelvic tilt.<sup>10</sup> LCEA was measured on AP X-rays of bilateral hips. ASA was measured as described in Figure 2. Anterior and posterior ASA (AASA, PASA) were measured in the axial CT plane through the femoral head centers to determine the equatorial ASA (Eq-ASA) (Figures 2A and 3B). To characterize acetabular coverage proximal to the equatorial line, we established two additional ASAs: intermediate ASA (Int-ASA) (Figure 3C) and proximal ASA (Pro-ASA) (Figures 2A and 3D). Figure 3A shows the position of these measurement levels along the demarcated anterior and posterior acetabular borders of a dysplastic hip. AA in the equatorial slice was measured as the angle between the anterior and posterior acetabular rim and the line perpendicular to the axis connecting the femoral head centers.

One blinded reader (C. C. N.) completed all measurements for each included hip. Intra- and interobserver reliability was assessed by comparing these measurements on a subset of 20 hips (10 from each group, dysplastic and non-dysplastic), with those completed by another reader (E. R. P.). Intraclass correlation coefficients (ICC) were calculated to assess reliability with ICC between 0.75 and 0.9 being considered good and greater than 0.9 being excellent.<sup>11</sup>



**FIGURE 2** (A–C) The axial location of the Eq-ASA and Pro-ASA measurements is illustrated along the femoral head (A) and saggital view of the acetabulum (B). The equatorial axial slice was determined through visual inspection as the level at which the cross-sectional diameter of the femoral head was the largest. The proximal axial slice was obtained between 1.2 and 2.5 mm below the superior surface of the femoral head. The midpoint between the proximal and equatorial levels was considered the intermediate slice (Int-ASA). The ASA measurement is shown (C) as the angle between the horizontal reference line and the lines connecting the femoral head center to the anterior (AASA) or posterior (PASA) acetabular borders. The horizontal reference line is the connection between the centers of the circles fitted to femoral head cross sections in the equatorial slice. The same horizontal reference line was used to measure ASA at each axial level. ASA, acetabular sector angle; Eq-ASA, equatorial ASA; Pro-ASA, proximal ASA. [Color figure can be viewed at [wileyonlinelibrary.com](https://onlinelibrary.wiley.com/doi/10.1002/jor.25479)]

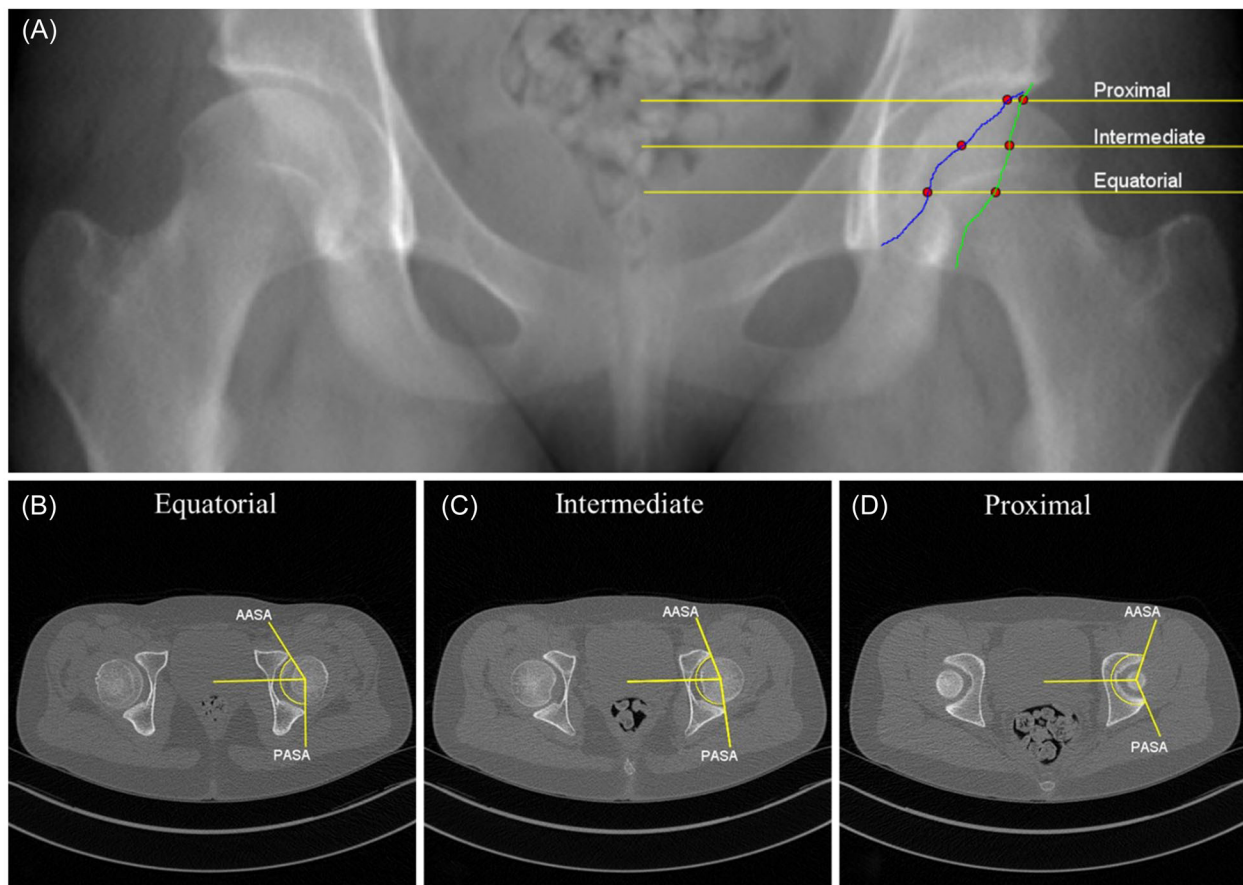
Intra- and interobserver reliability was good for Eq-PASA and excellent for pelvic tilt, AA and all other ASA measurements (Table 1).

## 2.1 | Statistical analysis

All values are presented as mean  $\pm$  standard deviation. Dedicated statistical software packages (StatView 5.0; Abacus Concepts Inc./EZR; Saitama Medical Center; Ichi Medical University) were used to analyze the collected data. Cut-off values for AASA and PASA at different axial positions were determined using receiver operating characteristic (ROC) curves. The area under the curve (AUC) measured the accuracy of classifying the outcome based on the model. An AUC between 0.7 and 0.8 is considered acceptable, an AUC between 0.8 and 0.9 is excellent, and an AUC of 1.0 is a perfect assignment.<sup>12</sup> The threshold was found through the specificity and sensitivity approach; the point on the curve that achieves the highest sensitivity and specificity was used to set the optimal threshold value. Based on the ROC cut-off values of Eq-ASA and previous literature,<sup>13</sup> deficiency patterns were categorized in four groups: global- (Eq-AASA  $<50^\circ$ , Eq-PASA  $<90^\circ$ ), anterior- (Eq-AASA  $<50^\circ$ , Eq-PASA  $\geq 90^\circ$ ), posterior- (Eq-AASA  $\geq 50^\circ$ , Eq-PASA  $<90^\circ$ ), and non- (Eq-AASA  $\geq 50^\circ$ , Eq-PASA  $\geq 90^\circ$ )

deficiency. Additionally, hips were classified into the same deficiency patterns using Pro-ASA cut-off values: Global- (Pro-AASA  $<120.9^\circ$ , Pro-PASA  $<120.5^\circ$ ), anterior- (Pro-AASA  $<120.9^\circ$ , Pro-PASA  $\geq 120.5^\circ$ ), posterior- (Pro-AASA  $\geq 120.9^\circ$ , Pro-PASA  $<120.5^\circ$ ), and non- (Pro-AASA  $\geq 120.9^\circ$ , Pro-PASA  $\geq 120.5^\circ$ ) deficiency. Comparison between two groups (dysplastic vs. non-dysplastic) were performed using the unpaired *t*-test for quantitative variables and Fisher's exact test for qualitative variables. Correlation between ASA at different axial positions and other radiological measurements were assessed using Pearson's correlation. Analysis of covariance (ANCOVA) was performed using pelvic tilt and AA as the covariables to compare ASA between dysplastic and non-dysplastic hips at different axial positions while controlling for the effects of pelvic tilt and AA. *p* Values below 0.05 were considered to indicate statistical significance.

Based on our pilot study with 10 samples, we considered  $5^\circ$  in equatorial, intermediate, and proximal AASA and PASA as a meaningful difference, corresponding with a large effect size of 0.8 based on the standard deviation of AASA from our pilot data (Table 2). We calculated that if there was a sample of 56 patients (28 patients per group), the study would have 80% power to detect a meaningful difference in equatorial AASA with a type I error ( $\alpha$ ) of 0.05.



**FIGURE 3** (A–D) Average intensity projection of 3D-CT coronal reconstructions (A) is shown for a left dysplastic hip. The blue and green lines trace the anterior and posterior acetabular walls, respectively. Acetabular sector angle measurements are shown at the (B) equatorial, (C) intermediate, and (D) proximal axial slices. CT, computed tomography. [Color figure can be viewed at [wileyonlinelibrary.com](https://onlinelibrary.wiley.com/doi/10.1002/jor.25479)]

**TABLE 1** Intraclass correlation coefficients for intraobserver and interobserver reliability

	Intraobserver		Interobserver	
	ICC	95% confidence interval	ICC	95% confidence interval
Pelvic tilt	0.98	0.95–0.99	0.99	0.98–1.00
Acetabular anteversion	0.98	0.95–0.99	0.92	0.81–0.97
Eq-AASA	0.93	0.83–0.97	0.94	0.85–0.98
Eq-PASA	0.84	0.64–0.94	0.83	0.63–0.94
Int-AASA	0.96	0.89–0.98	0.94	0.86–0.98
Int-PASA	0.91	0.78–0.97	0.93	0.83–0.97
Pro-AASA	0.95	0.87–0.98	0.93	0.83–0.97
Pro-PASA	0.93	0.83–0.97	0.92	0.80–0.97

Note: ICC between 0.75 and 0.9 is good\* and greater than 0.9 is excellent.\*

Abbreviations: AASA, anterior acetabular sector angle; ICC, intraclass correlation coefficients; PASA, posterior acetabular sector angle.

### 3 | RESULTS

The dysplastic group included younger subjects with lower LCEA and higher proportion of females than the non-dysplastic group. Pelvic tilt was also different between groups (Table 3).

In dysplastic hips, mean AASA values were significantly smaller in the equatorial ( $46.1 \pm 7.3$  vs.  $54.9 \pm 8.5^\circ$ ,  $p < 0.001$ ), intermediate ( $62.1 \pm 11.2$  vs.  $69.0 \pm 10.6^\circ$ ,  $p = 0.02$ ), and proximal ( $102.9 \pm 14.2$  vs.  $128.3 \pm 23.0^\circ$ ,  $p < 0.001$ ) levels and mean PASA values were significantly smaller in the intermediate ( $96.8 \pm 6.9$  vs.  $106.5 \pm 6.8^\circ$ ,  $p < 0.001$ ) and proximal ( $113.1 \pm 13.8$  vs.  $149.1 \pm 23.1^\circ$ ,  $p < 0.001$ ) levels (Table 4).

ROC cut-off values for AASA in dysplastic hips were  $50.3^\circ$  (equatorial; sensitivity = 0.767, specificity = 0.667, AUC = 0.78),  $67.7^\circ$  (intermediate; sensitivity = 0.800, specificity = 0.500, AUC = 0.66), and  $120.9^\circ$  (proximal; sensitivity = 0.900, specificity = 0.767, AUC = 0.84) (Figure 4A–C). For PASA in dysplastic hips, cut-off values were  $91.3^\circ$  (equatorial; sensitivity = 0.677, specificity = 0.733, AUC = 0.72),  $101.5^\circ$  (intermediate; sensitivity = 0.800, specificity = 0.733, AUC = 0.81), and  $120.5^\circ$  (proximal; sensitivity = 0.767, specificity = 0.967, AUC = 0.93) (Figure 4D–F).

**TABLE 2** Pilot study measurements

	Dysplastic (n = 5)	Non-dysplastic (n = 5)	p Value
Eq-AASA (degree)	47.9 ± 6.9	57.3 ± 12.4	0.18
Eq-PASA (degree)	86.4 ± 6.8	94.1 ± 6.8	0.11
Int-AASA (degree)	69.1 ± 11.3	73.1 ± 10.0	0.57
Int-PASA (degree)	92.3 ± 8.7	111.2 ± 6.6	<0.005*
Pro-AASA (degree)	107.7 ± 13.8	148.1 ± 11.4	0.001*
Pro-PASA (degree)	100.3 ± 12.9	171.9 ± 28.6	<0.001*
Lateral center edge angle (degree)	10.6 ± 3.9	36.6 ± 10.0	<0.001*
Pelvic tilt (degree)	11.4 ± 4.7	6.8 ± 3.9	0.13
Acetabular anteversion (degree)	19.0 ± 5.0	19.1 ± 6.5	0.98

Note: Data presented as mean ± standard deviation. p Values were calculated using student's t-test.

Abbreviations: AASA, anterior acetabular sector angle; PASA, posterior acetabular sector angle.

\*Statistically significant difference (p < 0.05).

**TABLE 3** Patient demographics

	Dysplastic (n = 30)	Non-dysplastic (n = 30)	p Value
Age (years)	25.3 ± 7.4	35.6 ± 12.2	0.0002*
Sex, female/male	26/4	14/16	0.002*
Side, right/left	14/16	14/16	1.00
Tönnis OA grade, 0/1	21/8	15/14	0.23
Lateral center edge angle (degree)	12.8 ± 6.3	30.9 ± 4.2	<0.0001*
Pelvic tilt (degree)	12.3 ± 6.5	7.1 ± 5.3	0.001*
Acetabular anteversion (degree)	21.7 ± 5.6	19.3 ± 4.8	0.08

Note: Data presented as mean ± standard deviation. p Values were calculated using Fischer's exact test or student t-test.

\*Statistically significant difference (p < 0.05).

**TABLE 4** Comparison of acetabular sector angles at different axial positions between groups

	Dysplastic (n = 30)	Non-dysplastic (n = 30)	p Value
Anterior acetabular sector angle (degree)			
Equatorial	46.1 ± 7.3	54.9 ± 8.5	<0.001**
Intermediate	62.1 ± 11.2	69.0 ± 10.6	0.02*
Proximal	102.9 ± 14.2	128.8 ± 23.0	<0.001**
Posterior acetabular sector angle (degree)			
Equatorial	90.1 ± 7.3	93.4 ± 7.1	0.06
Intermediate	96.8 ± 6.9	106.5 ± 6.8	<0.001**
Proximal	113.1 ± 13.8	149.1 ± 23.1	<0.001**

Note: Data presented as mean ± standard deviation. p Values were calculated using Fischer's exact test or student t-test.

\*Statistically significant difference with \*p < 0.05 and with

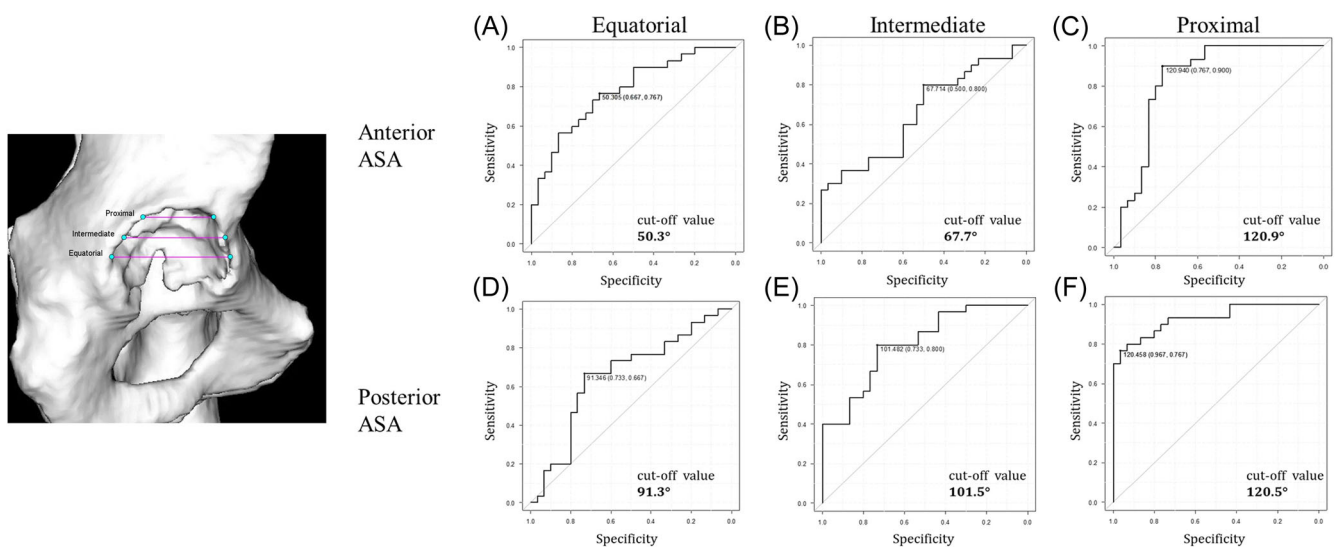
\*\*p < 0.001.

The distribution of deficiency patterns was significantly different between dysplastic and non-dysplastic hips (Tables 5 and 6). According to Eq-ASA cut-off values, anterior deficiency was most prevalent (12/30 hips or 40%), followed by global (10/30 hips or 33.3%) and posterior deficiency (7/30 hips or 23.3%) (Table 6). Contrarily, in the non-dysplastic group, most of the hips, 17/30 (56.7%), did not have any deficiency based on Eq-ASA cut-off values (Table 5).

According to Pro-ASA cut-off values, global deficiency was most prevalent (19/30, 63.3%), followed by anterior (6/30, 20%) and posterior (3/30, 10%) deficiency (Table 6). In the non-dysplastic group, Pro-ASA cut-off values indicated that (23/30, 76.7%) did not have deficiency (Table 6).

Correlations between radiographic measurements and AASAs at different axial positions are shown in Table 7. There was a strong correlation between LCEA and Pro-PASA (r = 0.82, p < 0.001) and moderate correlations between LCEA and Pro-AASA (r = 0.68, p < 0.001) and Int-PASA (r = 0.63, p < 0.001) (Table 7). AA had a strong negative correlation with Eq-AASA (r = -0.74, p < 0.001, Figure 5A).





**FIGURE 4** Cut-off values were shown on the receiver operating characteristic curve for anterior ([A] equatorial, [B] intermediate, [C] proximal) and posterior ([D] equatorial, [E] intermediate, [F] proximal) posterior acetabular sector angles at different axial positions. [Color figure can be viewed at [wileyonlinelibrary.com](http://wileyonlinelibrary.com)]

**TABLE 5** Comparison of deficiency pattern of acetabular coverage between dysplastic and non-dysplastic hips using Eq-ASA cut-off values

	Global deficiency	Anterior deficiency	Posterior deficiency	Normal coverage
Dysplastic (n = 30)	10	12	7	1
Non-dysplastic (n = 30)	5	6	2	17

Note: Fisher's exact test;  $p < 0.0001$ .

Abbreviations: ASA, acetabular sector angle; Eq-ASA, equatorial ASA.

**TABLE 6** Comparison of deficiency pattern of acetabular coverage between dysplastic and non-dysplastic hips using Pro-ASA cut-off values

	Global deficiency	Anterior deficiency	Posterior deficiency	Normal coverage
Dysplastic (n = 30)	19	6	3	2
Non-dysplastic (n = 30)	1	6	0	23

Note: Fisher's exact test;  $p < 0.0001$ .

Abbreviations: ASA, acetabular sector angle; Pro-ASA, proximal ASA.

ANCOVA for both the dysplastic and non-dysplastic cohorts indicated that AA did not have a significant interaction with Eq-AASA ( $p = 0.240$ ) or Eq-PASA ( $p = 0.806$ ) (Figure 6A,B). Adjusting for AA as a covariate resulted in significantly different Eq-AASA ( $p < 0.001$ ) and Eq-PASA ( $p < 0.001$ ) between dysplastic and non-dysplastic hips (Figure 6A,B). Likewise, pelvic tilt as a covariate did not have a significant effect on Eq-AASA ( $p = 0.724$ ) and resulted in significantly different Eq-AASA between dysplastic and non-dysplastic hips ( $p = 0.002$ ) (Figure 6C).

## 4 | DISCUSSION

Measuring acetabular coverage in 3D allows for a precise characterization of acetabular deficiency. ASA measured in the proximal femoral head can quantify acetabular coverage and identify deficiency

localized to a separate acetabular region proximal from the equatorial level. Therefore, our study both used Pro-ASA and Eq-ASA to classify both dysplastic and non-dysplastic hips into different patterns of acetabular deficiency, allowing for a more accurate characterization of acetabular morphology.

This study was not without limitations. First, the non-dysplastic group consisted of patients undergoing hip preservation surgery for symptomatic FAI. It is possible that some of the controls may suffer from cam-type FAI with associated shallow acetabulum; however, our control group included only cases with LCEA higher than  $25^\circ$  and the mean LCEA for the control group was  $30.9 \pm 4.2^\circ$ , so a shallow acetabular depth is unlikely to be present in our control cohort to the extent that the significance of our results would be affected. Patients without hip disease or true controls hips generally do not receive 3D-CT imaging, limiting the availability of healthy hips for analysis.

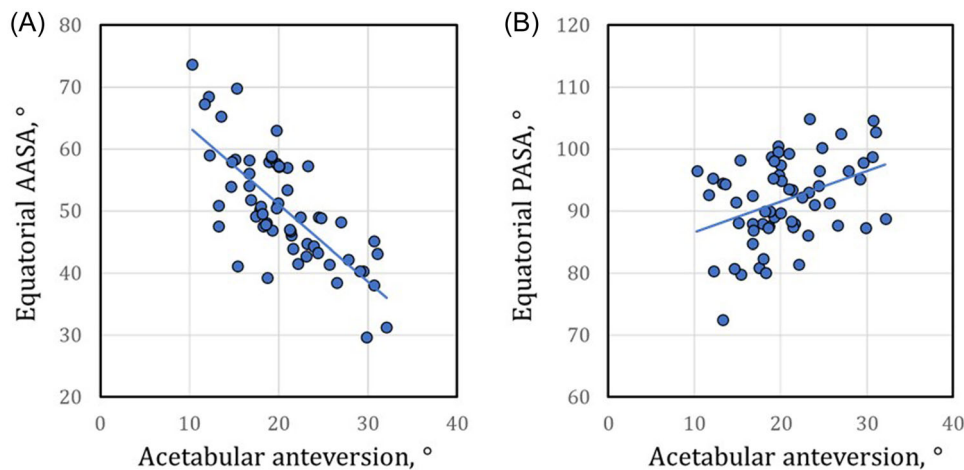
**TABLE 7** Correlation between radiographic measurements and AASAs at different axial positions

	Anterior acetabular sector angle			Posterior acetabular sector angle		
	Equatorial	Intermediate	Proximal	Equatorial	Intermediate	Proximal
LCEA	$r = 0.56^{**}$ (0.36–0.71) $p < 0.001$	$r = 0.44^*$ (0.18–0.60) $p = 0.001$	$r = 0.68^{**}$ (0.51–0.80) $p < 0.001$	$r = 0.33$ (0.08–0.54) $p = 0.011$	$r = 0.63^{**}$ (0.44–0.76) $p < 0.001$	$r = 0.82^{**}$ (0.71–0.89) $p < 0.001$
Pelvic tilt	$r = -0.37^*$ (-0.57 to -0.13) $p = 0.004$	$r = -0.06$ (-0.31 to -0.20) $p = 0.642$	$r = -0.38^*$ (-0.58 to -0.14) $p = 0.003$	$r = -0.041$ (-0.30 to 0.22) $p = 0.755$	$r = -0.32$ (-0.53 to 0.07) $p = 0.013$	$r = -0.42^{**}$ (-0.61 to -0.19) $p < 0.001$
Acetabular anteversion	$r = -0.74^{**}$ (-0.83 to -0.59) $p < 0.001$	$r = -0.68^{**}$ (-0.80 to -0.52) $p < 0.001$	$r = -0.37^*$ (-0.57 to -0.13) $p = 0.003$	$r = 0.38^*$ (0.14–0.58) $p = 0.002$	$r = 0.22$ (-0.03 to 0.45) $p = 0.08$	$r = -0.01$ (-0.22 to 0.29) $p = 0.79$

Note: Correlation coefficients were presented with (95% confidence interval).

Abbreviations: AASA, anterior acetabular sector angle; LCEA, lateral center edge angle.

Statistically significant correlation with  $*p < 0.01$  and  $**p < 0.001$ .

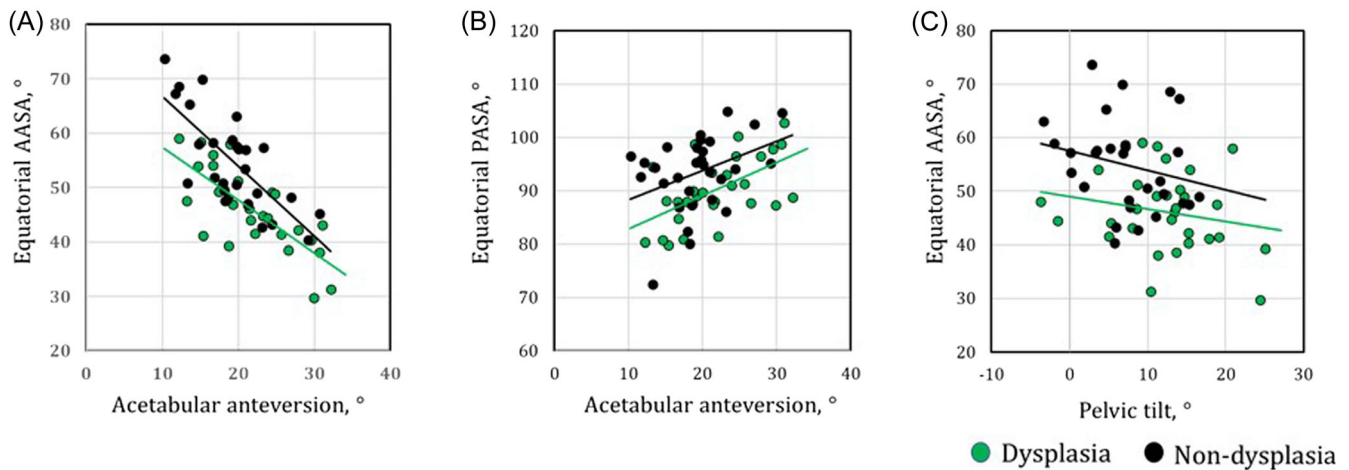


**FIGURE 5** Correlation curves between equatorial AASA and acetabular anteversion (AA) (A), equatorial PASA and AA (B). AASA, anterior acetabular sector angle; PASA, posterior acetabular sector angle. [Color figure can be viewed at [wileyonlinelibrary.com](http://wileyonlinelibrary.com)]

Prior studies on acetabular morphology similarly had control cohorts comprised of diseased or injured hips.<sup>5,14,15</sup> Therefore, assessing acetabular coverage between hips with acetabular dysplasia and hips with other diagnoses allows for an accurate comparison of results from this study with previously published literature. Second, the sample size of 30 for the dysplastic and non-dysplastic cohorts did not provide the statistical power for subgroup analysis of gender, deficiency pattern, or dysplasia severity categories. This sample size was determined using our pilot study to find a meaningful difference only in ASA, although LCEA, the conventional measurement for determining acetabular dysplasia, was still significantly different between cohorts. The higher prevalence of females in the dysplastic cohort may have caused measurements to vary on the basis of gender in addition to deficiency pattern. Nepple et al.<sup>4</sup> performed a subgroup analysis of dysplastic hips and found that posterosuperior

deficiency was significantly more common in males and that AA was significantly different between deficiency patterns. However, the authors found no significant differences in the frequency of deficiency patterns between categories of dysplasia severity.<sup>4</sup> Although the variation of deficiency patterns may have affected our analysis, ANCOVA with AA and pelvic tilt as covariates when comparing Eq-ASA still indicated a significantly different morphology between dysplastic and non-dysplastic hips.

To our knowledge, this is the first study to measure ASA at different axial positions in parallel for comparison between dysplastic and non-dysplastic hips, while also controlling for the effects of AA and pelvic tilt on the variation in Eq-ASA. Previous research assessing acetabular morphology in acetabular dysplasia supports the utility of measuring ASA at different axial levels. Fujii et al.<sup>3</sup> measured ASA at different directions along the acetabular clockface and



**FIGURE 6** Analysis of covariance (ANCOVA) for equatorial AASA (A) and equatorial PASA (B) using acetabular anteversion as a covariate. (C) ANCOVA for equatorial AASA with pelvic tilt as a covariate. AASA, anterior acetabular sector angle; PASA, posterior acetabular sector angle. [Color figure can be viewed at [wileyonlinelibrary.com](https://onlinelibrary.wiley.com/doi/10.1002/jor.25479)]

similarly found lower ASA angles in dysplastic hips. Goronzy et al.<sup>7</sup> evaluated 3D acetabular morphology in dysplastic hips by measuring ASA along the acetabular clockface for correlation with postsurgical outcomes of PAO. In the current study, AASA and PASA were lower in all axial positions in dysplastic hips, indicating deficient acetabular coverage or smaller socket; however, the strength of our correlations may have been affected by limited sample size and other confounding variables such as AA, which contributes to posterior coverage. ANCOVA was used to control for the effect of AA on Eq-ASA and still indicated significantly lower AASA and PASA in dysplastic hips. Because AA was measured at the equatorial level, ANCOVA with AA as a covariate was only used to compare Eq-ASA. In addition, we used ANCOVA to control for the effect of pelvic tilt on the variation in AASA and found significantly lower Eq-AASA in dysplastic hips. Therefore, pelvic tilt and AA as covariates in ANCOVA indicated that dysplastic hips have an acetabular morphology distinct from non-dysplastic hips.<sup>7</sup>

This study also determined ASA cut-off values for dysplasia at the equatorial, intermediate, and proximate levels (Figure 4). Specificity for acetabular dysplasia was highest for Pro-ASA (anterior, 0.767; posterior, 0.967). This may be because acetabular dysplasia is diagnosed using LCEA, which is measured as the angle between the vertical axis and the line connecting the femoral head center to the lateral edge of the acetabular sourcil, close to the proximal level. The accuracy of these cut-off values was excellent for Pro-PASA, and acceptable for all other ASAs except Int-AASA, which had a cut-off value accuracy of 0.66 (minimum acceptable = 0.7). Therefore, we classified hips into deficiency patterns using either Pro-ASA or Eq-ASA cut-off values. Previous studies<sup>3,4,7</sup> similarly identified regions of coverage deficiency using normative measurement values. Fujii et al.<sup>3</sup> and Goronzy et al.<sup>7</sup> used Eq-ASA values published by Anda et al.<sup>13,16</sup> and found that the mean  $-2$  standard deviations of Eq-AASA and Eq-PASA were 50° and 90°, respectively, which are similar to the Eq-AASA (50.3°) and Eq-PASA (91.3°) cut-off values in the current study.<sup>13,16</sup> This supports

the validity of this study's more objective technique of calculating cut-off values with ROC curves, which also quantify accuracy.

Measuring ASA at both the equatorial and proximal head levels allows acetabular deficiency to be identified more precisely at separate acetabular regions. Pro-ASA accounts for coverage from the most superolateral portion of the acetabulum, which may otherwise be neglected when solely measuring Eq-ASA. This may justify why global deficiency was most prevalent in the current study when classifying hips using Pro-ASA measurements whereas anterior deficiency was most prevalent according to Eq-ASA measurements; the superolateral acetabulum contributes to both anterior and posterior coverage. When using Eq-ASA and Pro-ASA cut-off values, anterior deficiency was still more prevalent than posterior deficiency in dysplastic hips, which is also evident in previous studies<sup>3,7,13</sup> Using radial acetabular coverage measurements, Nepple et al.<sup>4</sup> found that global deficiency was most prevalent (36%), followed by posterolateral deficiency (34%) and anterosuperior deficiency (30%), although the proportions of these deficiency patterns were not significantly different. This distribution of deficiency patterns is different from those in the current study because our deficiency patterns were defined using ASA in single discrete locations at either the equatorial or proximal level. Nepple et al. identified regions as deficient in coverage if they had at least a 3-quarter hour region of radial acetabular undercoverage in the anterior, lateral (superior), or posterior clockface regions; however, solely using radial quarter-hour coverage to identify deficiency patterns neglects the contributing coverage from adjacent acetabular regions. Pro-ASA is more useful for identifying coverage deficiency in the proximal acetabulum than radial quarter-hour coverage because it measures overall anterior and posterior coverage and includes the contributions from the superolateral acetabulum that is conventionally measured using LCEA. Furthermore, this study found that hips without a diagnosis of acetabular dysplasia can present with deficiency patterns also found in dysplastic hips (Tables 4 and 5). This may suggest that ASA can



indicate deficient coverage in hips without dysplasia. Previous research has shown that hips with an LCEA greater than 25° can still have deficient acetabular coverage.<sup>17</sup> Therefore, ASA measured at the proximal and equatorial levels could be a useful supplement to other clinical criteria when identifying acetabular deficiency.

The strength of correlation between AA and ASA increased as the ASA measurement location approached the equatorial level, possibly because of the equatorial location of the AA measurement. Fujii et al.<sup>3</sup> correlated ASA along the acetabular clockface with AA and also found stronger correlations with AA at the equatorial level. The negative correlation between AA and AASA in this study is likely a result of anteversion decreasing anterior coverage and contributing to posterior coverage. Conversely, the strength of correlation between LCEA and both posterior and anterior ASA was highest at the Pro-ASA measurement location, which may be justified from how LCEA is measured in the proximal region of the acetabulum. Irie et al.<sup>15</sup> correlated mean radial coverage of the femoral head for defined segments along the acetabular clockface with LCEA and similarly found stronger correlations for the superior segments near the proximal measurement location. Because LCEA and AA are measured in 2-dimensions, they cannot provide an accurate insight into specific coverage deficient regions. LCEA may underestimate the extent of anterior deficiency while AA may underestimate superior deficiency, indicating the need for measuring ASA in 3-dimensions to correctly identify regions of deficient acetabular coverage.

This study also correlated AASA and PASA with pelvic tilt. Although there was a significant difference in pelvic tilt between dysplastic and non-dysplastic hips, Pearson's correlation analysis found no strong or moderate correlation between pelvic tilt and any ASA measurement. Positive pelvic tilt may have contributed to anterior coverage and decreased posterior coverage. This may explain why there was a weak significantly positive correlation between pelvic tilt and equatorial and proximal AASA, and a weak significantly negative correlation between pelvic tilt and proximal PASA. Bosse et al. measured AASA and PASA at different pelvic tilt angles using a human pelvis model and found a linear relationship between change in pelvic tilt and ASA.<sup>18</sup> However, anatomic variations between subjects in the current study likely masked the effects of pelvic tilt on ASA.

In conclusion, characterizing acetabular coverage in 3D allows for specific regions of acetabular coverage to be identified. This is crucial for preoperative planning of the correction of hip dysplasia via PAO, which requires correctly identifying regions of deficient acetabular coverage. Because this is the first study to define Pro-ASA and apply its measurements towards characterizing deficiency patterns in hip dysplasia, further investigation is necessary using a larger sample size to confirm our findings. Measuring ASA along the axial axis is a useful and convenient method for quantifying acetabular coverage and classifying dysplastic hips into deficiency patterns, including when measuring Pro-ASA. This would allow surgeons to directly target the region of coverage deficiency when rotating the acetabulum during a PAO. Therefore, future studies would be needed to evaluate the surgical outcomes of measuring

ASA along the axial axis in preoperative planning and surgical execution.

## AUTHOR CONTRIBUTIONS

All authors provided substantial contributions to [1] research design and the acquisition, analysis and interpretation of data [2]; drafting the paper or revising it critically; and [3] approval of the submitted and final versions.

## ACKNOWLEDGMENTS

The authors thank Sean M. Akers, Karla J. Crook, and Caroline Drain for their support of research coordination. The Curing Hip Disease Fund and Jackie and Randy Baker Research Funds provided partial salary support for research personnel. One of the authors (Chadi Nahal) has received funding from the National Center For Advancing Translational Sciences of the National Institutes of Health under Award Number TL1TR002344. The content is solely the responsibility of the authors and does not necessarily represent the official views of the National Institutes of Health.

## ORCID

Emma R. Payne  <http://orcid.org/0000-0003-3283-8089>

Cecilia Pascual-Garrido  <http://orcid.org/0000-0001-7487-4753>

## REFERENCES

1. Wilkin GP, Ibrahim MM, Smit KM, Beaulé PE. A contemporary definition of hip dysplasia and structural instability: toward a comprehensive classification for acetabular dysplasia. *J Arthroplasty*. 2017;32:S20-S27.
2. Tannast M, Hanke MS, Zheng G, Steppacher SD, Siebenrock KA. What are the radiographic reference values for acetabular under- and overcoverage? *Clin Orthopae Related Res*. 2015;473:1234-1246.
3. Fujii M, Nakashima Y, Sato T, Akiyama M, Iwamoto Y. Acetabular tilt correlates with acetabular version and coverage in hip dysplasia. *Clin Orthopae Related Res*. 2012;470:2827-2835.
4. Nepple JJ, Wells J, Ross JR, Bedi A, Schoenecker PL, Clohisy JC. Three patterns of acetabular deficiency are common in young adult patients with acetabular dysplasia. *Clin Orthopae Related Res*. 2017;475:1037-1044.
5. Goronzy J, Blum S, Hartmann A, et al. Is MRI an adequate replacement for CT scans in the three-dimensional assessment of acetabular morphology? *Acta Radiol*. 2019;60:726-734.
6. Wyles CC, Vargas JS, Heidenreich MJ, et al. Hitting the target: natural history of the hip based on achieving an acetabular safe zone following periacetabular osteotomy. *J Bone Jt Surg*. 2020;102:1734-1740.
7. Goronzy J, Franken L, Hartmann A, et al. Acetabular- and femoral orientation after periacetabular osteotomy as a predictor for outcome and osteoarthritis. *BMC Musculoskelet Disord*. 2020;21:846.
8. Clohisy JC, Carlisle JC, Beaulé PE, et al. A systematic approach to the plain radiographic evaluation of the young adult hip. *J Bone Jt Surg*. 2008;90(suppl 4):47-66.
9. Merle C, Grammatopoulos G, Waldstein W, et al. Comparison of native anatomy with recommended safe component orientation in total hip arthroplasty for primary osteoarthritis. *J Bone Jt Surg*. 2013;95:e172.
10. Zahn RK, Grotjohann S, Ramm H, et al. Pelvic tilt compensates for increased acetabular anteversion. *Int Orthop*. 2016;40:1571-1575.

11. Koo TK, Li MY. A guideline of selecting and reporting intraclass correlation coefficients for reliability research. *J Chiropr Med*. 2016;15:155-163.
12. Copay AG, Subach BR, Glassman SD, Polly Jr DW, Schuler TC. Understanding the minimum clinically important difference: a review of concepts and methods. *Spine J*. 2007;7:541-546.
13. Anda S, Terjesen T, Kvistad KA, Svenningsen S. Acetabular angles and femoral anteversion in dysplastic hips in adults: CT investigation. *J Comput Assist Tomogr*. 1991;15:115-120.
14. Ashwell ZR, Flug J, Chadayammuri V, Pascual-Garrido C, Garabekyan T, Mei-Dan O. Lateral acetabular coverage as a predictor of femoroacetabular cartilage thickness. *J Hip Preserv Surg*. 2016;3:262-269.
15. Irie T, Espinoza Orias AA, Irie TY, et al. Computed tomography-based three-dimensional analyses show similarities in anterosuperior acetabular coverage between acetabular dysplasia and borderline dysplasia. *Arthroscopy: J Arthroscopic Related Surg*. 2020;36:2623-2632.
16. Anda S, Svenningsen S, Dale LG, Benum P. The acetabular sector angle of the adult hip determined by computed tomography. *Acta Radiol, Diagn*. 1986;27:443-447.
17. Salih S, Grammatopoulos G, Burns S, Hall-Craggs M, Witt J. Do acetabular parameters measured on 2D imaging correlate with CT, and can lateral centre-edge angle predict femoral head coverage? *Bone Joint Open*. 2022;3(1):12-19.
18. van Bosse HJP, Lee D, Henderson ER, Sala DA, Feldman DS. Pelvic positioning creates error in CT acetabular measurements. *Clin Orthopae Related Res*. 2011;469:1683-1691.

**How to cite this article:** Nahal C, Slullitel PA, Kamenaga T, et al. Acetabular coverage analysis of the proximal femoral head accurately characterizes dysplastic acetabular morphology. *J Orthop Res*. 2022;1-10. doi:10.1002/jor.25479