

## Canine Acanthomatous Ameloblastoma (CAA)

with Ingrid Tundo DVM MRCVS Resident in Dentistry and Oral Surgery

CAA is a benign tumor, but shows aggressive local behavior and frequent invasion into bone of the underlying mandible or maxilla. The rostral mandible is the most common site and they do not metastasize.

Mac is an entire, male English Springer Spaniel 7 years old. He developed an oral mass affecting his right mandible in July 2017. The referring veterinarian performed an incisional biopsy which confirmed the presence of a 'Canine Acanthomatous Ameloblastoma' (CAA).

Mac was referred to the dentistry and oral surgery service at Eastcott Referrals. A high resolution computed tomography scan was performed of Mac's jaw with a GE Lightspeed Four Slice CT Scanner in order to localise the tumour and define his margins. A 3D model was printed for planning of the surgery and preoperative plate contouring.

To achieve clean margins around the mass a rostral segmental mandibulectomy was performed from rostral to the right mandibular canine to caudal to the right mandibular second premolar.

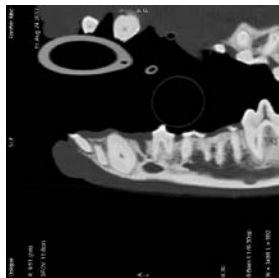
After 4 weeks Mac was presented for jaw reconstruction. At this point, jaw function was good,

but both mandibles were unstable and there was evidence of impaired function when picking up food.

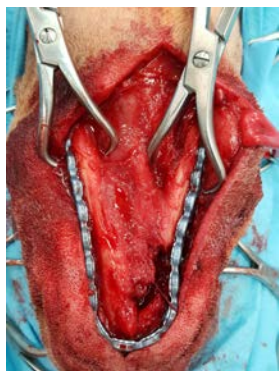
A ventral approach was made to both mandibles. A pre-contoured 20 hole Synthes 2.4m reconstruction plate was fixed to the mandible. Mac's occlusion was evaluated at this point and it was normal. A 2.7 cm section of Mastergraft compression resistant matrix, impregnated with BMP (Inductos - Medtronic) at 0.5mg/ml was placed in the defect and a tight soft tissue capsule was created to stabilize the graft.

Two months after the reconstruction a follow up CT-scan was performed which demonstrated good new bone formation and a complete bridge between the ends of the bone resection. There was no evidence of screw loosening.

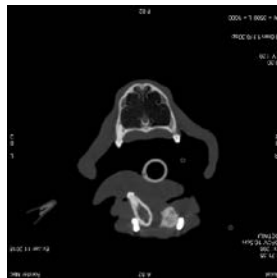Significant bone defects after segmental mandibulectomy allow mandibular drift towards the side of the resection resulting in malocclusion, difficulty in eating and temporomandibular joint pain. Though segmental mandibulectomy without reconstruction produces acceptable and functional results in most cases, there are clear benefits to jaw reconstruction where this is possible.



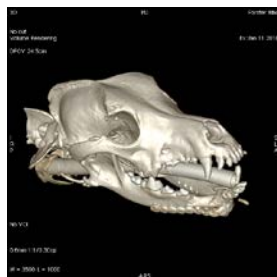**Figure 1:** Intraoperative picture showing a pre-contoured 20-hole Synthes 2.4m reconstruction plate fixed to the mandible. Notice the defect caused by the resection of an acanthomatous ameloblastoma.



**Figure 2:** Sagittal view of a CT scan showing the presence of an invasive mass at the level of the right first mandibular premolar in a dog.




**Figure 3:** Transversal view of a CT scan showing new bone formation after mandibular reconstruction.




**Figure 4:** Right lateral view of a three-dimensional reconstruction of a CT scan of the skull of a dog showing new bone formation and a complete bridge between the ends of the bone resection after a rostral segmental mandibulectomy.

## Dermatology has Arrived

We are pleased to announce that Natalie Barnard RCVS Recognised and European Specialist in Veterinary Dermatology has now joined the referral team. If you have any dermatology cases that you wish to refer we are now accepting referrals. She is also happy to discuss and advise on any problematic dermatology cases you might have.



**Natalie will be discussing Otitis Externa in Dogs at our free CPD evening on 17th April 2018 (see back page).**



A 3D printer was used to print a 3D model for the planning of this surgery and preoperative plate contouring. We find 3D printing for surgery pre-planning increasingly useful and have recently invested in our own 3D printer.



**Congratulations to Ms Doris Gangl from Cogges Vets in Witney who won £200 to spend at The Nut Tree Inn in Murcott.**

# Silke Stein Joins the Soft Tissue Specialist Team



We welcome Silke to the Soft Tissue Referral Team. Silke is an experienced Specialist and is interested in all aspects of soft tissue surgery, particularly in wound management and reconstruction and oncological surgeries.

Silke qualified from Leipzig University, Germany, in 2002. She completed an internship at the Small Animal Hospital of the University of Berlin, during which she also finished her doctoral thesis. In 2006 she became a resident of the European College of Veterinary Surgeons, first in a private referral hospital in the UK and then at the University of Cambridge. She passed her RCVS certificate for Small Animal Surgery in 2010 and the ECVS Diploma in Small Animal Surgery in

2012. After working at referral hospitals in the UK, Silke moved back to Germany at the end of 2012, working as a Soft Tissue Surgeon at the small animal hospital in Berlin. Silke has regularly lectured in Germany and Switzerland on surgical topics.

## Soft Tissue Surgery Case: Sentinel Lymph Node Identification in a Dog with Nasal Squamous Cell Carcinoma

### “Cadbury”

Cadbury is a 10-year-old Labrador who initially presented with a small ulcer on his nasal planum. This gradually enlarged until Cadbury had a large proliferative and erosive mass (Figure 1). A histological biopsy was taken confirming a diagnosis of Squamous Cell Carcinoma (SCC).

Nasal SCC is the most common malignancy diagnosed affecting the canine nasal planum. It is characterised by being locally invasive whilst also having the potential for metastases to the draining lymph nodes and lungs. Many cases are amenable to resection but this is often declined by owners as any resection of the nasal planum will fundamentally alter the appearance of the dog and this is very hard for many owners to come to terms with. It is therefore imperative that cases are adequately staged prior to surgery to avoid any dogs undergoing this type of invasive surgery unless there is a good chance of cure or at least a reasonable period of remission.

SCC can spread to the draining lymph nodes but the size alone of these lymph nodes is sadly not enough to determine whether or not any metastasis has occurred. Many cases of metastases can be detected

using ultrasound-guided aspiration of these nodes but there is still a significant risk of either a false-negative or even a false-positive result. The gold standard is, therefore, histological evaluation of the draining lymph nodes with extirpation of multiple lymph nodes (e.g. submandibular, parotid and retropharyngeal) usually being recommended to adequately stage a solid neoplasm of the head.

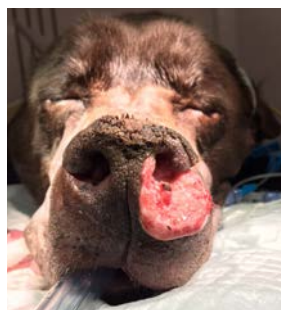
There has been a considerable drive in human surgery to identify the main draining lymph node to a specific tumour site. This lymph node is termed the Sentinel Lymph Node (SLN) and analysis of the SLN should indicate the true stage of the tumour without the need to take out multiple lymph nodes which is associated with considerable morbidity (e.g. lymphedema) in people. Recent work in veterinary patients has shown that similar techniques can be employed. Sometimes the SLN is not the nearest or seemingly most logical lymph node and can be surprisingly distant from the tumour being assessed.

Cadbury had his tumour staged using Computed Tomography (CT) scans. In addition to conventional CT which showed the local extent of his nasal tumour (Fig.

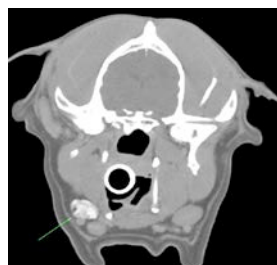
2) and excluded overt pulmonary metastases, multiple enlarged lymph nodes were seen. These lymph nodes may have been enlarged due to either metastases or lymphoid reaction to the inflammation associated with the mass.

Peritumoral injection of contrast agent was then used as a type of indirect lymphography. In Cadbury's case, the lymphatics could be traced from the tumour site to one of the submandibular lymph nodes which were therefore identified as the SLN (Figure 3). Peritumoral vital dye was then injected and Cadbury was taken to theatre where the dye had drained along the lymphatics to colour the SLN blue aiding its identification (fig 4).

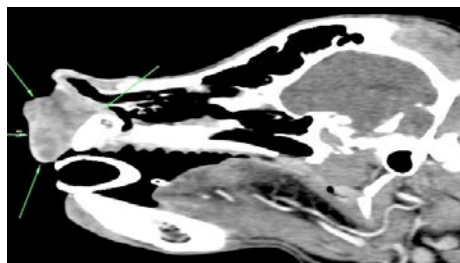
Fortunately, Cadbury's SLN was clear of metastases and so he was later taken to surgery where his nasal planum was resected en-bloc with a rostral maxillectomy. Surgery went well, a modified technique was used which involved rotating the rostral labial tissue dorsomedially to reconstruct a nasal philtrum and to create a nasal vestibule which is more cosmetic than the older techniques of simple excision and mucosal-skin apposition. A clean margin of excision was achieved and Cadbury is now recovering well.



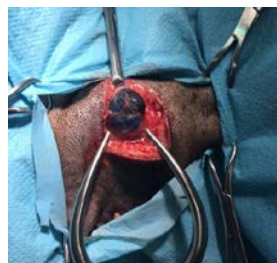**Figure 1:** Preoperative appearance of erosive nasal SCC.



**Figure 3:** Indirect lymphographic CT showing contrast enhancing SLN.



**Figure 2:** Coronal CT showing local extent of tumour.



**Figure 4:** SLN stained blue allowing easy identification.



**Figure 5:** Postoperative appearance following en bloc SCC resection with rostral maxillectomy.

# Thoracoscopy

Thoracoscopy is the application of minimally invasive surgery within the thorax. This requires very similar equipment to that used for laparoscopy and it therefore confers similar advantages to the patient i.e. patients recover faster and experience less postoperative discomfort than those that have equivalent surgeries performed via traditional “open” approaches.

Many patients with thoracic disease are older dogs and so traditional open approaches are often resisted by their owners due to concerns regarding anticipated postoperative discomfort and morbidity. “Keyhole surgery” often allows us to provide a low morbidity alternative approach which is more readily accepted by many such owners.

Examples of procedures that can be performed thoroscopically include (but are not limited to):

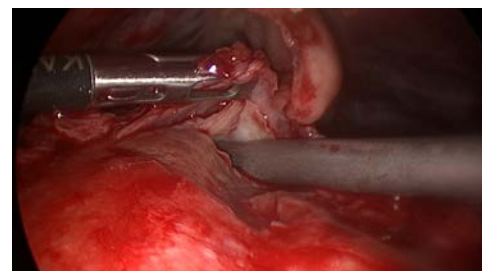
- Pericardiectomy
- Lung lobe biopsy
- Lymph node biopsy
- Pleural biopsy
- Mediastinal debridement (e.g. selected cases of Pyothorax)
- Thoracic duct ligation (for idiopathic Chylothorax)
- Assessment/biopsy of neoplasia
- Exploratory Thoracoscopy

Pericardiectomy is one of the most common therapeutic thoracoscopic procedures that is performed in veterinary patients. Pericardiectomy is indicated in patients that have pericardial effusion that restricts diastolic filling causing cardiac tamponade and associated abdominal effusion. Pericardial effusion can be caused by neoplasia (e.g. haemangiosarcoma, chemodectoma) in which case pericardiectomy is palliative. Most commonly, however, pericardial effusions are judged to be idiopathic and pericardiectomy can be curative in these cases. All cases require full echocardiography prior to surgery in order to preoperatively identify any possible mass lesions that may require biopsy or removal or affect the expected prognosis.

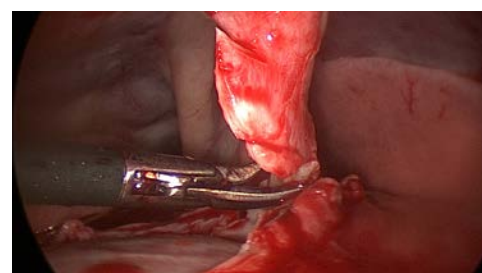
Thoracoscopic sub-total pericardiectomy/pericardial window techniques can be safely performed using 3, 5-10mm incisions. The required section of pericardium is removed and submitted for histology and a chest drain placed to allow evacuation of air from the thorax and monitoring/removal of any postoperative effusion. The majority of dogs are discharged the next day once the drain has been removed. The long-term prognosis (for cases of idiopathic effusion) is excellent.

We are more than happy to discuss any possible referrals with our referring vets including assessing whether or not MIS approaches are suitable for any cases that you may wish to refer.

Please do contact us if you have any queries or want to find out more.



**Figure 1:** The thickened pericardium has been entered and a suction probe is used to remove any residual pericardial effusion.



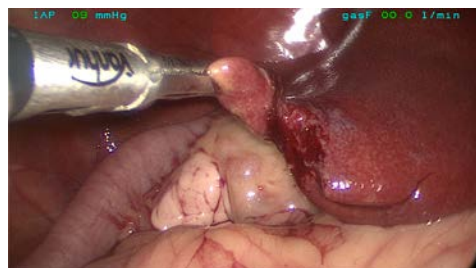
**Figure 2:** A patch of pericardium is resected and submitted for histopathology.

# Minimally Invasive Surgery

Minimally invasive surgery (MIS) is becoming increasingly popular as a surgical approach in human healthcare. Although early procedures were limited to diagnostics, an increasing range of therapeutic interventions are now widely being used and in fact have now been adopted as “standard of care” based on evidence from large clinical trials.

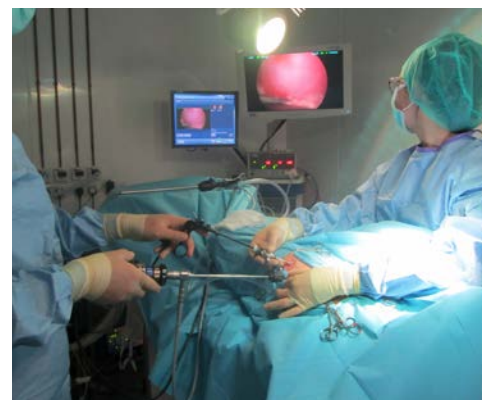MIS is also becoming increasingly popular among veterinary surgeons. The principles of MIS are that it provides a highly magnified, well-lit image of a region of anatomy that would otherwise require a significantly larger incision and higher morbidity for the equivalent procedure to be performed as an “open surgery”. This, therefore, allows the MIS patients to recover faster and experience less postoperative pain than those animals who undergo equivalent open surgery. There are also significant advantages to the surgeon in that it is often easier to access certain areas of anatomy using MIS, procedures are often faster than the equivalent open surgery and anatomy is greatly magnified potentially leading to an increased sensitivity in detecting early disease.

MIS is associated with some disadvantages. These include: a loss of tactile feedback; the magnification of viscera can be confusing and complicated surgeries can take much longer than open surgical techniques. There is also a lack of flexibility once the instrument ports have been placed should the operative plan change during the procedure.



There have been significant advances made in the field of MIS. Laparoscopy/thoracoscopy is no longer limited to being purely diagnostic. Therapeutic interventions such as cholecystectomy, adrenalectomy, pericardiectomy and thoracic duct ligation can now be safely performed providing that appropriate cases are selected.

It must be remembered that MIS is a type of surgical approach. It will not always be appropriate to perform a specific surgery using MIS techniques in a specific patient. Similarly, the surgical objectives have to be able to be accomplished in as safe a manner as the open alternative approach. There is always a risk of having to convert an MIS procedure to an open surgery if unanticipated circumstances are encountered and clients need to be aware of and accept this risk.



## Why refer MIS cases to Eastcott?

We are one of a very small number of centres in the UK with well over 10 years experience in performing MIS procedures. We have accumulated a wealth of experience during that time.

Tim is regularly involved with training vets from all over the UK in the field of laparoscopy/MIS and has lectured both nationally and internationally on the subject.

Eastcott Referrals has invested in top of the range HD systems and advanced instrumentation allowing us to safely perform advanced, complex procedures such as cholecystectomy and thoracic duct ligations.

All referred patients are operated on by one of our experienced referral surgeons who are all recognised specialists.

# RSA Preferred Referral Network Insurance Information

RSA (Royal Sun Alliance) Insurance who underwrite Argos, Homebase, John Lewis, Marks & Spencer, More Than and Tesco, have introduced a 'Preferred Referral Network' list of veterinary referral practices.

Under the RSA's new requirements, if a veterinary surgeon recommends a referral practice that is not part of the network, their client may need to pay £200 towards the referral practice's bill, depending on the conditions of their insurance policy and the date of inception of the policy.

Eastcott Referrals, along with a significant number of the most highly regarded referral practices, has not signed up to join the RSA Preferred Referral Network List. However, your choice and ability to refer to us will remain unchanged.

If RSA chooses to enforce an additional excess for clients referred to us for full referrals, we will, through our free insurance claims service, liaise with RSA and cover any resulting excess up to the £200 penalty. This does not apply to patients referred solely for outpatient services.

All emergency referrals are clearly excluded from the new Preferred Referral Network terms and will be seen as normal.

The RCVS states: "Whilst pet insurers may maintain a list of preferred veterinary service providers, depending on the terms of their policies, they should not take on the professional responsibility of the veterinary surgeon who has the animal under his/her care. Veterinary surgeons remain the most qualified people to decide what is in the best health and welfare interests of their patients."

## FREE CPD Evenings

### Internal Medicine CPD 13<sup>th</sup> March 2018

#### Top tips in the investigation of chronic diarrhoea and an introduction to endoscopy

This evening with our medicine specialists Paul Higgs and Jenny Reeve will cover our approach to chronic diarrhoea in dogs and cats and an introduction to endoscopy use and management with case examples.

With Paul Higgs MA VetMB CertSAM DipECVIM-CA MRCVS, RCVS Recognised and European Specialist in Small Animal Internal Medicine and Jenny Reeve BVSc DipECVIM-CA MRCVS RCVS Recognised and European Specialist in Small Animal Internal Medicine.

### Dermatology CPD 17<sup>th</sup> April 2018

#### The diagnostic approach and management of otitis externa in the dog

This free evening talk will cover the aetiology, investigation and management of otitis externa in the dog. The aim will be to give you practical tips on how to investigate and manage cases in general practice. Natalie will also cover how to make treatment decisions based on your cytology findings.

With Natalie Barnard BVetMed CertVD DipECVD MRCVS RCVS Recognised and European Specialist in Veterinary Dermatology.

**CPD COURSES RUN FROM 7.30PM - 9PM WITH REFRESHMENTS FROM 7PM**

**For more information or to book a place on one of our courses, please visit our website**

## Disciplines at Eastcott Referrals

<b>Soft Tissue Surgery</b> <i>including Laparoscopy</i>	<b>Oral Surgery</b> <i>including Maxillofacial Surgery</i>
<b>Dentistry</b>	<b>Cardiology</b>
<b>Dermatology</b>	<b>Internal Medicine</b>
<b>Ophthalmology</b> <i>including Cataract Surgery</i>	<b>Orthopaedics</b> <i>including Total Hip Replacements</i>
<b>CT &amp; Imaging</b>	<b>Thoracoscopy and Minimally Invasive Surgery</b>

eastcott

REFERRALS

#### Eastcott Referrals

Eastcott Veterinary Hospital  
Edison Park, Dorcan Way, Swindon, Wiltshire SN3 3FR  
(sat nav postcode SN3 3RB)  
Tel: 01793 528341 Fax: 01793 401888  
Email: [referrals@eastcottvets.co.uk](mailto:referrals@eastcottvets.co.uk)  
[www.eastcottreferrals.co.uk](http://www.eastcottreferrals.co.uk)

#### Opening Hours

Monday to Friday:  
7am - 8pm  
Saturday and Sunday:  
8.30am - 8pm

