

Modern definition of mediastinal compartments and the current approach to patients with an anterior mediastinal mass

*Prof. Dr. Pier Luigi Filosso
University of Torino
Department of Thoracic Surgery
C.so Dogliotti,14
10126 Torino
ITALY
pierluigi.filosso@unito.it*

AIMS

- Mediastinum & Mediastinal Compartments: definition
- How to approach the mediastinal masses
- Diagnostic techniques of the mediastinum
- Evaluation and diagnostic approach according to the mediastinal compartments
- Summary and take home messages

SUMMARY

Mediastinum & Mediastinal Compartments: definition

The mediastinum is a virtual space located in the thorax, extending from the thoracic inlet (1st rib) to the diaphragm, between the pleural cavities. The definition of “compartments” within the mediastinum was used to better define the lesions to be found primarily in one of them. The scheme proposed by Shields [1] is recommended and it is the currently most used. It includes an anterior compartment (which extends between the back of the sternum and the anterior surface of the pericardium and the great vessels), a middle (or visceral) compartment (which includes the heart, great vessels, trachea and oesophagus, and is posteriorly bound by the anterior longitudinal ligament (the anterior surface of the vertebral bodies), and a posterior (paravertebral) compartment, which extends from the anterior longitudinal ligament to the posterior ribcage (Figure 1).

The majority of mediastinal lesions are located within the anterior mediastinum (Figure 2).

Figure 3 shows the incidence of mediastinal lesions according to patients’ age interval.

In the anterior compartment, the most common tumors in the childhood are teratomas and lymphoproliferative lesions [2]. Thymic cysts, hygromas and other cystic lesions occur frequently too. In females, with age between 10 and 40 years, lymphomas are the most common tumors, followed by thymomas. In men, malignant germ cell tumors, lymphomas, teratomas and thymomas are more commonly observed in this range of age [3]. In older patients (age > 40 years), thymomas and substernal goiters are frequently observed.

In the middle compartment, the most common lesions are: pericardial and bronchogenic cysts, sarcoidosis or tuberculosis, lymphomas or lymph nodal metastases from primary lung cancer [4].

The most frequent lesions in the posterior compartment are: Schwannomas, neurofibromas, ganglioneuromas and neurofibrosarcomas, even if tuberculosis and other haematopoetic disorders are also detected [5].

How to approach the mediastinal masses

Clinical and anamnestic data (gender, age and mediastinal compartment location) are always of paramount importance to identify and diagnose the mediastinal lesion. Also, the duration of symptoms may orient to its biology: benign lesions are, in fact often asymptomatic, while malignant ones present with cough, dyspnoea, weight loss, fatigue, cardiac tamponade or superior vena cava syndrome. Moreover, “B symptoms” (fever, weight loss and night sweats) may anticipate a lymphoma diagnosis [6]. Thymomas are sometimes associated with particular thymic disorders and paraneoplastic syndromes (Myasthenia Gravis, pure red cell aplasia, hypogammaglobulinemia) [7].

Diagnostic techniques of the mediastinum

Thoracic CT scan with intravenous contrast [8] and sometimes MRI are the 2 most effective radiological diagnostic tools to evaluate a mediastinal lesion [9]. Through the CT/MRI findings, a presumptive diagnosis is oftentimes possible, making a cyto/histologic tumor confirmation useless. Teratoma, thymoma or substernal goiters usually do not require other diagnostic procedures, and can be resected upfront. PET scan is useful to determine the biological activity (and therefore the biological behaviour) of a mediastinal tumor, and it is employed as a part of patient’s preoperative workup, especially in case of large and invasive masses.

Evaluation and diagnostic approach according to the mediastinal compartments

In most cases, TC (or MRI) findings are sufficient to diagnose the mediastinal lesion (especially in case of: thymoma, germ cell tumor, teratoma, substernal goiter). A cyto-histological tumor confirmation is needed when equivocal CT images are present, or in case of suspected lymphoma, or when a primarily unresectable thymoma should be treated with induction therapy. A surgical biopsy is almost always diagnostic and the technique depends upon the anatomical location. Mediastinoscopy or anterior mediastinotomy are two surgical options; figure 4 shows the different thoracic regions accessible by these procedures. Another surgical alternative is Video Assisted Thoracic Surgery (VATS). Minimally invasive techniques (EBUS, EUS, core biopsy) may be regarded as an effective alternative to a surgical mediastinal exploration in selected cases [10].

SUMMARY AND TAKE HOME MESSAGES

Optimal evaluation and diagnosis of mediastinal tumors require an integrated clinical, radiological and histological approach. The clinical approach includes taking in account the following: age, sex, presence/duration of symptoms and associated paraneoplastic conditions. The radiological approach includes CT scan with intravenous contrast; CT scan is essential to assign the tumor to one of the mediastinal anatomic compartments. MRI and PET-CT are used on a selective basis. Histological confirmation is most often needed for suspected lymphomas and in locally advanced/unresectable thymic tumors.

More than half of the tumors are in the anterior region, the remaining are equally distributed in the visceral and paravertebral regions.

IMAGES

Figure 1: The Shields' mediastinal compartment scheme

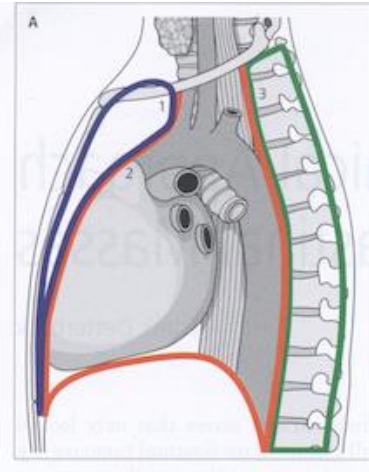


Figure 2: Mediastinal masses: incidence by Compartments

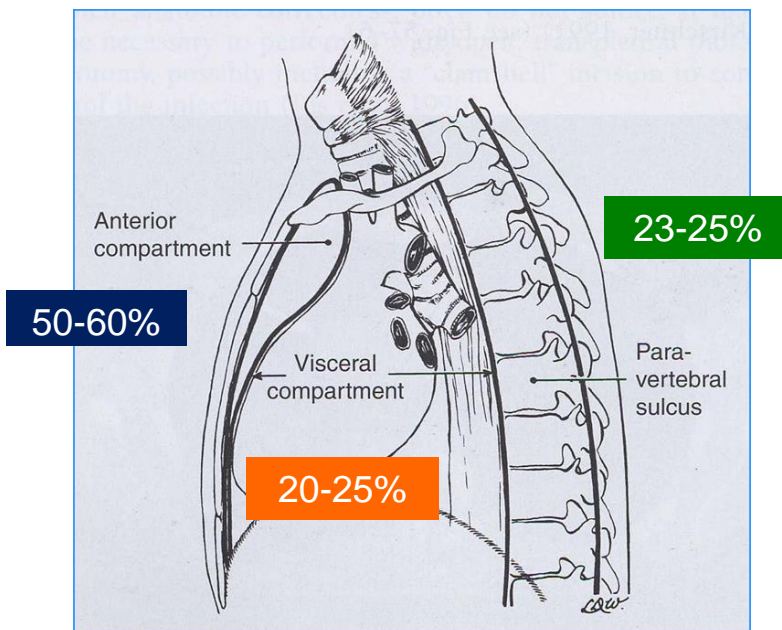
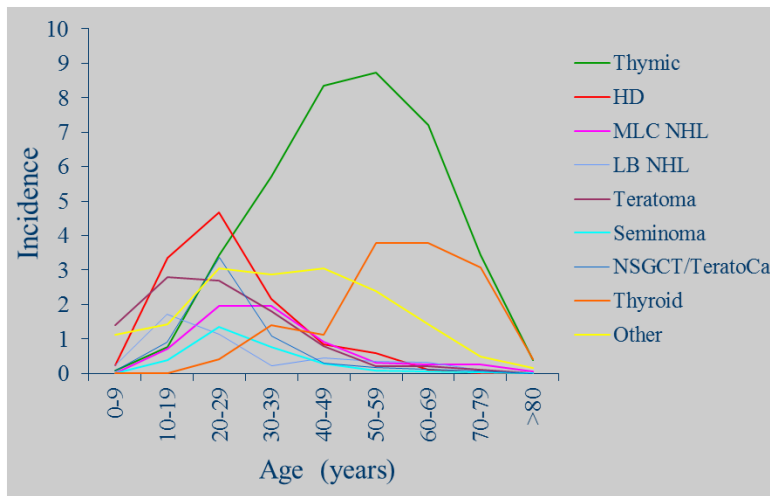
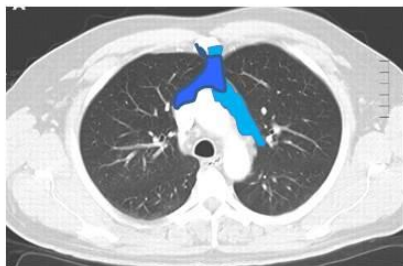

Figure 3: Mediastinal lesions incidence according to the patients' age intervals

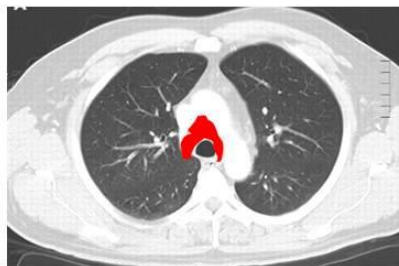

Courtesy of Prof. F. Detterbeck

Figure 4: Mediastinal regions accessible through mediastinoscopy/mediastinotomy



Thoracic regions accessible through an anterior mediastinotomy



Thoracic regions accessible through a mediastinoscopy

REFERENCES

1. Shields TW: Primary tumors and cysts of the mediastinum. In: Shields TW, LoCicero J, Reed CE, Feins RH, eds. General thoracic surgery. 2nd edition Philadelphia: Lea & Febiger; 1983:927-954
2. Mullen B, Richardson JD: Primary anterior mediastinal tumors in children and adults. Ann Thorac Surg 1986;42:338-345

3. Azarow KS, Pearl RH, Zurcher R, Edwards FH, Cohen AJ: Primary mediastinal masses. A comparison of adult and pediatric populations. *J Thorac Cardiovasc Surg.* 1993 Jul;106:67-72
4. Whooley BP, Urschel JD, Antkowiak JG, Takita H: Primary tumors of the mediastinum. *J Surg Oncol.* 1999;70:95-99
5. Davis RD Jr, Oldham HN Jr, Sabiston DC Jr: Primary cysts and neoplasms of the mediastinum: recent changes in clinical presentation, methods of diagnosis, management, and results. *Ann Thorac Surg.* 1987;44:229-237
6. Petersdorf S: Mediastinal lymphomas. In: Wood DE, Thomas CR Jr eds. *Mediastinal tumors: update 1995.* New York: Springer-Verlag; 1995;27-36
7. Detterbek FC, Parsons AM: Thymic tumors. *Ann Thorac Surg.* 2004;77:1860-1869
8. Nejatheid M, Strashun AM: CT vs. iodine scanning in diagnosis of mediastinal thyroid. *AJR Am J Roentgenol.* 1982;139:834-835
9. Boiselle PM: Mediastinal masses. In: McLoud TC ed. *Thoracic radiology: the requisites.* St.Louis: Mosby; 1998:431-462
10. Marchevsky A, Marx A, Ströbel P, Suster S, Venuta F, Marino M, Yousem S, Zakowski M: Policies and reporting guidelines for small biopsy specimens of mediastinal masses. *J Thorac Oncol.* 2011;6:S1724-1729