

Series Editors

Bernhard A. Herzog

John P. Greenwood

Sven Plein



Cardiovascular Magnetic Resonance

Congenital Heart Disease Pocket Guide

Bernhard A. Herzog

Ananth Kidambi

George Ballard

First Edition 2014

Congenital Pocket Guide

Foreword

Standard Views

Difficult Scans

Sequential
Segmental Analysis

Shunts

AV Disease /
Aortic Coarctation

Tetralogy /
Pulmonary Atresia

TGA

Single Ventricle

Ebstein Anomaly

Coronary Artery
Anomalies

References
Terminology

Series Editors

Bernhard A. Herzog
John P. Greenwood
Sven Plein

Authors

Bernhard A. Herzog
Ananth Kidambi
George Ballard



Foreword

The role of cardiovascular magnetic resonance (CMR) in evaluating the adult population with congenital heart disease continues to expand. This pocket guide aims to provide a day-to-day companion for those new to congenital CMR and for those looking for a quick reference guide in routine practice. The booklet gives an overview of the most common abnormalities and interventions as well as post-operative complications. It also provides typical scan protocols, key issues and a guide for reporting for each topic.

Bernhard A. Herzog

Ananth Kidambi

George Ballard


The Cardiovascular Magnetic Resonance Pocket Guide represents the views of the ESC Working Group on Cardiovascular Magnetic Resonance and was arrived at after careful consideration of the available evidence at the time it was written. Health professionals are encouraged to take it fully into account when exercising their clinical judgment. This pocket guide does not, however, override the individual responsibility of health professionals to make appropriate decisions in the circumstances of the individual patients, in consultation with that patient and, where appropriate and necessary, the patient's guardian or carer. It is also the health professional's responsibility to verify the applicable rules and regulations applicable to drugs and devices at the time of prescription.

We acknowledge the support and advice we have received from Emanuela Valsangiacomo Buechel and James Oliver.

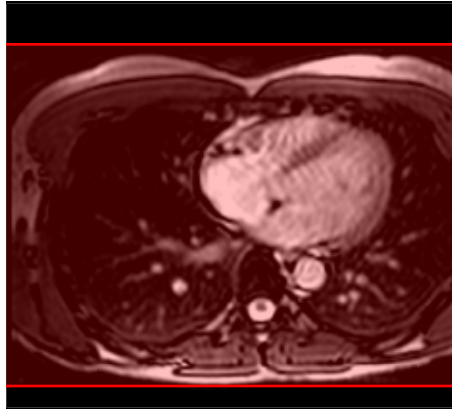
[Index](#)

Standard Views

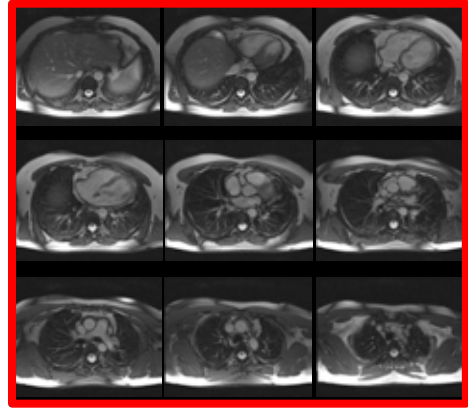
- Anatomical Stacks -



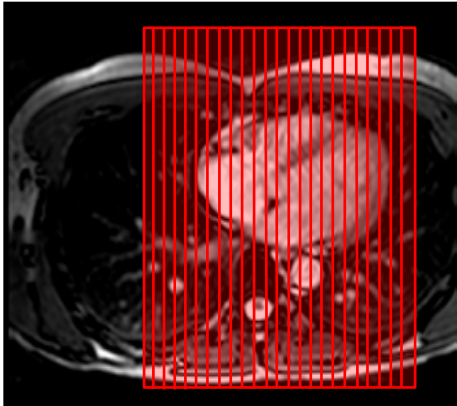
Sagittal localizer



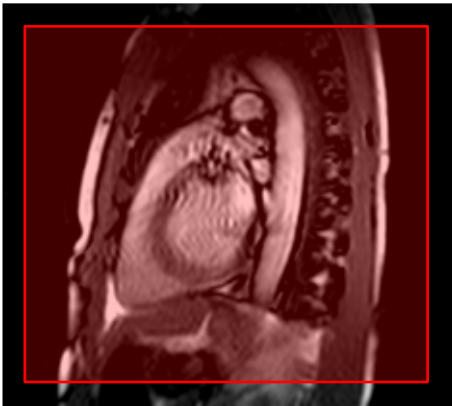
Transaxial localizer



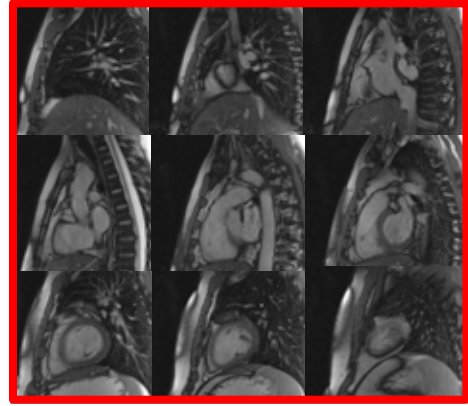
Transaxial stack



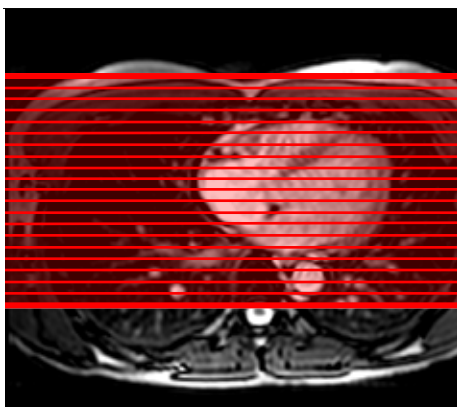
Transaxial localizer



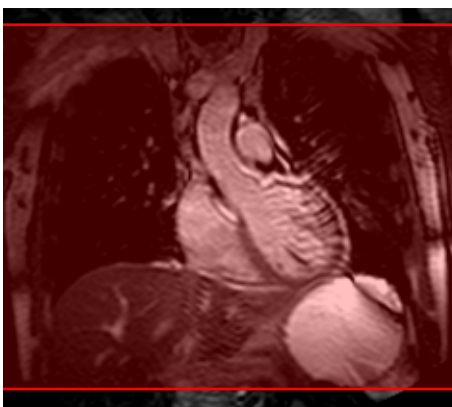
Sagittal localizer



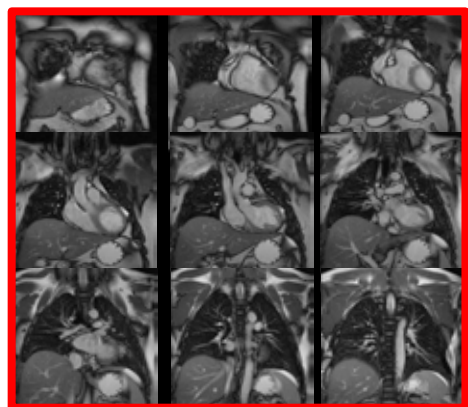
Sagittal stack



Transaxial localizer



Coronal localizer

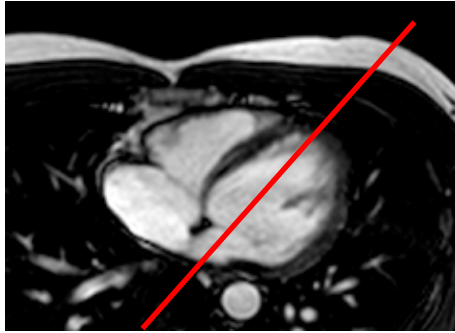


Coronal stack

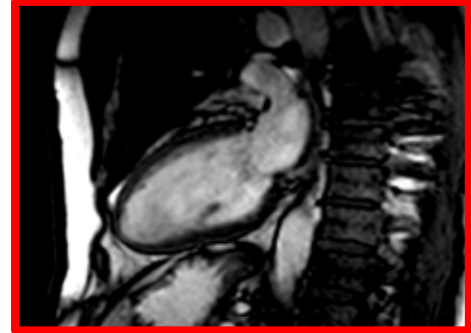
Index

Standard Views

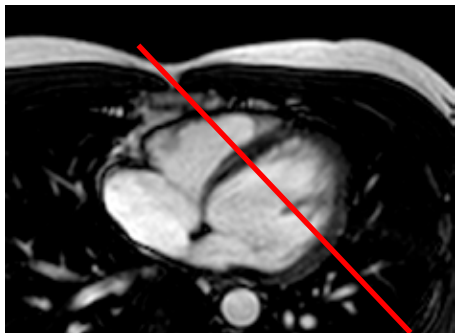
- Cine Imaging -



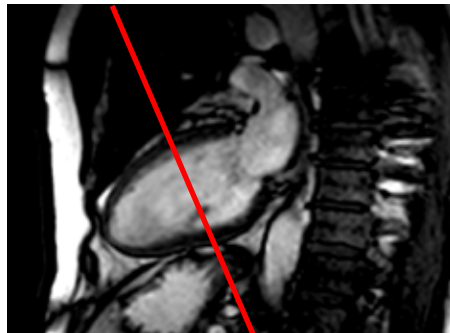
Transaxial stack



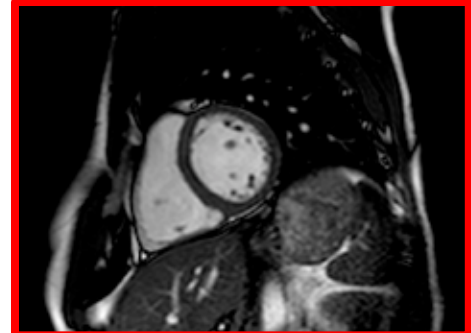
pVLA



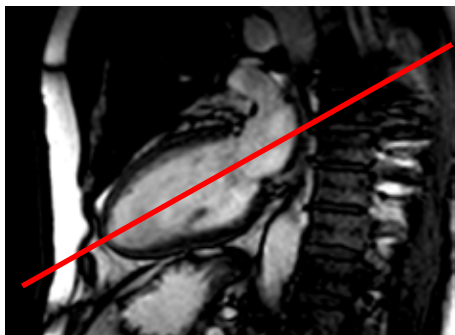
Transaxial stack



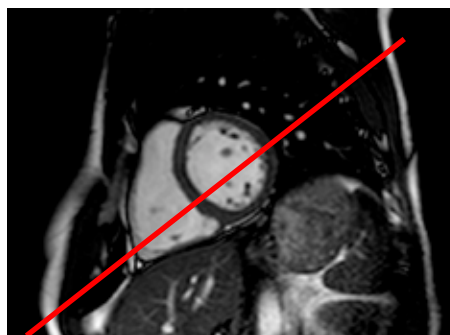
pVLA



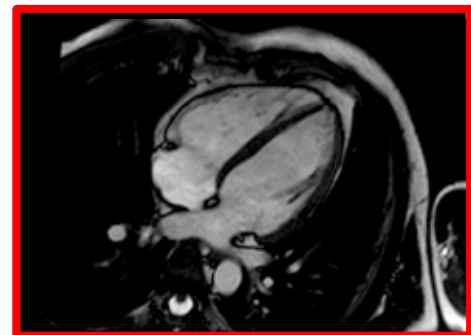
pSA



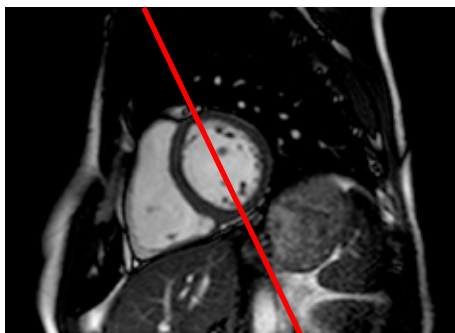
pVLA



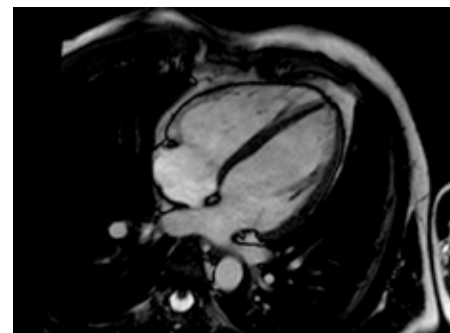
pSA



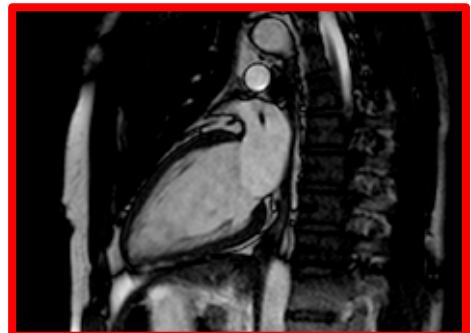
HLA



pSA



HLA



VLA

Simplified planning:


Use pVLA, pHLA and pSA instead of VLA, HLA and SA (see LV stack)

Synonyms:


VLA = 2CH; HLA = 4CH

[Index](#)

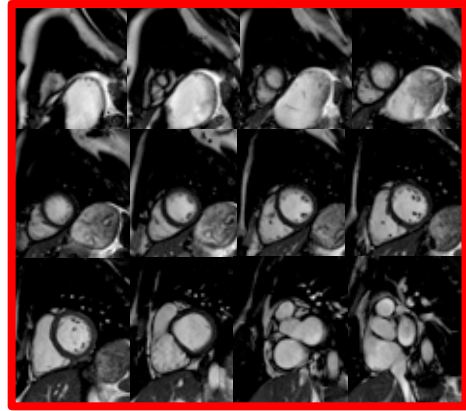
Standard Views - Cine Imaging -



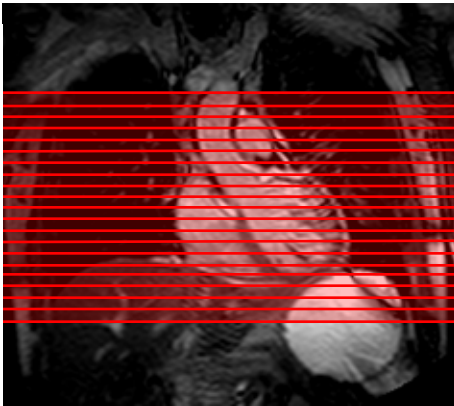
HLA



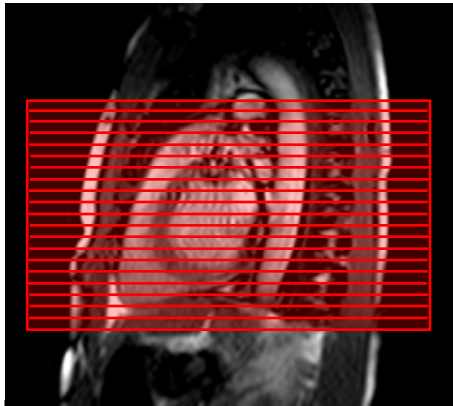
VLA



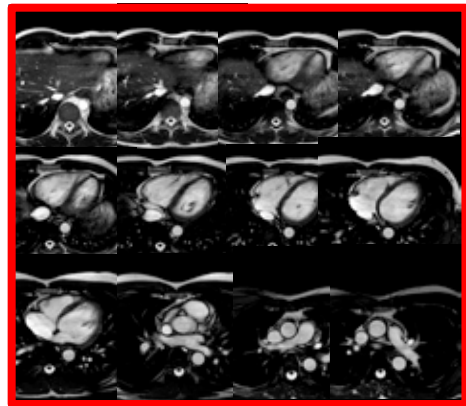
SA cine stack



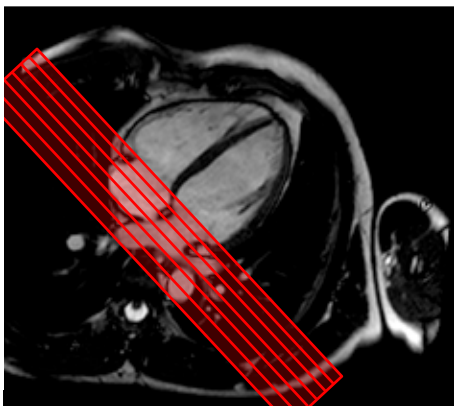
Coronal localizer



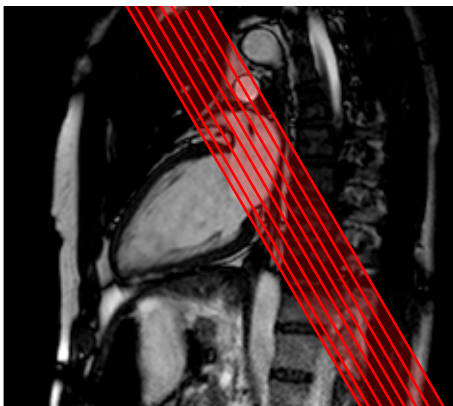
Sagittal localizer



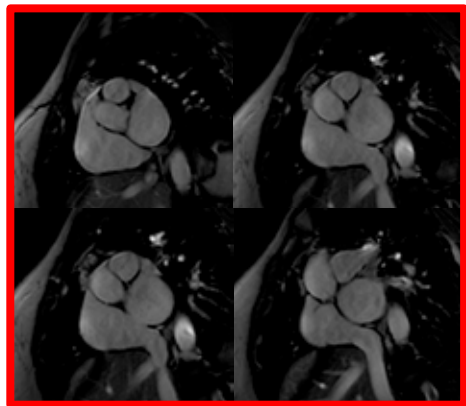
Transaxial cine stack[©]



HLA



VLA



Atrial cine stack*

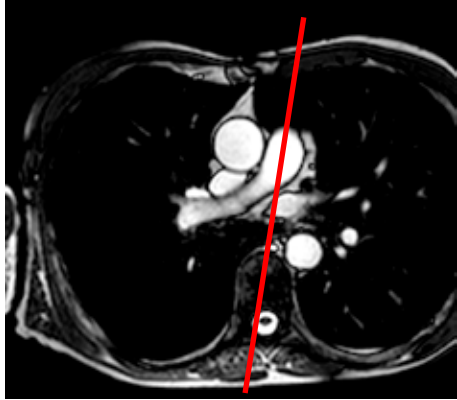
[©] RV measurements alternatively from SA LV stack
Important is consistency for reproducibility

* Alternatively use HLA stack

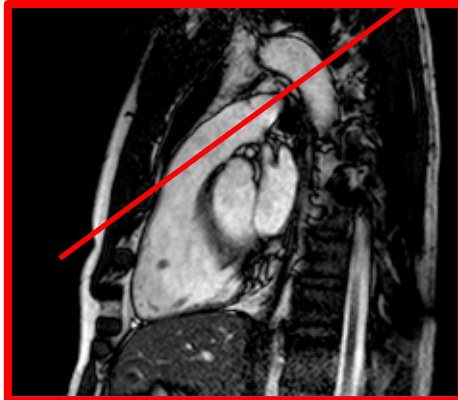
Index

Standard Views

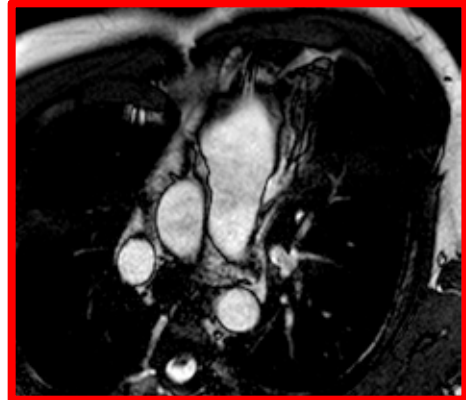
- Cine Imaging -



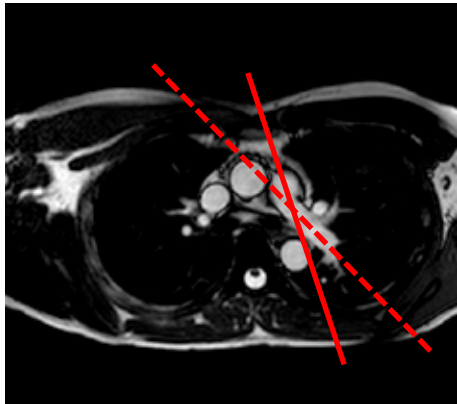
Transaxial stack



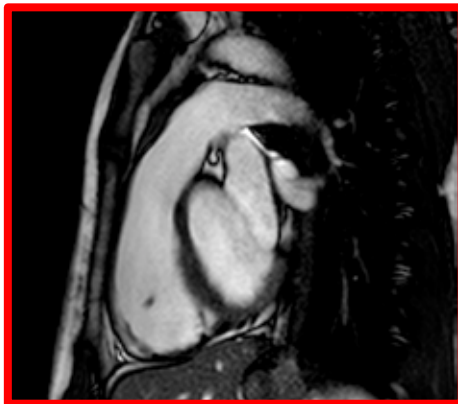
Sagittal RVOT



Coronal RVOT



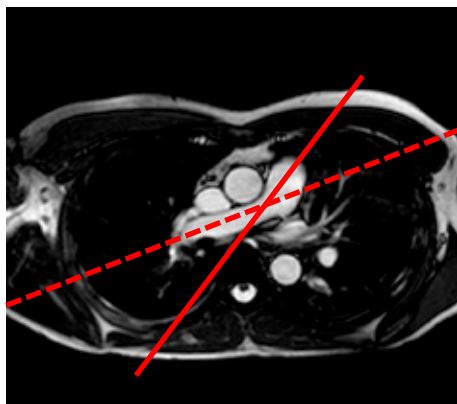
Transaxial stack



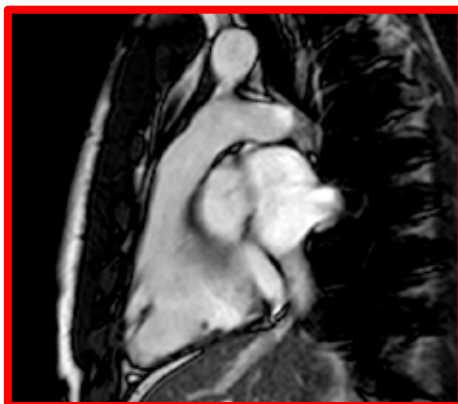Proximal LPA^o



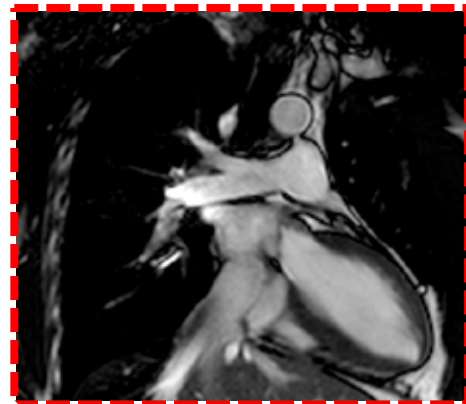
Distal LPA^o



Transaxial stack



Proximal RPA^o

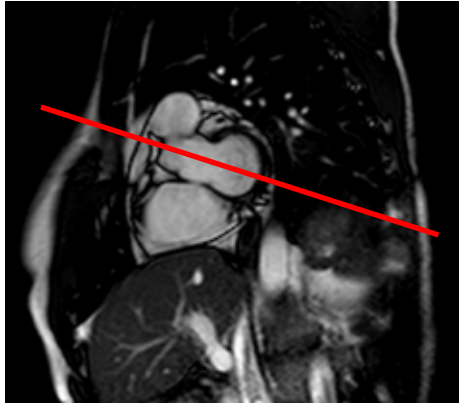


Distal RPA^o

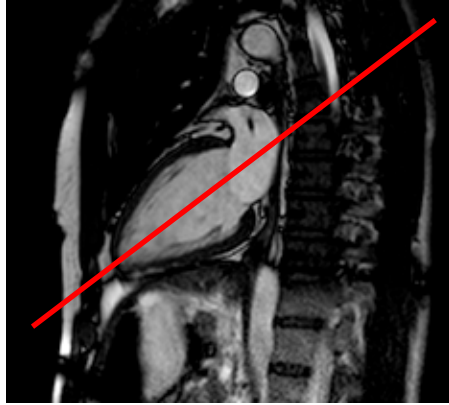
^o Full bifurcation planned from transaxial and coronal localizer

Index

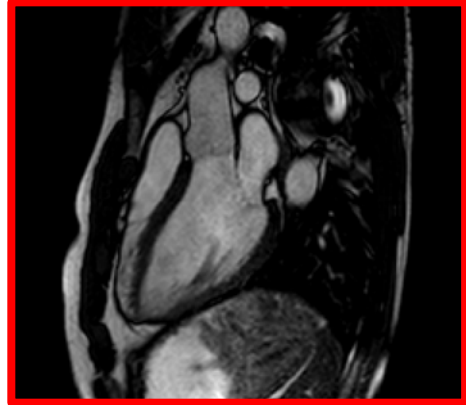
Standard Views - Cine Imaging -



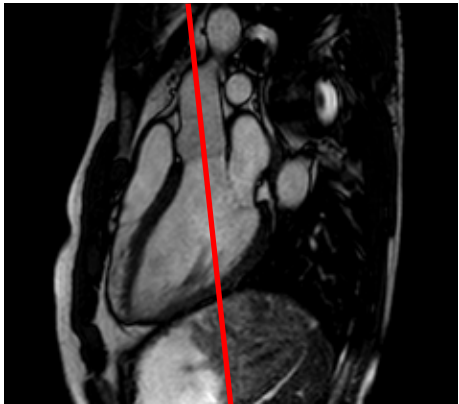
Basal SA of LV stack



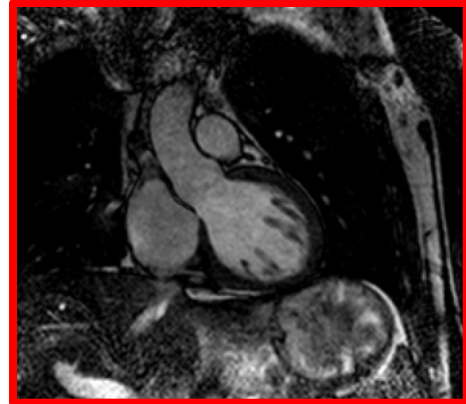
VLA through apex



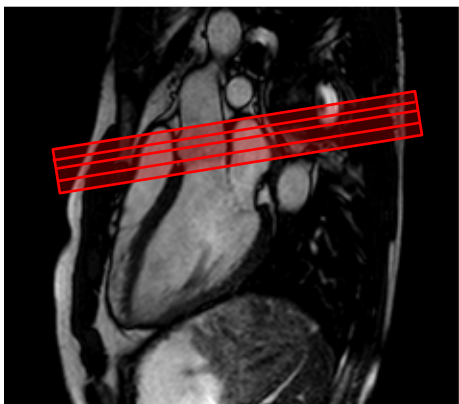
Sagittal LVOT



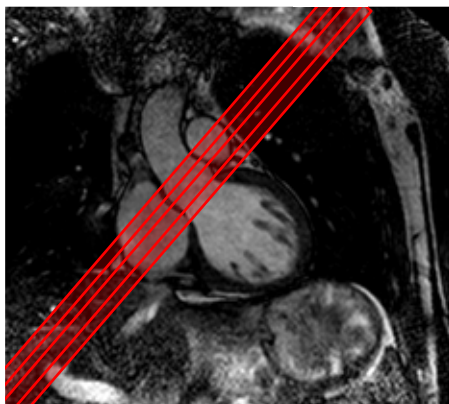
Sagittal LVOT



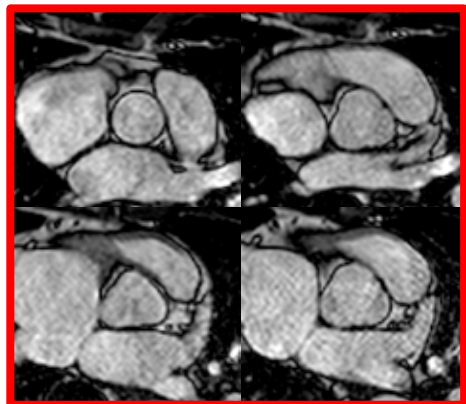
Coronal LVOT



Sagittal LVOT



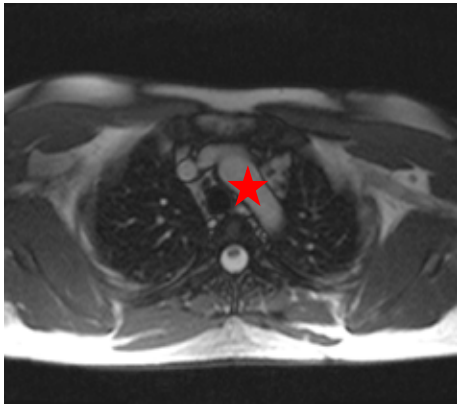
Coronal LVOT



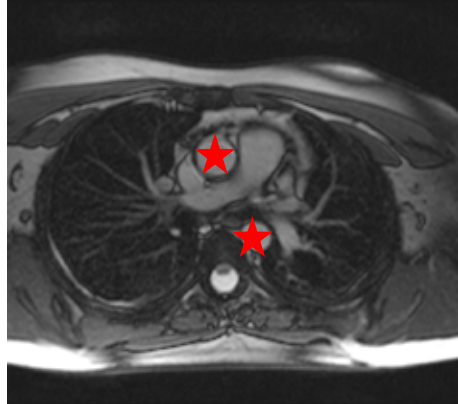
Aortic valve /root

Standard Views

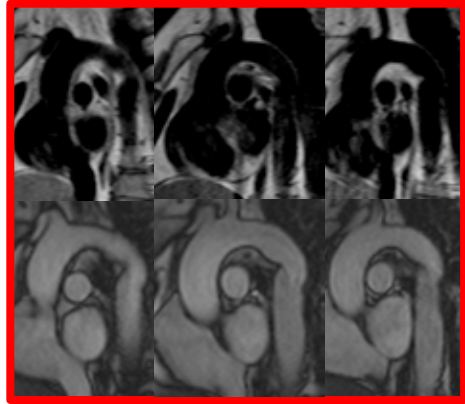
- Cine Imaging -



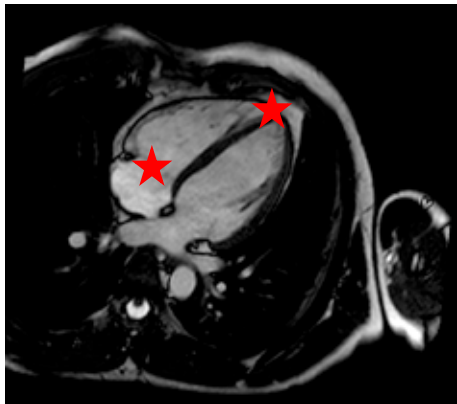
Transaxial



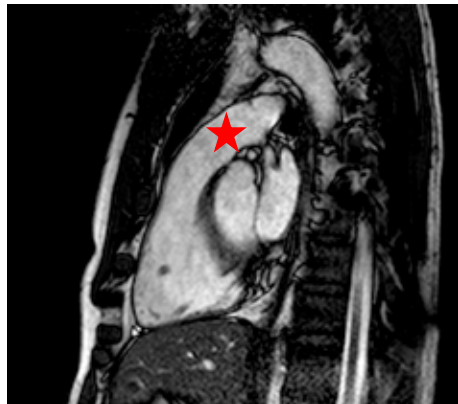
Transaxial



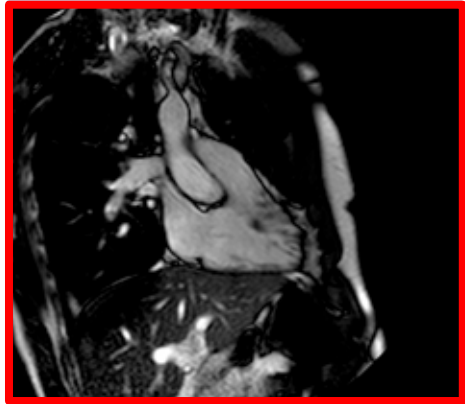
Aortic arch



HLA

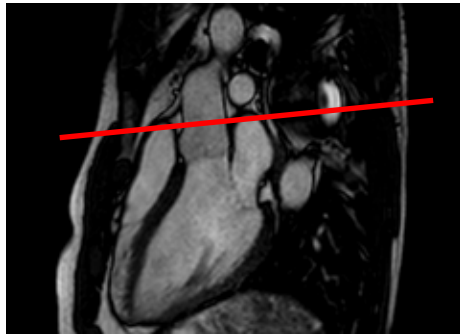


RVOT

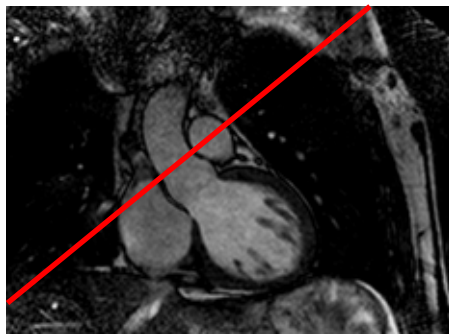


RV in-/outflow


Standard Views - Flow Imaging -



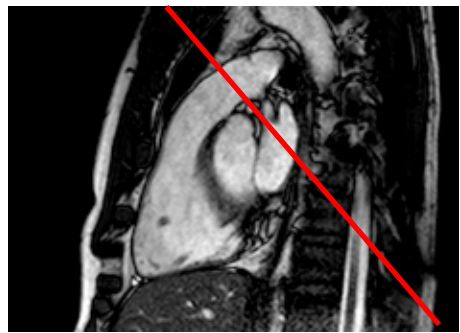
Sagittal LVOT



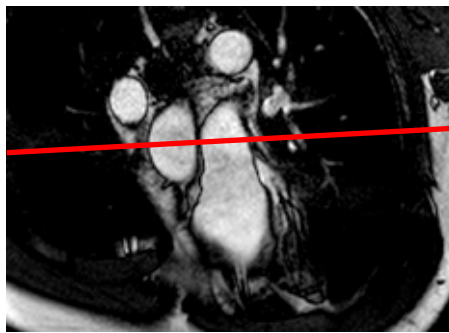
Coronal LVOT



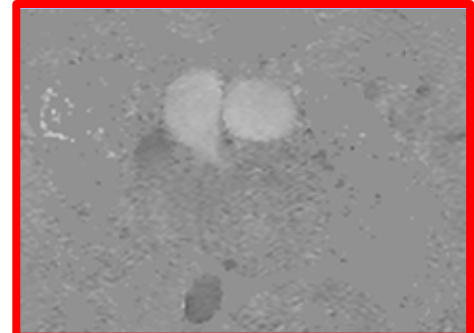
Ao flow



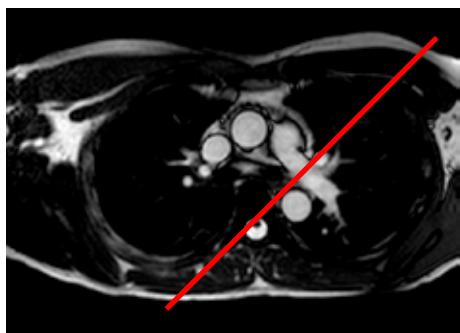
Sagittal RVOT



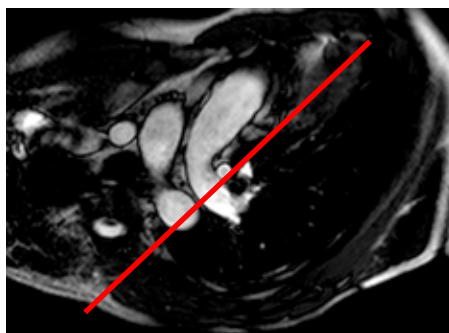
Coronal RVOT




MPA flow



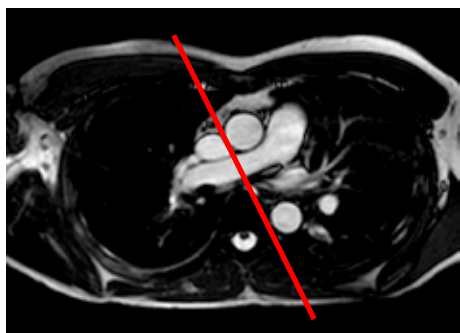Transaxial stack



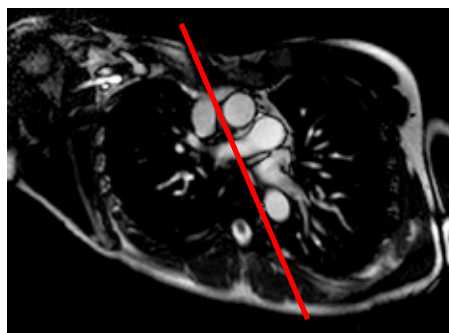
LPA cross-cut



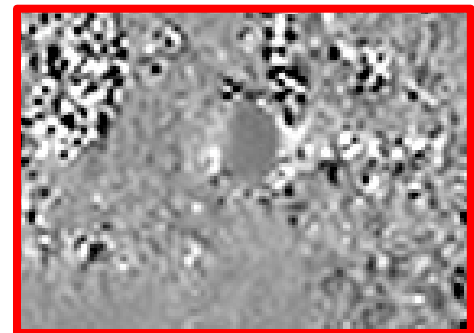
LPA flow®



Transaxial stack



RPA cross-cut



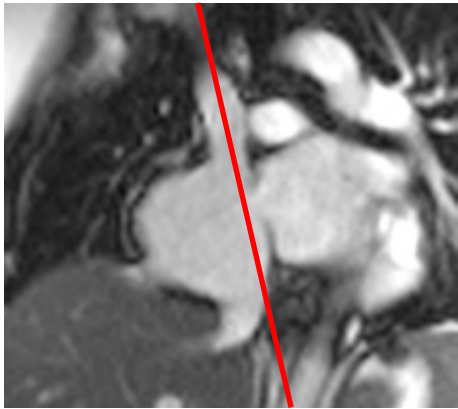
RPA flow®

Simplified planning:

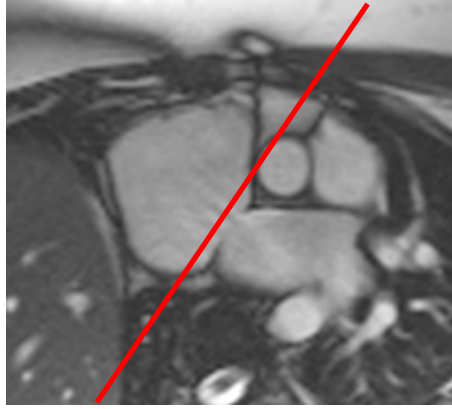
® Directly from coronal and axial localizer

Index

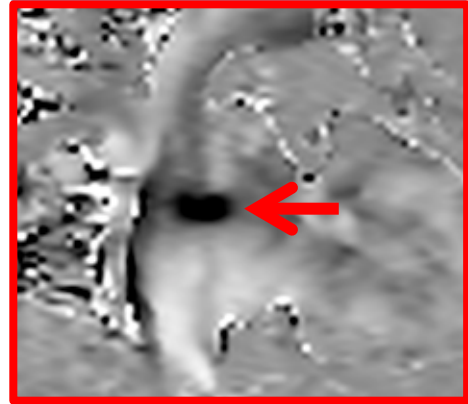
Standard Views - Flow Imaging -



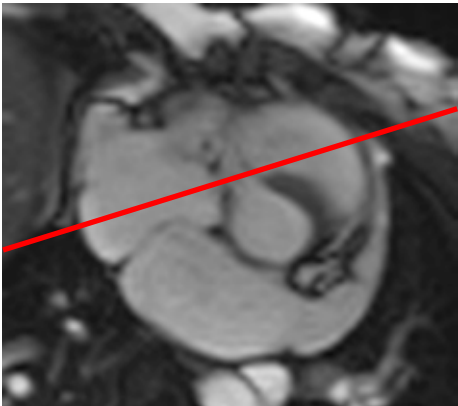
Modified sagittal



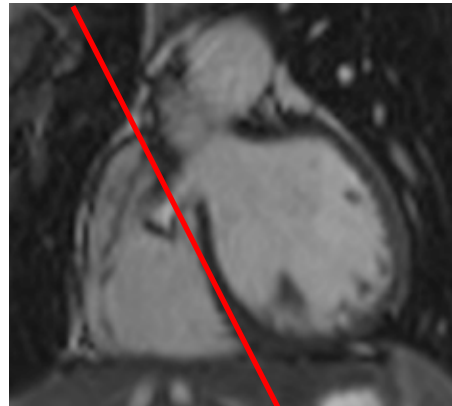
Basal SA of LV stack



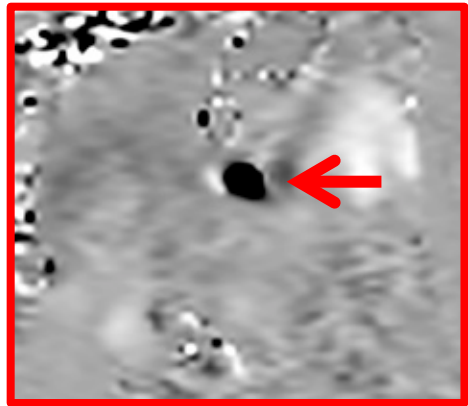
ASD flow



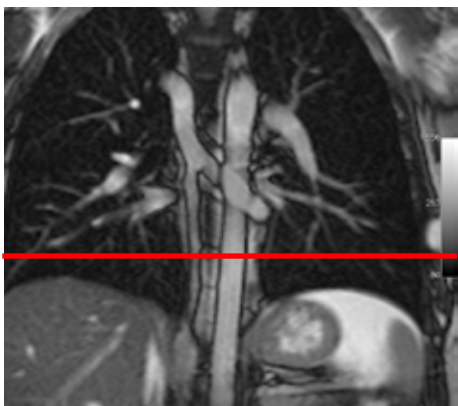Basal SA of LV stack



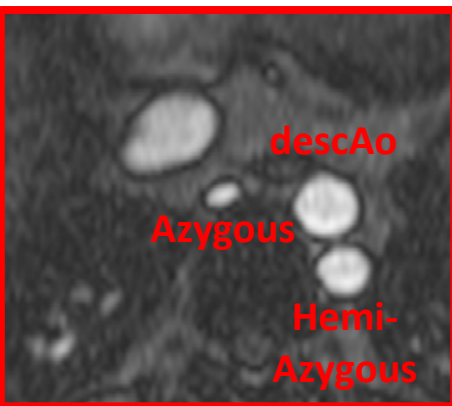
Coronal localizer




VSD flow



Coronal localizer



**Transaxial
magnitude**

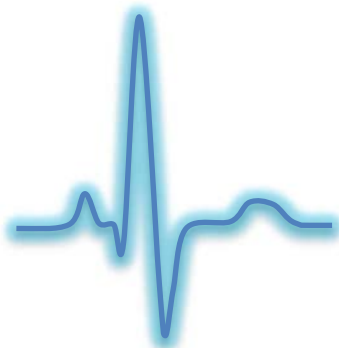

Transaxial flow

Index

Arrhythmia

Technique	Comment
<ul style="list-style-type: none">• Ensure correct lead position	
<ul style="list-style-type: none">• Try again	<ul style="list-style-type: none">• You might be lucky!
<ul style="list-style-type: none">• Heart rate and/or rhythm control before scanning	<ul style="list-style-type: none">• Use beta-blockers or other antiarrhythmic medication
<ul style="list-style-type: none">• Use arrhythmia rejection	<ul style="list-style-type: none">• Increases breath-hold time
<ul style="list-style-type: none">• Use prospective triggering	<ul style="list-style-type: none">• Cardiac diastole is not entirely visualised
<ul style="list-style-type: none">• Use real-time imaging	<ul style="list-style-type: none">• Reduces temporal and spatial resolution as well as SNR
<ul style="list-style-type: none">• Scan in inspiration	<ul style="list-style-type: none">• If heart signal capture is suboptimal• Reduces vasovagal arrhythmias
<ul style="list-style-type: none">• Increase NSA	<ul style="list-style-type: none">• Signal averaging can be useful for e.g. delayed contrast imaging
<ul style="list-style-type: none">• Alternative sequence	<ul style="list-style-type: none">• E.g. turbo field echo rather than SSFP, white blood imaging rather than black blood sequences



Poor Breath-Holders

Acceleration technique	Comment
<ul style="list-style-type: none">• Reduce number of slices acquired per breath-hold	<ul style="list-style-type: none">• Increases overall scan time
<ul style="list-style-type: none">• Reduce number of phases for each breath-hold:<ul style="list-style-type: none">- by reducing acquisition matrix (scan or phase percentage)- by reducing FOV	<ul style="list-style-type: none">• Reduces SNR• Increases spatial resolution
<ul style="list-style-type: none">• Increase voxel size	<ul style="list-style-type: none">• Decreases spatial resolution
<ul style="list-style-type: none">• Use parallel imaging	<ul style="list-style-type: none">• Prone to artefacts
<ul style="list-style-type: none">• Use respiratory navigator	<ul style="list-style-type: none">• Increases overall scan time
<ul style="list-style-type: none">• Acquire images in inspiration	<ul style="list-style-type: none">• Varying slice position with each breath-hold
<ul style="list-style-type: none">• Use real time imaging	<ul style="list-style-type: none">• Reduces image quality
<ul style="list-style-type: none">• Consider general anaesthesia	
<ul style="list-style-type: none">• Ensure correct understanding of breath-hold technique	<ul style="list-style-type: none">• If patient has no respiratory problems

Sequential Segmental Analysis - Overview -

- Important to start report with comprehensive segmental analysis

Cardiac Situs

Situs solitus
Situs inversus
Situs ambiguous
Based on atrial morphology
Bronchial situs is a surrogate

Cardiac Position

Levocardia
Dextrocardia
Mesocardia
Based on position in thorax

Cardiac Segments

Atrial Segment
Ventricular Segment
Arterial Segment

Connections

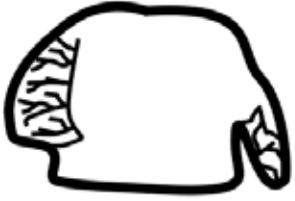Veno-Atrial Connection
Atrio-Ventricular Connection
Ventricular-Arterial Connection

Taken together, segmental analysis can describe any congenital heart disease

[Index](#)

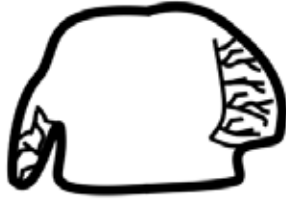Sequential Segmental Analysis - Cardiac Situs -

Cardiac Situs



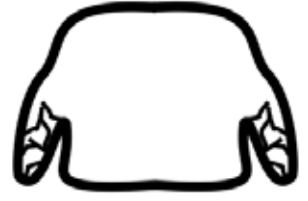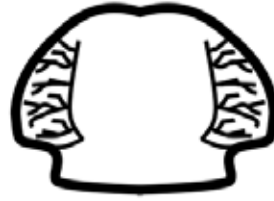Situs Solitus

- Anterior RA (on right)
- Posterior LA (on left)



Situs Inversus

- Posterior RA (on left)
- Anterior LA (on right)



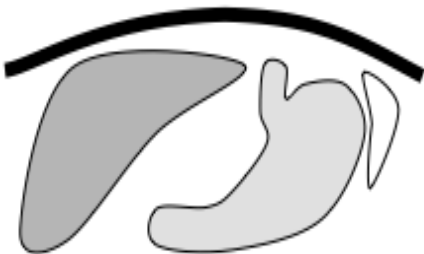Situs Ambiguous

Right

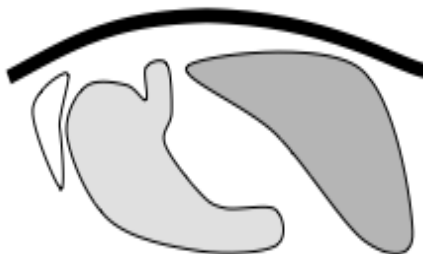Left

- RA or LA isomerism

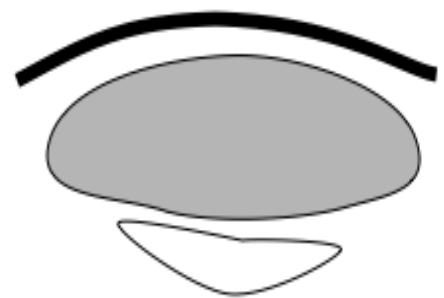Abdominal Situs



Situs Solitus



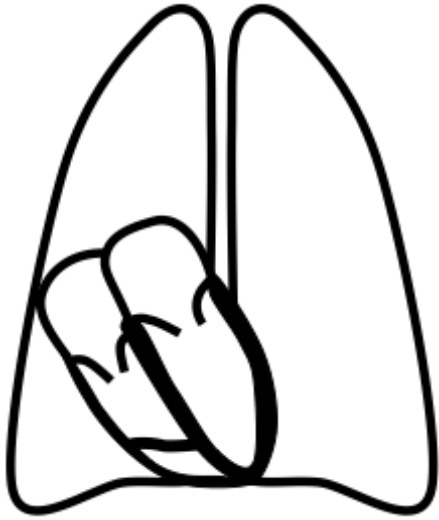
Situs Inversus



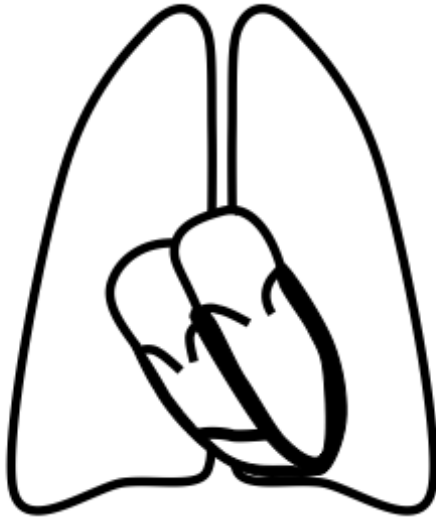
Heterotaxia

Sequential Segmental Analysis - Cardiac Position -

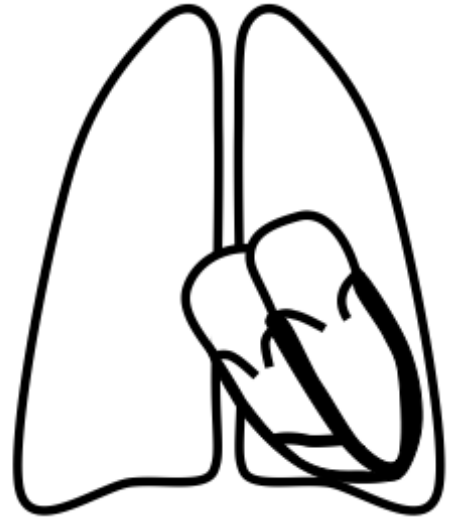
Cardiac Position



Dextrocardia



Mesocardia

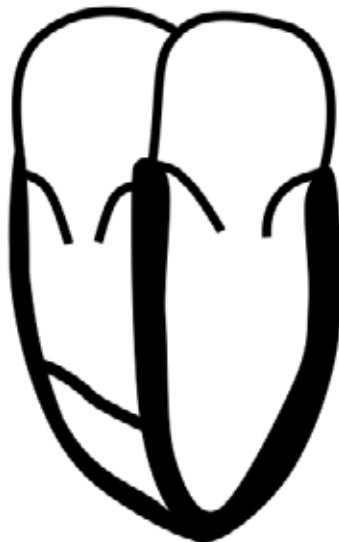

Levocardia

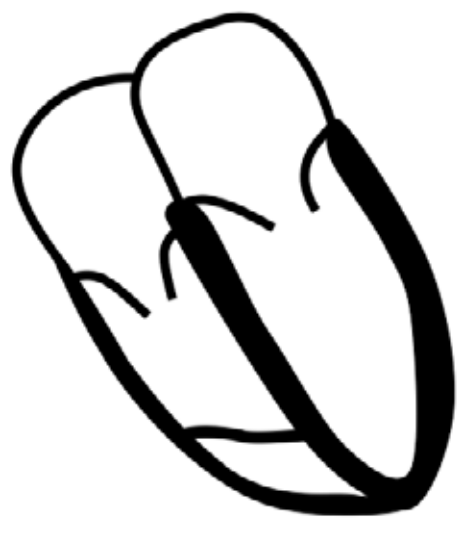Cardiac Orientation



Dextrocardia



Mesocardia



Levocardia

Sequential Segmental Analysis - Cardiac Segments-

Atrial Segment



Right atrium

- Broad, based, triangular appendage
- Short and vertical bronchus arrangement



Left atrium

- Narrow, tubular appendage
- Long and horizontal bronchus arrangement

Ventricular Segment

Right ventricle

- Trabeculated
- TV associated, TV attachments to the septal moderator band
- Muscular infundibulum between inlet and outlet



Left ventricle

- Smooth walled
- MV associated, MV attachments to papillary muscles

Arterial Segment

Pulmonary Trunk

- Bifurcation to RPA and LPA

Aorta

- Left- or right-sided
- Coronary arteries
- Regular branches

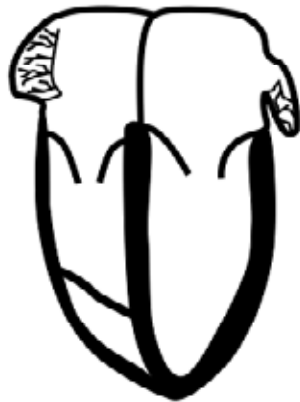[Index](#)

Sequential Segmental Analysis - Connections-

Veno-Atrial Connection

- IVC and SVC connections
- Presence of left SVC (90% left SVCs drain to RA via coronary sinus)
- Normal, partial or total anomalous pulmonary venous drainage

Atrio-Ventricular Connection and Inlets

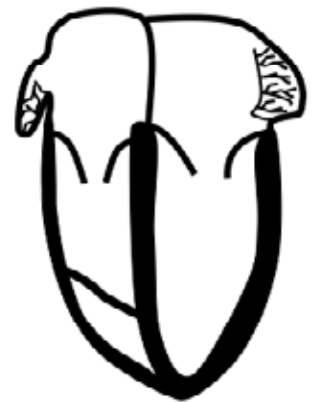

AV concordance

- RA is connected to RV, LA to LV

The valves go with the ventricles

Double inlet, mitral atresia, tricuspid atresia, AVSD



AV discordance

- RA is connected to LV, LA to RV

Ventricular-Arterial Connection

VA concordance

- LV is connected to Ao
- RV to MPA

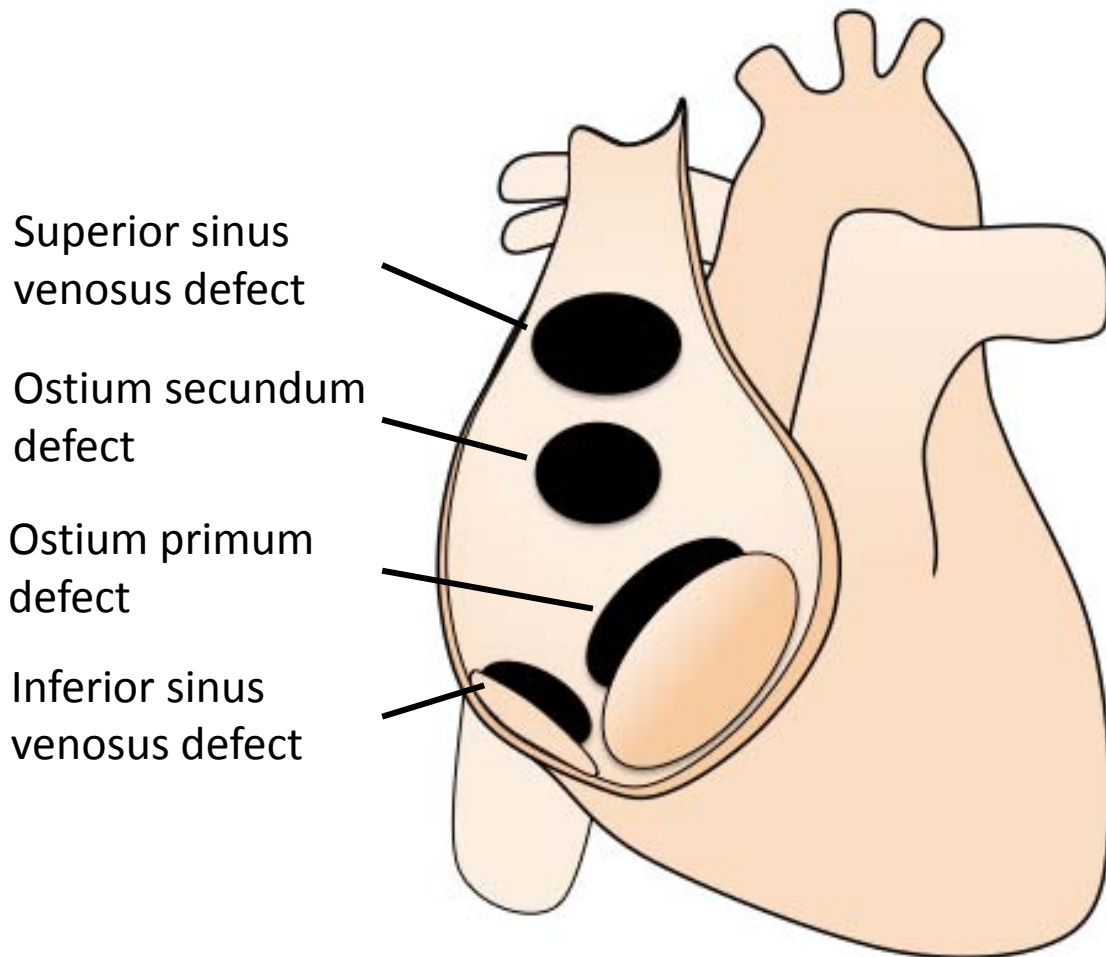
Double outlet, single outlet

(e.g. pulmonary atresia or truncus arteriosus)

VA discordance

- LV is connected to MPA
- RV to Ao

Atrial Septal Defect



Pre-operative findings

- ASD
- RA and RV dilation RV dysfunction

Associated findings

- Partial anomalous pulmonary venous drainage
 - look for right upper pulmonary vein (most common anomaly)
- Mitral valve abnormalities and regurgitation (ostium primum)
- Tricuspid regurgitation

Atrial Septal Defect

Interventions

- Percutaneous device (secundum)
- Surgical atrial septal closure

Post-operative complications

- Residual ASD

Protocol

1. **Anatomical stack**
2. **VLA, HLA, LV stack, RV stack**
3. **LVOT, RVOT**
4. **MPA flow**
5. **Ao flow**
5. **Atrial stack**
6. **ASD flow**
7. **MRA pulmonary veins**
8. **3D whole heart**

Report

1. **Size** (corrected for BSA) and **function**
 - LV: EDV, ESV , SV, EF, RWMA
 - RV: EDV, ESV, SV, EF, RWMA, note any RV dilation
2. **ASD type, size and location**
3. **Qp (MPA flow) : Qs (Ao Flow)**
4. **Pulmonary venous connection**
5. **Associated findings**

Atrial Septal Defect

Key issues

1. 'Red flags'

- Significant RV dilatation or dysfunction
- $Q_p:Q_s > 1.8:1$
- Associated abnormalities e.g. PAPVD
- Pulmonary hypertension

2. Major types of ASD

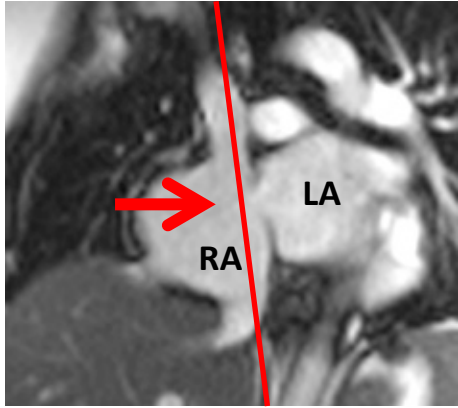
- **Ostium secundum defect**
 - Most common defect, 75% of all ASD cases
 - Fenestrated or netlike septum possible
- **Ostium primum defect**
 - Atrioventricular septal defect
 - Commonly associated with mitral valve abnormalities, e.g. mitral cleft - common AV valve
- **Sinus venosus defect**
 - Commonly associated with partial anomalous connection of the right-sided pulmonary veins

3. Calculation of shunting volume

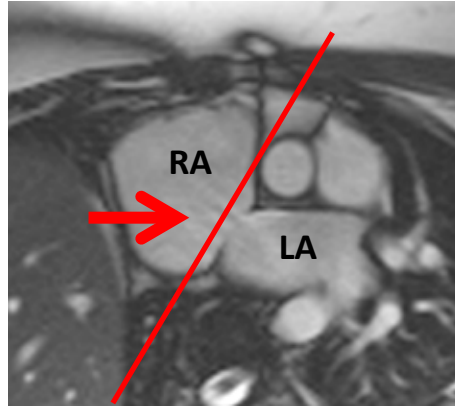
- $SV \text{ from MPA flow} / SV \text{ from Ao flow}$
- Alternatively $RV \text{ SV} / LV \text{ SV}$ (w/o valve disease)
- Use $MPA / Ao \text{ flow}$ and $RV \text{ SV} / LV \text{ SV}$ as internal validation

Atrial Septal Defect

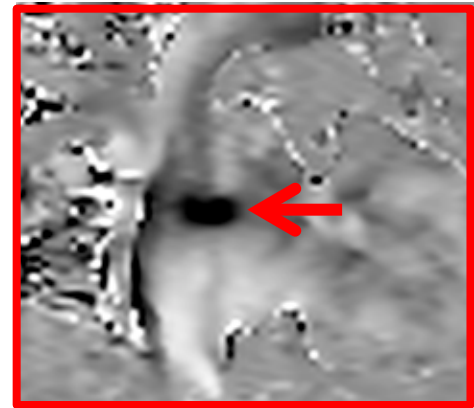
Ostium secundum defect



ASD with left-to-right shunt

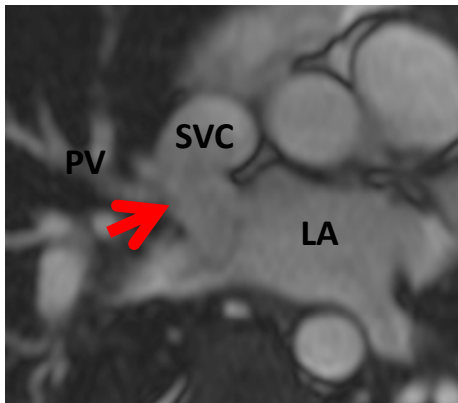


ASD with left-to-right shunt




ASD jet - VENC

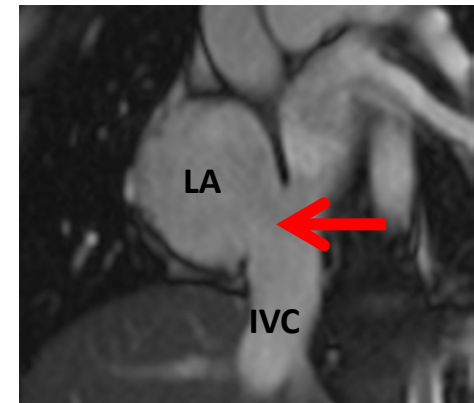
Sinus venosus defect



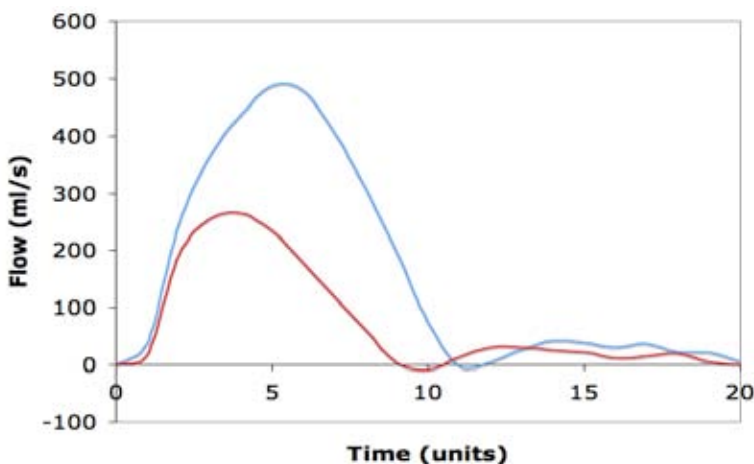
Superior SVASD



Anomalous PV to SVC

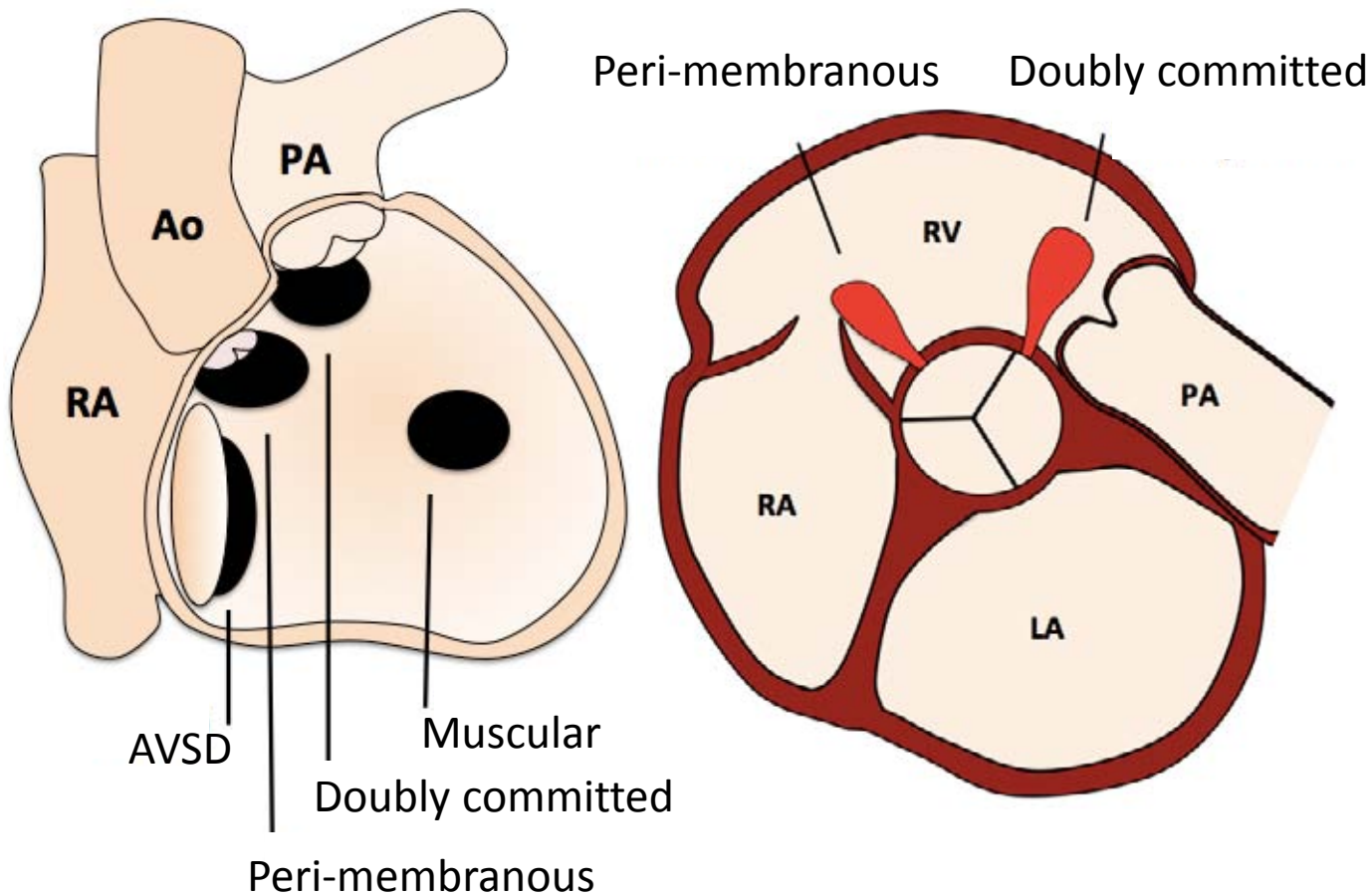


Inferior SVASD



Flow-time curve of ASD with left-to-right shunt: $Q_p:Q_s$ 2.5:1

Ventricular Septal Defect



Pre-operative findings

- VSD
- LA and LV dilation LV dysfunction
- LV and RV dilation with AVSD
(shunting at atrial and ventricular levels)

Associated findings

- Peri-membranous VSD: Septal aneurysm, double chambered RV, aortic valve prolapse and aortic incompetence, sub-AS
- AVSD: Common AV valve and regurgitation

Ventricular Septal Defect

Interventions

- Surgical closure with ventricular septal patch
- Percutaneous device

Post-operative complications

- Residual VSD
- RVOT obstruction
- Valvular regurgitation

Protocol

1. **Anatomy stacks**
2. **VLA, HLA, LV stack, RV stack**
3. **LVOT, RVOT**
4. **AoV**
5. **MPA flow**
6. **Ao flow**
7. **VSD flow**

Report

1. **Size** (corrected for BSA) and **function**
 - LV: EDV, ESV , SV, EF, RWMA, note any LV dilation
 - RV: EDV, ESV, SV, EF, RWMA
2. **VSD type, size and location**, VSD jet velocity
3. **Qp (MPA flow) : Qs (Ao Flow)**
4. **Associated findings**

Ventricular Septal Defect

Key issues

1. 'Red flags'

- Non-restrictive
- Dilated LV \pm RV
- Qp:Qs > 1.8
- Associated valvular dysfunction

2. Is the VSD restrictive or not?

- Restrictive VSD
 - Small (<1/2 aortic valve diameter)
 - High left to right velocity
 - Normal RV and pulmonary pressures
- Non-restrictive
 - Large VSDs
 - RVH and pressure-loaded RV
 - Eisenmenger syndrome if uncorrected

3. If the VSD is small, CMR may not detect it

- Consider TTE/TEE instead

4. VSD jet

- Jet size and velocity are dependent on defect size and pressure differences between the chambers
- Peak velocity often underestimated by CMR

Ventricular Septal Defect

Key issues

5. LV or RV dilation?

- The VSD shunts the blood directly into the RVOT leading to LV dilation even in large defects
- + RV dilation only if
 - AVSD
 - Eccentric VSD jet flow through TV into RA
 - End-stage disease with Eisenmenger

6. Gerbode defect

- LV to RA shunt
- RA \pm RV dilation
- Congenital disorder or after endocarditis or iatrogenic

7. Calculation of shunting volume

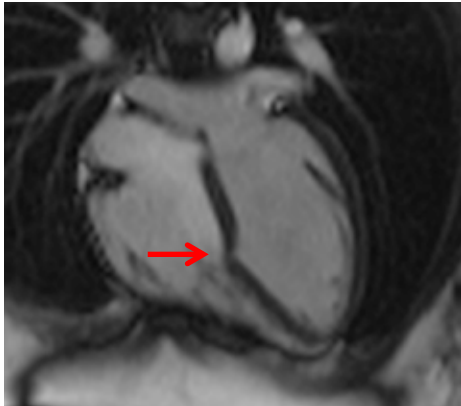- SV from MPA flow / SV from Ao flow
- Alternatively RV SV / LV SV (in patients w/o valve disease)

8. Common synonyms

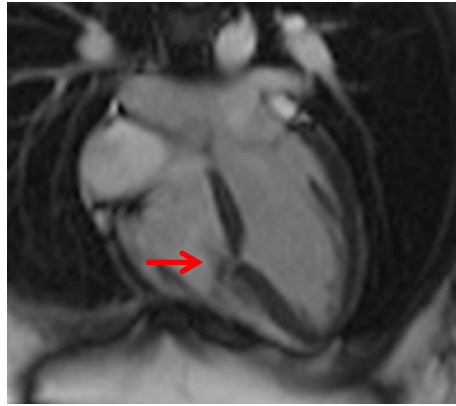- Peri-membranous: infracristal, conoventricular
- Muscular: trabecular
- Doubly committed: supracristal, subarterial, outlet
- AVSD: canal-type, cushion-type, AV-septum type

Ventricular Septal Defect

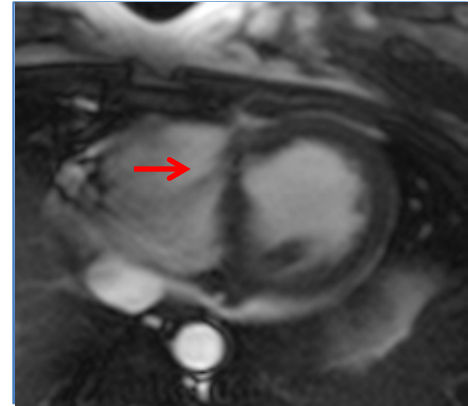
Muscular VSD



VSD – HLA diastole

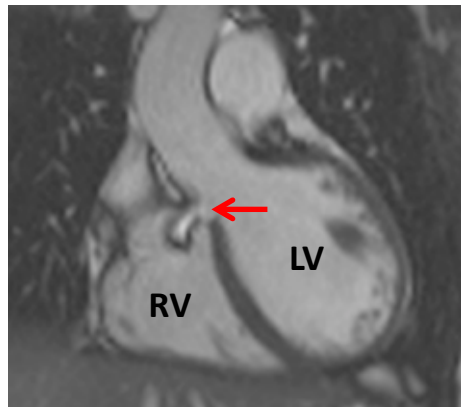


VSD jet – HLA systole

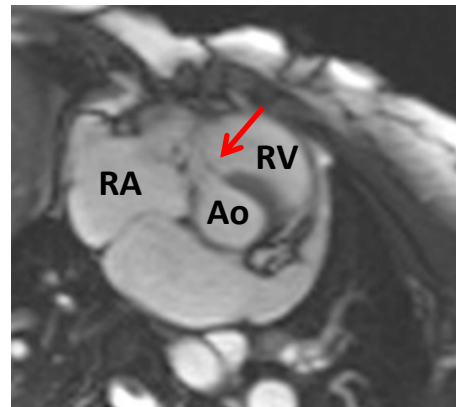


VSD jet - SA

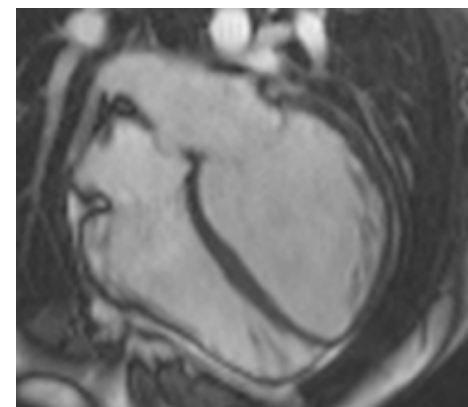
Peri-membranous VSD



VSD jet - LVOT

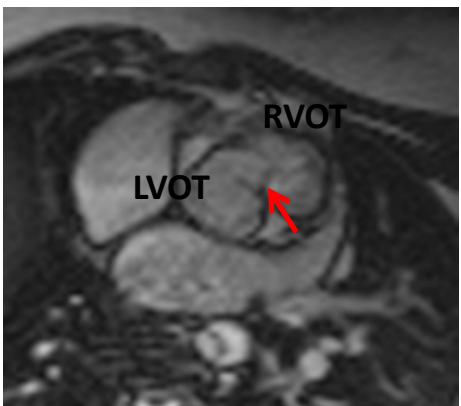


VSD jet – basal SA

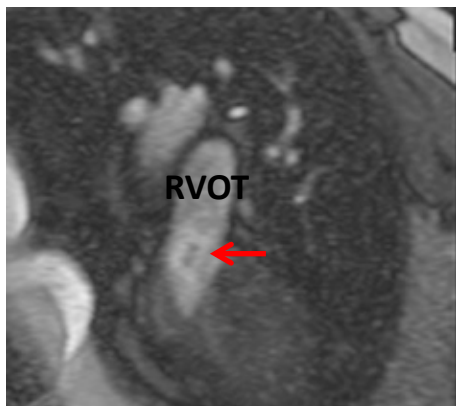

Dilated LV – HLA

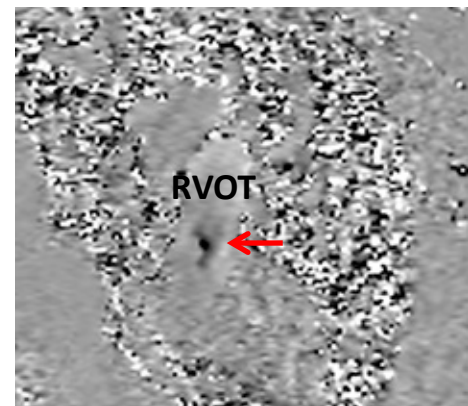
Doubly committed VSD



VSD jet – basal SA



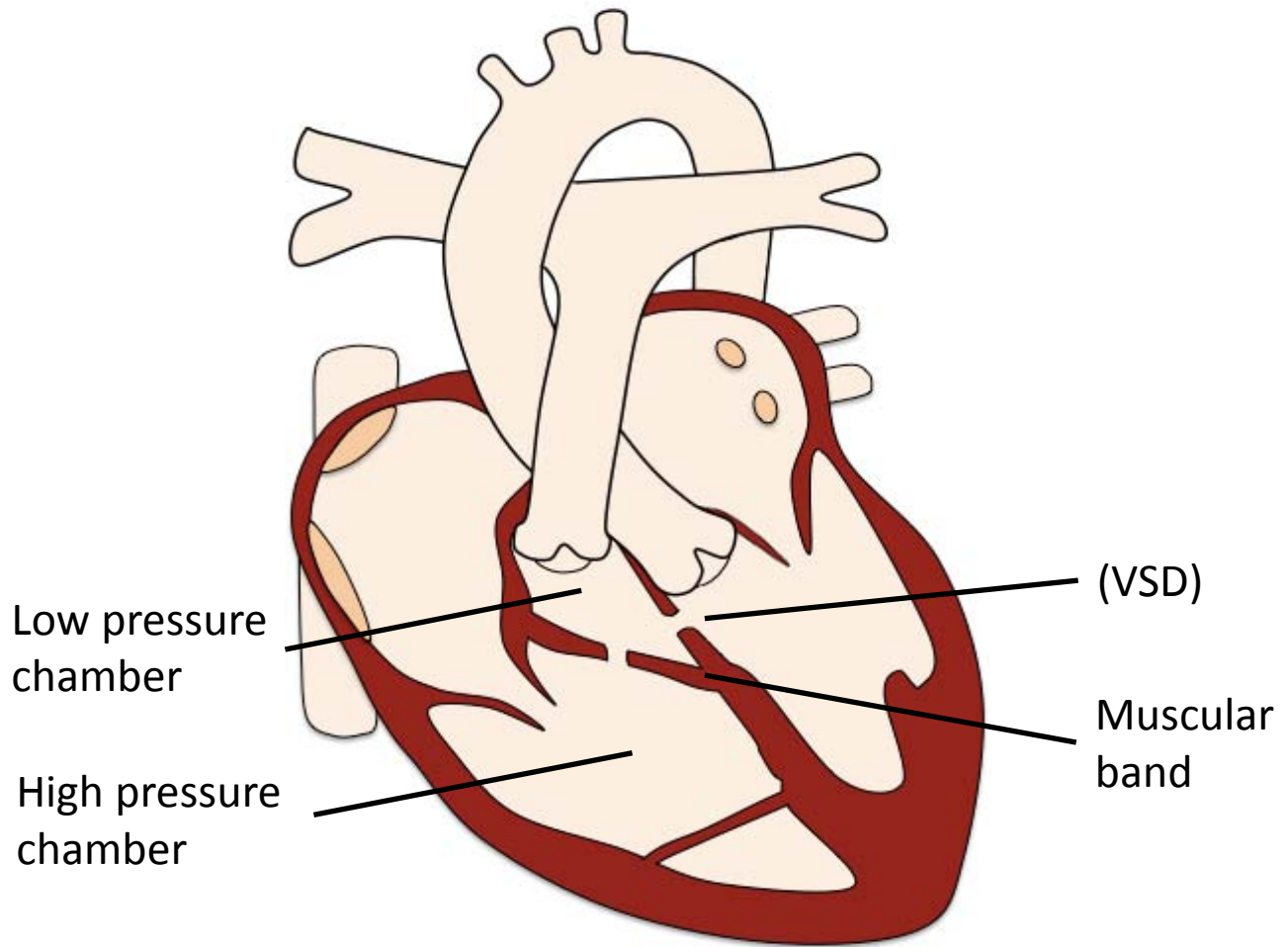
VSD jet - RVOT



VSD jet –
RVOT
VENC

[Index](#)

Double-Chambered Right Ventricle



Pre-operative findings

- Muscular anomalous sub-pulmonary band dividing the RV cavity into two chambers
- RV hypertrophy (may contribute to sub-pulmonary stenosis)
- VSD (not always present)
 - Often per-membranous
 - Can flow into low or high pressure chamber

Associated findings

- TR (high velocity jet)
- RVOT obstruction

Double-Chambered Right Ventricle

Interventions

- Surgical resection
- VSD closure

Post-operative complications

- Intra-ventricular restenosis

Protocol

1. **Anatomy stacks**
2. **VLA, HLA, LV stack, RV stack**
3. **LVOT, RVOT**
4. **RV in- / outflow**
5. **MPA flow**
6. **AoV flow**
7. **Coronal stack**
8. **VSD flow**
9. **TR flow**

Report

1. **Size** (corrected for BSA) and **function**
 - LV: EDV, ESV , SV, EF, RWMA, mass
 - RV: EDV, ESV, SV, EF, RWMA
2. **RV muscular band: location** (high / low) **and severity of stenosis** – difficult to assess adequately by CMR
3. **LVOT or RVOT obstruction**
4. **Hypertrophy of proximal / inflow RV chamber**
5. **VSD type, size, location, Qp (MPA flow):Qs (AoV flow)**
6. **Presence of TR**

Double-Chambered Right Ventricle

Key issues

1. **Anomalous muscle bundle**

- Usually associated with a VSD; consider spontaneous closure if not present
- Divides the RV into a prestenotic inflow chamber and a low-pressure infundibular chamber
- May occur anywhere through RV from adjacent to PV down to apex
- Best visible on RV in- / outflow or coronal view
- Can be missed on HLA view

2. **VSD**

- Most commonly peri-membranous
- May communicate with either proximal or distal chamber
- Shunts in the proximal chamber can be underestimated due to the high-pressure status

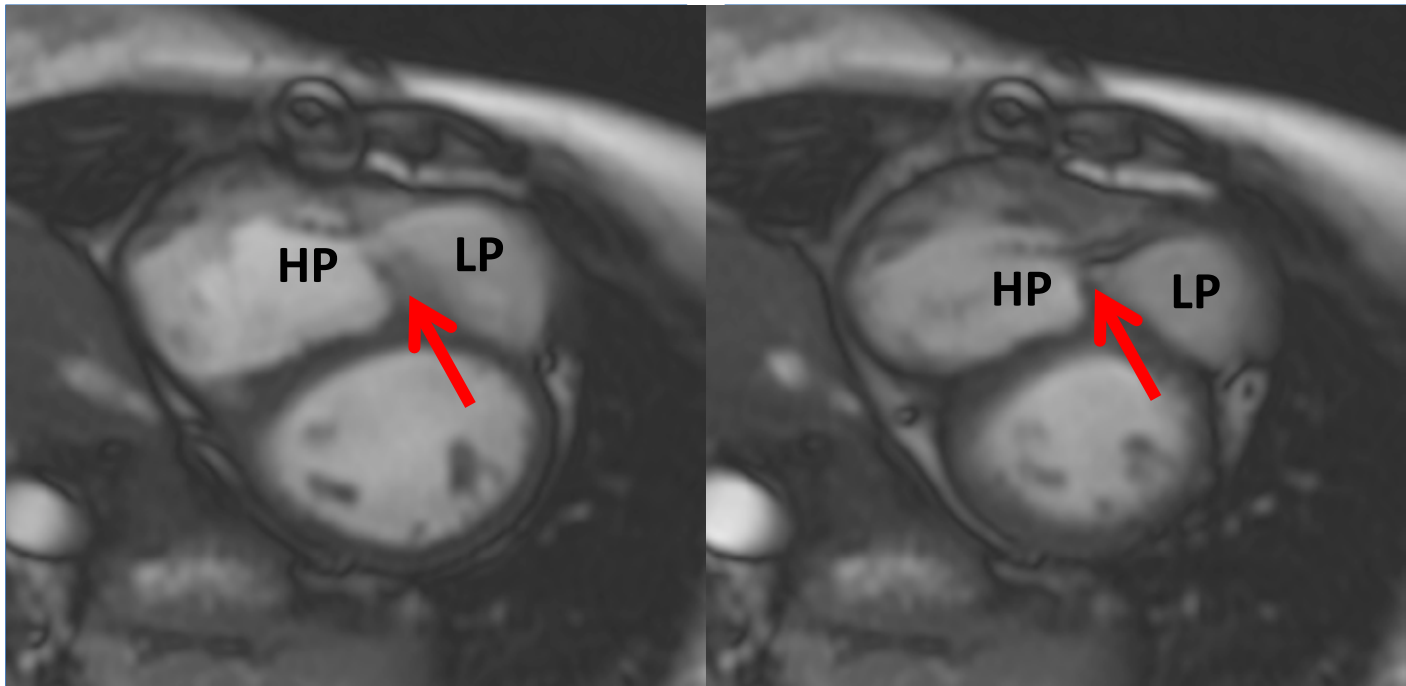
3. **RVOT obstruction**

- Due to progressive hypertrophy of RV and muscle bundles
- May lead to RV failure

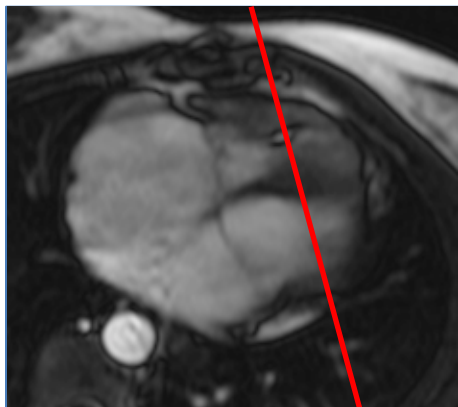
4. **TR**

- High TR jet velocity can be mistaken as PH

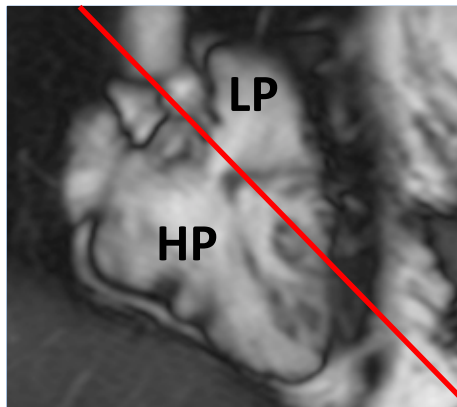
Double-Chambered Right Ventricle



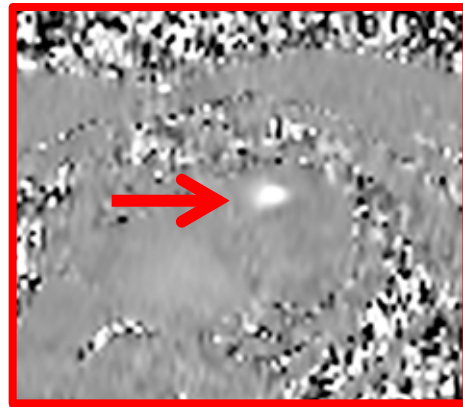
Muscular band (arrow) dividing the RV in a high (HP) and a low pressure chamber (LP) - diastole and systole



HLA

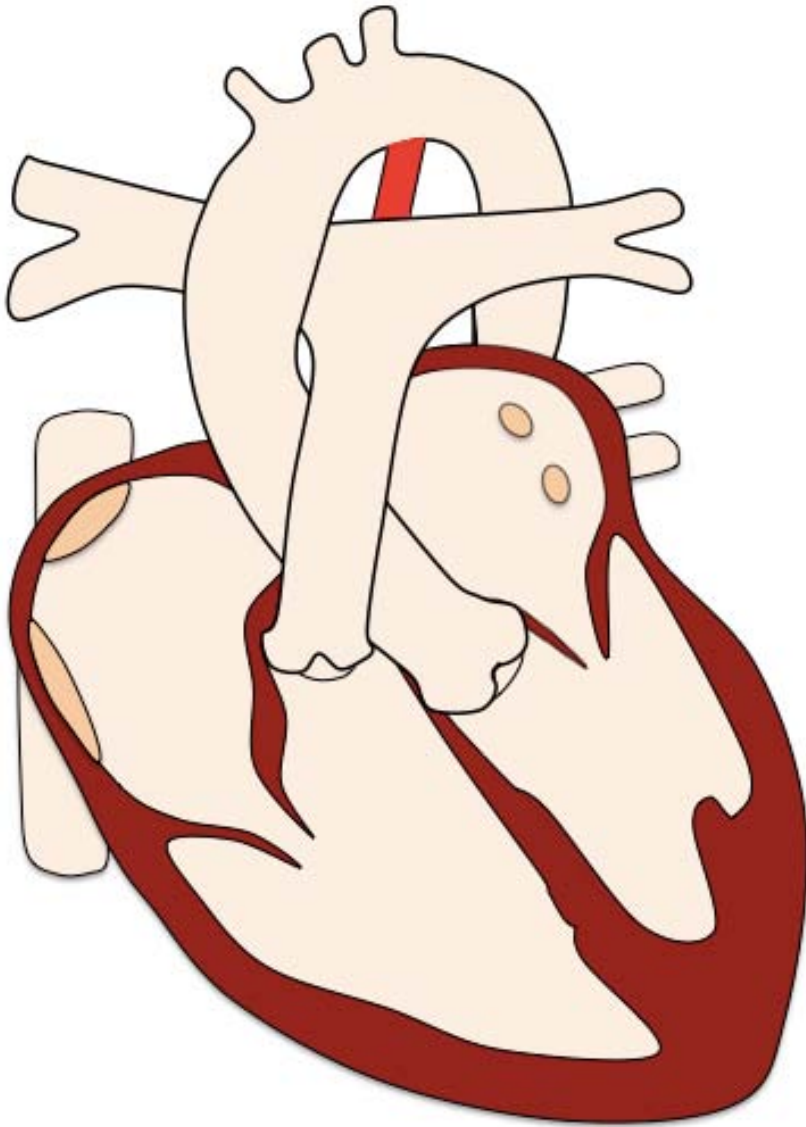


Coronal



RV jet - VENC

Patent Ductus Arteriosus



Pre-operative findings

- PDA
- LA and LV dilation LV dysfunction
- Dilated pulmonary veins and ascAo in large PDA

Associated findings

- Occasionally aortic coarctation

Patent Ductus Arteriosus

Interventions

- Occluder device
- Coil embolization
- Surgical ligation

Post-operative complications

- Residual shunt

Protocol

1. **Anatomy stacks**
2. **VLA, HLA, LV stack, RV stack**
3. **LVOT, RVOT**
4. **PAs**
5. **AoArch**
6. **PDA cine stack**
7. **MPA and branch PAs flow**
8. **AoV flow**
9. **Pre-/post PDA aortic flow**
10. **PA in-plane flow**
11. **MRA aorta**
12. **3D whole heart**

Report

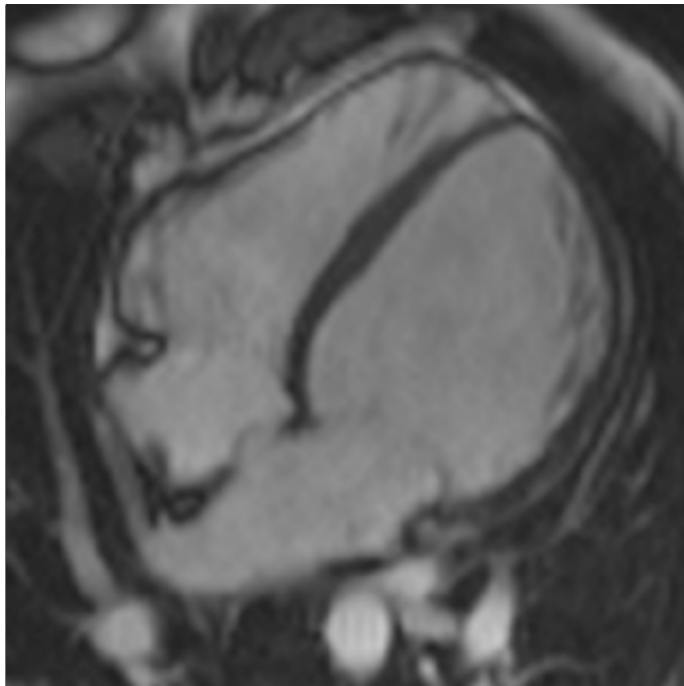
1. **Size** (corrected for BSA) and **function**
 - LV: EDV, ESV, SV, EF, mass, note any LV dilation
 - RV: EDV, ESV, SV, EF
2. **PDA length, diameter and form** (conical / window / tubular)
3. **Qp (MPA flow) : Qs (AoV flow)**

Patent Ductus Arteriosus

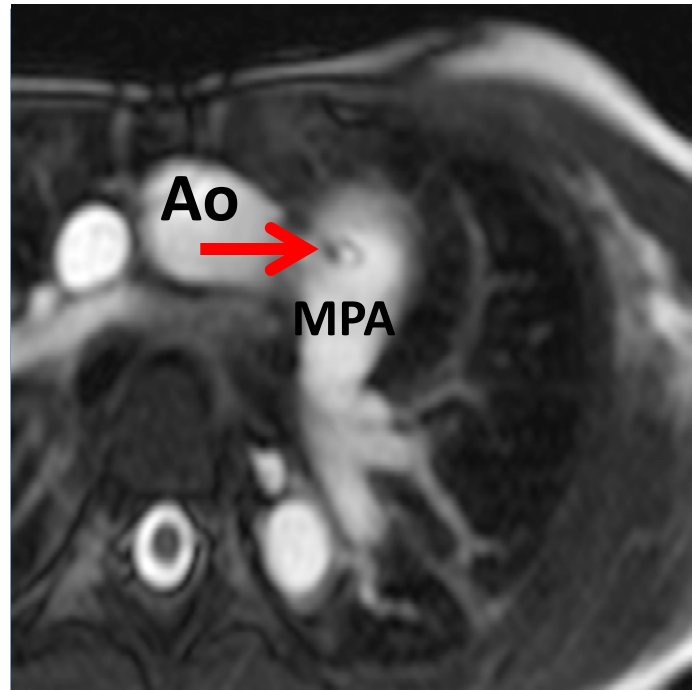
Key issues

- 1. Search for PDA if:**
 - Unexplained flow artefacts in PAs or MPA
 - Unexplained LA and LV dilation
 - Continuous machine-like heart murmur
 - Endocarditis with no valvular defects
- 2. Calculation of shunting volume**
 - $SV \text{ from Ao flow} / SV \text{ from MPA flow}$
 - Alternatively $LV \text{ SV} / RV \text{ SV}$ (in patients w/o valve disease)
- 3. Magnitude of the excess pulmonary blood flow depends on:**
 - Diameter and length of PDA
 - Systemic and pulmonary vascular resistance
- 4. A large and uncorrected PDA can result in pulmonary hypertension**
- 5. Right sided PDA** typically associated with other congenital abnormalities

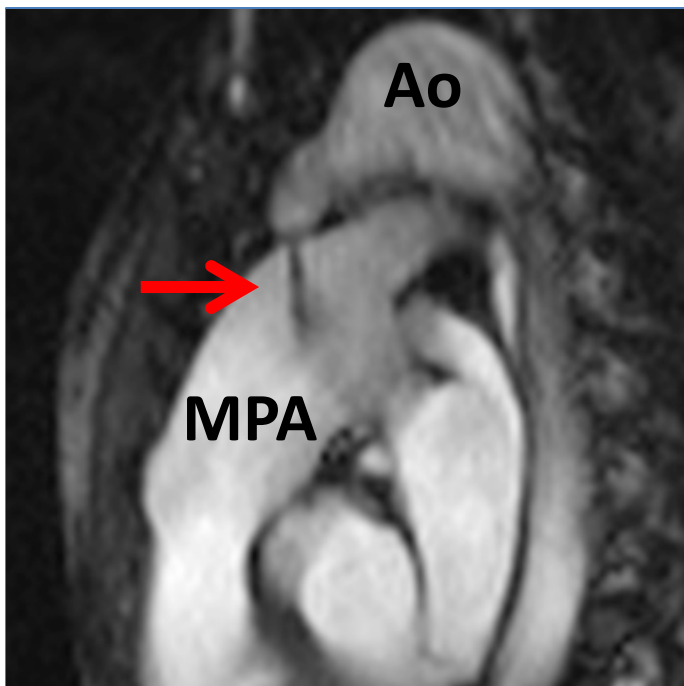Patent Ductus Arteriosus



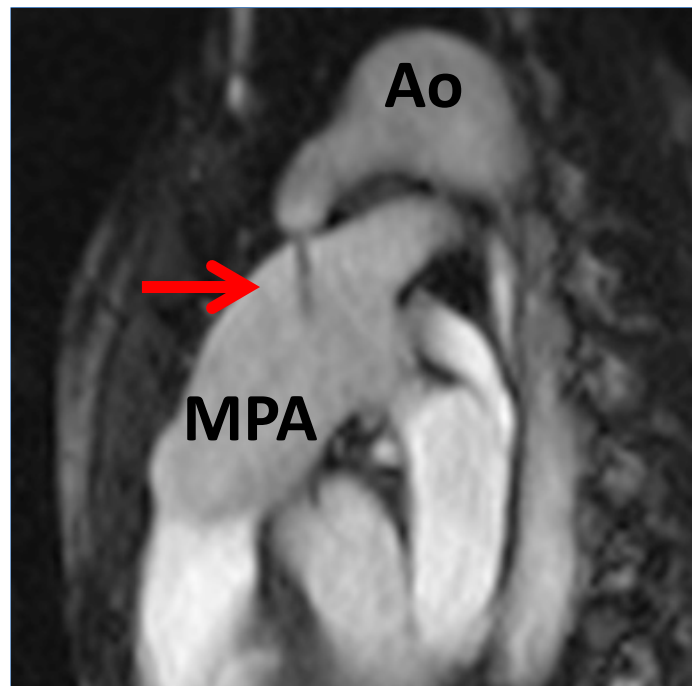
Dilated LV



PDA jet in MPA

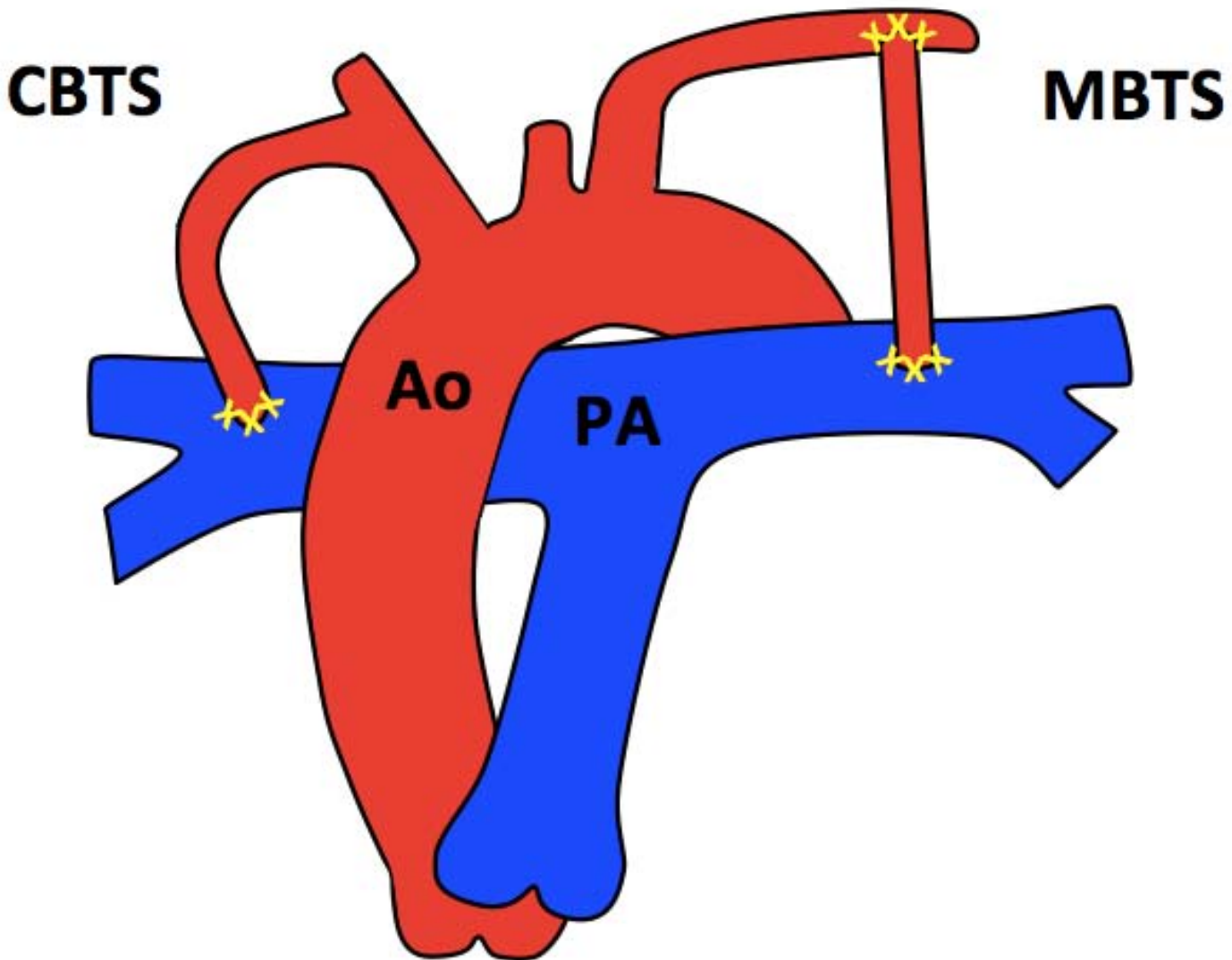


Systolic flow of PDA in MPA



Diastolic flow of PDA in MPA

Blalock-Taussig Shunt



Findings

Classic BT Shunt (CBTS)

- Subclavian artery to PA

Modified BT Shunt (MBTS)

- Gore-Tex tube from subclavian artery to PA

Blalock-Taussig Shunt

Late interventions

- BT stent

Postoperative complications

- BT shunt stenosis
- Aneurysm formation
- PA dilatation
- Pulmonary hypertension if large /excess shunting

Protocol

1. **Anatomy stacks**
2. **VLA, HLA, LV stack, RV stack**
3. **LVOT, RVOT**
4. **PAs**
5. **Shunt cines and flow**
6. **AoV flow**
7. **MPA**
8. **PAs flow distal to shunt**
9. **MRA**
10. **3D whole heart**

Report

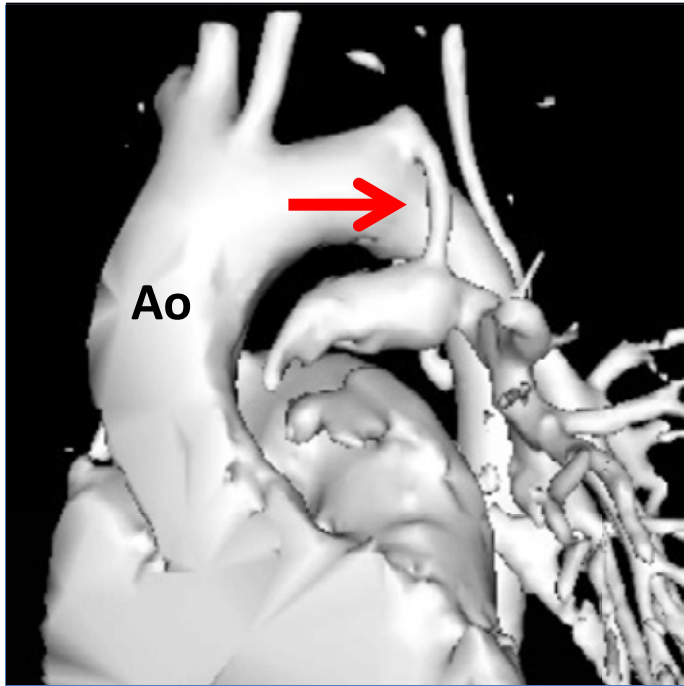
1. **Size (corrected for BSA) and function**
 - LV: EDV, ESV , SV, EF, mass
 - RV: EDV, ESV, SV, EF
2. **BT shunt dimensions, patency and flow**
3. **Presence of aneurysm formations**
4. **Qp (MPA flow) :Qs (AoV flow)**

Blalock-Taussig Shunt

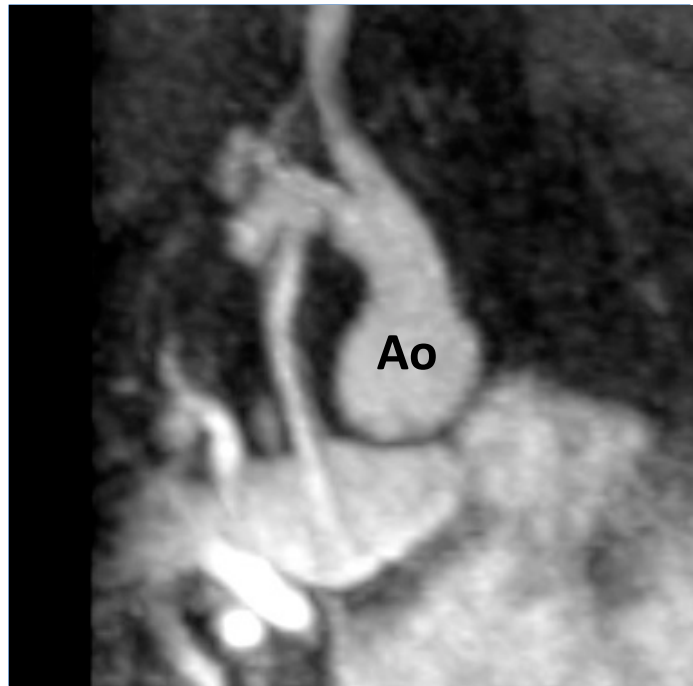Key issues

1. **Palliative intervention in cyanotic heart disease**
2. May be used as a **bridge** to Glenn / Fontan circulation
3. Shunts may be small, and best seen with MRA (timed to aorta)
4. **Haemodynamic complications**
 - Subclavian steal (vertebrobasilar ischemia)
5. **A number of alternative palliative shunts exist:**
 - Waterston (ascending aorta to RPA)
 - Potts (descending aorta to LPA)
 - Central (aorta to MPA)
 - Cooley (ascending aorta to RPA, intra-pericardial)

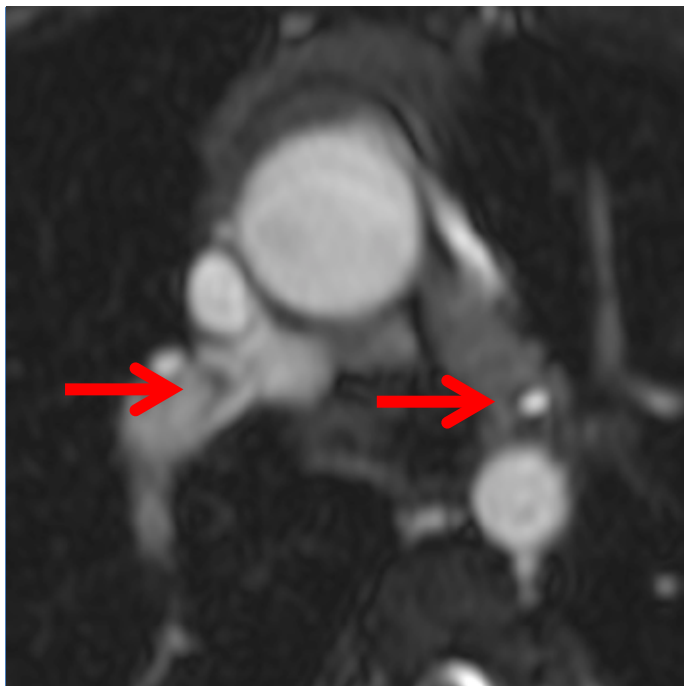
Blalock-Taussig Shunt



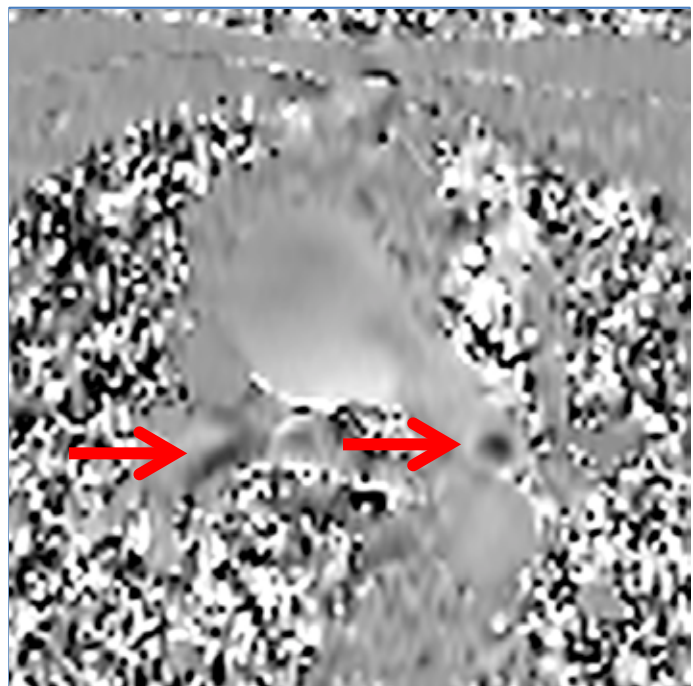
Classic BT shunt of left subclavian artery to MPA - MRA



Modified BT shunt from the right subclavian artery to MPA - MIP

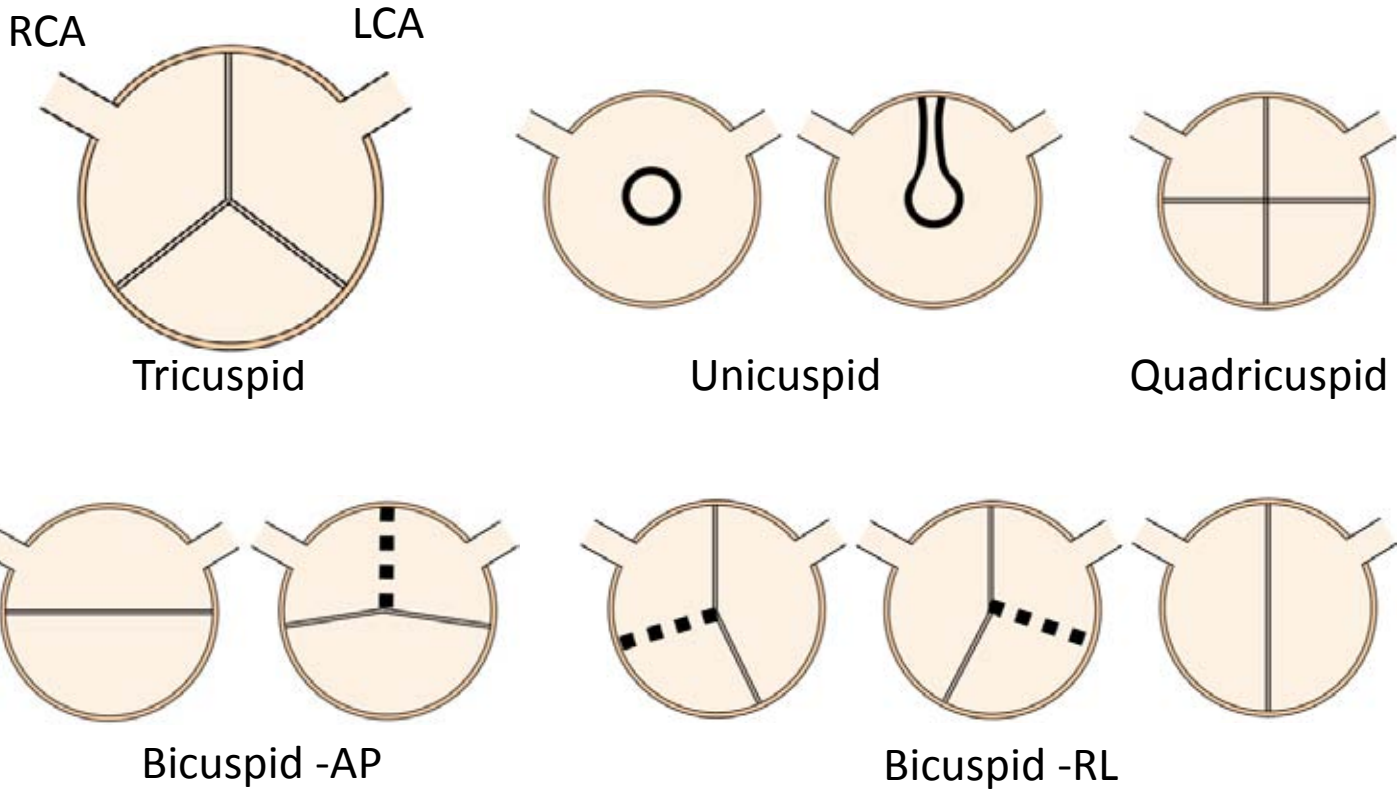


Bilateral MBT shunt - transaxial



Bilateral MBTS- flow imaging

Aortic Valve Disease



Pre-operative findings

- Aortic valve stenosis and / or regurgitation
- Concentric LV hypertrophy – aortic stenosis
- Dilated LV with excentric hypertrophy– aortic regurgitation
- Dilated LV with impaired systolic function – late stage AS or AR

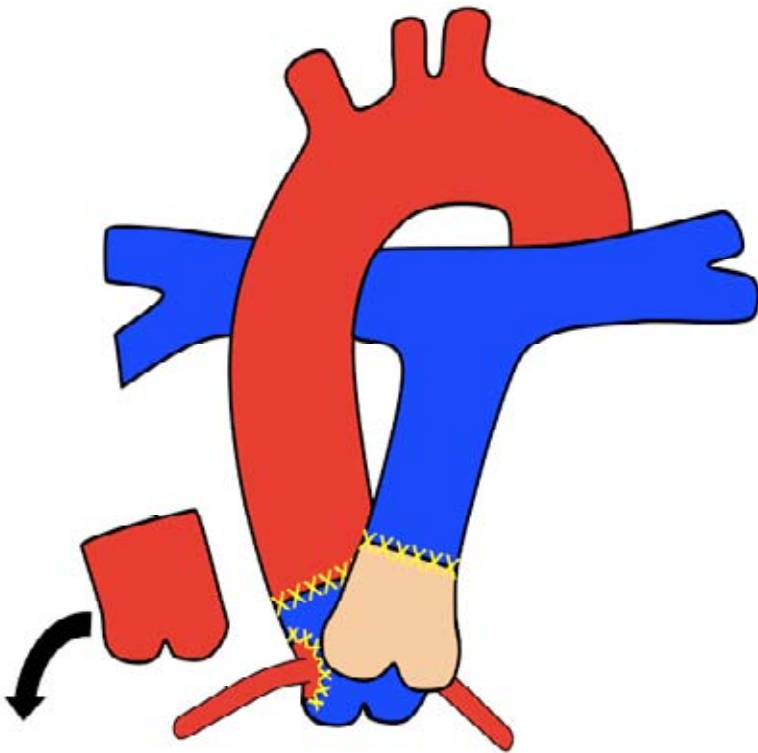
Associated abnormalities

- Aortic coarctation
- Subaortic- or supra- valvular aortic stenosis
- VSD in subaortic stenosis
- Shone Complex: parachute mitral valve, mitral stenosis, BAV, and coarctation of the aorta

Aortic Valve Disease

Interventions

- Aortic valve repair
- Aortic valve replacement (+/- aortic root; ascending aorta)
- **Ross procedure**



- Replacement of aortic valve with patients own pulmonary valve (autograft)
- Reimplantation of coronary arteries
- RV-to-PA homograft conduit

Post-operative complications

- Valve dysfunction; Paravalvular regurgitation

Ross procedure

- Aortic insufficiency
- Aortic autograft / ascending aortic dilation
- RVOT obstruction
- Pulmonary allograft stenosis or regurgitation
- Coronary artery stenosis

Aortic Valve Disease

Protocol

1. **Anatomy stack**
2. **VLA, HLA, LV stack, RV stack**
3. **LVOT, RVOT**
4. **AoV, PV**
5. **Aortic arch**
6. **AoV flow**
7. **MPA flow**
8. **MRA aorta**
9. **3D whole heart**

Report

1. **Size** (corrected for BSA) and **function**
 - LV: EDV, ESV, SV, EF, mass, note any LV dilation
 - RV: EDV, ESV, SV, EF, RWMA
2. **Aortic stenosis and/or regurgitation**
3. **Aortic dimensions:**
 - **LVOT, annulus, SoV, STJ, ascAo, arch, isthmus, descAo**
4. **Aneurysm formation**
5. **Post Ross procedure**
 - **RV RVOT obstruction, PV stenosis and/or regurgitation, coronary stenosis**
6. **Associated pathologies**

Aortic Valve Disease

Key issues

1. CMR has lower spatial and temporal resolution than ultrasound but is a reasonable alternative if poor echo image quality
2. **Comprehensive valve assessment:**
 - LV / RV dimensions, mass, fibrosis, and function
 - Forward and regurgitant flow / fraction
 - Mean / peak velocity – *will underestimate*
 - Jet detection, direction and origin
 - Valve area by direct planimetry
3. **Ross procedure**

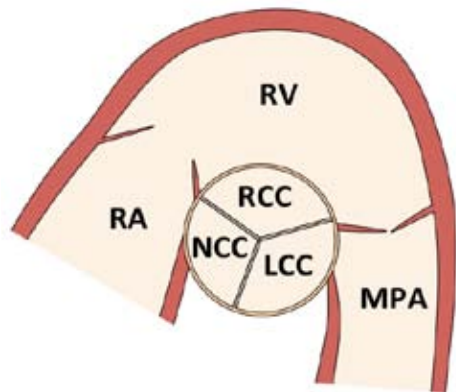
Advantages

- Longevity of the pulmonary allograft is superior to biological prosthesis
- Favourable hemodynamics
- No need for anticoagulation
- The valve grows as the patient grows

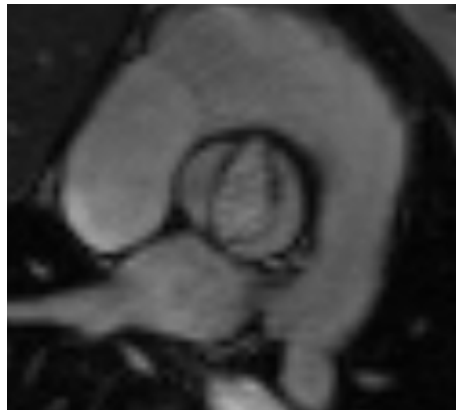
Disadvantages

- Single valve disease (aortic) treated with a two valve procedure (aortic and pulmonary)

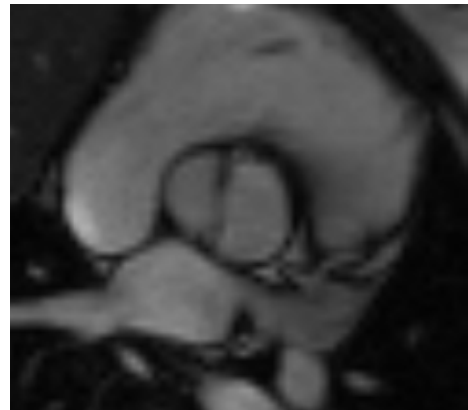
Aortic Valve Disease



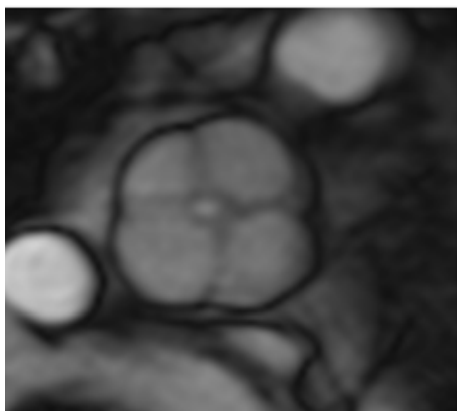
Tricuspid AV



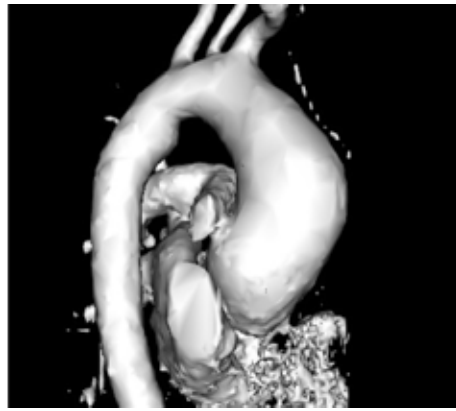
Bicuspid AV in systole



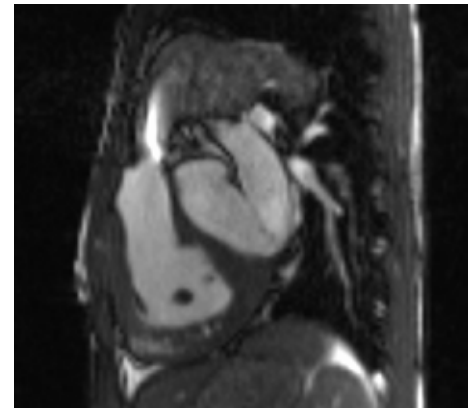
Bicuspid AV in diastole



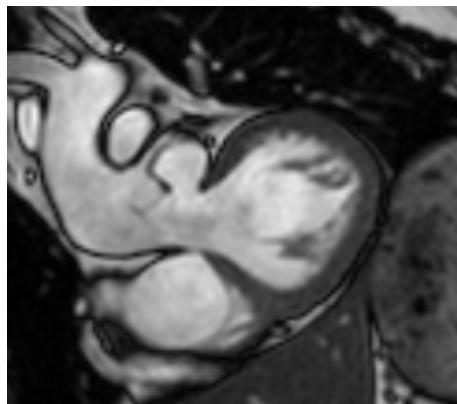
Quadricuspid AV



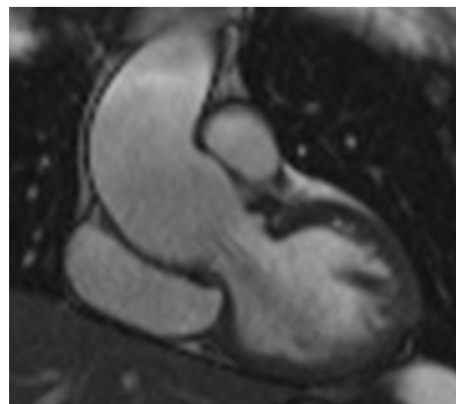
Ross procedure - Dilated ascending aorta



Ross procedure – RV homograft stenosis

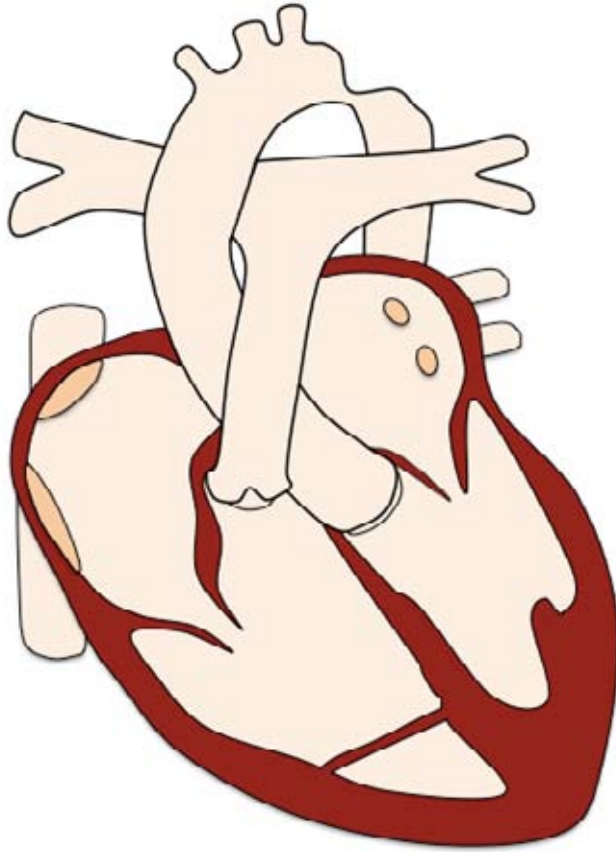


Ross procedure – proximal autograft anastomosis dehiscence



Ross procedure - Dilated SoV and ascending aorta, AR

Aortic Coarctation



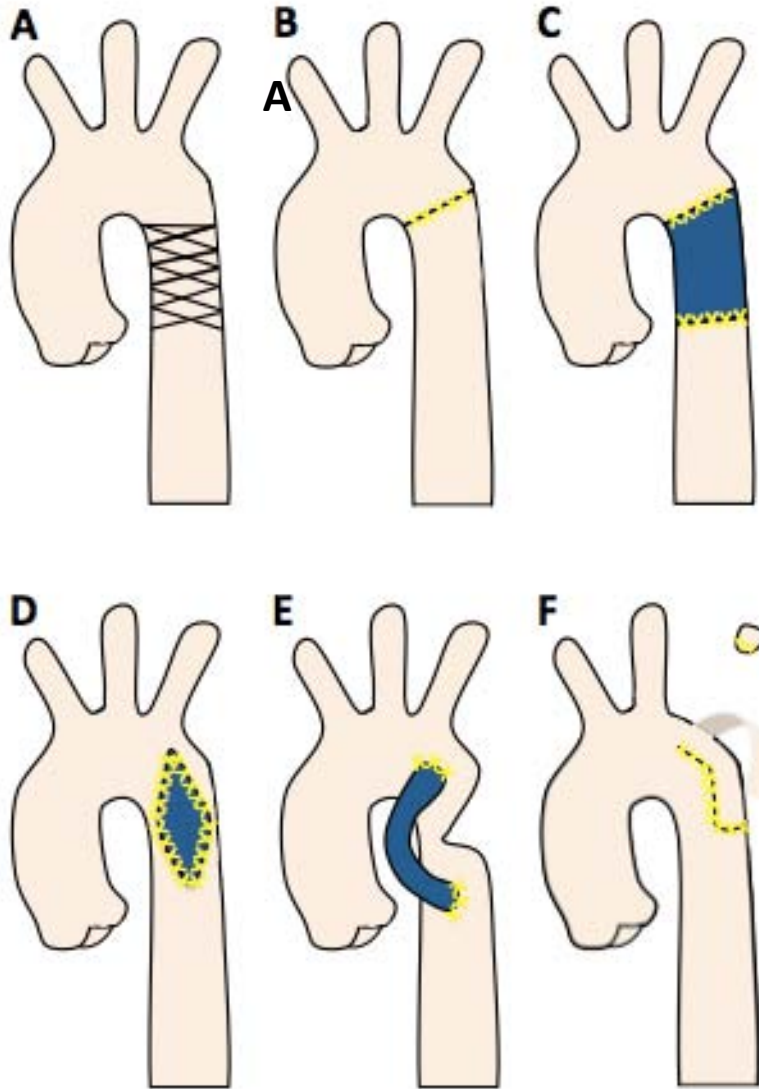
Pre-operative findings

- Narrowing in the region of the ligamentum arteriosum, the arch or the isthmus
- Collaterals
- +/- hypertrophic LV

Associated abnormalities

- Bicuspid AV and dilated ascending aorta
- Subaortic stenosis
- Arch hypoplasia
- VSD
- Mitral valve abnormalities, such as parachute MS

Aortic Coarctation



Initial interventions

- A) Stent
- B) End-to-end anastomosis
- C) Interposition graft
- D) Patch augmentation
- E) Bypass graft
- F) Subclavian flap repair

Post-operative complications

- Restenosis
- Aneurysm formation
- Collaterals

Aortic Coarctation

Protocol

1. **Anatomy stack**
2. **VLA, HLA, LV stack**
3. **LVOT**
4. **AoV**
5. **Aortic arch**
6. **AoV flow**
7. **Pre-stenotic flow**
8. **Post-stenotic peak flow**
9. **DescAo flow (diaphragm)**
10. **MRA aorta**

Report

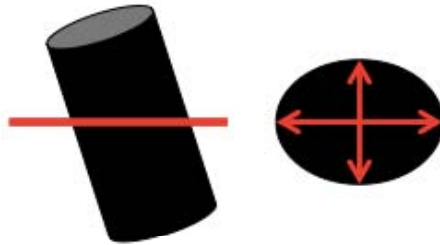
1. **Size (corrected for BSA) and function**
 - LV: EDV, ESV , SV, EF, mass
2. **Aortic dimensions:**
 - **LVOT, annulus, SoV, STJ, ascAo, arch, isthmus, descAo**
 - Add cardiac phase, orientation and sequence
3. **Severity of stenosis**
 - Minimal dimensions
 - Post-stenotic peak flow
 - Presence and degree of collateral flow
4. **Aneurysm formation**
5. **Associated pathologies**

Aortic Coarctation

Caveats of aortic measurements

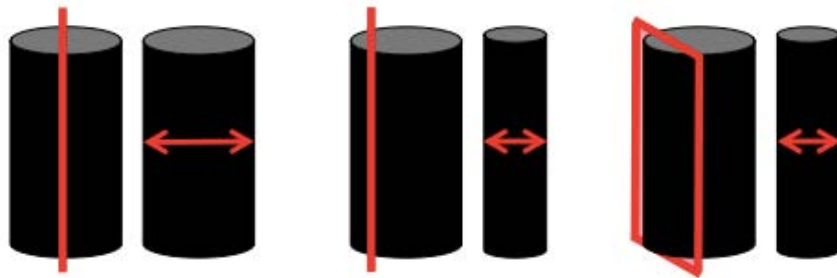
Transaxial

Overestimation due to non-orthogonal plane



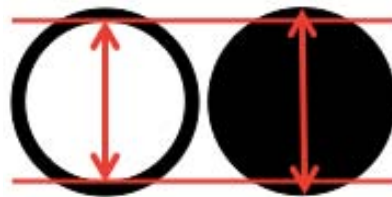
Oblique sagittal

Underestimation due to non-central or non-perpendicular plane



Black Blood


Overestimation possible due to inclusion of aortic wall



MRA

Over- / underestimation due to:

- Acquisition not cardiac cycle specific
- Motion artefacts, particular at aortic root /ascAo



3D whole heart

Over- / underestimation due to:

- Lower spatial resolution
- Motion artefacts

Index

Aortic Coarctation

Key issues

1. **Aortic dimensions:**

- Be aware of caveats of aortic measurements – see above
- Diastolic measurements from cine images are preferred
- Be clear in your report, which cardiac phase, orientation and sequence you used for measurements

2. **Severity of coarctation:**

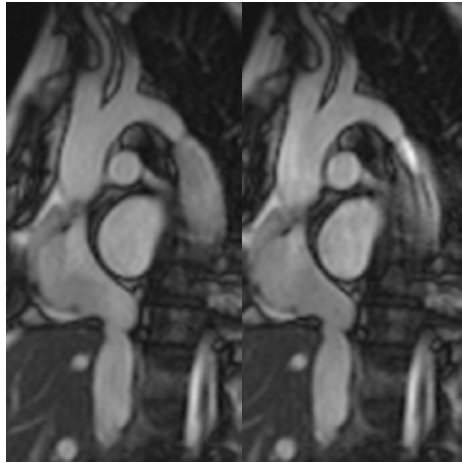
- Peak systolic flow is often underestimated by CMR
- echocardiography superior to CMR
- Diastolic prolongation of forward flow is a sign of significant coarctation

3. **Collateral flow:**

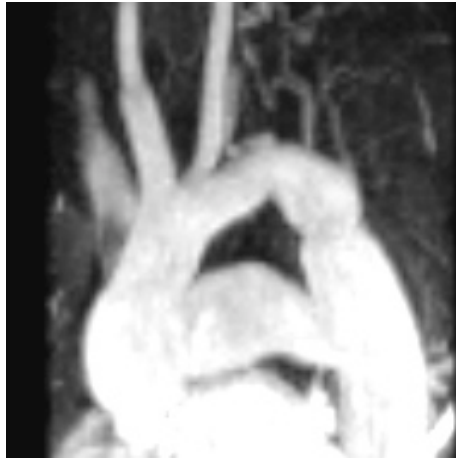- A decrease of <10% (prestenotic - descAo flow) is expected physiologically
- An increase implies collateral flow rejoining the descending thoracic aorta
- Abundant collaterals may reduce the gradient across the coarctation and mask the severity of the obstruction

4. **Aneurysms** of the circle of Willis or other cerebral vessels occur in up to 10% of patients with coarctation

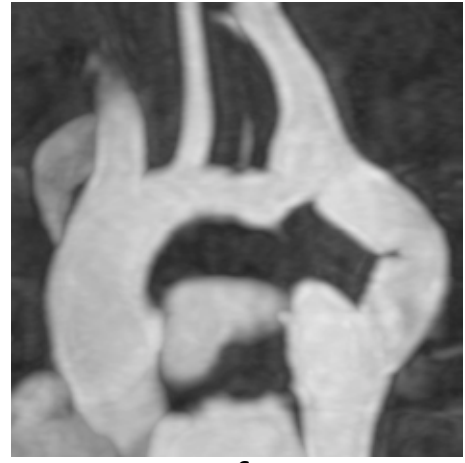Aortic Coarctation



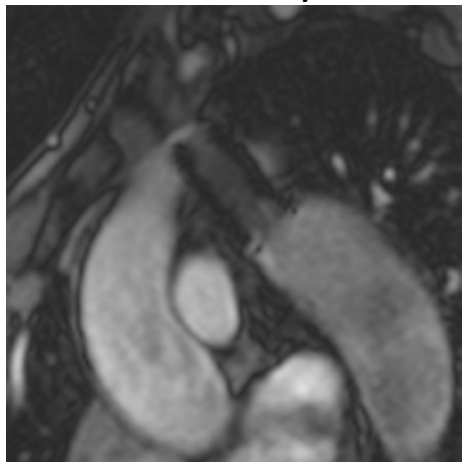
Coarctation in diastole and systole



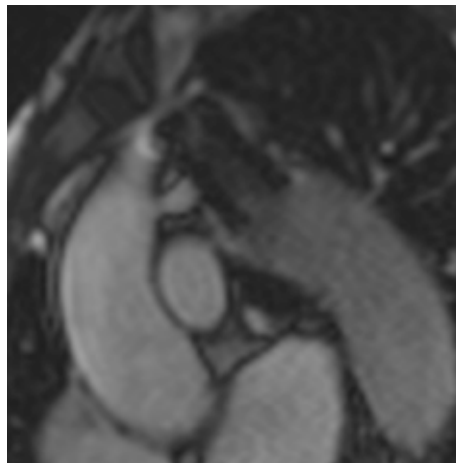
Subclavian flap



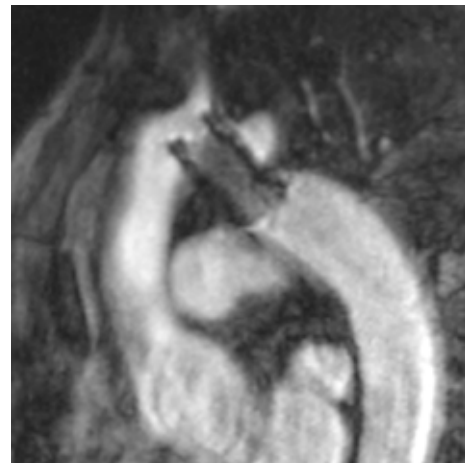Bypass graft



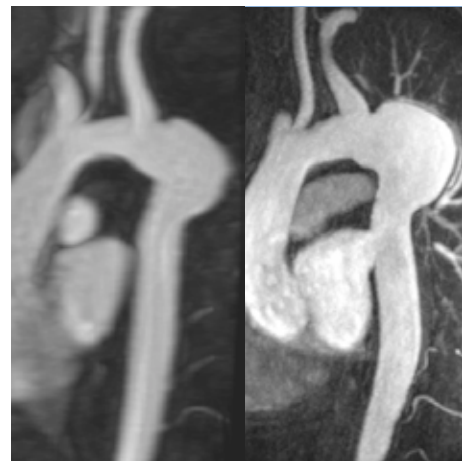Stent (FLASH)



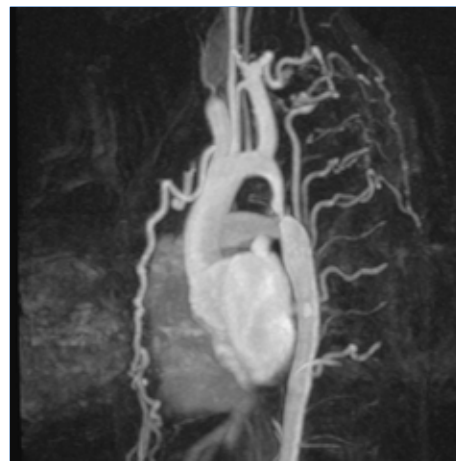Stent (SSFP)



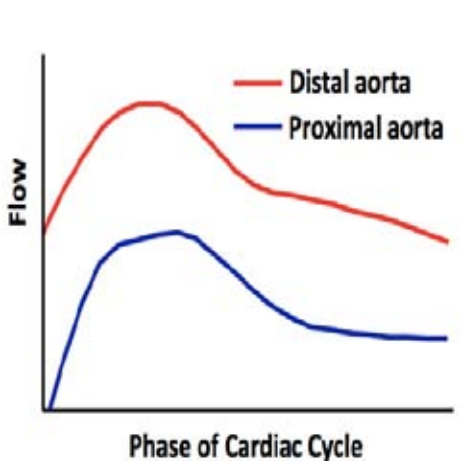
Stent (MIP)



Aortic patch with progressive aneurysm formation after 6y



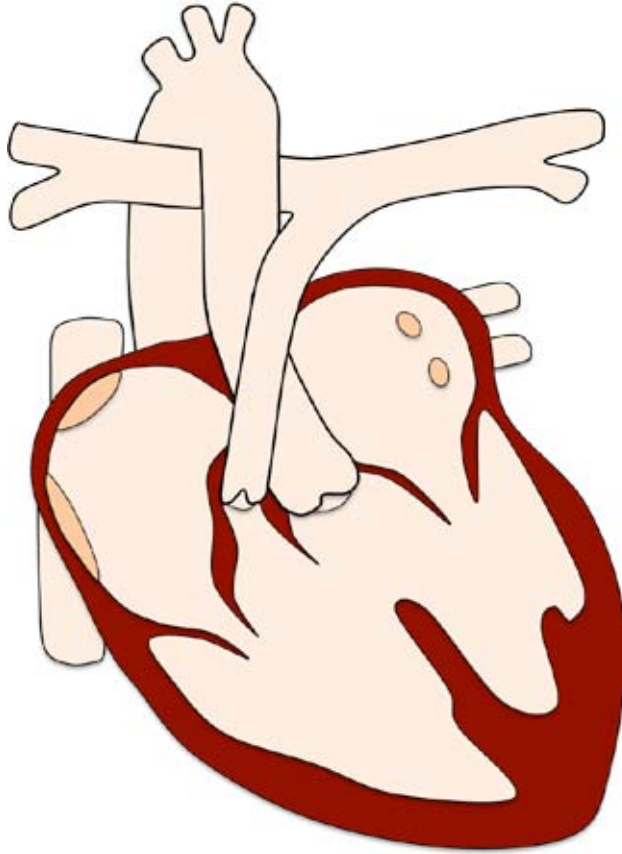
Severe coarctation and collateralization



Aortic flow with severe collaterals

[Index](#)

Tetralogy of Fallot



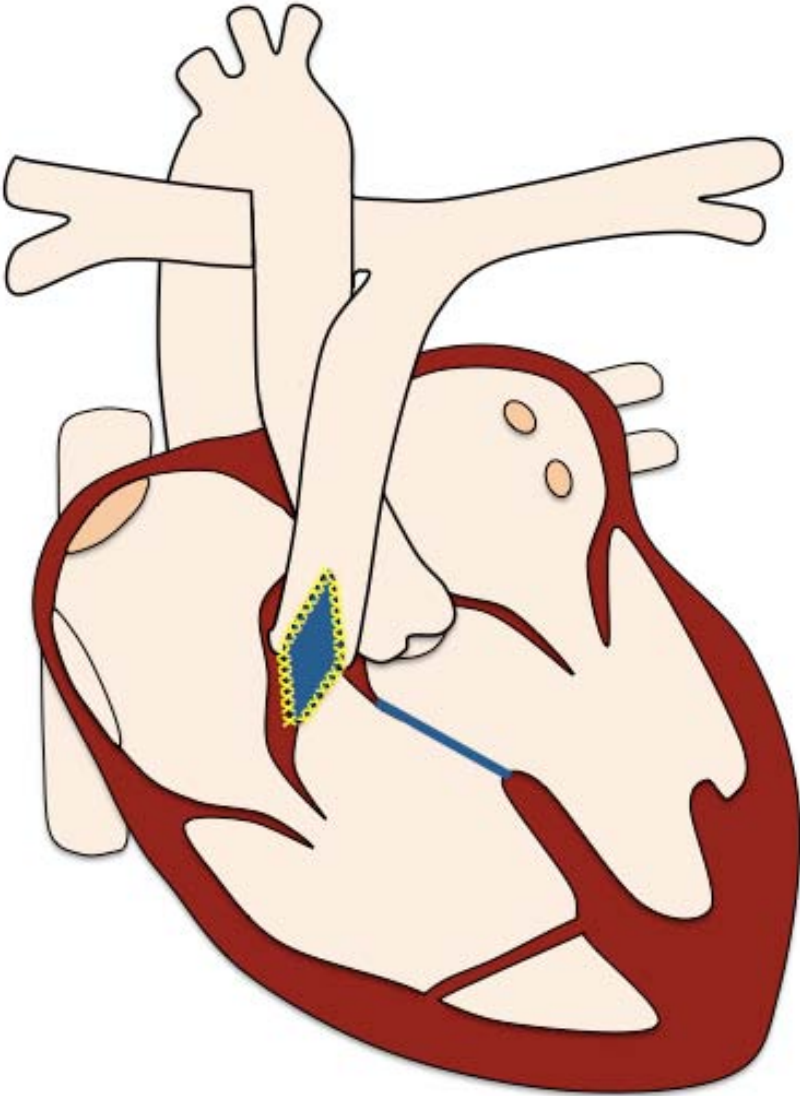
Pre-operative findings

- VSD
- Aortic override
- RV outflow tract obstruction
- RV hypertrophy

Associated findings

- ASD
- Muscular VSD, AVSD
- PDA
- Right sided aortic arch
- Anomalous coronary arteries / pulmonary venous return

Tetralogy of Fallot



Initial interventions

BT-shunt or RVOT stent

- If cyanosed++ neonatally

Total repair

- VSD patch
- RVOT patch
- conduit

Late interventions

- PV replacement (homograft, biological prosthesis)
- Re-do conduit
- PA stenting

Post-operative complications

- RV outflow and/or pulmonary artery stenosis
- Pulmonary and tricuspid valve regurgitation
- RV dilation and dysfunction, LV dysfunction
- Myocardial scarring / fibrosis
- Residual ASD and VSD
- Aortic root and ascending aorta dilation
- Aortic regurgitation

Tetralogy of Fallot

Protocol

1. **Anatomy stack**
2. **VLA, HLA, LV stack, RV stack**
3. **LVOT, RVOT**
4. **PAs**
5. **MPA flow**
6. **AoV flow**
7. **Branch PAs flow**
8. **MRA PAs**
9. **LGE LV stack, VLA, HLA**
10. **3D whole heart**

Report

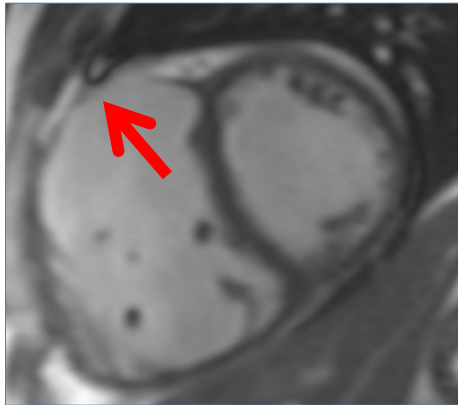
1. **Size** (corrected for BSA) and **function**
 - LV: EDV, ESV, SV, EF, RWMA, (LGE)
 - RV: EDV, ESV, SV, EF, RWMA, (LGE)
2. **RVOT obstruction**: Subvalvular, valvular, supralvalvular
3. **Main PA and branch PA obstruction and flows**
4. **Pulmonary regurgitation fraction** \pm volume
5. **Presence** and severity of TR
6. **Residual shunting**: ASD, VSD, APCs; $Q_p : Q_s$
7. **Relation to coronary arteries**
8. **Aortic root and ascAo dimensions**
9. **AV regurgitation**
10. **Associated findings**

Tetralogy of Fallot

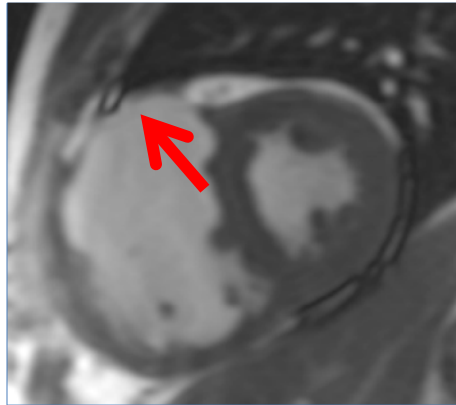
Key issues

- 1. Free PR:**
 - Is common after repair of ToF
 - May be tolerated without symptoms
 - Is typically associated with a **regurgitant fraction of 35–45%**
- 2. Unilateral branch PA stenosis**
 - compare LPA and RPA flow volumes
- 3. Regurgitant fraction may exceed 50%, if**
 - RV is unusually large and compliant
 - Pulmonary trunk / branch PAs are large and compliant
 - Elevated pulmonary vascular resistance
- 4. Late diastolic antegrade flow in the MPA**
 - Sign of restrictive RV
- 5. Timing for PV replacement remains controversial. Consider:**
 - Homograft replacement may function for 15-20 years
 - Pre-operative indexed **RV EDV >160-170 mL/m²** and **RV ESV >82-85 mL/m²** fail to recover to the normal range after operation
- 6. Percutaneous intervention of RVOT / branch PA obstruction**
 - Consider 3D whole heart to identify close relation to coronary arteries

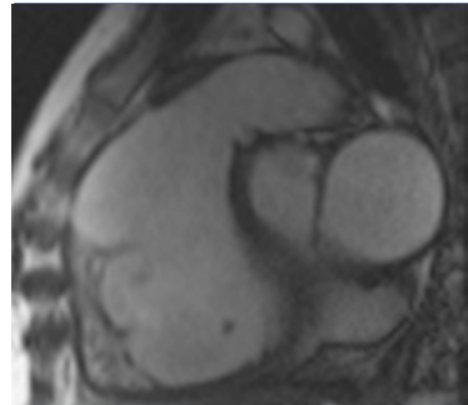
Tetralogy of Fallot



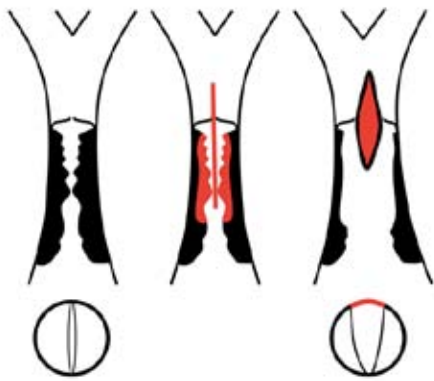
RV dilation, RVOT patch, SA diastole




RV dilation, dyskinetic RVOT patch, SA systole



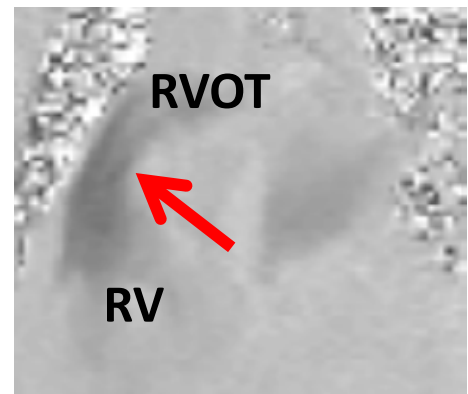
Sagittal RVOT



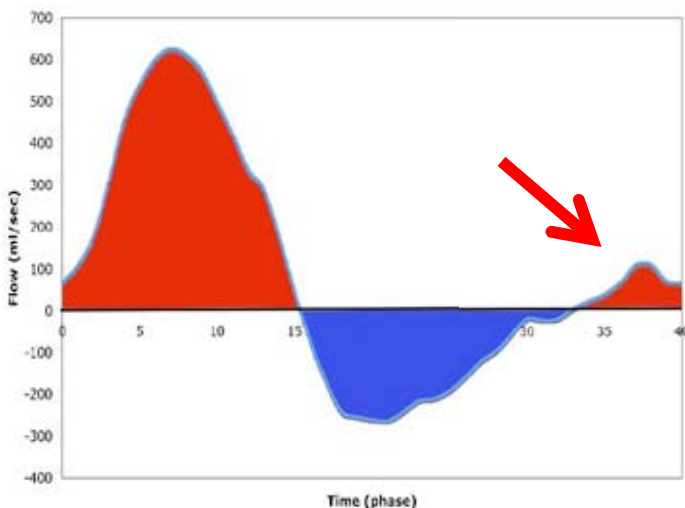
Pulmonary incompetence after RVOT patch operation



Free PI – high blood flow in RVOT in systole – inplane

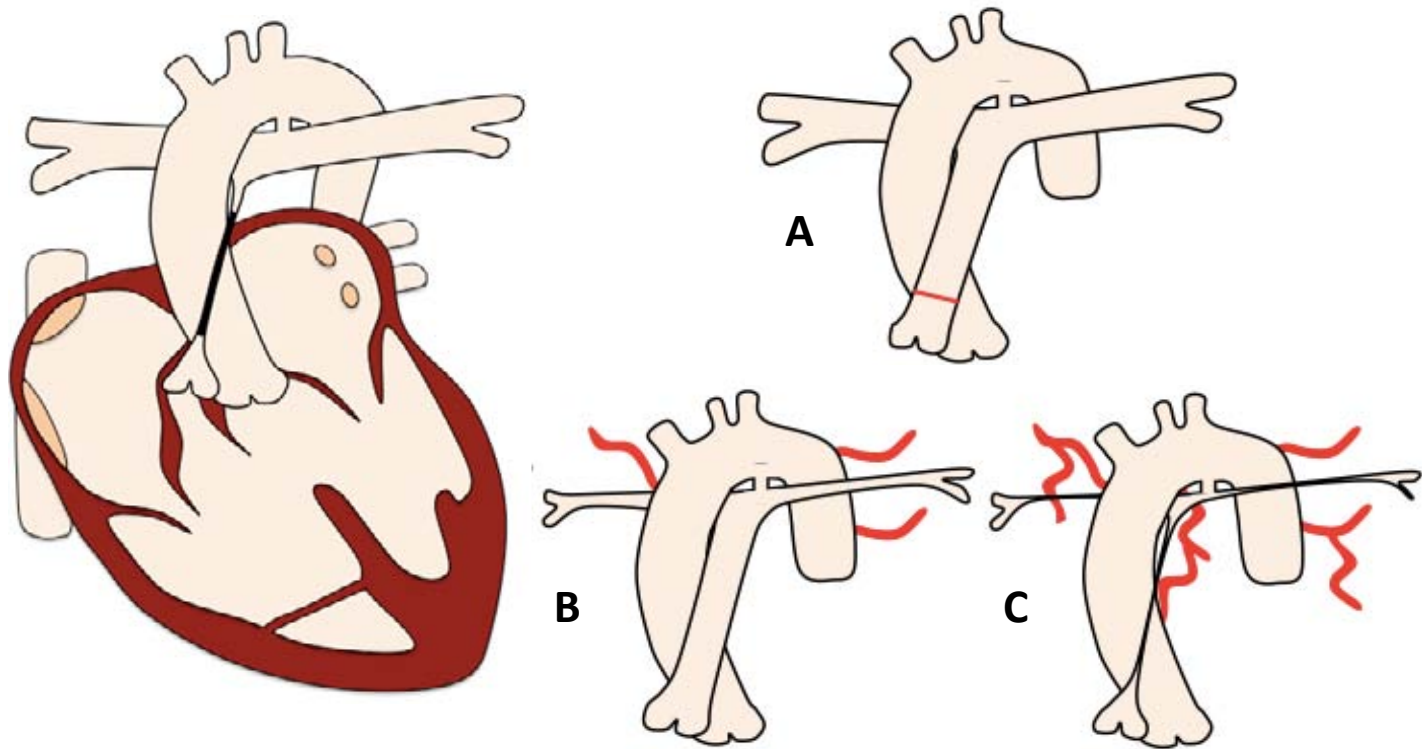


Free PI - RVOT in diastole - inplane



Late diastolic antegrade flow in the MPA as sign of restrictive RV or severe PI

Pulmonary Atresia



Pre-operative findings

- Underdeveloped RVOT and PV
 - Membranous PV (A)
 - Hypoplastic PAs (B)
 - Atretic PAs and MAPCAs (C)
- VSD / PDA
- Pulmonary collaterals
- RV / RA dilation and hypertrophy

Associated findings

- PFO / ASD
- Tricuspid atresia or stenosis
- dTGA / CCTGA

Pulmonary Atresia

Initial interventions

- Radiofrequency perforation of membranous PV
- BT shunt
- Total repair
 - PV valvulotomy or conduit, if suitable RV
 - Atrial septostomy and Glenn → Fontan, if RV small or coronaries depend on RV

Late interventions

- PV valvuloplasty
- PV replacement
- TV repair / replacement
- Conduit replacement
- MAPCA stenting / occlusion / unifocalization

Post-operative complications

- See BT-shunt, ToF or single ventricle physiology depending on severity and initial operation

Pulmonary Atresia

Protocol

1. **Anatomy stack**
2. **VLA, HLA, LV stack, RV stack**
3. **LVOT, RVOT**
4. **PAs**
5. **MPA \pm branch PAs flow**
6. **Ao flow**
7. **MRA PAs**
8. **MRA aorta (MAPCAs)**
9. **3D whole heart**
10. **LGE**

Report

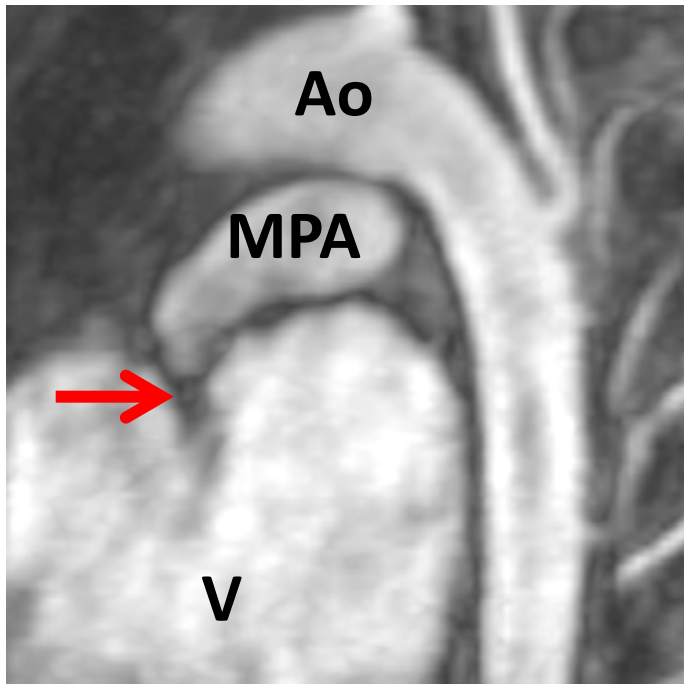
1. **Size** (corrected for BSA) and **function**
 - LV: EDV, ESV , SV, EF, RWMA, (LGE)
 - RV: EDV, ESV, SV, EF, RWMA, (LGE)
2. **PA stenosis/ hypoplasia** – extent and severity
3. **MAPCAs**
4. **Presence and severity of VSD, PDA and / or ASD**
5. **Associated findings, depending on initial interventions**

Pulmonary Atresia

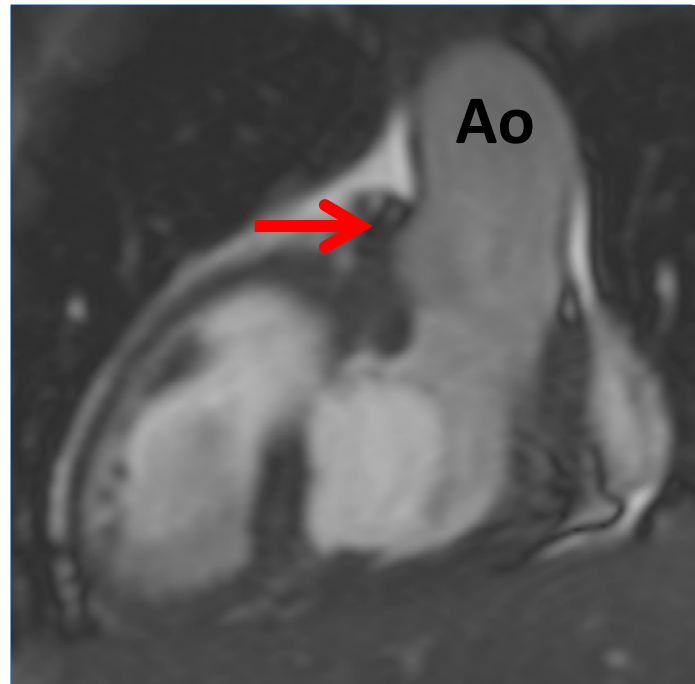
Key issues

- 1. Pulmonary atresia vs. ToF with pulmonary atresia**
 - PAs in ToF are usually normal in size with normal peripheral arborisation
 - Systemic-to-pulmonary collaterals are less developed in ToF
- 2. Complete surgical repair, if**
 - Central PAs are present
 - Sufficient PA blood supply to the lungs
 - A single PA is normal in size and reaches all lung segments
- 3. Complete surgical repair is contraindicated, if**
 - Intact ventricular septum and hypoplastic right ventricle
 - Hypoplastic or absent central PAs
 - Inadequate peripheral arborization of PAs
- 4. Palliative procedures**
 - BT shunt, Waterston shunt
- 5. MAPCAs**
 - Are best visualized on an aortic MRA
 - Strict removal of air bubbles if MRA performed
 - Consider CT to visualize small MAPCAs

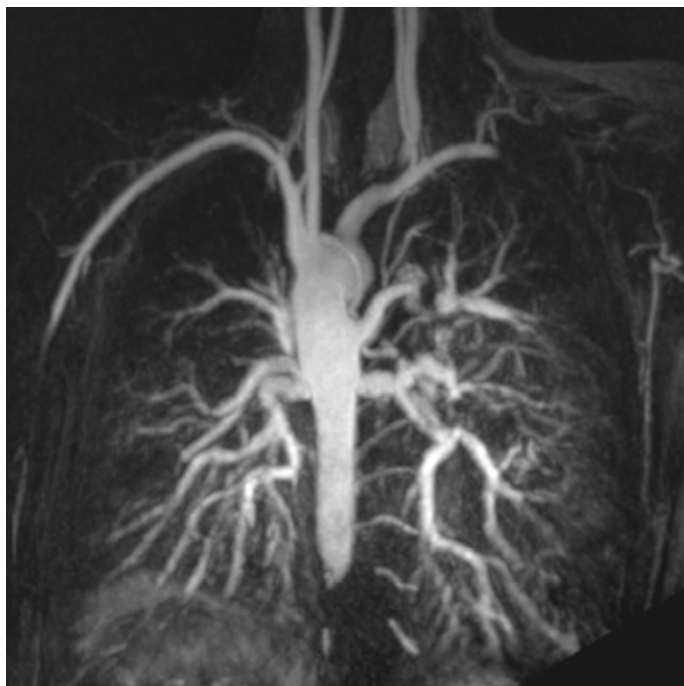Pulmonary Atresia



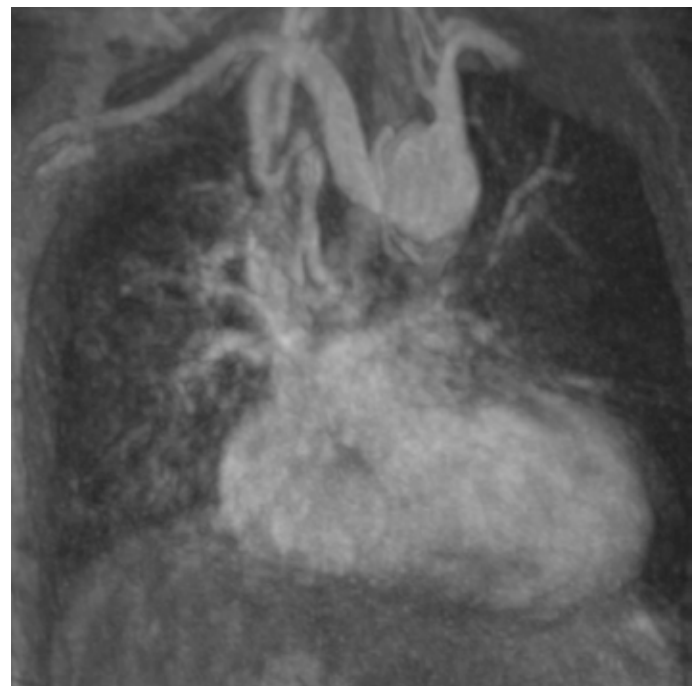
Vestigial pulmonary artery (arrow)
- MIP



Vestigial pulmonary artery (arrow),
VSD - coronal

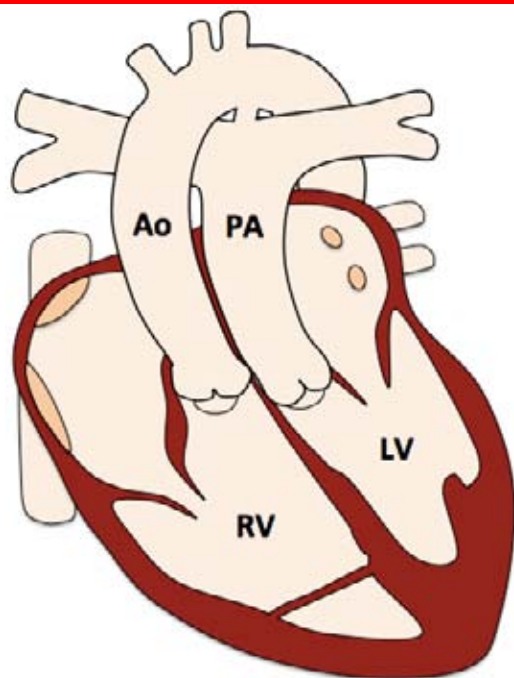


Major aorto-pulmonary
collateral arteries - MIP



Major aorto-pulmonary
collateral arteries - MIP

Dextro-Transposition of the Great Arteries - dTGA



Pre-operative findings

- **VA discordance** (morphological RV to aorta, LV to MPA)
- **Parallel great arteries**

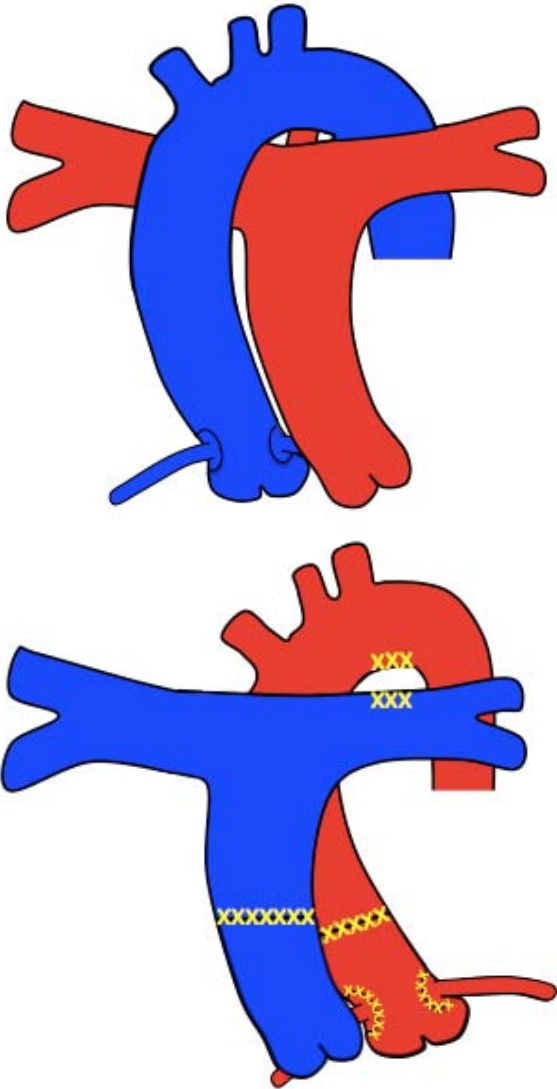
Associated findings

- **VSD / pulmonary stenosis**
- **LVOT obstruction (sub PS)**
- **PDA/ASD**
- **Aortic coarctation**
- **Coronary origin anomalies**

Common interventions

- **Arterial switch**
- **Rastelli, if accompanied with VSD and RVOT obstr. / PS**
- **Atrial switch – historical (Senning/Mustard)**

Arterial Switch



Initial interventions

- Switch of aortic and pulmonary root
- Anterior positioning of distal MPA / branch PAs (LeCompte manoeuvre)
- Translocation of coronary arteries from aorta to neo-aortic root

Late interventions

- AV replacement
- Ao root replacement
- RVOT enlargement
- PA stenting

Post-operative complications

- RVOT obstruction / MPA and branch PA stenosis
- LVOT obstruction
- Neo-aortic root dilatation
- Neo-aortic valve regurgitation
- Neo-pulmonary valve regurgitation
- Coronary artery stenosis
- Systemic RV dysfunction

Arterial Switch

Protocol

1. **Anatomy stack**
2. **VLA, HLA, LV stack, RV stack**
3. **LVOT, RVOT**
4. **PAs**
5. **MPA flow**
6. **AoV flow**
6. **3D whole heart**
7. **Branch PAs flow**
8. **MRA PAs**
9. **LGE**
10. **Stress myocardial perfusion**

Report

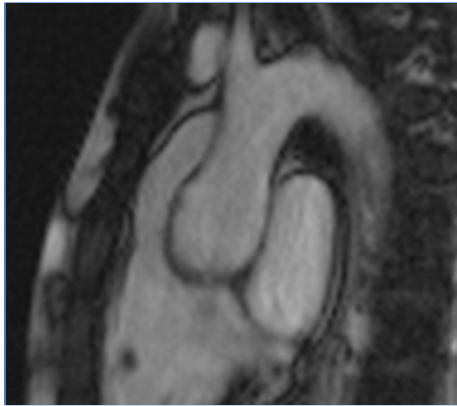
1. **Size (corrected for BSA) and function**
 - LV: EDV, ESV , SV, EF, RWMA, mass
 - RV: EDV, ESV, SV, EF, RWMA
2. **RVOT / LVOT obstruction**
3. **MPA & branch PA patency (and flow)**
4. **PR and AR**
5. **Aortic dimensions**
6. **Coronary artery origins, proximal course and patency**
7. **Myocardial ischemia and / or scar**

Arterial Switch

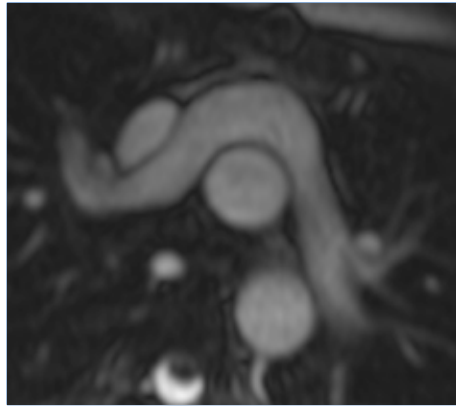
Key issues

- 1. Arterial switch procedure:**
 - Is the operation of choice in dTGA
 - Is usually performed in the first two weeks of life
 - Has a favourable long-term outcome
- 2. Most progressive post-operative complications:**
 - Neo-aortic regurgitation
 - Neo-pulmonary stenosis
 - Coronary obstruction
- 3. If coronary obstruction is suspected, consider:**
 - 3D whole heart to assess the coronary origin and course (& patency)
 - Stress perfusion for the assessment of ischemia
 - LGE imaging for the assessment of scar

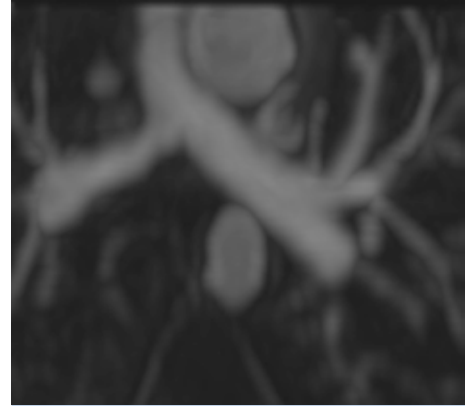
Arterial Switch



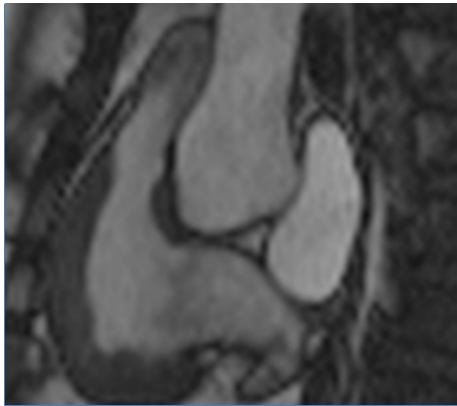
dTGA with parallel great arteries



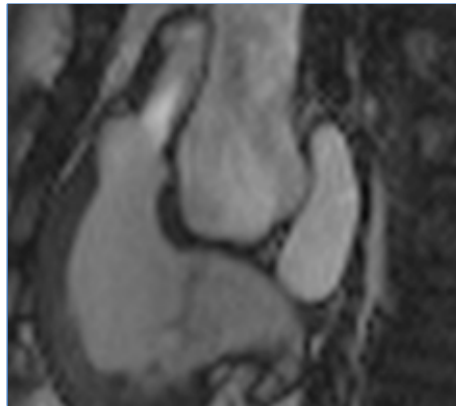
LeCompte maneuver with anterior PAs



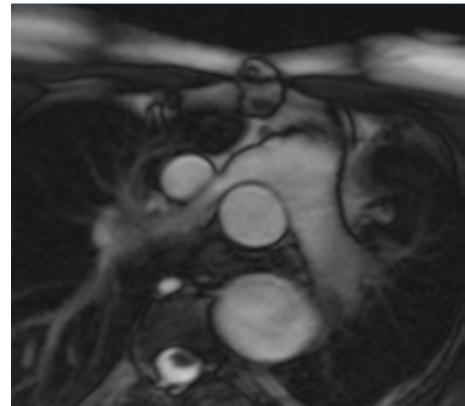
Posterior PAs - side by side arteries



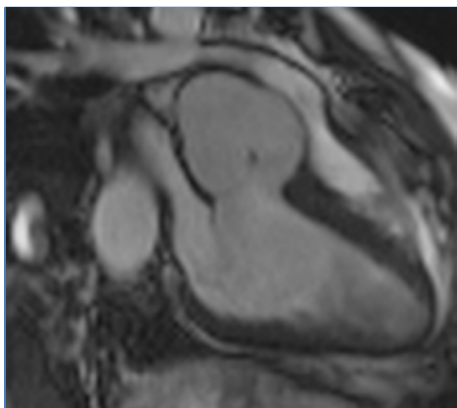
Supralvalvular RVOT obstruction in diastole



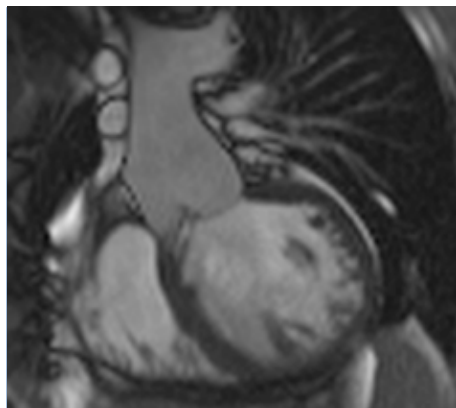
Supralvalvular RVOT obstruction in systole



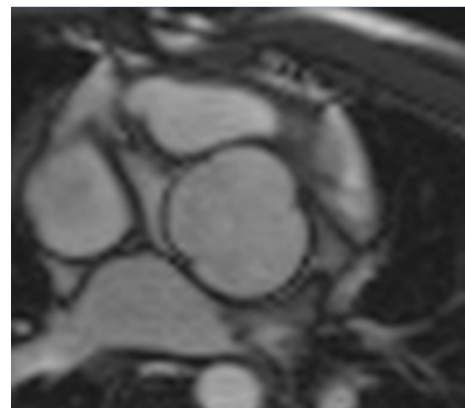
RPA stenosis



Aortic root dilatation - sagittal LVOT



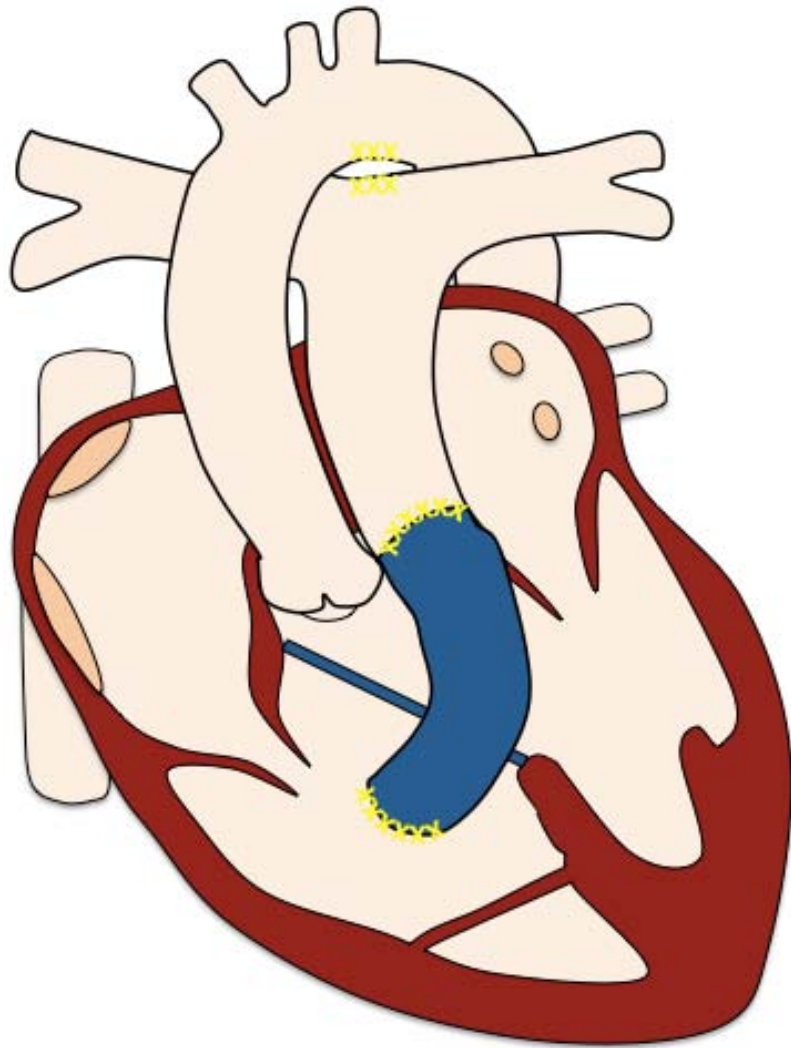
Aortic root dilatation - coronal LVOT



Aortic root dilatation - AV stack

[Index](#)

Rastelli



Initial interventions

- Conduit RV-MPA
- Intra-ventricular baffle
 - VSD closure
 - Redirection of left ventricular outflow to anterior aortic valve

Late interventions

- Re-operation conduit
- VSD closure device

Post-operative complications

- Conduit or conduit valve stenosis / obstruction
- LVOT obstruction
- Residual VSD
- Residual ASD
- Branch PA stenosis

Rastelli

Protocol

1. **Anatomy stack**
2. **VLA, HLA, LV stack, RV stack**
3. **LVOT, RVOT**
4. **PAs**
5. **Conduit cross-cuts**
6. **MPA flow**
7. **AoV flow**
8. **Branch PAs flow**
9. **3D whole heart**
10. **Coronal cine stack**

Report

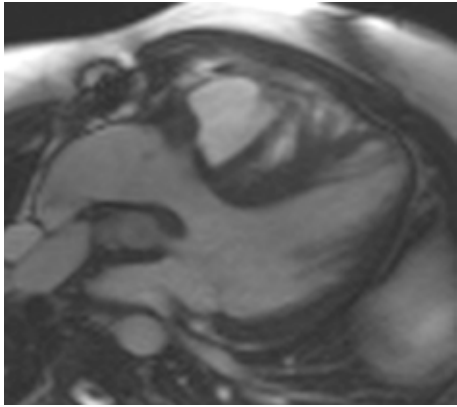
1. **Size (corrected for BSA) and function**
 - LV: EDV, ESV , SV, EF, RWMA, mass
 - RV: EDV, ESV, SV, EF, RWMA
2. **Conduit patency and proximity to sternum**
3. **LVOT obstruction**
4. **MPA & branch PA patency (and flow)**
5. **Residual ASD, VSD, Qp (MPA flow) : Qs (Ao flow)**
6. **Course of coronary arteries and likelihood of compression if percutaneous intervention to the conduit**

Rastelli

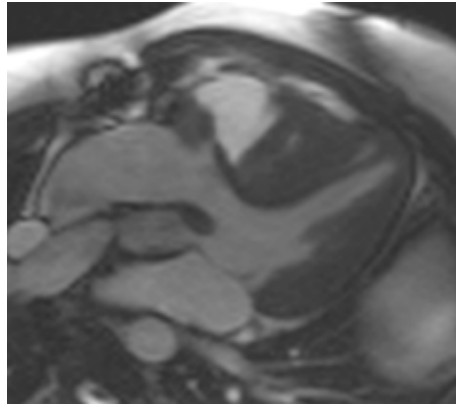
Key issues

1. Is usually performed between one and two years of age with a BT shunt in the meantime
2. **Allows for correction of a combination of congenital defects**
 - dTGA / double outlet right ventricle and
 - VSD and
 - RVOT obstruction
 - Pulmonary atresia
 - Pulmonary / subpulmonary stenosis
3. **Maintains systemic LV**
 - At the cost of possible LVOT obstruction and inevitable conduit interventions (surgical or percutaneous)
4. **Obstruction of RV-PA conduit**
 - The conduit runs very anteriorly, mostly directly beyond the sternum. This frequently causes an obstruction.

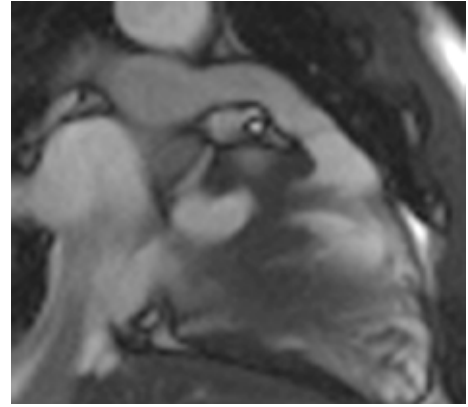
Rastelli



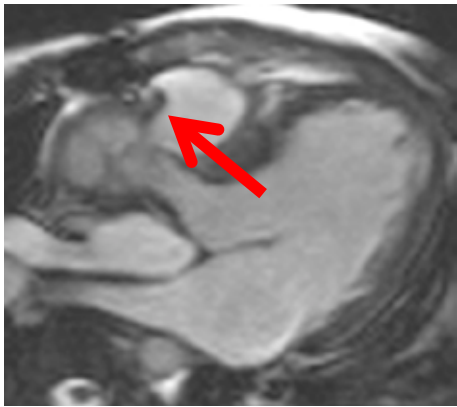
Intra-ventricular
baffle in diastole



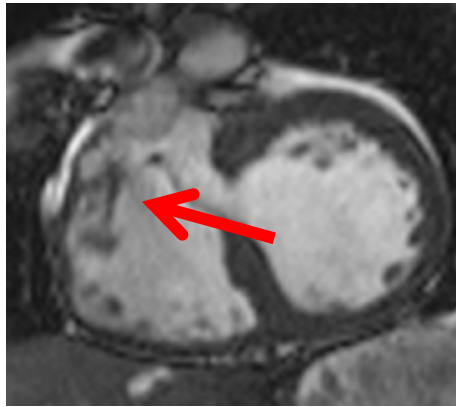
Intra-ventricular
baffle in diastole



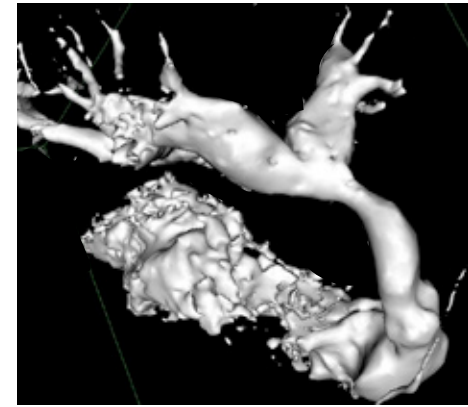
RV-MPA conduit



VSD baffle leak

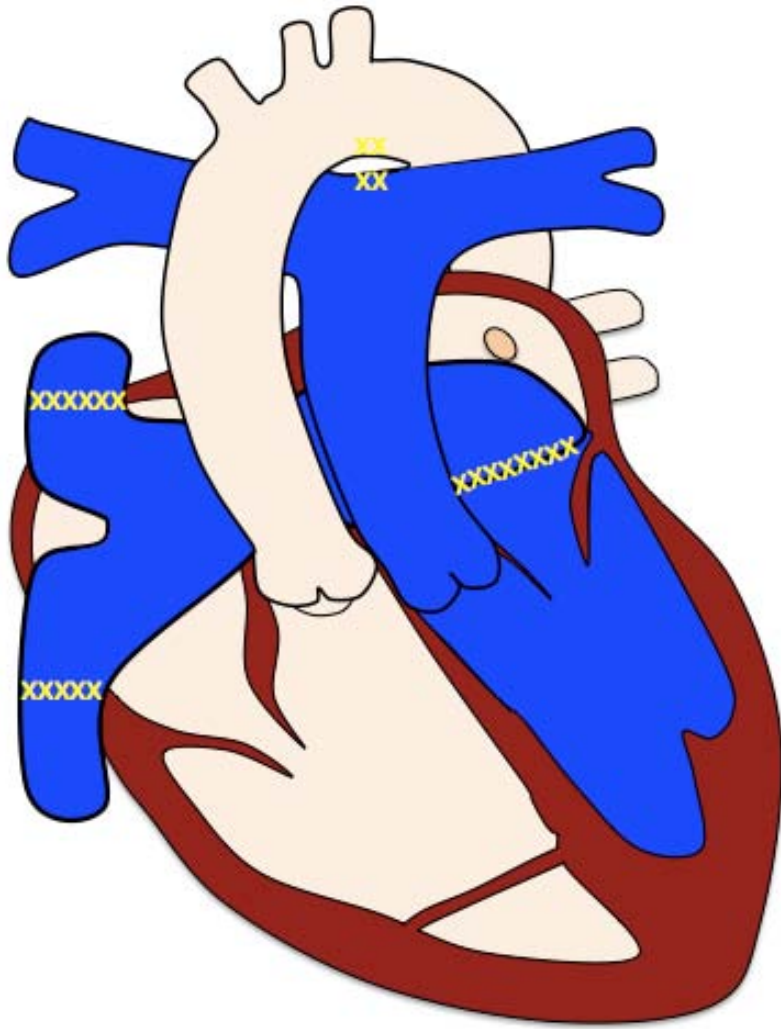


VSD baffle leak



RV-MPA conduit

Mustard / Senning



Initial interventions

- Systemic venous baffle
 - directing systemic venous blood to MV
- Pulmonary venous baffle
 - directing pulmonary venous blood to TV

Late interventions

- Baffle dilation / stenting
- Closure devices
- Surgical baffle revision
- Pacemaker

Post-operative complications

- Systemic and pulmonary venous baffle obstruction
- Systemic and pulmonary venous baffle leak
- Systemic RV dysfunction
- Tricuspid regurgitation
- Sub-pulmonary obstruction

Mustard / Senning

Protocol

1. **Anatomy**
2. **VLA, HLA, LV stack, RV stack**
3. **LVOT, RVOT**
4. **PAs**
5. **Baffle cine stack in axial and SA plane**
7. **MPA flow**
8. **AoV flow**
9. **MRA PAs**
9. **3D whole heart**
10. **Coronal stack**

Report

1. **Size (corrected for BSA) and function**
 - LV: EDV, ESV , SV, EF, RWMA, mass
 - RV: EDV, ESV, SV, EF, RWMA
2. **Baffle obstruction**
3. **Baffle leak / shunt, Qp/Qs**
4. **Presence (and severity) of RVOT obstruction**
5. **Presence (and severity) of TR**

Mustard / Senning

Key issues

1. **If baffle stenosis, consider**

- 3D whole heart
- MRA
- Transaxial flow to assess flow reversal in azygous veins system, if SVC baffle-limb is stenosed

2. **Systemic venous baffle stenosis**

- In 5-15% of patients, SVC > IVC
- SVC channel patency required for transvenous pacing
- IVC baffle stenosis less-well tolerated than SVC b. stenosis
 - Alternative blood drainage through azygos veins system
 - Elevated venous pressure on the liver

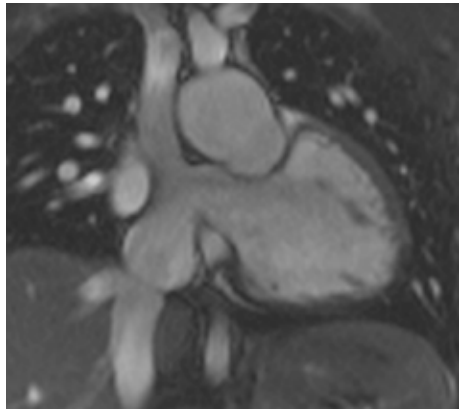
3. **Pulmonary venous baffle stenosis**

- Physiology similar to mitral stenosis in the normal heart
- Consider stenosis in patients with pulmonary hypertension

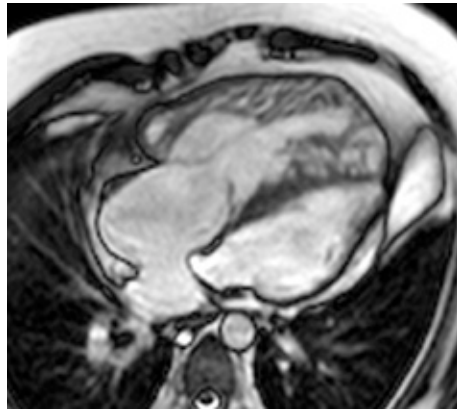
4. **Systemic right ventricle**

- MRI allows longitudinal follow up and change in function
- If dilated RV with good function and severe systemic TR valve replacement may be advantageous
- If TR valve regurgitation due to systemic RV failure and annular dilatation then no conventional options available

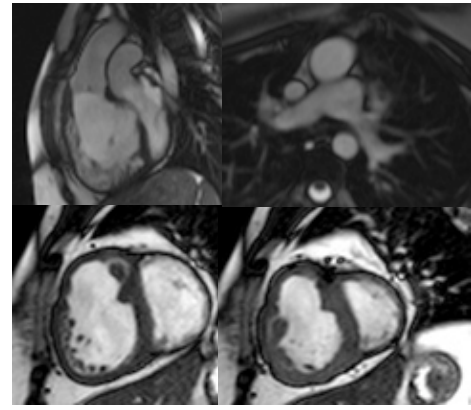
Mustard / Senning



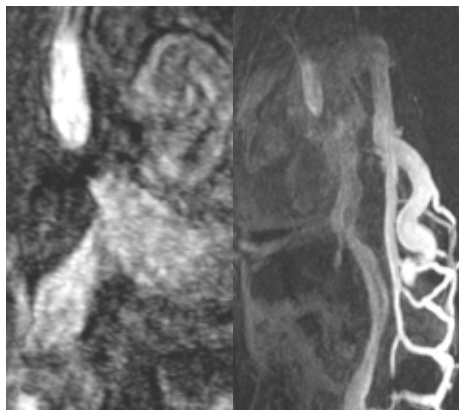
Systemic venous baffle



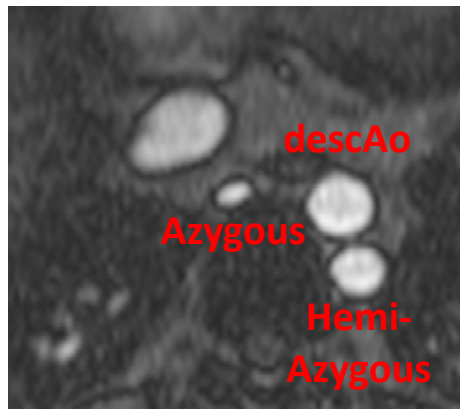
Pulmonary venous baffle



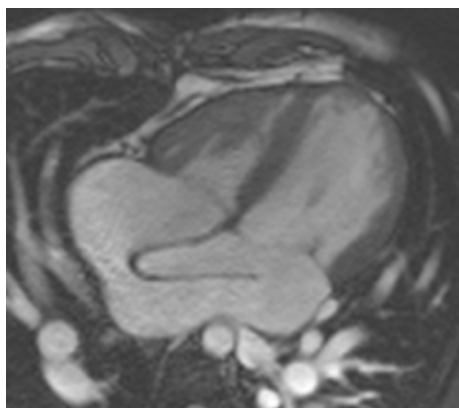

Parallel great arteries
Systemic RV



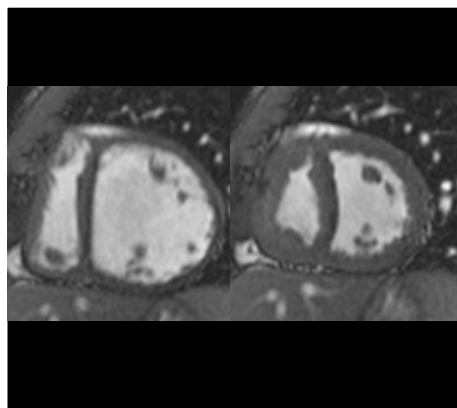
Occluded SVC baffle
with azygous drainage



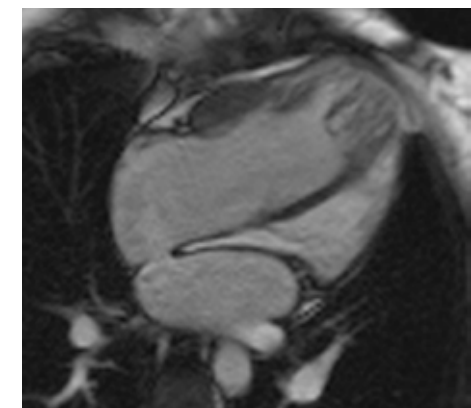
Reversed drainage through azygous system –
same direction as flow in descAo



Pulmonary venous
baffle leak with LV
volume overload



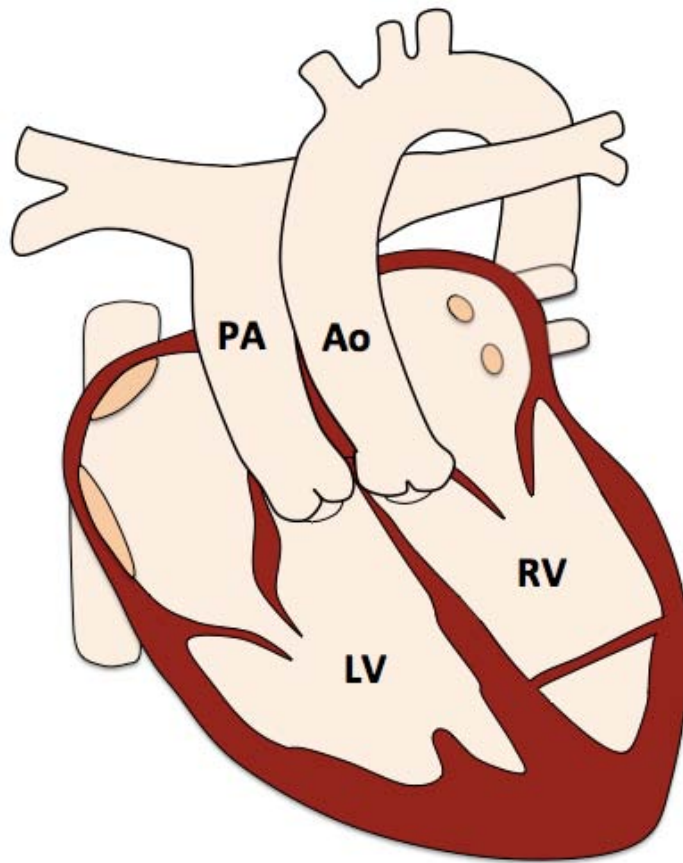
LV (sub-pulmonary)
volume overload
(diastole / systole)
with baffle leak



Pulmonary venous
baffle
stenosis

[Index](#)

Congenitally Corrected Transposition of the Great Arteries



Pre-operative findings

- L-TGA: AV and VA discordance
- Systemic RV
- Parallel great arteries

Associated abnormalities

- VSD
- Ebstein-like malformation of the left-sided TV
- (Sub-)pulmonary stenosis
- Aortic coarctation
- Abnormal situs

Congenitally Corrected

Transposition of the Great Arteries

Interventions

- Depend on associated findings

Protocol

1. **Anatomy**
2. **VLA, HLA, LV stack, RV stack**
3. **LVOT, RVOT**
4. **PAs**
5. **MPA flow**
6. **AoV flow**
7. Branch PAs flow
8. 3D whole heart
9. Coronal stack
10. TR flow

Report

1. **Size** (corrected for BSA) and **function**
 - LV: EDV, ESV, SV, EF, RWMA, mass
 - RV: EDV, ESV, SV, EF, RWMA
3. **Presence and type, size and location of VSD**, jet velocity, **Qp:Qs**
4. **Presence** (and severity) of **TR**
5. **Presence** (and severity) of **(sub-)pulmonary stenosis**
6. **Other associated findings**

Congenitally Corrected

Transposition of the Great Arteries

Key issues

1. CCTGA

- Usually associated with other congenital anomalies
- A large and peri-membranous VSD is the most common associated anomaly
- Prognosis depends on associated anomalies
- May present late in life

2. Coronary arteries

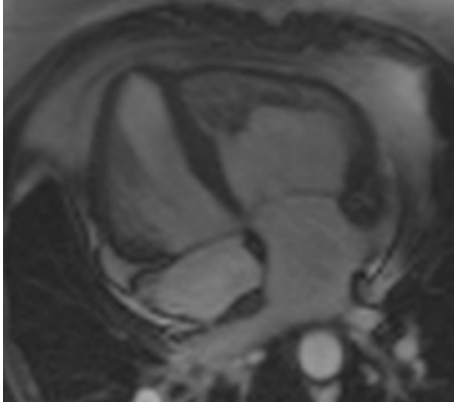
- Mirror image location

3. Systemic RV

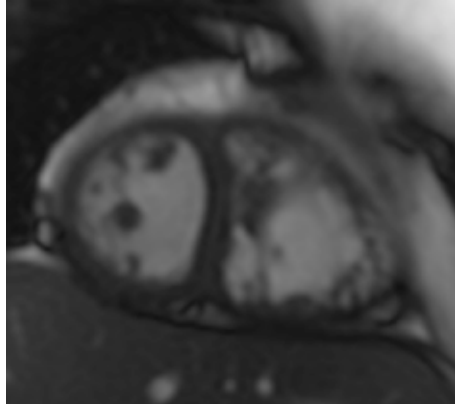
- Multiple coarse trabeculations, including the moderator band, arising from RV side of the septum
- Best visible on RV stack (and LV stack)
- Prone to dysfunction
- AV valve goes with ventricle TV with RV, MV with LV

Congenitally Corrected

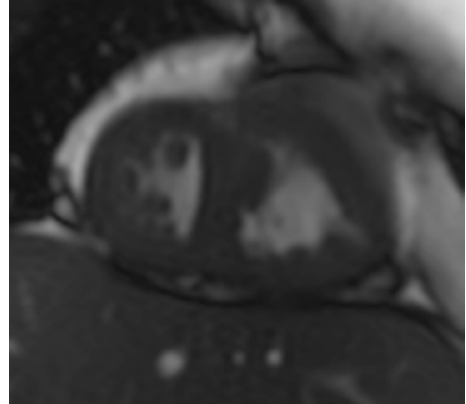
Transposition of the Great Arteries



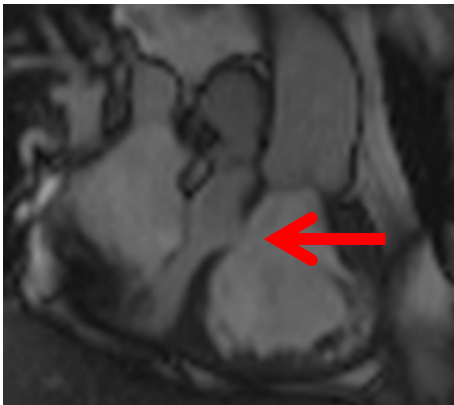
CCTGA with AV discordance



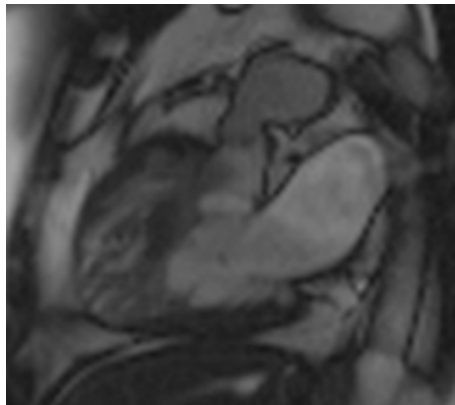
Systemic RV in diastole



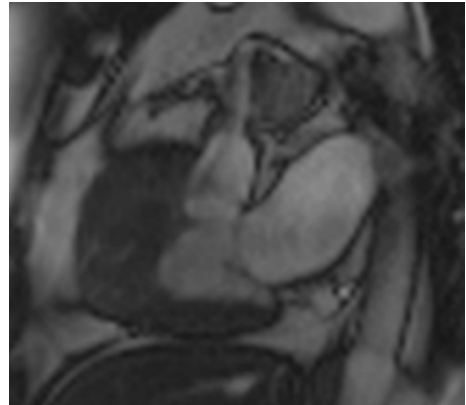
Systemic RV in systole



Parallel arteries,
VSD

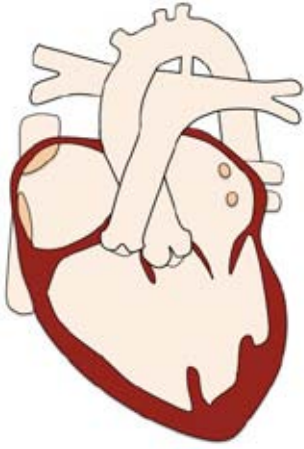


Supravalvular RVOT
stenosis in diastole

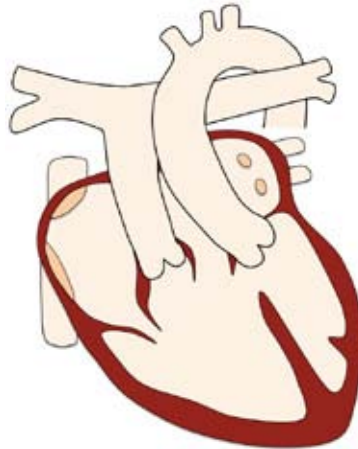


Supravalvular RVOT
stenosis in systole

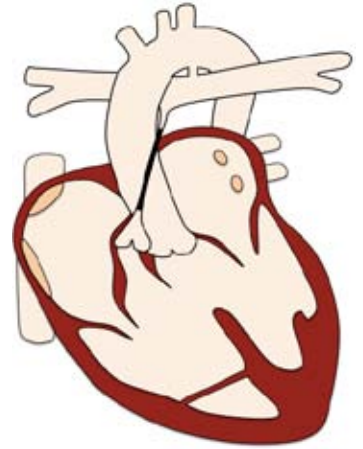
Single Ventricle Physiology



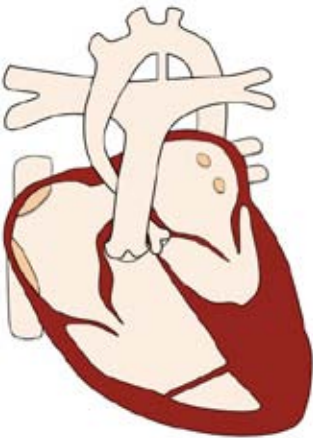
Tricuspid atresia



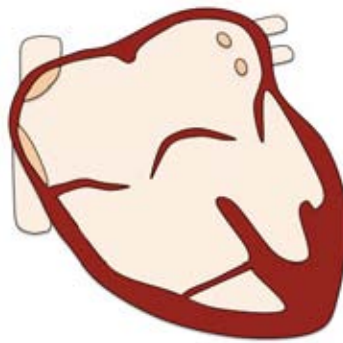
Double inlet ventricle



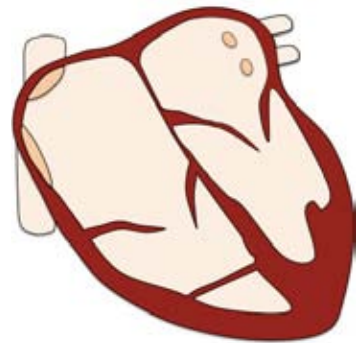
Pulmonary atresia



Hypoplastic left heart



Unbalanced AVSD



Ebstein anomaly

Pre-operative conditions

- Tricuspid atresia
- Double inlet ventricle
- Pulmonary atresia
- Hypoplastic left heart
- Unbalanced AVSD
- Severe Ebstein anomaly

Single Ventricle Physiology

Palliative procedure

Stage 1 - Glenn procedure

Stage 2 - Fontan completion

- Total cavo-pulmonary connection (TCPC)
 - Lateral tunnel - intracardiac
 - Extracardiac
 - Atrio-pulmonary

Additional interventions

Atrial septostomy

- to maintain systemic venous return to heart

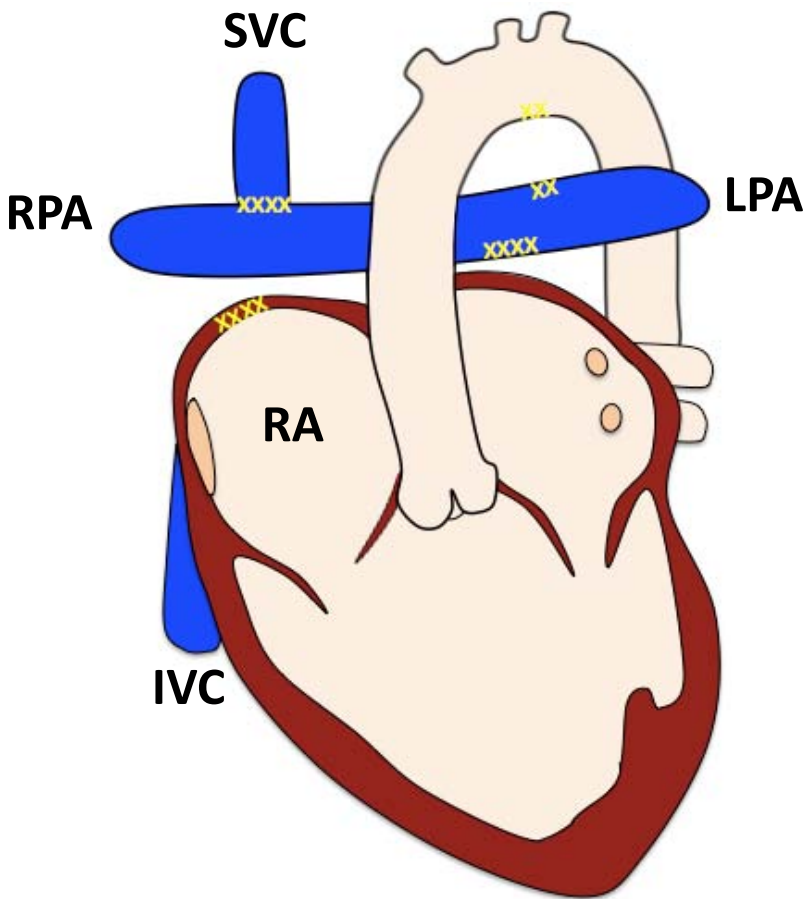
Arterial shunt

- if inadequate pulmonary blood supply

PA banding

- if excessive pulmonary blood supply

Glenn Procedure



Initial interventions

- SVC detachment from RA
- Reconnection to RPA

Late interventions

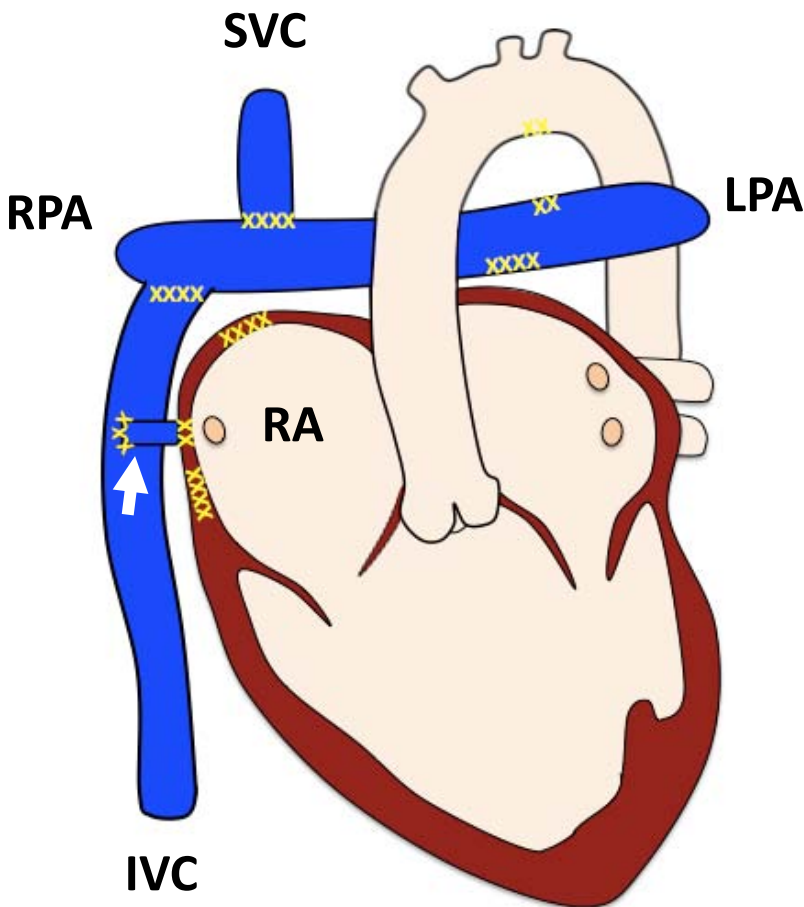
- Usually proceeds Fontan
- Collateral vessels may require occlusion if significant desaturation

Post-operative complications

- Proximal insertion stenosis
- PA dilation
- Collateral formation (usually via azygous dilatation)

Fontan Procedure

- Extracardiac -



Initial interventions

- Preceded by Glenn shunt or BT shunt

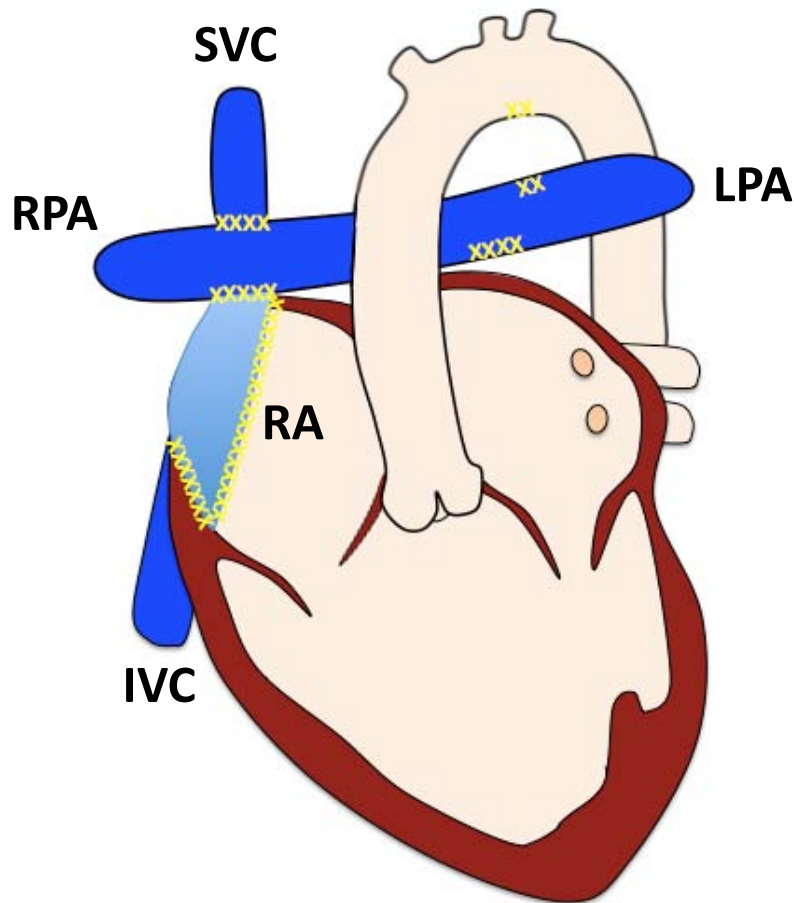
Late interventions

- Occasional fenestration (arrow) closure
- Occlusion of systemic to pulmonary venous collaterals

Post-operative complications

- Stenosis to systemic venous pathways
- Ascites (due to protein losing enteropathy)
- Deterioration of ventricular function
- Thrombus always possible
- Pulmonary venous compression
- AV valve regurgitation

Fontan Procedure - Lateral Tunnel -



Initial interventions

- Preceded by Glenn shunt or BT shunt

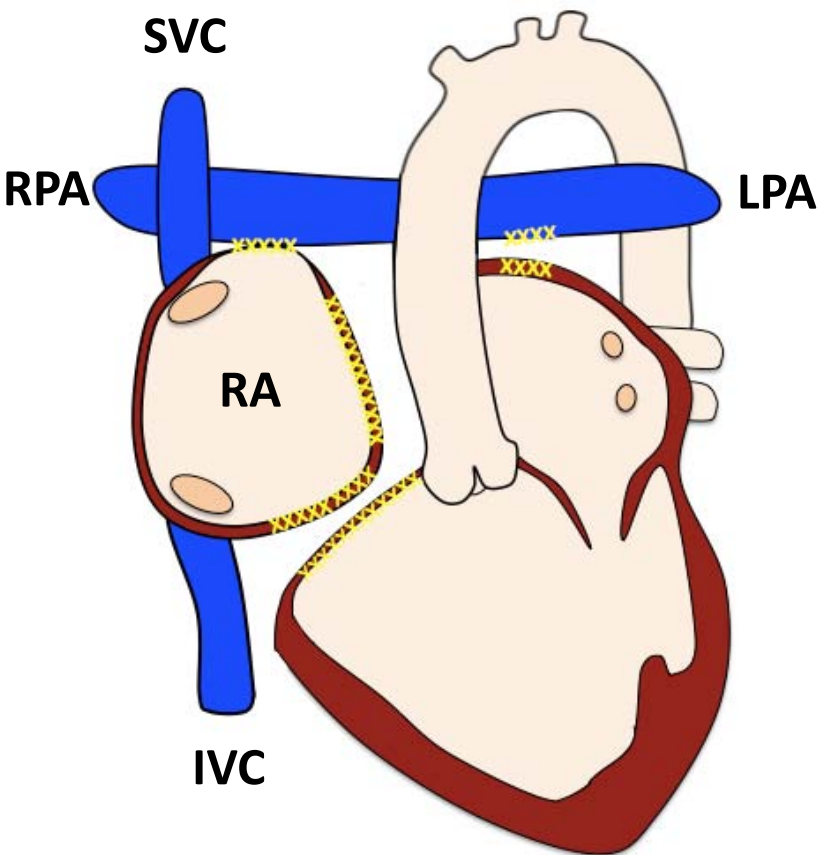
Late interventions

- Occasional fenestration closure
- Occlusion of systemic to pulmonary venous collaterals

Post-operative complications

- Stenosis to systemic venous pathways
- Ascites (due to protein losing enteropathy)
- Deterioration of ventricular function
- Thrombus always possible
- Pulmonary venous compression
- AV valve regurgitation

Atrio-pulmonary Fontan Procedure



Initial interventions

- Preceded by Glenn shunt or BT shunt

Late interventions

- Occasional fenestration closure
- Occlusion of systemic to pulmonary venous collaterals

Post-operative complications

- Stenosis to systemic venous pathways
- Ascites (due to protein losing enteropathy)
- Deterioration of ventricular function
- Massively dilated RA
- Thrombus risk particularly high
- Pulmonary venous compression
- AV valve regurgitation
- No Glenn shunt as direct communication

Single Ventricle Physiology

Protocol

1. **Anatomy stack**
2. **VLA, HLA, LV stack, RV stack**
3. **LVOT, RVOT**
4. **AoV**
5. **PAs**
6. **MPA \pm branch PAs flow**
7. **AoV \pm desc Ao flow**
8. **SC, IVC flow**
9. **MRA for collaterals**
10. **3D whole heart**
11. **EGE**

Report

1. **Size (corrected for BSA) and function**
 - Ventricle: EDV, ESV , SV, EF, RWMA
2. **Systemic venous pathways**
3. **PA stenosis or dilation**
4. **Presence of pulmonary vein compression**
5. **Outflow tract obstruction or dilation and VA valve function**
6. **AV valve regurgitation**
7. **Presence of thrombus**
8. **Fenestration patency**
9. **Extra cardiac findings (pleural effusions, ascites)**

Single Ventricle Physiology

Key issues

1. Ventricular function

- The **single ventricle drives the circuit** so there is a **chronic low output state**
- Deterioration in function results in worsening of clinical state in part due to **increase in LVEDP** and **the pulmonary artery pressures**

2. AV valve function

- Regurgitation results in inefficiency of ventricular function, increased risk of atrial arrhythmias and increase in atrial pressures

3. Patent systemic venous pathways

- If obstructed then essentially cardiac afterload increases and there is an increased risk of ascites, PLE and ventricular failure

4. Pulmonary venous compression

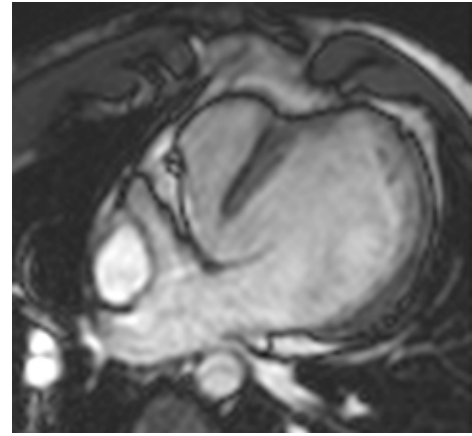
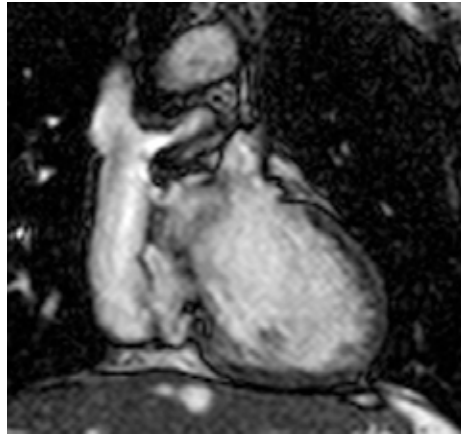
- Particularly occurs in atrio-pulmonary Fontan as the RA dilates and compresses the right pulmonary veins.
- Increased pulmonary venous pressure and PA pressure with the same risks as obstructed systemic venous pathways

5. Assessment of thrombus

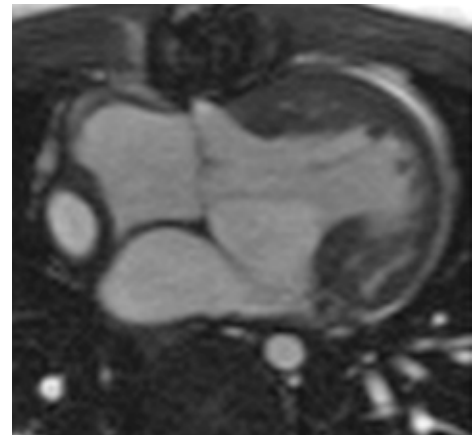
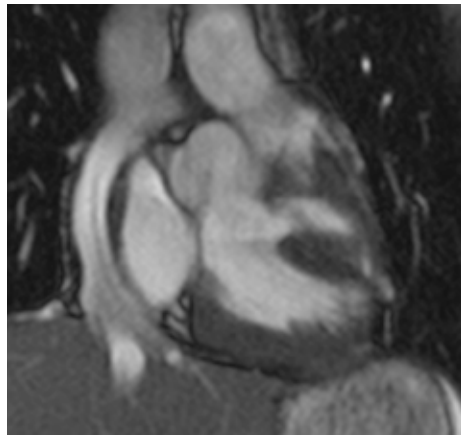
- The Fontan circuit is prone to thrombus formation due to low flow
- If PLE \square increased pulmonary vascular resistance

Single Ventricle Physiology

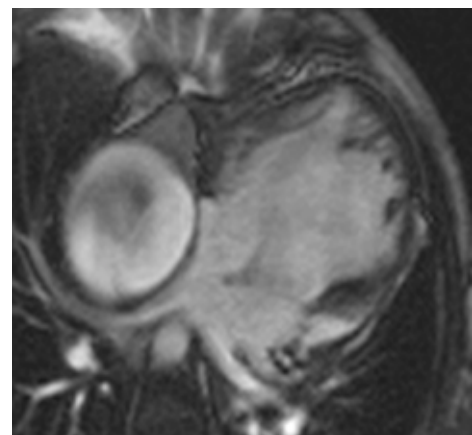
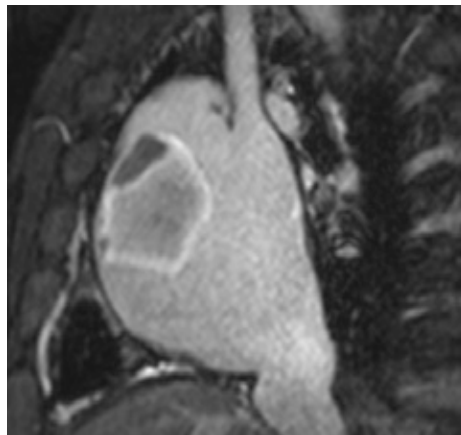Lateral tunnel Fontan



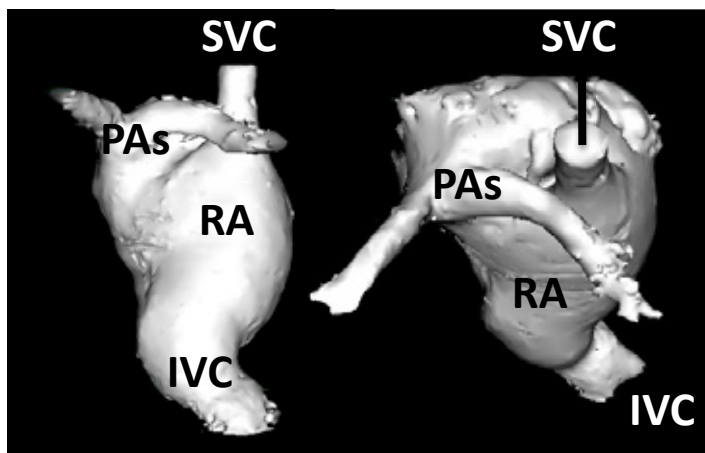
Extracardiac Fontan



Classical AP Fontan with thrombus in RA

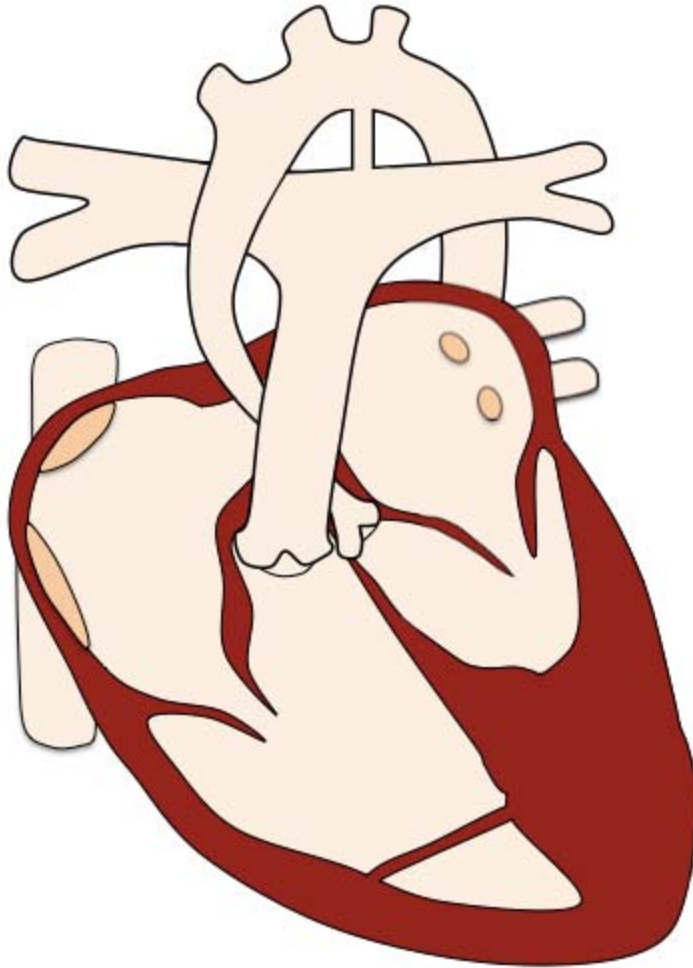


Classical AP Fontan MRA



[Index](#)

Hypoplastic Left Heart



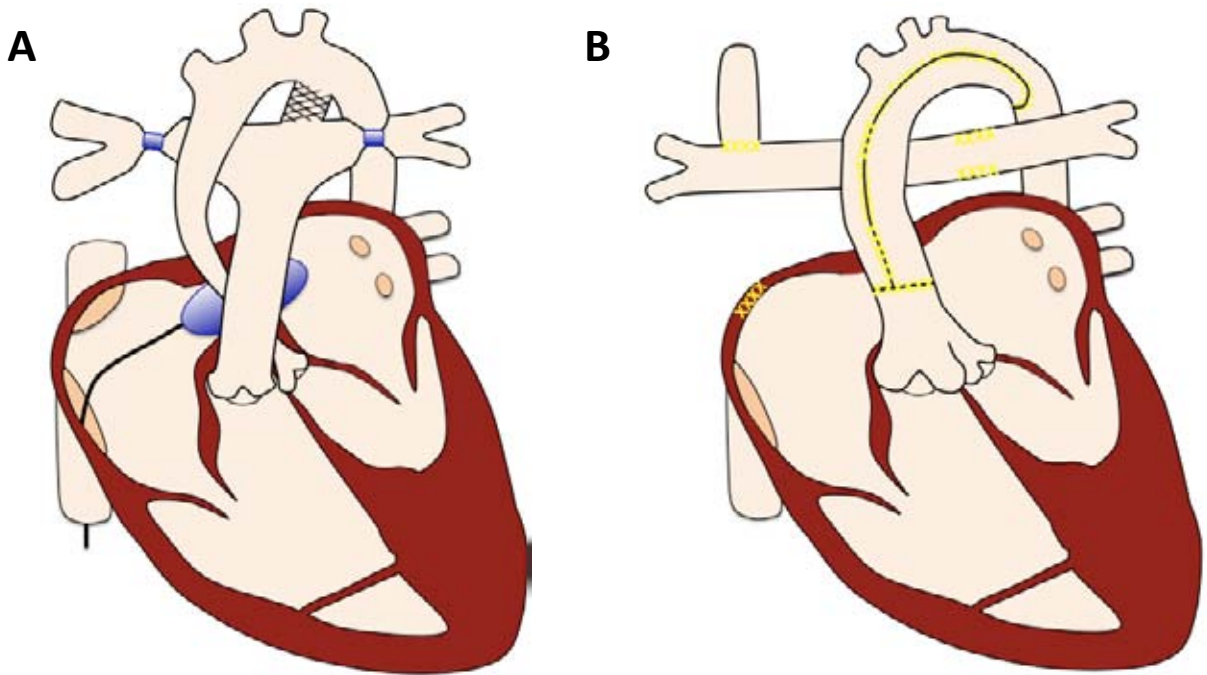
Pre-operative findings

- Marked hypoplasia of the LV and ascending aorta
- AV and MV are atretic, hypoplastic, or stenotic
- PDA and / or ASD
- Double outlet RV in 25%

Associated findings

- Aortic coarctation

Hypoplastic Left Heart



Interventions

Hybrid procedure (A)

- PDA stent, atrial septostomy, pulmonary banding

Norwood procedure (B)

Stage 1: MPA used to augment aorta

RV utilised as a systemic ventricle

PA to ascAo anastomosis to supply coronary circulation

BT shunt or RV to PA shunt to supply PAs

Atrial septectomy

Stage 2: Glenn procedure

Stage 3: Fontan completion

Damus-Kaye-Stancel anastomosis (augmented neo-aorta)

Index

Hypoplastic Left Heart

Post-operative complications

As per Fontan, plus:

- Aortic recoarctation
- ASD restriction / closure
- LPA stenosis
- Dysfunction of systemic RV
- TR
- Coronary insufficiency / ischemia

Protocol

1. **Anatomy stack**
2. **VLA, HLA, LV stack, RV stack**
3. **LVOT, RVOT**
4. **AV / TV**
5. **PAs**
6. **MPA \pm branch PAs flow**
7. **Cavo-pulm. shunt flow**
8. **3D whole heart**
9. **MRA PAs**

Report

As per Fontan, plus:

1. **Neo-aortic dimensions**
2. **ASD flow / patency**
3. **Degree of TR**

Hypoplastic Left Heart

Key issues

Vast majority of surviving adult patients will have staged Norwood procedure and Fontan circulation. **Assessment is the same as for the Fontan circulation with additional caution:**

1. Arch function

- Stenoses or dilatations where the aorta has been augmented
- Stenosis of proximal head and neck vessels

2. Coronary artery supply

- Arises from the hypoplastic ascAo which has been anastomosed to the neo-aorta
- Careful assessment of the anastomosis

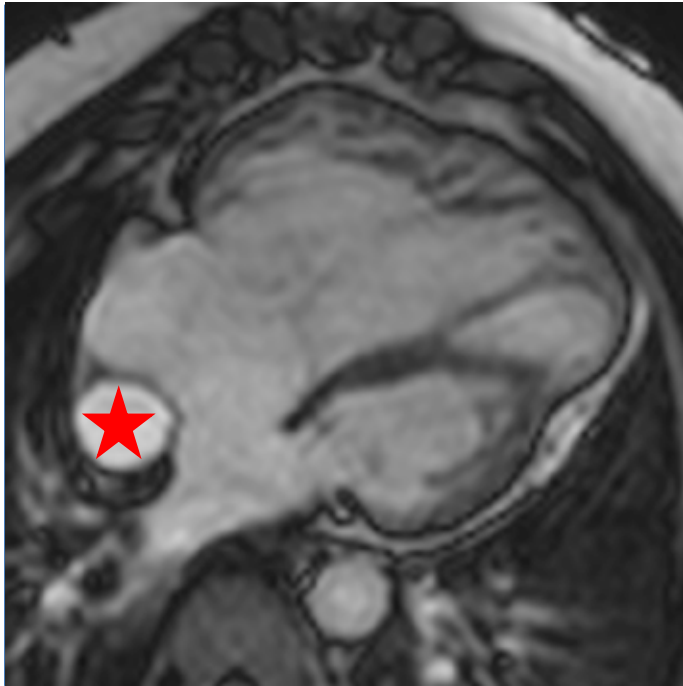
3. AV valve function

- The tricuspid valve is functioning as a systemic AV valve and there is a higher likelihood that it will become regurgitant

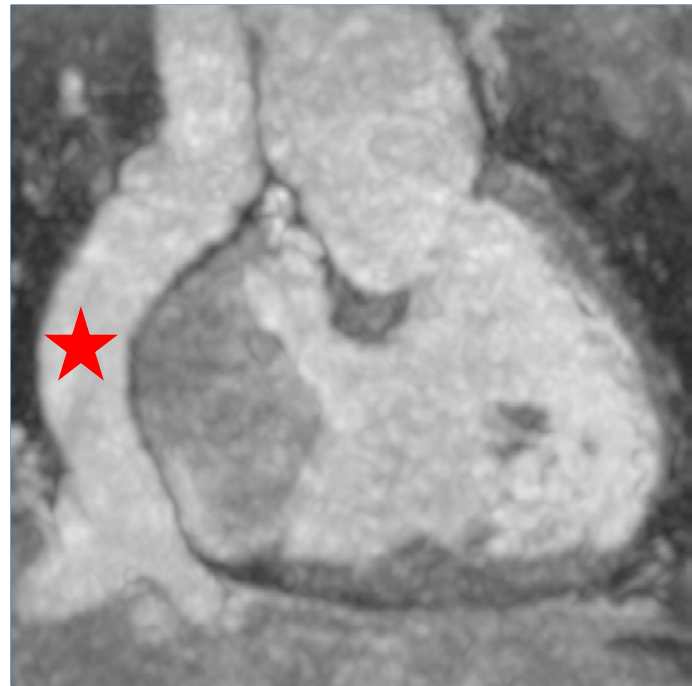
4. Follow-up

Given the number of surgical interventions and the presence of a systemic ventricle which is of right morphology, it is generally accepted that these patients will, on balance, do worse than a standard Fontan in the long term.

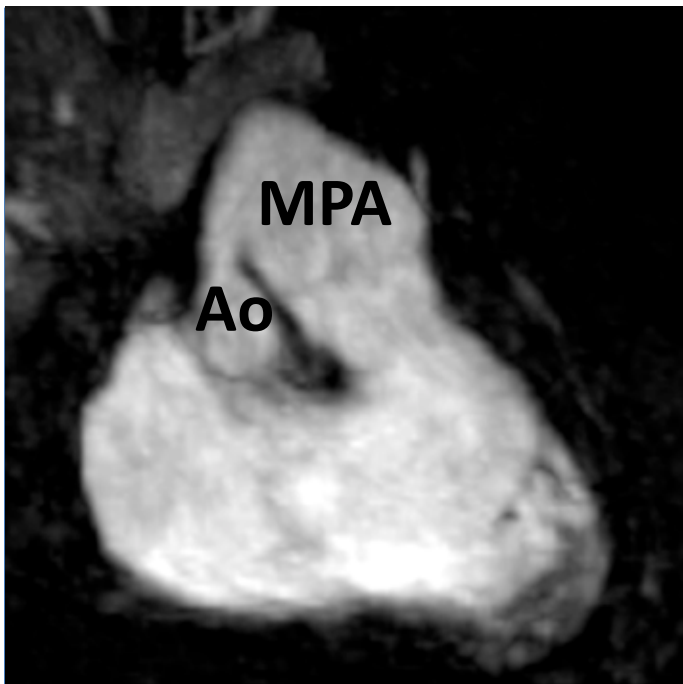
Hypoplastic Left Heart



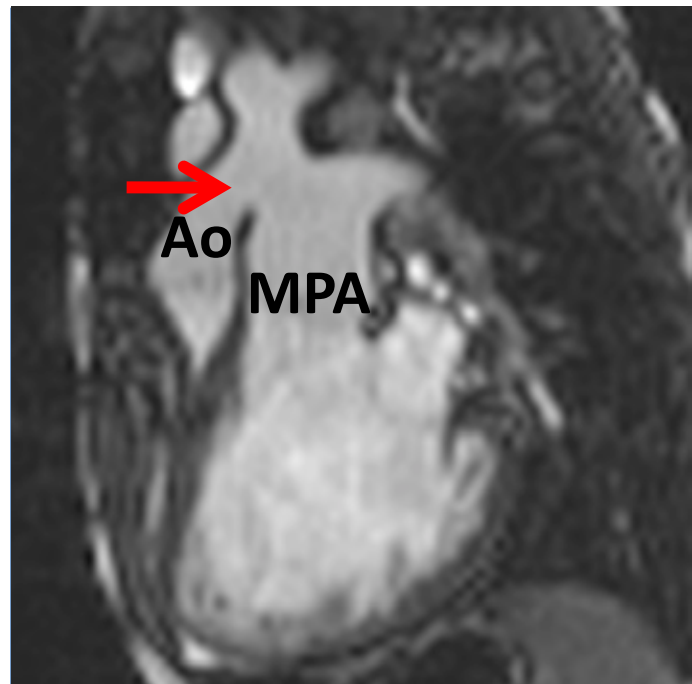
Hypoplastic left heart in diastole with an extracardiac Fontan



Extracardiac Fontan

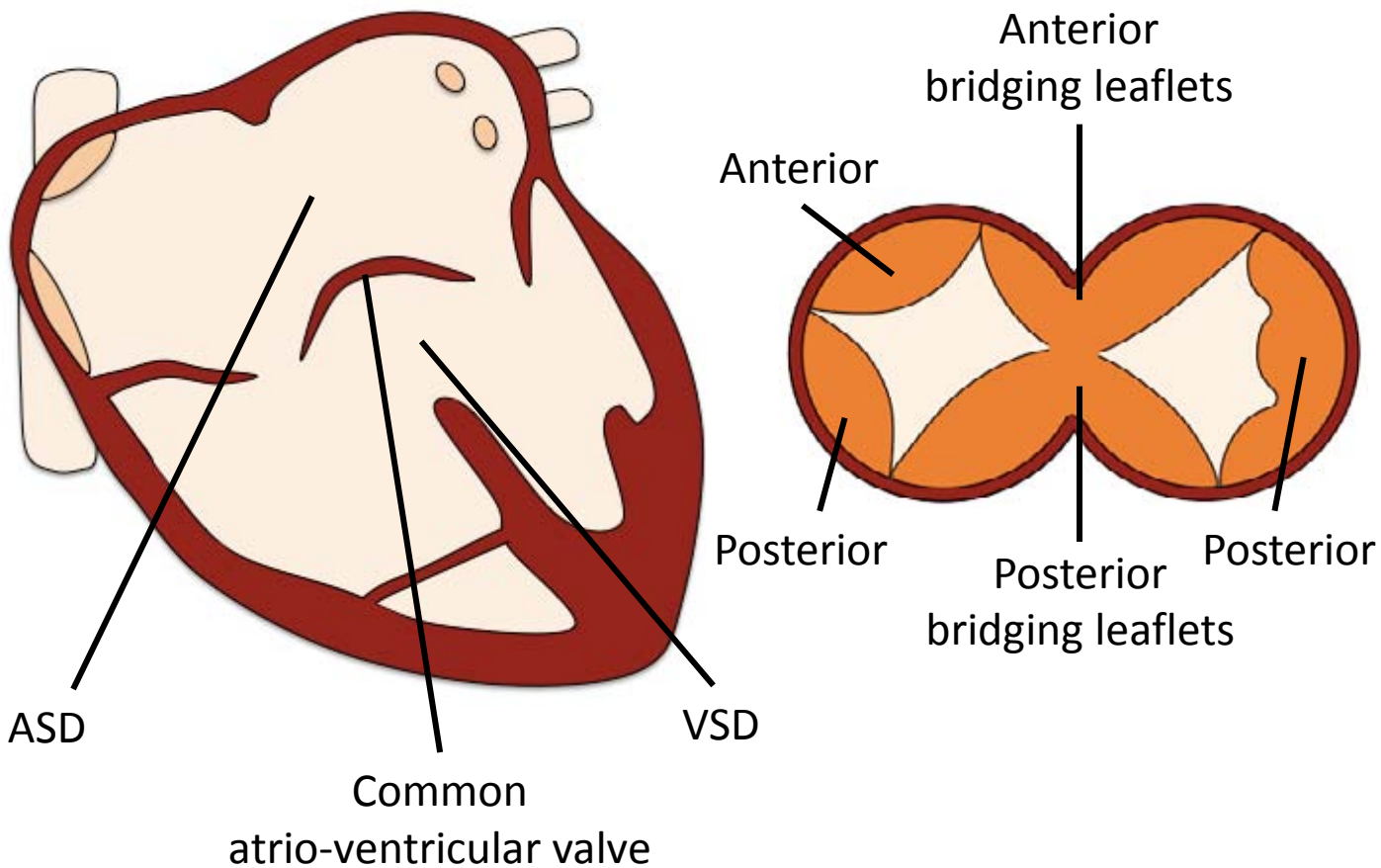


Aorto-pulmonary anastomoses



Aorto-pulmonary anastomoses

Atrioventricular Septal Defect



Pre-operative findings

- Defects of the primum atrial septum and inlet ventricular septum
- Presence of a common atrio-ventricular valve

Associated findings

- ASD / PDA
- Coarctation of the aorta
- Anomalous pulmonary venous return
- MV anomalies, e.g. parachute MV, double orifice MV
- ToF

Atrioventricular Septal Defect

Interventions

- PA banding as staged approach in pulmonary overcirculation
- Surgical closure with atrial and ventricular septal patch
- Atrio-ventricular valve repair
- PDA ligation

Post-operative complications

- Residual ASD and/or VSD
- Residual atrio-ventricular valve insufficiency or stenosis
- LVOT obstruction

Protocol

1. **Anatomy stacks**
2. **VLA, HLA, LV stack, RV stack**
3. **LVOT, RVOT**
4. **MPA flow**
5. **Ao flow**
6. **VSD flow**
7. **ASD flow**
8. **3D whole heart**

Report

1. **Size** (corrected for BSA) and **function**
 - LV: EDV, ESV, SV, EF, RWMA, note any LV dilation
 - RV: EDV, ESV, SV, EF, RWMA
2. **Presence and extent of ASD / VSD**
3. **Qp (MPA flow) : Qs (Ao flow)**
4. **Valve regurgitation or stenosis**

Atrioventricular Septal Defect

Key issues

1. **Spectrum of defects**

- Ranges from a primum ASD and cleft mitral valve to complete AVSD
- Partial AVSD: R and L AV valves have separate orifices; usually small VSD
- Complete AVSD: common AV valve and orifice; large VSD

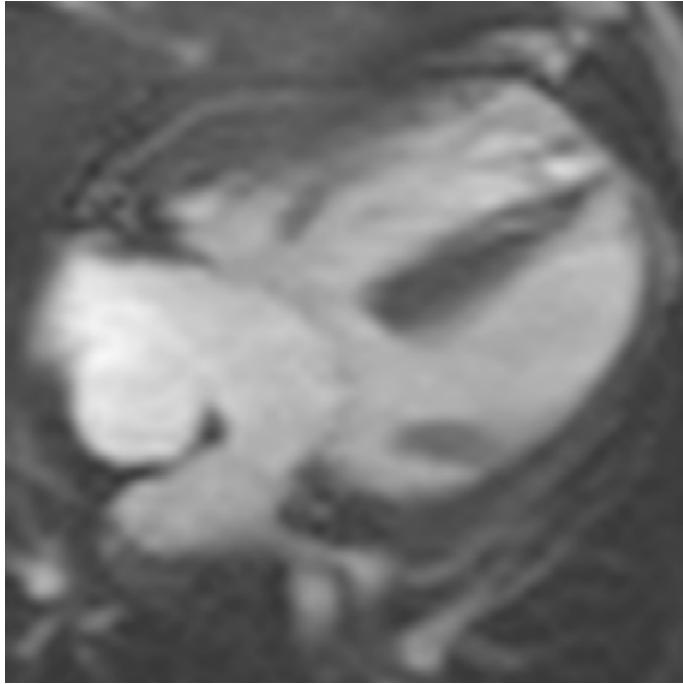
2. **Most common post-operative complications requiring reoperation**

- Severe MV regurgitation
- LVOT obstruction

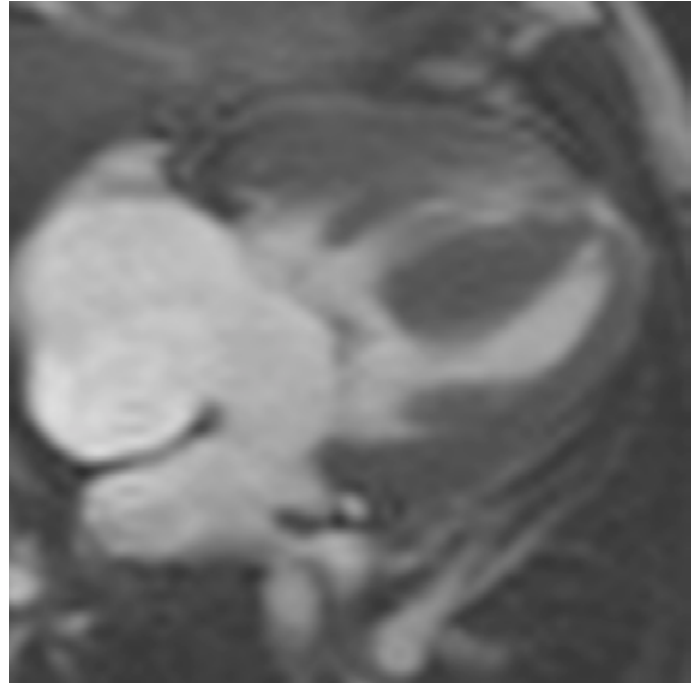
2. **Synonyms**

- Atrioventricular canal defect
- Endocardial cushion defect
- Absent crux

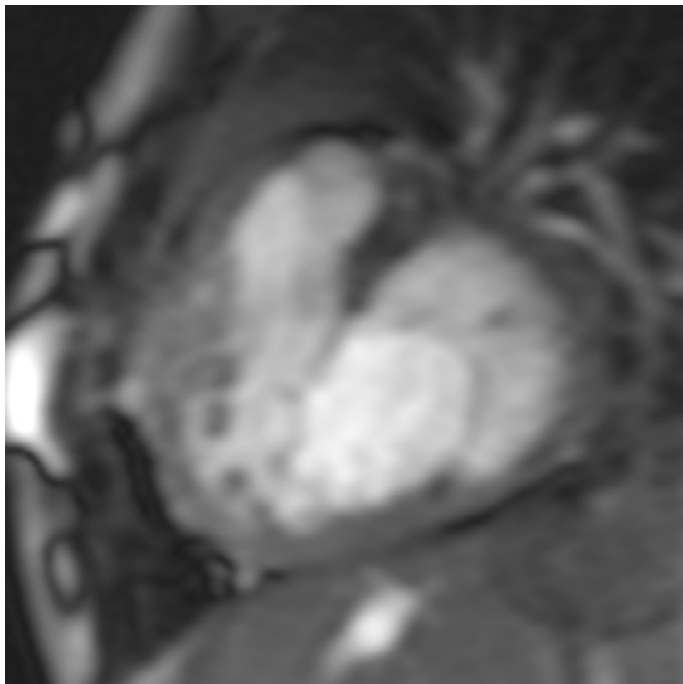
Atrioventricular Septal Defect



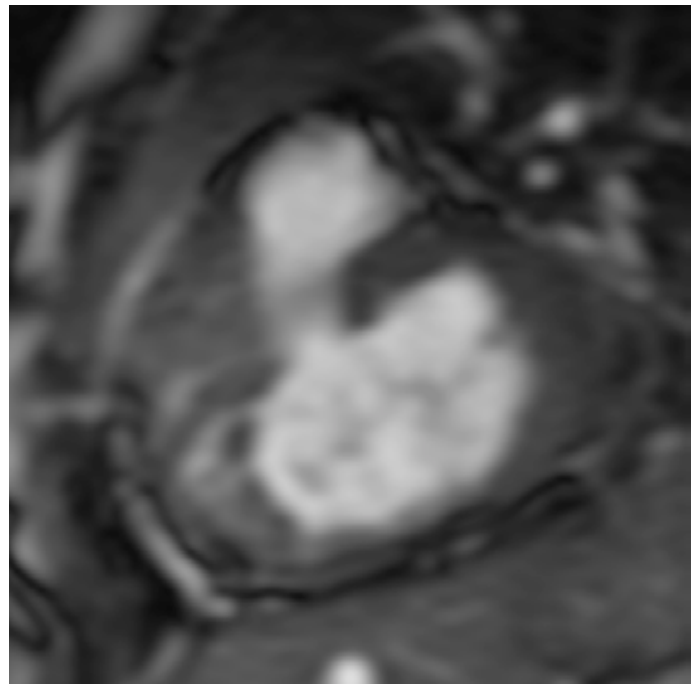
AVSD - diastole



AVSD - systole

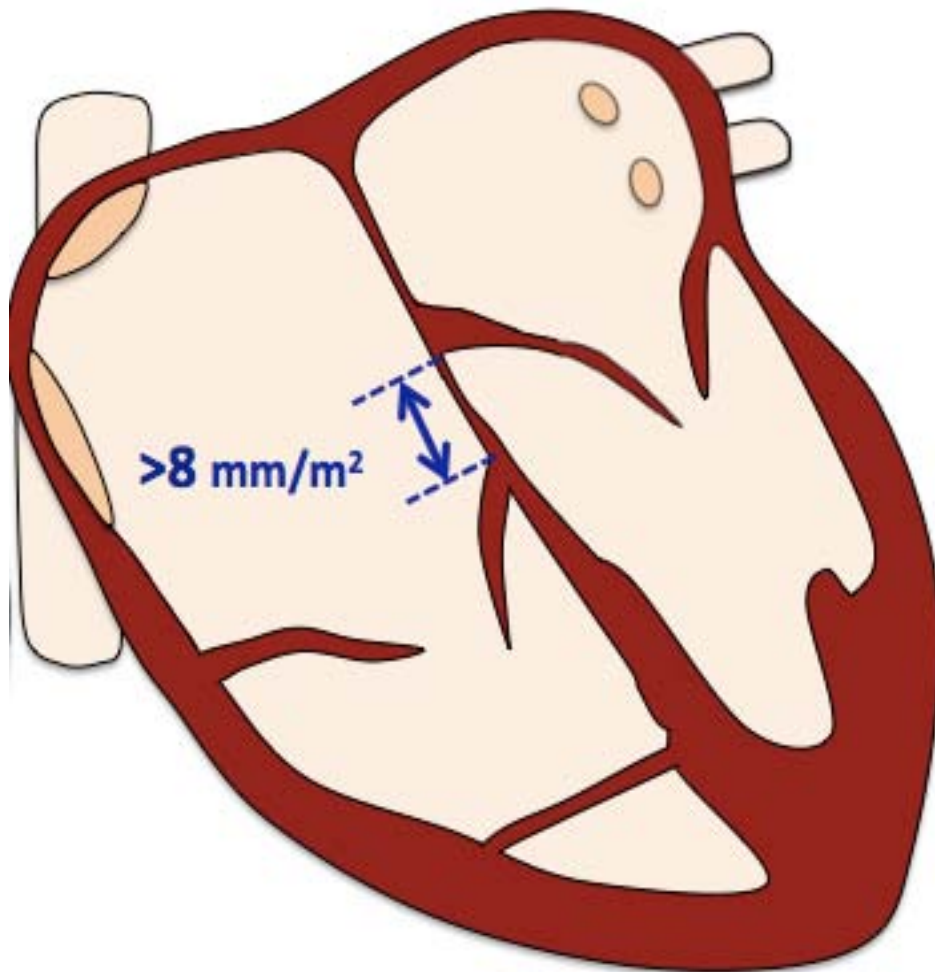


AV valve *en face*



AVSD – valve closure line

Ebstein Anomaly



Pre-operative findings

- Displacement of septal/posterior tricuspid leaflet towards the apex
- Atrialization and dilation of the RV inflow
- Varying degrees of TR

Associated abnormalities

- PFO / ASD ($>50\%$)
- VSD
- RVOT obstruction

Ebstein Anomaly

Interventions

- TV repair or replacement
- PFO/ASD closure
- Reduction atrioplasty
- Glenn or Fontan procedure, if severe

Post-operative complications

- Residual tricuspid regurgitation
- RV / (LV) failure

Protocol

1. **Anatomy stack**
2. **VLA, HLA, LV stack, RV stack**
3. **LVOT, RVOT**
4. **MPA flow**
5. **AoV flow**
6. **Atrial SA stack**
7. **TR flow**

Report

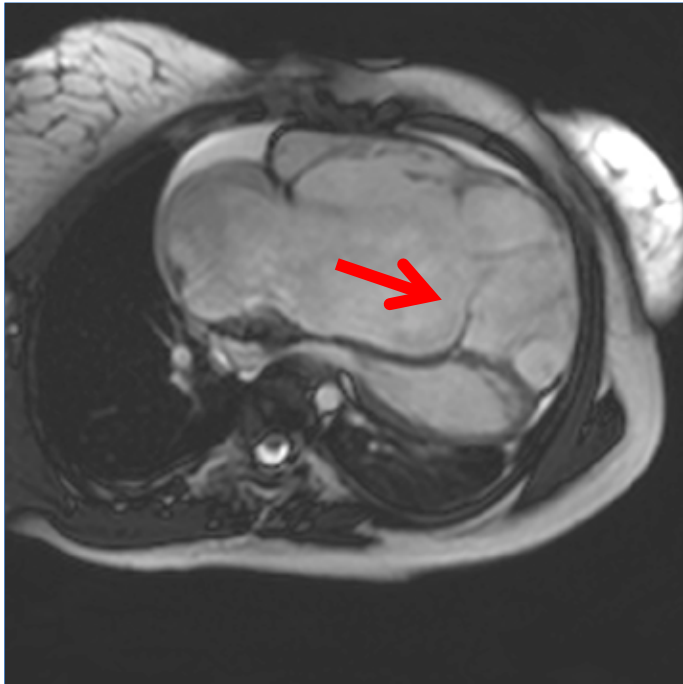
1. **Size** (corrected for BSA) and **function**
 - LV: EDV, ESV , SV, EF, RWMA
 - RV: EDV, ESV, SV, EF, RWMA
2. **Presence of PFO/ASD or VSD, Qp:Qs**
3. **Presence** (and severity) of **TR**
4. **Presence and severity of RVOT obstruction**

Ebstein Anomaly

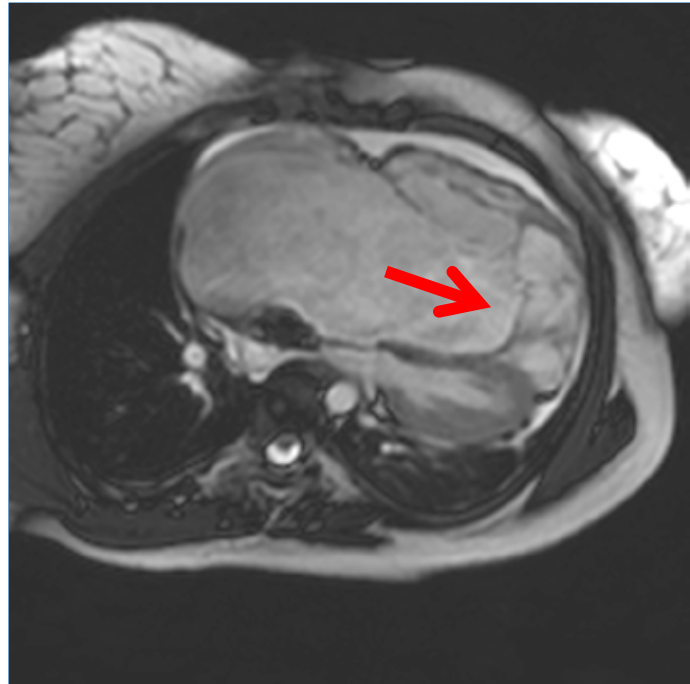
Key issues

1. The **clinical presentation** depends on the:
 - extent of tricuspid valve leaflet distortion
 - size of the right side of the heart
 - degree of TR
 - right atrial pressure
 - right-to-left shunt
 - RVOT obstruction
2. In patients with **chest pain consider myocardial ischemia** due to a compromised RCA by suture plication.
3. **Right ventricle**
 - **often dilated** despite severe apical displacement and rotation of the tricuspid valve
 - might compress the LV in diastole due to volume overload and therefore impair LV filling and **limit the cardiac output**

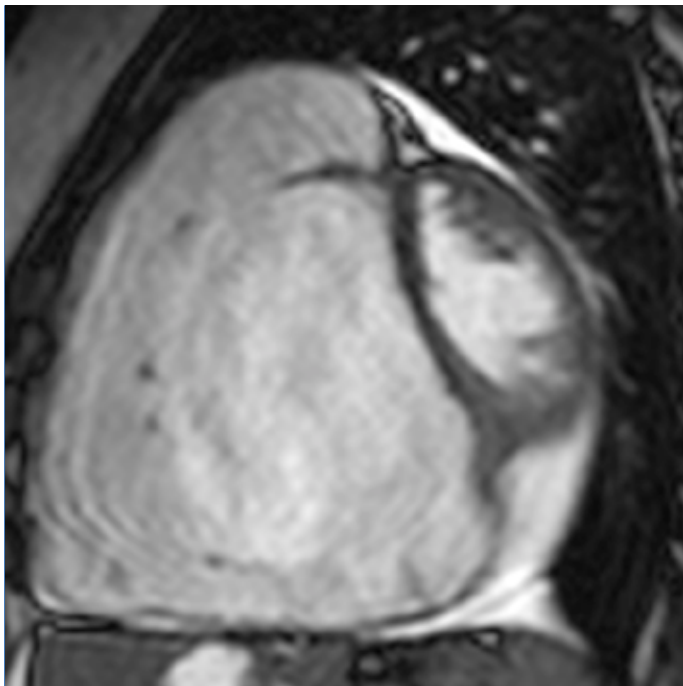
Ebstein Anomaly



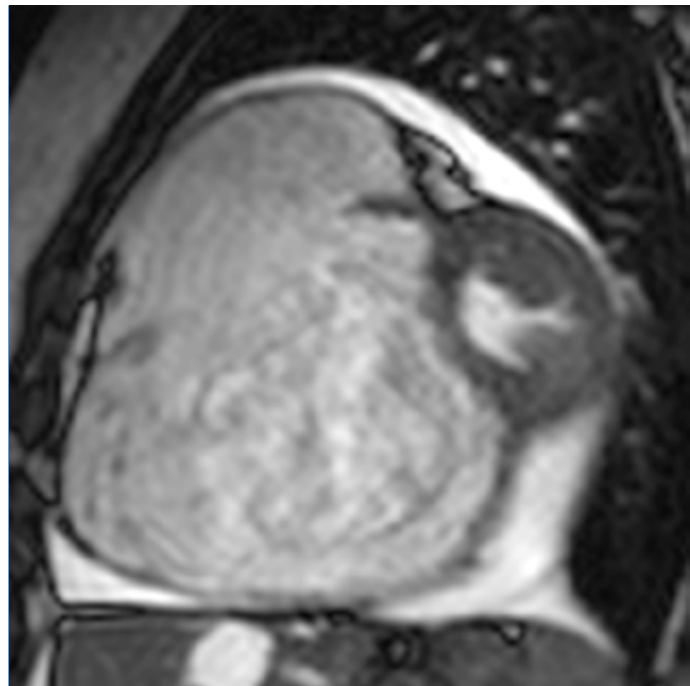
Severe displacement of the septal tricuspid leaflet (arrow) in diastole



Severe displacement of the septal tricuspid leaflet (arrow) in systole



RV volume overload with LV compression due to diastolic septal flattening, limiting cardiac output



RV volume overload in systole

Anomalous Coronary Arteries

Protocol

1. 3D whole heart

Report

1. Origin

- High / low / commissural
- From opposite coronary sinus
- Outside coronary sinuses
- Separate ostium for LAD and CX
- From pulmonary artery (ALCAPA and ARCAPA)

2. Anomalous course

- Inter-arterial (anterior)
- Retro-aortic (posterior)

3. Anomalies of intrinsic coronary arterial anatomy

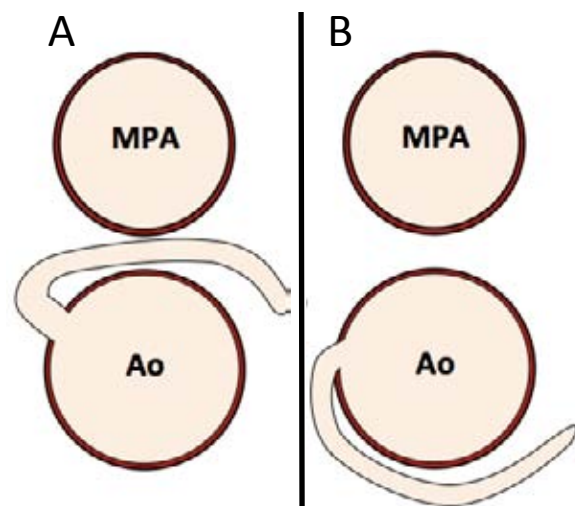
- Ectasia, aneurysm, hypoplasia
- Intramural coronary artery (muscular bridge)

4. Anomalies of coronary termination

5. Anomalous collateral vessels

6. Relation to other heart structures, if interventions planned

Inter-arterial course of a LCA arising from the right sinus (A) and **retro-aortic** course of a LCA arising from the right sinus (B)

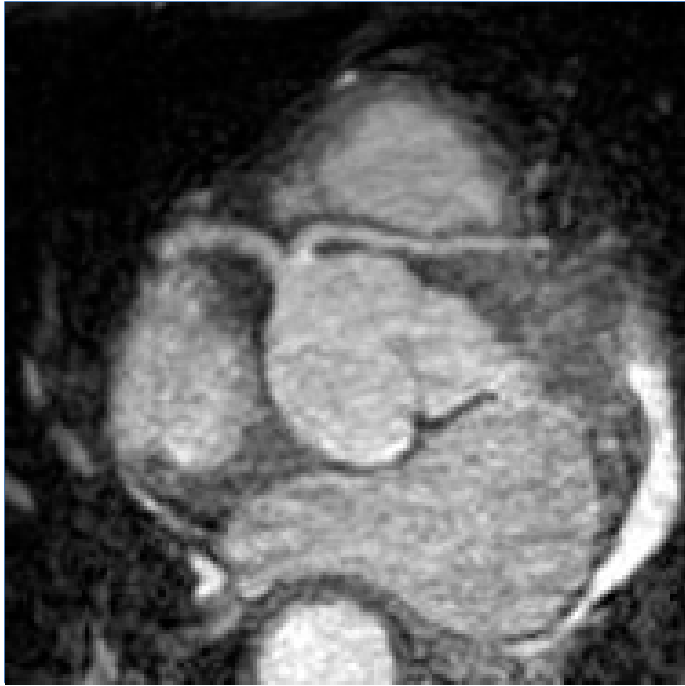

Anomalous Coronary Arteries

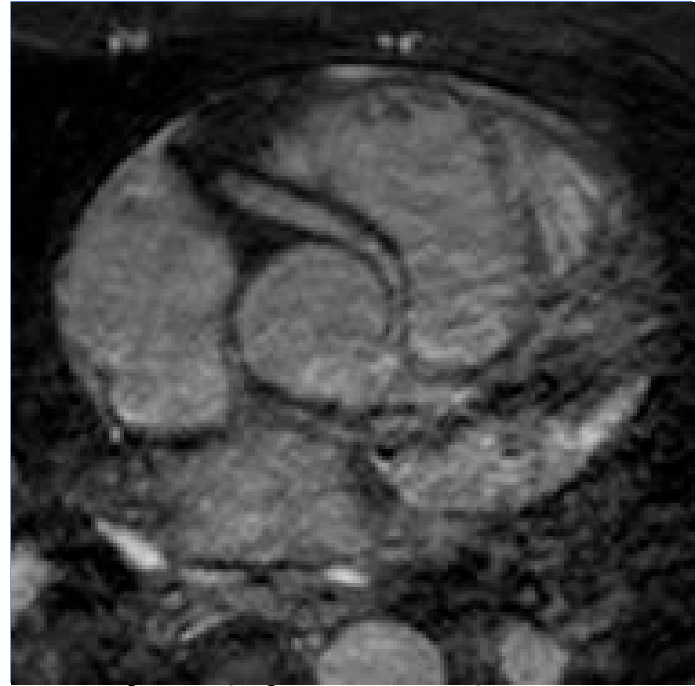
Key issues

1. **Malignant course:**
 - Inter-arterial course between aorta and RVOT, in particular **left coronary artery from right sinus**
2. **Possible causes of ischemia:**
 - Inter-arterial dynamic compression
 - Slit-like origin
 - Myocardial bridging
3. **Consider dobutamine stress** to demonstrate a regional wall motion abnormality (if inter-arterial course), although limited prognostic value
4. **Anomalous left (or right) coronary artery from the pulmonary artery (ALCAPA/ARCAPA)**
 - Usually associated with a regional wall motion abnormality, possible infarction, MR due to affected papillary muscles or ventricular dilatation
 - Re-implantation or bypass grafting may be required if no myocardial infarction
 - Can present in adulthood

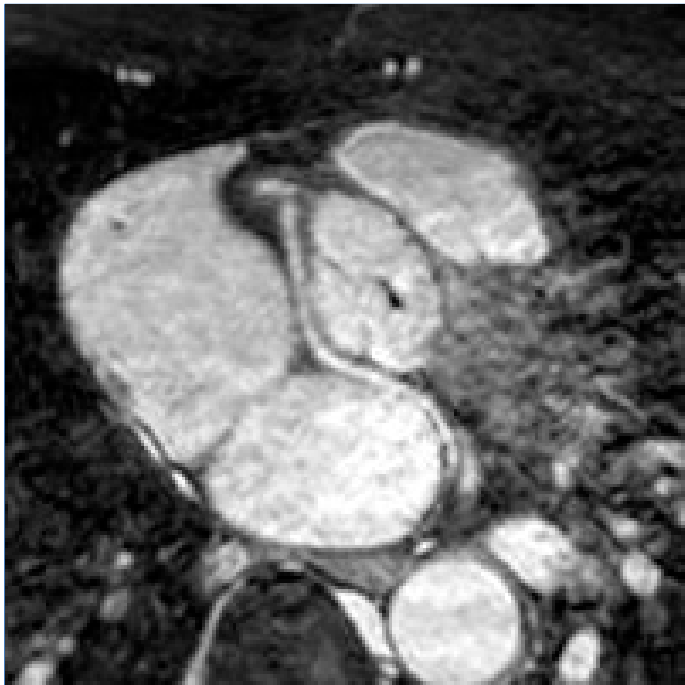Anomalous Coronary Arteries



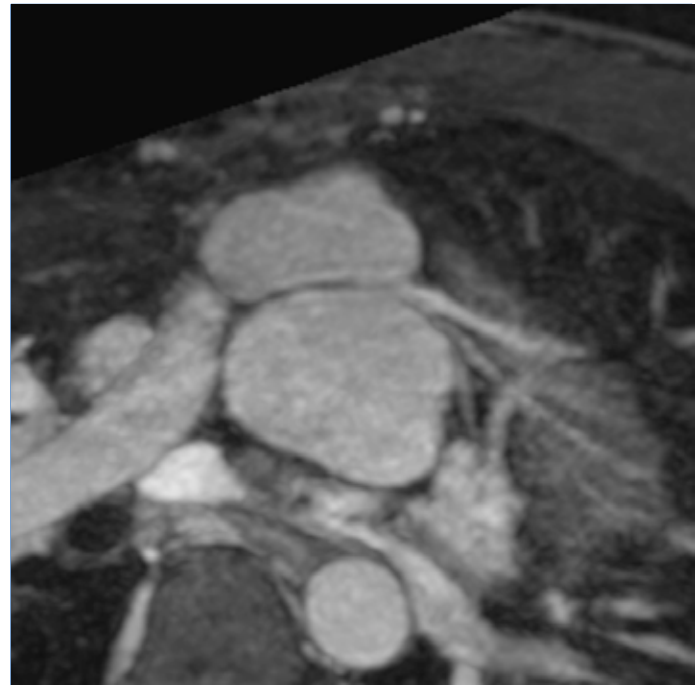
LCA from right sinus with inter-arterial course



RCA from left sinus with inter-arterial course



LCA from right sinus with retro-aortic course



Kinking of the proximal LCA after arterial switch procedure

References

- Fratz S, Chung T, Greil GF, Samyn MM, Taylor AM, Valsangiacomo Buechel ER, Yoo S-J, Powell AJ. Guidelines and protocols for cardiovascular magnetic resonance in children and adults with congenital heart disease: SCMR expert consensus group on congenital heart disease. *J Cardiovasc Magn Reson*. 2013;15:51.
- Kilner PJ, Geva T, Kaemmerer H, Trindade PT, Schwitter J, Webb GD. Recommendations for cardiovascular magnetic resonance in adults with congenital heart disease from the respective working groups of the European Society of Cardiology. *European Heart Journal*. 2010;31:794–805.
- Baumgartner H, Bonhoeffer P, De Groot NMS, de Haan F, Deanfield JE, Galiè N, Gatzoulis MA, Gohlke-Baerwolf C, Kaemmerer H, Kilner P, Meijboom F, Mulder BJM, Oechslin E, Oliver JM, Serraf A, Szatmari A, Thaulow E, Vouhe PR, Walma E, Task Force on the Management of Grown-up Congenital Heart Disease of the European Society of Cardiology (ESC), Association for European Paediatric Cardiology (AEPC), ESC Committee for Practice Guidelines (CPG). ESC Guidelines for the management of grown-up congenital heart disease (new version 2010). *European Heart Journal*. 2010. p. 2915–2957.
- Warnes CA, Williams RG, Bashore TM, Child JS, Connolly HM, Dearani JA, del Nido P, Fasules JW, Graham TP, Hijazi ZM, Hunt SA, King ME, Landzberg MJ, Miner PD, Radford MJ, Walsh EP, Webb GD. ACC/AHA 2008 Guidelines for the Management of Adults with Congenital Heart Disease: a report of the American College of Cardiology/American Heart Association Task Force on Practice Guidelines (writing committee to develop guidelines on the management of adults with congenital heart disease). *Circulation*. 2008. p. e714–e833 .

Abbreviations

3D	3 Dimensional	HR	Heart rate	PS	Pulmonary stenosis
2CH	2-chamber view - VLA	IVC	Inferior vena cava	pSA	Pseudo SA
3CH	3-chamber view	LA	Left atrium	pVLA	Pseudo VLA
4CH	4-chamber view - HLA	LAD	Left anterior descending artery	RA	Right atrium
Ao	Aorta	LCA	Left coronary artery	RCA	Right coronary artery
ALCAPA	Anomalous LCA from PA	LGE	Late gadolinium enhancement	RF	Regurgitation fraction
APC	Atrio-pulmonary collaterals	LP	Low pressure	RPA	Right pulmonary artery
AR	Aortic regurgitation	LPA	Left pulmonary artery	RV	Right ventricle
ARCAPA	Anomalous RCA from PA	LV	Left ventricle	RVOT	Right ventricular outflow tract
ASD	Atrial septum defect	LVEDP	LV end-diastolic pressure	RWMA	Regional wall motion abnormalities
AV	Aortic valve	LVOT	Left ventricular outflow tract	SA	Short axis
AVSD	Atrioventricular septal defect	MAPCA	Major aorto-pulmonary collateral artery	SNR	Signal-to-noise ratio
BT	Blalock Taussig	MBTS	Modified BT shunt	SV	Stroke volume
BSA	Body surface area	MIP	Maximum intensity projection	SVASD	Sinus venosus ASD
CBTS	Classic BT Shunt	MPA	Main pulmonary artery	SVC	Superior vena cava
CCTGA	Congenital corrected TGA	MR	Mitral regurgitation	TCPC	Total cavo-pulmonary connection
CMR	Cardiac magnetic resonance	MRA	Magnetic resonance angiography	TGA	Transposition of the great arteries
Cx	Circumflex artery	MV	Mitral valve	TOE	Transoesophageal echocardiography
DCRV	Double chamber right ventricle	NSA	Number of signal averages	ToF	Tetralogy of Fallot
Desc	Descending	PA	Pulmonary artery	TR	Tricuspid regurgitation
EDV	End-diastolic volume	PDA	Persistent ductus arteriosus	TV	Tricuspid valve
EF	Ejection fraction	PFO	Persistent foramen ovale	VENC	Velocity Encoding
ESV	End-systolic volume	pHLA	Pseudo HLA	VLA	Vertical long axis -2CH
FOV	Field of view	PI	Pulmonary incompetence		
HLA	Horizontal long axis – 4CH	PLE	Pulmonary lung embolism		
HP	High pressure	PR	Pulmonary regurgitation		

Visit www.cmr-guide.com

Bernhard A. Herzog

University Hospital Zurich
Cardiac Imaging, C NUK 40
Rämistrasse 100
CH-8901 Zürich
Switzerland

George Ballard

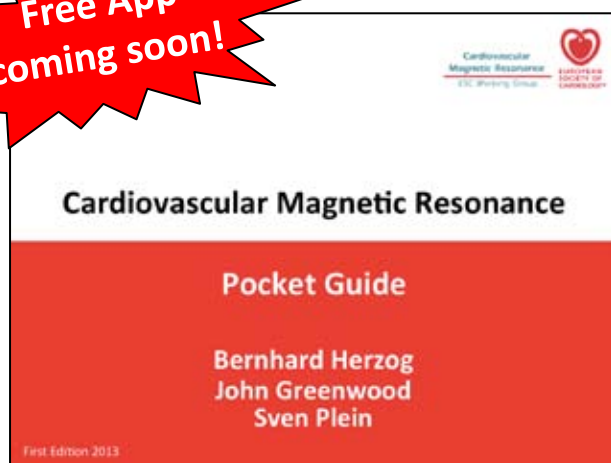John P. Greenwood

Ananth Kidambi

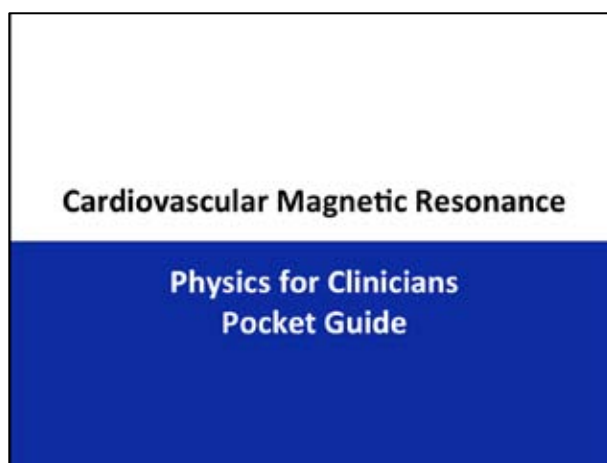
Sven Plein

Multidisciplinary Cardiovascular
Research Centre & The Division of
Cardiovascular and Diabetes
Research, Leeds Institute of
Genetics, Health & Therapeutics
University of Leeds
Leeds General Infirmary
Great George Street, Leeds
LS1 3EX, United Kingdom

**Free App
coming soon!**



Also available!



Coming soon!

**If you have any question, suggestion or feedback,
please contact:**

cmr@cmr-guide.com