

# Paranasal Sinus Osteomas: Surgical Outcomes at a Single Institution

Ahmet Erim Pamuk<sup>1</sup> , Büşra Kılıç<sup>2</sup> , Serdar Özer<sup>2</sup> , Ahmet Emre Süslü<sup>2</sup> , Metin Önerci<sup>2</sup> 

<sup>1</sup>Department of Otorhinolaryngology, Kırıkkale Yüksek İhtisas Hospital, Kırıkkale, Turkey

<sup>2</sup>Department of Otorhinolaryngology, Hacettepe University School of Medicine, Ankara, Turkey

## Abstract

**Objective:** Osteomas represent the most common benign tumors of the paranasal sinuses. In spite of being slow-growing and usually asymptomatic, osteomas can cause symptoms depending on their size, location, and extension to the adjacent anatomical structures. The aim of this study was to investigate and discuss the clinical features and surgical management of patients with paranasal sinus osteomas who were treated in one center.

**Material and Methods:** A retrospective chart review of 40 patients undergoing surgical treatment for paranasal sinus osteoma between January, 2005 and December, 2019 was carried out. Patients' demographic characteristics, presenting symptoms, osteoma size and location, imaging findings, and surgical outcomes were analyzed.

**Results:** The mean duration of follow-up was 31 months (range, 6-122 months). The most frequently affected site was the frontal sinus (55%), followed by the frontoethmoid region (27.5%) and the ethmoid sinus (7.5%). Headache was found to be associated with frontal sinus osteomas ( $p=0.014$ ). Besides, extra-sinusal extension was observed in 10 (25%) patients. While 20 (50%) patients were treated with a purely endonasal endoscopic technique, an external technique was most commonly used for frontal sinus osteomas ( $p=0.035$ ). There were no major surgical complications in 33 patients (85%); complete resection, however, could not be successfully achieved in 6 patients (15% residual tumor rate), 2 of whom subsequently underwent revision surgery (5% revision rate).

**Conclusion:** Paranasal sinus osteomas are benign, slow-growing, and usually asymptomatic lesions with potentially important complications. That being said, surgical removal remains the treatment of choice for symptomatic or rapidly growing osteomas of the paranasal sinuses.

**Keywords:** Osteoma, paranasal sinus, benign tumor, endoscopic surgery, external approach, computed tomography

**Cite this article as:** Pamuk AE, Kılıç B, Özer S, Süslü AE, Önerci M. Paranasal Sinus Osteomas: Surgical Outcomes at a Single Institution. Eur J Rhinol Allergy 2020; 3(1): 4-9.

**Address for Correspondence:** Ahmet Erim Pamuk

**E-mail:** dr\_erim@hotmail.com

**Received:** 08.01.2020

**Accepted:** 24.03.2020

**DOI:** 10.5152/ejra.2020.253

Copyright@Author(s) - Available online at [www.eurjrhinol.org](http://www.eurjrhinol.org)

Content of this journal is licensed under a Creative Commons Attribution-NonCommercial 4.0 International License.



## INTRODUCTION

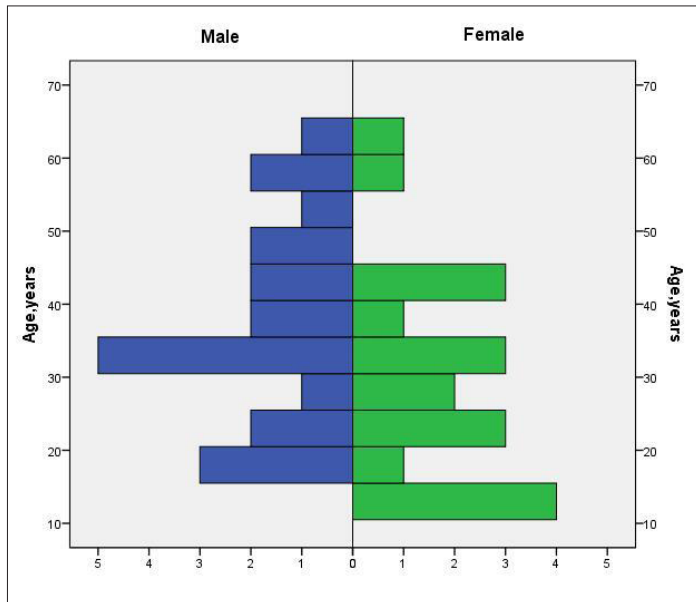
Representing the most common benign tumors of the paranasal sinuses, osteomas are slow-growing and asymptomatic osteogenic tumors usually detected incidentally on 3% of computed tomography (CT) scans (1, 2). They have a male predominance (1.5:1) and a mean age of diagnosis around the 3rd and 4th decades of life (3). There is an ongoing debate in the literature over the etiology of osteomas, with theories relating to developmental, traumatic, and infectious causes having been proposed (3, 4). Paranasal sinus osteomas most commonly arise from the frontal sinus, followed in descending order of frequency by the ethmoid, maxillary, and sphenoid sinuses (5).

Depending on their size, location, and extension to the adjacent anatomical structures, osteomas—which are usually asymptomatic—can produce various symptoms, with facial pain and headache with or without concomitant sinusitis being the most frequent ones (6). Moreover, intraorbital extension may lead to diplopia, proptosis, and vision impairment, whereas skull base erosion may cause meningitis secondary to mucocoeles, cerebrospinal fluid leakage, cerebral abscess formation, or tension pneumocephalus (7).

Thin-slice CT is the imaging method of choice (6, 7), as it allows for the precise localization of osteomas as well as any possible extra-sinusal extension to the surrounding structures. Differential diagnosis includes other benign fibro-osseous lesions such as ossifying fibroma, fibrous dysplasia, and osteoblastoma (8). Asymptomatic cases should be followed up on a regular basis. However, surgery is the treatment of choice for symptomatic patients or patients with rapidly growing tumors (1). Herein, we report the clinical features and surgical outcomes of 40 patients with paranasal sinus osteomas who were surgically treated at a single institution between 2005 and 2019.

## MATERIAL AND METHODS

The medical records of 40 patients undergoing surgery for histologically confirmed paranasal sinus osteoma at the Department of Otorhinolaryngology, Hacettepe University, Ankara, Turkey between January, 2005 and December, 2019, were retrospectively reviewed. Data were obtained on patient demographics, osteoma size and location, clinical presentation,



**Figure 1.** Age-gender distribution of the study population

**Table 1.** Patient characteristics and clinical features of the study cohort

Demographic and Clinical Data	Value
Mean age, y	34.3±14.1
Gender	
Male	21
Female	19
Osteoma size, mm	23.85 mm (range 4-55 mm)
Extrasinusual extensions	
Lamina papyracea	2
Orbita	6
Intracranial	2
Symptoms	
Headache	24
Nasal obstruction	13
Proptosis	8
Vision impairment	4
Facial pain	3
Facial swelling	2
Surgical technique	
Endoscopic	20
External	12
Combined	8

surgical approach, follow-up duration, intraoperative complications, and recurrence status. The study protocol was approved by the Hacettepe University Ethics Committee (GO 18/980-31).

All operations were performed under general anesthesia. Surgical approaches used for the resection of the osteomas were classified as endoscopic, external, and combined procedures. Angled endoscopes, cold instruments, and both diamond and standard burs were used in endonasal endoscopic surgery. It's worth mentioning that the intraoperative navigation system has been available in our clinic and is being used in selected cases. External approaches comprised osteoplastic flap, frontal sinus trephination via medial eyebrow incision, and Caldwell-Luc. Combined procedures took advantage of both endonasal endoscopic surgery and external techniques, depending on the location and size of the tumor. Although all of the subjects received surgical treatment at our hospital, 2 of them had undergone surgery at another center before being referred to our clinic due to recurrence. Patients who underwent revision surgery after initial surgery at our institution were classified as recurrent cases. With regard to tumor location, tumors confined to a single sinus were classified under the same name as the involved sinus (i.e. frontal, ethmoid), and tumors invading multiple sinuses were grouped separately (i.e. frontoethmoid, sphenothmoid). Control CT was performed in patients with unresolved complaints or intraoperative incomplete resection.

Statistical analysis was performed using IBM Statistical Package for the Social Sciences software version 23.0 (IBM SPSS Corp.; Armonk, NY, USA) and Microsoft Excel spreadsheet software (Redmond, Washington, USA). After descriptive analysis was carried out, categorical variables were compared using Pearson's chi-square test and Fisher's exact test for small-sample data ( $n < 5$ ). The Shapiro-Wilk test and normal distribution parameters were employed to examine the normality of data distribution. A  $p < 0.05$  was considered statistically significant.

## RESULTS

### Patients' Characteristics

A total of 40 patients surgically treated for osteoma were enrolled in the study. Of these cases, 21 were male and 19 were female, with the male-to-female ratio being 1.1:1. The mean age ( $\pm$ standard deviation) was 34.3±14.1 years. Age-gender distribution of the study population is shown in Figure 1. In addition, Gardner's syndrome was found in 1 patient with multiple craniofacial osteomas. Table 1 shows baseline features of the patients.

### Clinical Presentation and Radiological Imaging

Routine ENT examination and fiberoptic nasopharyngoscopy were performed in all cases. All the patients were symptomatic and underwent preoperative CT. The most common symptom was headache in 24 patients (60%), followed by nasal obstruction in 13 patients (32%), proptosis in 8 patients (20%), vision impairment in 4 patients (10%), facial pain in 3 patients (7.5%), and facial swelling in 2 patients (5%). Headache was found to be significantly associated with osteomas localized in the frontal sinus ( $p=0.014$ ). Furthermore, 11 patients (27.5%) presented with more than one symptom. While all the patients with ethmoid osteoma suffered from nasal obstruction ( $p=0.028$ ), facial pain appeared to be the most common symptom in those with maxillary sinus osteoma ( $p=0.003$ ). Table 2 shows symptoms observed with osteomas located in different regions.

Preoperative CT results appeared otherwise normal in 24 patients (60%), whereas 16 patients showed opacification of at least one sinus, of whom 5 were diagnosed with nasal polyposis and 11 with sinusitis.

**Table 2.** Relationship between the symptoms and the localization of the osteomas

	Headache	p	Nasal obstruction	p	Proptosis	p	Facial pain	p	Facial swelling	p	Vision Impairment	p
Frontal No.(%)	17/22 (77.2)	0.014*	6/22 (27.2)	0.43	3/22 (13.6)	0.42	0/22 (0)	0.08	1/22 (4.5)	0.99	1/22 (4.5)	0.31
Fronto Ethmoid No.(%)	6/11 (54.5)	0.48	3/11 (27.2)	0.99	4/11 (36.3)	0.09	0/11 (0)	0.54	1/11 (9)	0.47	2/11 (18.1)	0.30
Ethmoid No.(%)	1/3 (33.3)	0.55	3/3 (100)	0.028*	0/3 (0)	0.99	0/3 (0)	0.99	0/3 (0)	0.99	0/3 (0)	0.99
Spheno Ethmoid No.(%)	0/1 (0)	0.99	0/1 (0)	0.99	1/1 (100)	0.20	0/1 (0)	0.99	0/1 (0)	0.99	1/1 (100)	0.10
Maxillary No.(%)	0/2 (0)	0.15	1/2 (50)	0.99	0/2 (0)	0.99	2/2 (100)	.003*	0/2 (0)	0.99	0/2 (0)	0.99

The patient with multiple osteomas was not included into the table due to the possible confounding effect of osteomas in more than one sinus.

\* Values in bold indicate statistically significant

**Table 3.** Relationship between the surgical technique and the localization of the osteoma

	Endoscopic	p	External	p	Combined	p
Frontal, No. (%)	8/22 (36.3)	0.056	10/22 (45.4)	0.035*	4/22 (18.1)	0.99
Frontoethmoid, No. (%)	7/11 (63.6)	0.48	2/11 (18.1)	0.45	2/11 (18.1)	0.99
Ethmoid, No. (%)	3/3 (100)	0.23	0/3 (0)	0.54	0/3 (0)	0.99
Sphenoethmoid, No. (%)	1/1 (100)	0.99	0/1 (0)	0.99	0/1 (0)	0.99
Maxillary, No. (%)	0/2 (0)	0.48	0/2 (0)	0.99	2/2 (100)	0.035*

The patient with multiple osteomas was not included into the table due to the possible confounding effect of osteomas in more than one sinus.

\*Values in bold indicate statistically significant

### Tumor Size and Location

The mean tumor size was 23.85 mm (range, 4-55 mm). Of the observed tumors, 5 (12.5%) were smaller than 10 mm and 15 (37.5%) measured larger than 30 mm in size. There was no significant difference regarding complication rates and surgical approach choice between giant (>3cm) and small (<1cm) tumors (complications, p=0.39; endoscopic, p=0.1; external, p=0.07; combined, p=0.99)

Osteomas affected different locations which were classified as follows: the frontal sinus (n=22, 55%); the ethmoid sinus (n=3, 7.5%); the frontoethmoid region (n=11, 27.5%); the maxillary sinus (n=2, 5%); the sphenoethmoid region (n=1, 2.5%); and Gardner's syndrome with multiple osteomas located bilaterally in the frontal, ethmoid, and maxillary sinuses (n=1, 2.5%). Besides, they occurred on the right side in 20 cases and on the left side in 19 subjects.

Osteomas were limited to the paranasal sinuses in 30 patients (75%), whereas 6 cases (15%) had intraorbital extension, 2 (5%) subjects exhibited skull base erosion and intracranial extension, and 2 patients (5%) displayed lamina papyracea invasion without any orbital extension (Figure 2). One of the 2 patients with intracranial extension had undergone surgery for a 55-mm frontoethmoid tumor before the residual tumor progression to a sphenoethmoid tumor resulted in skull base erosion and intracranial extension; in the other one, a 48-mm sphenoethmoid tumor had led to intracranial extension and dural tear.

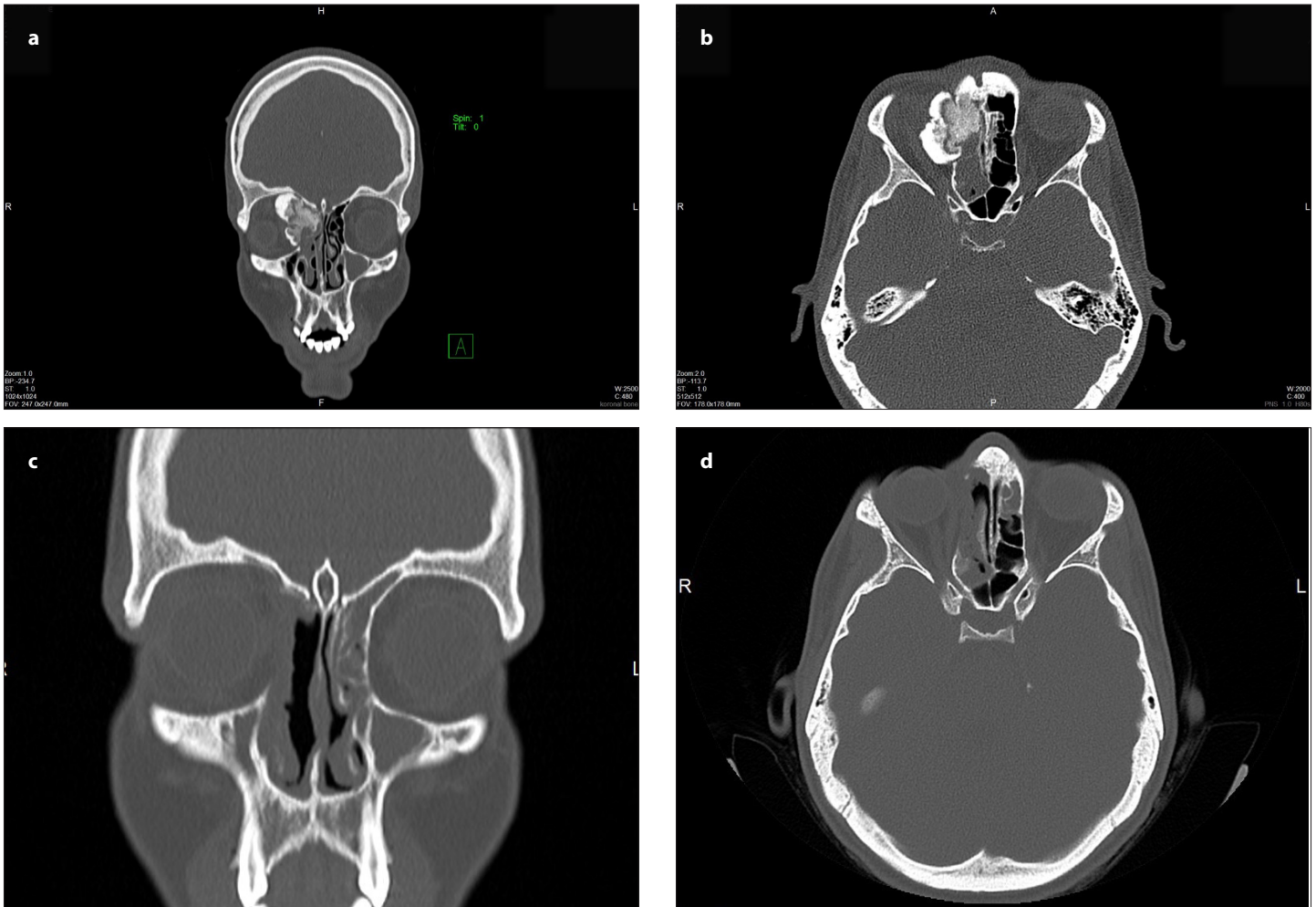
### Surgical Approach

A purely endoscopic endonasal procedure was conducted in 20 patients (50%); external approaches were performed in 12 (30%) patients (9 osteoplastic flap, and 3 frontal trephination with medial eyebrow incision); and combined techniques were employed in 8 (20%) patients (2 Caldwell-Luc + endoscopic surgery, 4 frontal trephination + endoscopic surgery, and 2 osteoplastic flap + endoscopic surgery). External approaches were the most commonly used techniques in frontal sinus osteomas (p=0.035). Table 3 depicts the preferred surgical approach with regard to the location of osteomas.

### Complications, Follow-up, and Residue/Recurrence

The mean duration of follow-up was 31 months (range, 6-122 months). While 33 patients (85%) were operated on without any complications, 6 subjects developed an intraoperative cerebrospinal fluid (CSF) fistula, which was repaired endoscopically during the operation. Also, a patient with a giant (55 mm) osteoma in the frontoethmoid region with intraorbital extension experienced incomplete resection, oculomotor nerve palsy, and blindness after the surgery. In this case, ophthalmologists at the Department of Ophthalmology enucleated the eyeball as a result of phthisis bulbi and subsequently placed an ocular prosthesis. Furthermore, 7 years after the initial operation, revision surgery via an endoscopic approach was performed due to a symptomatic recurrence of the disease in the sphenoethmoid region. Complete resection could be achieved, and an intraoperative CSF fistula which occurred during the revision operation was repaired.

Complete resection could not be successfully accomplished in 6 patients (15% residual tumor rate), 2 of whom underwent revision surgery (5% revision rate). The other 4 patients with residual tumor remained asymptomatic for at least 6 months of follow-up, so revision surgery was not planned.



**Figure 2. a-d.** CT scans show coronal (a) and axial (b) view of a patient suffering frontoethmoid osteoma with intraorbital extension presenting with proptosis, vision impairment, and facial swelling. Postoperative scans after endoscopic resection show no sign of residual tumor (c, d).

## DISCUSSION

Paranasal sinus osteomas are slow-growing osteogenic tumors of the paranasal sinuses which usually remain asymptomatic before reaching a certain size or involving adjacent structures. In the present study, headache was found to be the most common symptom with an incidence rate of 60%, which was comparable to the variable rates (52-100%) reported in previous studies (7). Also, headache was present in 77% of the patients with lesions located in the frontal sinus ( $p=0.014$ ). In a study by Arslan et al., the rate of frontal headache was reported to be 100% in frontal sinus osteomas (9). However, Buyuklu et al. (6) found that headache was significantly lower in osteomas located in the frontal sinus. They argued that the larger size of the frontal sinus provided the tumor with enough space to grow without compressing the surrounding mucosa.

There are controversial reports regarding gender predominance in paranasal sinus osteomas. Although the majority of studies have noted a predominance of male patients, some have reported the opposite (3, 5, 10). The genders were almost equally represented in this study with a slight preponderance of males (1.1:1), which was not deemed remarkable enough to make any definite judgment.

The third and fourth decades of life have been reported in the literature as the most common ages of diagnosis (1, 5, 6). Here, the mean age was 34.3

years, which was similar to the reports in the literature. It is known that osteomas grow slowly but continuously and that their growth is greatest during adolescence with maximal skeletal growth (3). However, the onset of symptoms vary from case to case depending on the location of the tumor. In the current study, for instance, 6 pediatric patients were diagnosed with osteoma and then treated surgically, one of whom received second surgery in adulthood for recurrent osteoma.

As shown in a large number of studies, the frontal sinus is the most commonly involved site, followed by the ethmoid, maxillary, and sphenoid sinuses in a descending order of frequency (10). The high rates of osteomas observed in the frontal and ethmoid sinuses are said to be rooted in endochondral and intramembranous ossification processes in these regions (2). Some reports have classified frontoethmoid region osteomas as a distinct entity, as we did in our study; in contrast, some have analyzed CT scans to determine their origin/base and have categorized them accordingly (8, 10). Our results were consistent with those announced by Castelnovo et al., who found that the frontoethmoid region was the second most frequently involved site following the frontal sinus (8).

Categorized as a rare and unique pathological condition, Gardner's syndrome is an autosomal-dominant genetic disorder characterized by multiple osteomas, pigmented skin lesions, intestinal polyps, and soft tissue tumors. Multiple craniofacial osteomas should always raise suspicion



about Gardner's syndrome. Early diagnosis and treatment are crucial because the clonic polyps have a high chance of malignant transformation. Thus, lower gastrointestinal endoscopy, DNA testing, and barium enema imaging should be carried out. One of the patients enrolled in our study, who had multiple osteomas in the paranasal sinuses and mandible, was diagnosed with Gardner's syndrome and has been followed up for 8 months now.

CT scan is the primary imaging tool for the diagnosis of osteomas, which appear as masses with bone density and a well-defined border (11). Thin-slice paranasal CT is helpful to determine the precise location, size, and borders of the mass. Magnetic resonance imaging (MRI) may prove useful in cases with mucocèles and extension to the intraorbital or intracranial region (7). In our study, CT was the primary imaging modality of choice for establishing the diagnosis of osteoma, with an additional MRI performed in cases with complications.

Ossifying fibroma and fibrous dysplasia are other benign fibro-osseous lesions which should be considered in the differential diagnosis of osteomas. These lesions are generally less well-defined. Ossifying fibroma has sharply defined outside margins and exhibits a mixture of bone density and soft tissues with thick bony walls in addition to intracortical osteolysis with a characteristic sclerotic band (osteoblastic rimming). Fibrous dysplasia has poorly defined borders and a characteristic "ground-glass" or "salt and pepper" sign (12).

The management of asymptomatic patients is a matter of debate in the literature. Most authors agree that asymptomatic and small osteomas, due to their slow growth rate, should be followed up with clinical and radiological examinations (2, 3, 13). They believe surgery should be performed in patients with rapidly growing osteomas, intracranial or intraorbital extension, and tumors in the sphenoid sinus (8, 14). On the other hand, some argue that smaller osteomas, which can be more easily removed with lower complication rates, might become symptomatic—due to their progressive growth pattern—later in the patient's life (15). All of our patients had tumor-related symptoms and therefore underwent surgery.

Surgical resection is believed to be the gold standard for symptomatic osteomas (10). Various factors including tumor location, extension to surrounding structures, and surgeon's experience and preference determine the surgical approach. Surgical treatment options include endoscopic, external, and combined techniques. Endoscopic surgery is associated with enhanced tumor visualization, less morbidity and scar formation, and shorter hospital stays. External approaches consist of osteoplastic flap, frontal trephine, and lateral rhinotomy. Despite having disadvantages such as lower patient comfort and frontal pain/numbness, external approaches are considered standard procedures—especially for frontal and giant tumors—due to providing better and safer exposure of the tumor (6). Lesions greater than 3 cm or >100 g are considered as "giant tumors" (16). In our study, external approaches were significantly higher in frontal osteomas. Nonetheless, there was no difference between "giant" and normal tumors in terms of surgical approaches and complication rates. Castelnuovo has also suggested that osteoma size does not have any effect on the surgical technique since cavitation techniques with drills make the endoscopic resection possible in the case of large frontal and frontoethmoid osteomas (8). Our treatment of choice was the endoscopic technique for purely ethmoidal osteomas, which is in line with the literature (17). Indications of combined techniques rather than an individual external procedure include concurrent recurrent sinusitis, sinonasal polyposis, or failure of the initial attempt for a purely endoscopic approach (10). Here,

2 cases with a laterally located maxillary sinus osteoma were treated with a combined Caldwell-Luc for better visualization and manipulation of the tumor. Moreover, 4 patients with frontal and frontoethmoid osteomas underwent combined endoscopic + supraciliary frontal trephine because of narrow frontal recess.

Even though true recurrences after surgery are rare, the regrowth of residual tumor tissues following incomplete resection may occur, necessitating revision surgery. In the present study, 2 patients with residual tumor growth and unresolved symptoms received second surgery and were followed up, during which period their tumor-free status was maintained. Besides, 6 patients suffered intraoperative CSF leakage and thus underwent immediate endoscopic repair with fascia lata grafts.

One of the limitations of this study had to do with the small number of patients and the fact that only a single center was studied. This research was further limited by the heterogeneity of patient groups as well as the retrospective design. Additional research with larger patient populations is required to provide a thorough analysis of the surgical outcomes.

## CONCLUSION

Paranasal sinus osteomas are benign, slow-growing, and usually asymptomatic lesions with potentially important complications. Symptomatic and rapidly growing tumors necessitate treatment. Treatment is surgical, and the surgical method to be chosen depends on such factors as the surgeon's experience and preference, tumor location, tumor size, and tumor complications. Despite the advent and increasing trend of using endoscopes, external and combined approaches still remain standard options in selected cases.

**Ethics Committee Approval:** Ethics committee approval was received for this study from the Non-Invasive Clinical Research Ethics Committee of Hacettepe University (24/10/2018-GO 18/980-31).

**Informed Consent:** No informed consent was taken from patients due to the retrospective nature of the study.

**Peer-review:** Externally peer-reviewed.

**Author Contributions:** Concept - A.E.P., B.K.; Design- A.E.P., B.K., S.Ö.; Supervision - S.Ö., A.E.S., M.Ö.; Resources - S.Ö., M.Ö.; Materials - B.K.; Data Collection and/or Processing - A.E.P., B.K.; Analysis and/or Interpretation - A.E.P.; Literature Search - A.E.P.; Writing Manuscript - A.E.P.; Critical Review - S.Ö., A.E.S., M.Ö.

**Conflict of Interest:** The authors have no conflicts of interest to declare.

**Financial Disclosure:** The authors declared that this study has received no financial support.

## REFERENCES

- Huang HM, Liu CM, Lin KN, Chen HT. Giant ethmoid osteoma with orbital extension, a nasoendoscopic approach using an intranasal drill. *Laryngoscope* 2001; 111: 430-2. [CrossRef]
- Erdogan N, Demir U, Songu M, Ozenler NK, Uluc E, Dirim B. A prospective study of paranasal sinus osteomas in 1,889 cases: Changing patterns of localization. *Laryngoscope* 2009; 119: 2355-9. [CrossRef]
- Atallah N, Jay MM. Osteomas of the paranasal sinuses. *J Laryngol Otol* 1981; 95: 291-304. [CrossRef]
- Cokkeser Y, Bayarogullari H, Kahraman SS. Our experience with the surgical management of paranasal sinus osteomas. *Eur Arch Otorhinolaryngol* 2013; 270: 123-8. [CrossRef]

5. Çelenk F, Baysal E, Karata ZA, Durucu C, Mumbuç S, Kanlıkama M. Paranasal sinus osteomas. *J Craniofac Surg* 2012; 23: e433-7. [\[CrossRef\]](#)
6. Buyuklu F, Akdogan MV, Ozer C, Cakmak O. Growth characteristics and clinical manifestations of the paranasal sinus osteomas. *Otolaryngol Head Neck Surg* 2011; 145: 319-23. [\[CrossRef\]](#)
7. Georgalas C, Goudakos J, Fokkens WJ. Osteoma of the skull base and sinuses. *Otolaryngol Clin North Am* 2011; 44: 875-90. [\[CrossRef\]](#)
8. Castelnuovo P, Valentini V, Giovannetti F, Bignami M, Cassoni A, Iannetti G. Osteomas of the maxillofacial district: endoscopic surgery versus open surgery. *J Craniofac Surg* 2008; 19: 1446-52. [\[CrossRef\]](#)
9. Arslan HH, Tasli H, Cebeci S, Gerek M. The Management of the Paranasal Sinus Osteomas. *J Craniofac Surg* 2017; 28: 741-5. [\[CrossRef\]](#)
10. Wolf A, Safran B, Pock J, Tomazic PV, Stammberger H. Surgical treatment of paranasal sinus osteomas: A single center experience of 58 cases. *Laryngoscope*. 2019 September 14. doi: 10.1002/lary.28299. [Online ahead of print]. [\[CrossRef\]](#)
11. Sayan NB, Ucok C, Karasu HA, Gunhan O. Peripheral osteoma of the oral and maxillofacial region: a study of 35 new cases. *J Oral Maxillofac Surg* 2002; 60: 1299-301. [\[CrossRef\]](#)
12. Gomez CK, Schiffman SR, Bhatt AA. Radiological review of skull lesions. *Insights Imaging* 2018; 9: 857-82. [\[CrossRef\]](#)
13. Earwaker J. Paranasal sinus osteomas: a review of 46 cases. *Skeletal Radiol* 1993; 22: 417-23. [\[CrossRef\]](#)
14. Pagella F, Pusateri A, Matti E, Emanuelli E. Transnasal endoscopic approach to symptomatic sinonasal osteomas. *Am J Rhinol Allergy* 2012; 26: 335-9. [\[CrossRef\]](#)
15. Pons Y, Blancal JP, Verillaud B, Sauvaget E, Ukkola-Pons E, Kania R, et al. Ethmoid sinus osteoma: diagnosis and management. *Head Neck* 2013; 35: 201-4. [\[CrossRef\]](#)
16. Izci Y. Management of the large cranial osteoma: Experience with 13 adult patients. *Acta Neurochir (Wien)* 2005; 147: 1151-5. [\[CrossRef\]](#)
17. Eller R, Sillers M. Common fibro-osseous lesions of the paranasal sinuses. *Otolaryngol Clin North Am* 2006; 39: 585-600. [\[CrossRef\]](#)