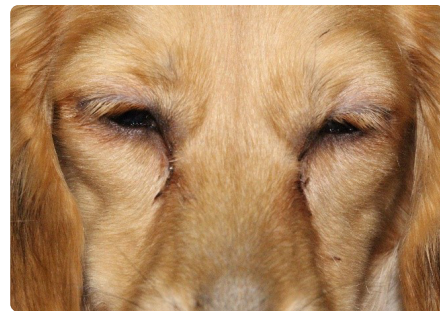
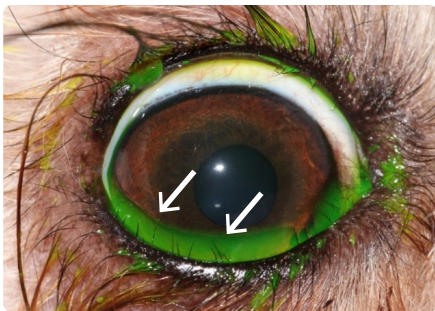

## Distichiasis



### What is distichiasis?

Distichiasis means that your dog has extra eyelashes, which come out in the wrong place on the lid margin. In some dogs, the lashes are soft and do not cause a problem whilst in others, the lashes can be stubby and cause varying levels of irritation as they rub on the eye. Distichia (which is the name for the aberrant eyelashes) are usually present from a young age.



Above a patient with distichiasis. On the photo on the left a close up of the distichia are highlighted by white arrows. On the photo above right, you can see typical signs from distichiasis with irritation by the lashes causing blinking and weeping.

### How is distichiasis diagnosed?

Suspicion about distichia is raised when young dogs present with irritated, weepy or painful eyes. This can be in pets as young as 8 weeks of age but most patients with distichiasis are presented to the vet around the age of 1 year. Sometimes owners have noticed the lashes themselves.

As explained above, distichia do not always cause irritation so if your vet has picked them up in your dog and you have not seen signs of eye irritation (such as blinking, winking, weepy eyes or keeping the eyes entirely shut) they may actually be an incidental finding. However, often your vet will suggest that you come and see the eye specialist for a referral to make sure that the lashes truly do not cause a problem.

The lashes can be very fine and hard to see with the naked eye. If your vet has picked them up, then we can check on them with our special eye examination microscope called a 'slit lamp'. This allows us to see lashes easily at about 12x magnification.

### Why has my dog developed distichiasis?

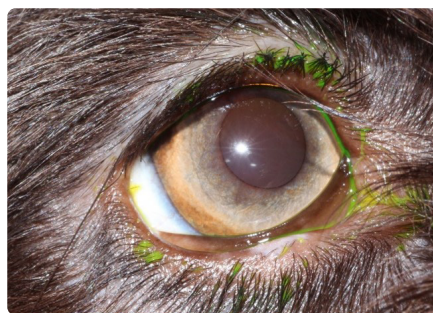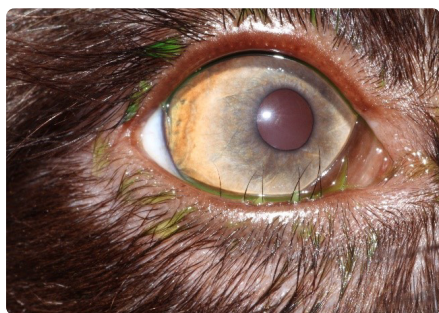
We believe that distichiasis is inherited, but there is no proof for this to date. However, we would recommend that dogs with significant distichiasis are not being bred from.

### How is distichiasis treated?

Unfortunately, there is no one single treatment for distichiasis that will remove all unwanted lashes once and for all without doing damage to the lid margins. A variety of treatments are available to reduce the number of distichia by about 50% each time and many patients will need two treatments with the odd one even requiring more repeat treatments than this. All methods of distichiasis treatment are painful whilst being applied and thus require a

general anaesthetic. Furthermore, all distichiasis treatments are carried out under the operating microscope to allow optimal visualisation of the fine hairs. The following treatment options are available:

- **Electrolysis:** Here, a fine needle is inserted into the lid margin to reach the root of the hair, which is then destroyed with an electrical current. This method causes minimal lid swelling and dogs are usually comfortable immediately after they wake up from their anaesthetic.
- **Cryotherapy:** Here the lid margins are subjected to extreme cold and effectively 'frozen and re-thawed' in a few cycles under very controlled conditions. This method of treatment can be very efficient but can cause marked lid swelling.
- **Surgical removal:** Under the operating microscope, the roots of the lashes are cut out with a fine wedge of eyelid margin. This procedure causes minimal swelling but possibly some bleeding post-operatively but has the highest risk to cause deformation of the eyelid margin.



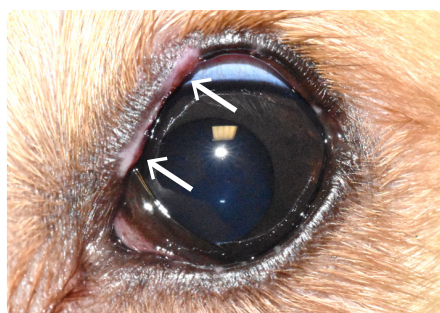Above right an eye prior to treatment for distichiasis. On the above left the same eye 2 weeks after repeat treatment with electrolysis – no lashes are left.

## What can go wrong with distichiasis treatment?

It is rare that we can remove all lashes with one treatment alone. However, often a reduction in number of lashes means that many patients show less, and possibly no clinical signs of irritation after the first procedure. When lashes regrow and the patient continues to show irritation, repeat treatment, possibly more than once, is required.

Other complications seen with distichiasis treatment are the following:

- The routine risks of general anaesthesia
- Scarring of the eyelid margins – this is very rare but occasionally might require surgical correction
- Damage to the tear film quality - this is common but fortunately rarely a significant problem to the patient. The roots of the distichia sit in glands on the eyelid margin. Treatment to destroy the distichia roots means that the gland where the root sits might also be damaged. This can affect the tear film quality as these glands produce part of the tear film. If this occurs, we can usually manage it with simple tear replacers.



A patient one week after electrolysis. Small areas of pigment loss on the upper lid are visible as marked by the white arrows. Temporary pigment loss and swelling are common with electrolysis and cryotherapy but will usually resolve quickly. Rarely, pigment loss is permanent and white fur can re-grow in the affected area.

