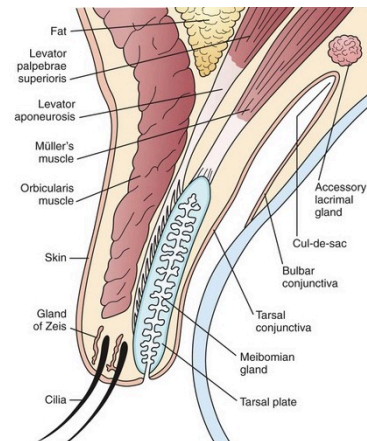




## Patient information leaflet

### Eyelid cysts

A number of cysts may occur in the eyelids and periocular area. These include for example, stye, chalazia, and translucent cysts of Moll (or apocrine hydrocystomas), which arise from the glands of Moll associated with the eyelash follicles. Similar lesions may arise from the sweat glands of the skin. The definitive treatment of cyst of Moll is deroofting with cautery (heat treatment to the base of the cyst) or excision.



Section through the upper lid

Other lesions of the eyelids include cysts of Zeiss, viral lesions (molluscum contagiosum) and yellowish lipid depositions (xanthelasma).

An external hordeolum (stye) is an acute abscess within an eyelash follicle and its associated glands. It can cause a tender, inflamed lump.

An internal hordeolum is one of the commonest of all lid lumps. It is an acute abscess of the meibomian glands in the eyelid margin. It is a tender, inflamed lump. Hot compresses are recommended and antibiotics and/or surgical incision and curettage may be recommended particularly if large and painful.

A chalazion is caused by longstanding inflammation of a blocked meibomian gland. Hot compresses may be used to encourage drainage from the oil glands however persistent and troublesome lesions may be treated surgically with incision and curettage. Recurrent or suspicious lesions may also be biopsied to exclude carcinoma.