

Five Life-Threatening Causes of Diplopia You Can't Afford to Miss

Danica J Marrelli OD FAAO
University of Houston College of Optometry

Financial Disclosure

- Aerie Pharmaceutical
- Allergan
- Bausch & Lomb
- Carl Zeiss Meditec

(None relevant to this presentation)

Diplopia = Intimidation

- Vast Differential
- Evaluation can be time consuming
- Often requires ancillary testing, referral

Most diplopia is not dangerous. Some is very dangerous! Look for the red flags to know which one you've got in your chair.

SYSTEMATIC APPROACH

- History:
 - Monocular or Binocular
 - Constant/intermittent/variable
 - Horizontal/vertical
- Clinical Evaluation:
 - Localize muscle/nerve involved
 - Associated structures
 - Pupils
 - Lids
 - Other CN
 - Other anatomic considerations
- Enhance localization with demographics/history to determine what other testing may be needed
 - Laboratory testing
 - Radiology testing

History: Monocular or Binocular?

- Monocular: Completely different (easier!!!!) approach:
 - Media
 - Refractive
 - Dry Eye
 - Pterygium
 - Polycoria
 - Cataract
 - IOL
 - Retinal problems

History: Monocular or Binocular?

- Binocular:
 - Mechanical
 - Neuromuscular
 - Neurologic
 - Vascular
- Horizontal or vertical?
- Worse in particular gaze?
- Constant/intermittent/variable?
- Other symptoms?
 - HA
 - Fatigue
 - Weakness
 - Redness/irritation
 - weight loss/appetite?
 - jaw pain?

Clinical Evaluation: Localize

Actions of extraocular muscles

Muscle	Primary action	Secondary action	Tertiary action
MR	Adduction	—	—
LR	Abduction	—	—
SR	Elevation	Intorsion	Adduction
IR	Depression	Extorsion	Adduction
SO	Intorsion	Depression	Abduction
IO	Extorsion	Elevation	Abduction

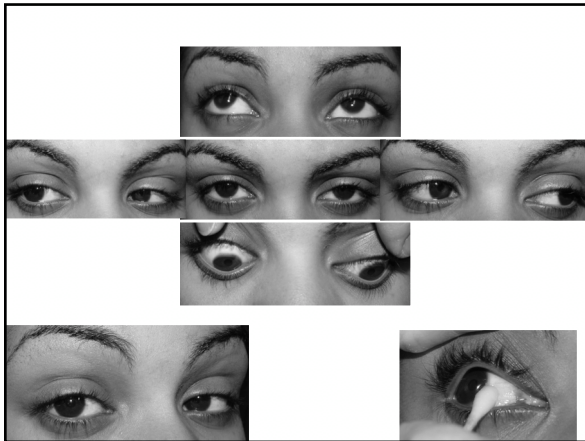
• Motility:
— Versions/ductions

RIGHT EYE

LEFT EYE

Clinical Evaluation: Localize

• Cover test: Nine positions of gaze (neutralize)



Clinical Evaluation: Localize

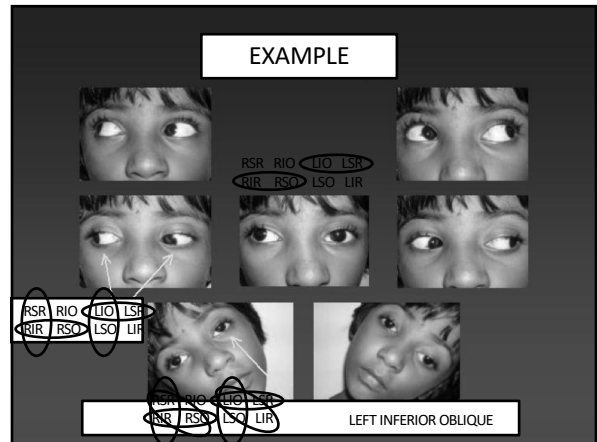
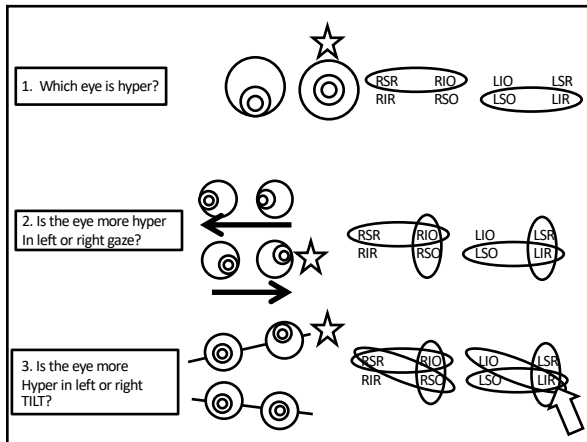
• Parks 3 Step Test (review)

• Question (all 3 steps): which eye is HYPER????

1. Which eye is hyper?

1. Which eye is hyper?

2. Is the eye more hyper in left or right gaze?

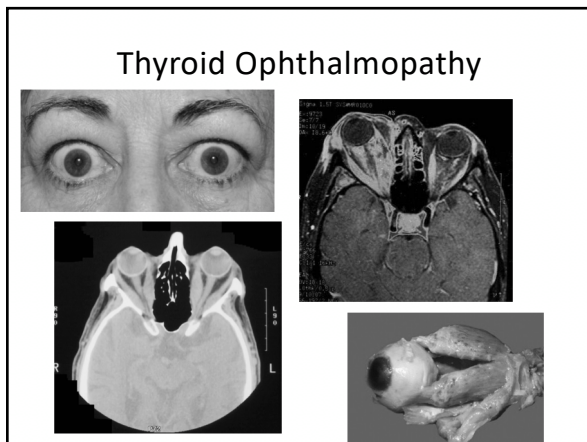


CLINICAL EVALUATION: OTHER SIGNS

- Gross Exam:
 - Eyelid position
 - Globe position (proptosis?)
 - Evidence of inflammation
- Other ophthalmic testing
 - Color
 - Visual Field
 - Ophthalmoscopy

Common Causes of Diplopia

- Thyroid Eye Disease (restrictive/mechanical)
 - Most common cause of diplopia in adults
 - IR most common/first muscle involved (MR, SR)
 - Restrictive (+ forced ductions)
 - “I’M So Lucky” (inferior, medial, superior, lateral)
 - Many times have other signs:
 - Lid retraction
 - Proptosis (Norms: 12-22mm (24 AA, 18 Asian); <3mm asymmetry)
 - Lid edema/conj chemosis
 - FB sensation, tearing, photophobia
 - Testing:
 - Laboratory: T3/T4/TSH
 - CT scan: enlargement of muscle belly, tendons spared



Common Causes of Diplopia

- Myasthenia Gravis
 - Neuromuscular junction transmission abnormality (Ach receptor antibodies)
 - Hallmark is transient/variable weakness
 - 48-53% of MG patients initially have ONLY eye signs (EOM, orbicularis, levator)
 - PUPIL IS NEVER INVOLVED!
 - Diagnostic Tools:
 - Lid fatigue test
 - Ice pack test (ptosis)
 - Enlon test (edrophonium)
 - Ach receptor antibodies



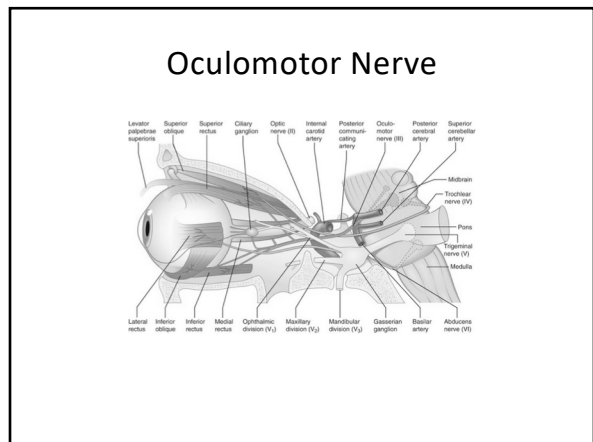
Table 1: Combinations of findings that should suggest both myasthenia gravis (MG) and thyroid eye disease (TED)

- Simultaneous or sequential true ptosis and true lid retraction
- Exotropia rather than esotropia in a patient with TED
- Proptosis in a patient with MG
- Optic neuropathy (compressive TED) in a patient with MG
- Eye pain in a patient with MG (MG is a neuromuscular and not sensory disease)
- Exposure keratopathy in a patient with MG not due to weak lid closure
- Variability and fatigue of findings in TED
- Orbicularis weakness in TED

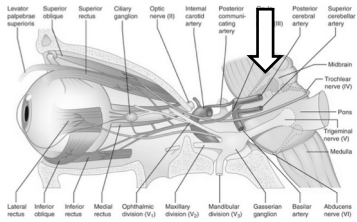
- ### Common Causes of Diplopia
- Cranial Nerve Palsy
 - CNIII
 - CNIV
 - CN VI

- ### Review of Oculomotor Control
- Two main pathways:
 - Supranuclear: controls pursuits, saccades, vergence (symmetrical ocular movements); lesions in the supranuclear pathways don't typically cause diplopia
 - Infranuclear: Begins in each CN nucleus/subnucleus and proceeds to innervate EOM; lesions in the infranuclear pathway will usually cause diplopia

- ### CN III – Oculomotor Nerve
- Cluster of nuclei near center of midbrain; exits in anterior aspect of midbrain
 - Enters subarachnoid space between posterior cerebral and superior cerebellar arteries, then runs lateral to posterior communicating artery
 - Enters cavernous sinus in very close proximity to carotid a.; divides into superior (SR, levator) and inferior (IR, IO, MR) divisions
 - Enters orbit through superior orbital fissure

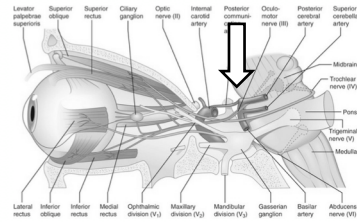


Oculomotor Nerve



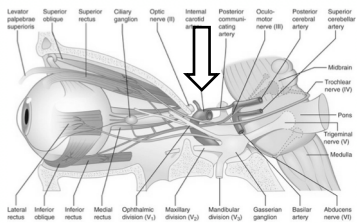
- Infarct
- AVM
- Cavernous Hemangioma
- Neoplasm
- MS
- Trauma

Oculomotor Nerve



- Aneurysm

Oculomotor Nerve

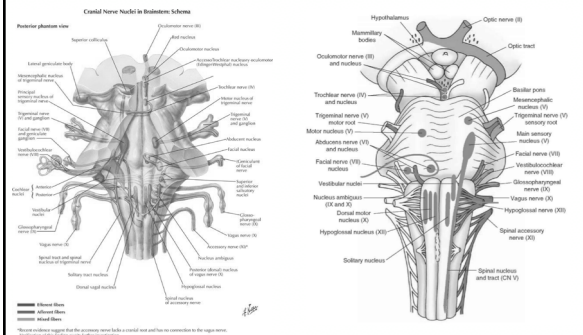


- CS thrombosis
- Carotid a. aneurysm

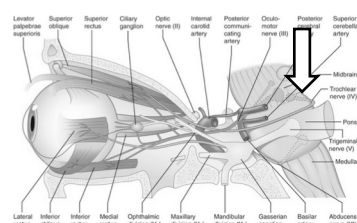
CN IV – Trochlear Nerve

- Trochlear nerve is the only nerve to exit from the dorsal aspect of midbrain, course anteriorly around the midbrain, then travel lateral to CNIII between posterior cerebral and superior cerebellar arteries
- Very long (lazy) course of this nerve = high susceptibility to injury after head trauma
- Travels through cavernous sinus and into orbit through superior orbital fissure, OUTSIDE of the annulus of Zinn

Trochlear Nerve

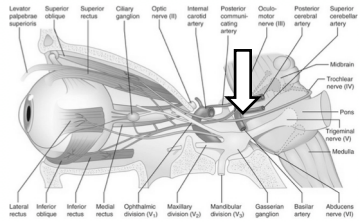


Trochlear Nerve



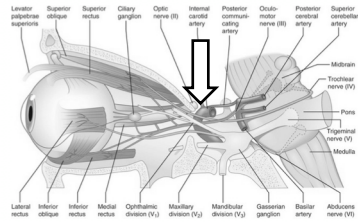
- Hemorrhage
- Trauma
- MS

Trochlear Nerve



- Aneurysm
- Tumor

Trochlear Nerve



- Cavernous sinus thrombosis
- Carotid a. dissection

Congenital vs Acquired CN IV Palsy

- Congenital:
 - Vast majority of CN IV palsy cases are congenital
 - Long standing head tilt (old pictures)
 - No torsional complaint
 - LARGE vertical phoria ranges
- Acquired:
 - >50% due to trauma (history)
 - 10% caused by tumor

CN VI – Abducens Nerve

- Nucleus in pons just ventral to floor of IV ventricle and just lateral to MLF, between pons and medulla
- 40% of fibers project to cross to the MLF to innervate contralateral MR subnucleus (CNIII) – coordinates horizontal gaze
- Ascends through subarachnoid space along clivus and makes a sharp bend over the temporal bone (site of compression with IICP)
- Travels through cavernous sinus and into orbit through superior orbital fissure

Abducens Nerve

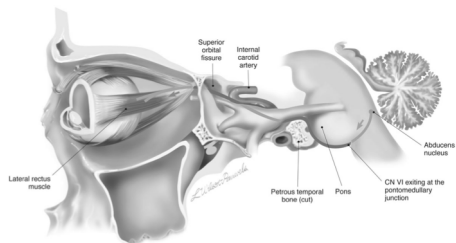
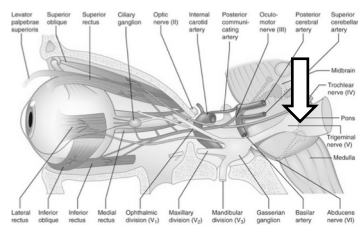


Figure VI-1 Overview of the abducens nerve.

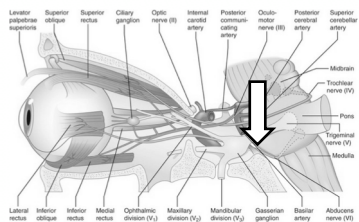
From Cranial Nerves 3rd Ed. ©2010 Wilson-Paivels, Stewart, Axelson, Spacey, PMPH-USA

Abducens Nerve



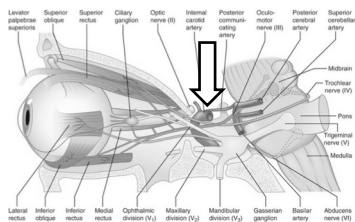
- Pontine glioma (children)
- Tumor

Abducens Nerve

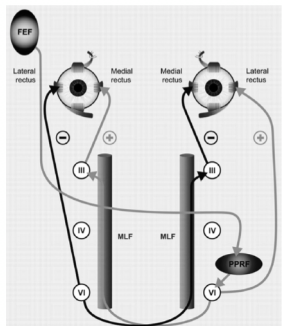


- Elevated ICP
- Hemorrhage
- Meningitis (young adults)
- Inflammation

Abducens Nerve



Abducens Nerve - MLF



Internuclear Ophthalmoplegia (INO)

RIGHT EYE (N.D. INT) LEFT EYE

Primary gaze

Left gaze (Abduction = mydriasis)

Right gaze (Adduction = miosis)

Normal

Convergence normal in posterior type

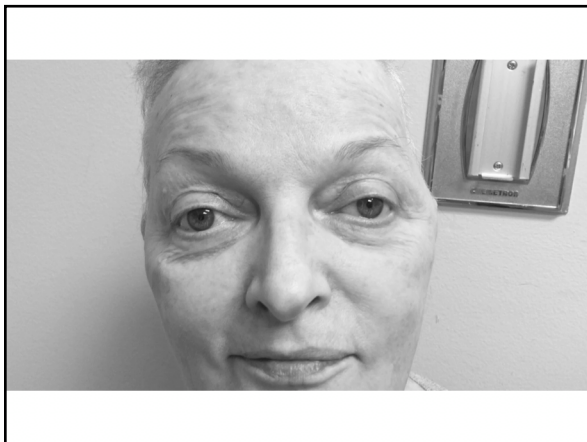
Lesion in the left MLF. Note right eye adduction deficit on left gaze.

"Look at me"

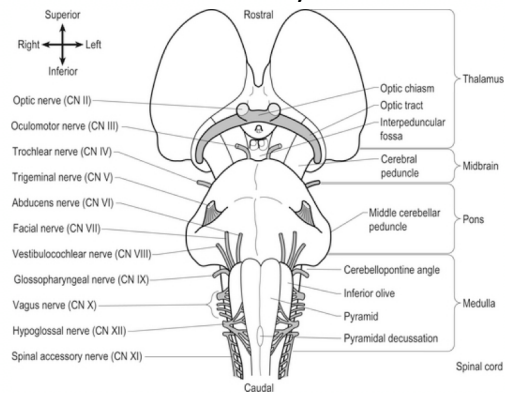
"Look to the right"

"Look to the left"

"Look at this object"



"Proximity"



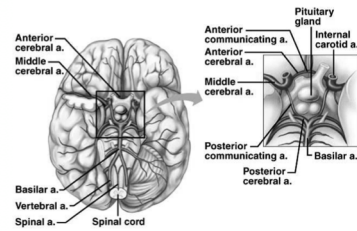
“Five To Fear”

1. Pupils
2. More than one:
 - Lid
 - Pupil
 - EOM
3. Polyneuropathy (more than one CN)
4. Weakness/fatigue
5. New headache/pain

“Deciphering Diplopia” Eynet November/December 2009

1. Pupil Involvement

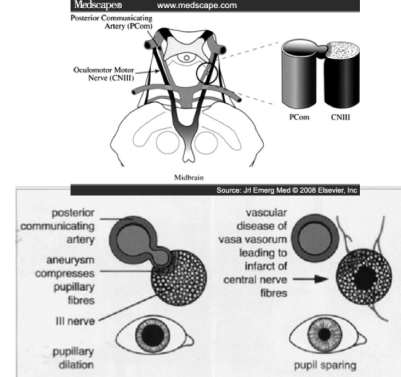
- CNIII palsy with pupil involvement: Must suspect LIFE-THREATENING aneurysm



CN III Palsy

- Aneurysm is the cause of 18-29% of CN III palsies
 - When an aneurysm is the cause, 95-97% will show pupil involvement
 - Likely that the palsy is the result of an acute change (hemorrhage, expansion) – significant risk of rupture
 - Possible (but extremely rare) that pupil is the ONLY sign (motility signs may be subtle)
 - Pupil involvement can evolve over days

CN III Palsy



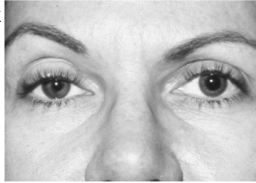
Two Important CN III Issues

- Partial versus Complete
 - Can be complete or partial, or divisional
 - All partial CNIII palsies should be imaged
- Neurologically Isolated
 - Be sure to check CNIV by looking for intorsion in downgaze to confirm CN IV is functioning

Cranial nerve palsy	Exam findings – evidence of incomitance		
	Direction of gaze	Primary position	Direction of gaze
Right 3rd nerve palsy	Smaller angle of horizontal squint	Right eye turns downwards and outwards	Unable to adduct right eye Larger angle of squint Double vision further apart
Right 4th nerve palsy	No obvious squint	Right eye turns upwards and outwards	Right eye elevates more as it moves medially Double vision further apart
Right 6th nerve palsy	Unable to adduct right eye Larger angle of squint Double vision further apart	Right eye turns medially	Able to adduct right eye No obvious squint

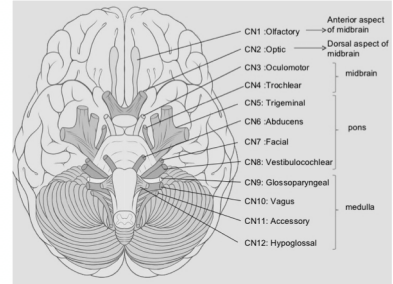
2. More than 1: Lids, Pupils, EOMS

- If any ONE of those has a problem (lids, pupils, EOMS), you HAVE to check the others
- Concerns:
 - Horner Syndrome (carotid dissection)
 - CN III with aneurysm
 - Inflammatory disease (Guillain-Barre')



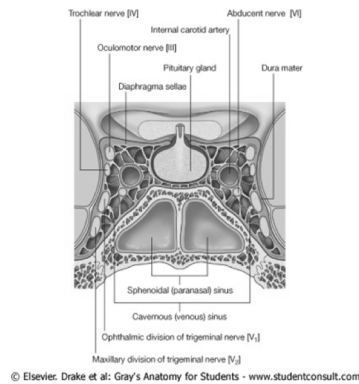
3. Polyneuropathy (more than 1 CN)

- Concerns:
 - Intracranial tumors
 - Meningitis
 - Cavernous Sinus lesion



Cavernous Sinus:

- ICA
- CNIII
- CNIV
- CNVI
- CNV₁
- CNV₂



CN Evaluation: Quick & Easy

- I (Olfactory)
- II (Optic)
- III (Oculomotor)
- IV (Trochlear)
- V (Trigeminal)
- VI (Abducens)
- VII (Facial)
- VIII (Auditory)
- IX (Glossopharyngeal)
- X (Vagus)
- XI (Spinal accessory)
- XII (Hypoglossal)

4. Weakness/fatigue

- Concern:
 - Myasthenia Gravis
- MG: must be considered in ANY pupil-sparing motility disturbance
- KEY:
 - Often transient/variable throughout day or day to day
 - Other features/symptoms:
 - Lid involvement (ptosis)
 - Weakness/hoarseness/difficulty swallowing
 - NEVER involves pupil

5. New headache/pain

- Concern:
 1. Giant Cell Arteritis (GCA)
 - Life-threatening and sight-threatening
 - Must be considered in anyone over 50 years old
 - Associated with aortic dissection, stroke, myocardial infarction
 - Diplopia can be constant or transient
- KEY Questions: any patient over 50
 - New headache/scalp tenderness/pain with chewing/fever/weight loss

5. New headache/pain (cont.)

- Other concern:
 - Intracranial tumor/increased ICP
 - KEY: Frequently have other neurologic symptoms
 - May have papilledema

When to Image?

- Scans don't diagnose!! (Doctors DO)
 - Some causes of diplopia will not be picked up on imaging
 - Myasthenia Gravis
 - Giant Cell
 - Monocular diplopia!
- When to scan:
 - When it's not neurologically isolated
 - When the pupil is involved
 - If CN III palsy is partial (? Scan all CNIII)
 - When the patient is younger than 50 (unless long history of vascular disease)
- When to *perhaps* wait:
 - Older patient with vascular disease or younger with long history of vascular disease, with MONO-neuropathy without pupil involvement and no pain
 - Have patient observe for pupil involvement
 - If no resolution in 6 weeks, work up/image
 - MANY CONSIDER IMAGING TO BE MANDATORY IN ALL CN III PALSIES

Isolated Third, Fourth, and Sixth Cranial Nerve Palsies from Presumed Microvascular versus Other Causes

A Prospective Study

Madhura A. Tamhankar, MD,¹ Valerie Bionese, MD,² Gui-Shuang Ying, MD, PhD,¹ Sushank Prasad, MD, PhD,³ Prem S. Subramanian, MD, PhD,⁴ Michael S. Lee, MD,⁵ Eric Eggenberger, DO,⁶ Heather E. Moss, MD, PhD,⁷ Stacy Pineles, MD,⁸ Jeffrey Bennett, MD, PhD,⁹ Benjamin Osborne, MD,¹⁰ Nicholas J. Volpe, MD,¹¹ Grant T. Liu, MD,¹ Beau B. Bruce, MD, MS,² Nancy J. Newman, MD,² Steven L. Galetta, MD,¹ Laura J. Balcer, MD, MSCE¹

Ophthalmology Volume 120, Number 11, November 2013

Case: Why Are My Eyes STILL Red?

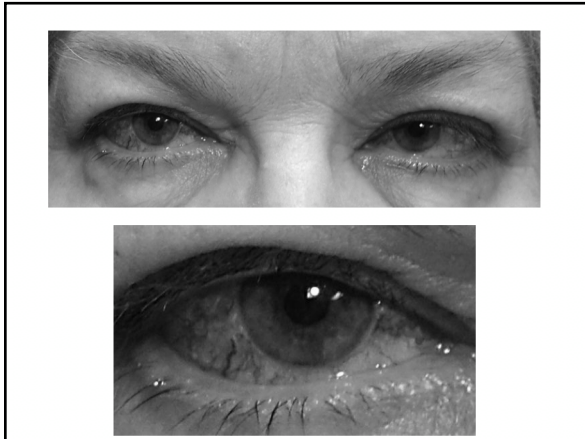
- 60yo HF presents complaining of worsening red eyes
- HPI:
 - (-) photophobia or eye pain
 - (+) itching & tearing
 - Diplopia “periodically” x 2 months
 - Most recent diagnosis was unspecified conjunctivitis WITH CNVI palsy due to DM

Patient History

- POH: Unremarkable
- PMH: DM2 x 4 years; HTN
 - Recent hospitalization due to severe HA
- FHx: non-contributory
- Meds: Benicar®, metformin
- All: None
- Social: No tobacco/alcohol

Examination:

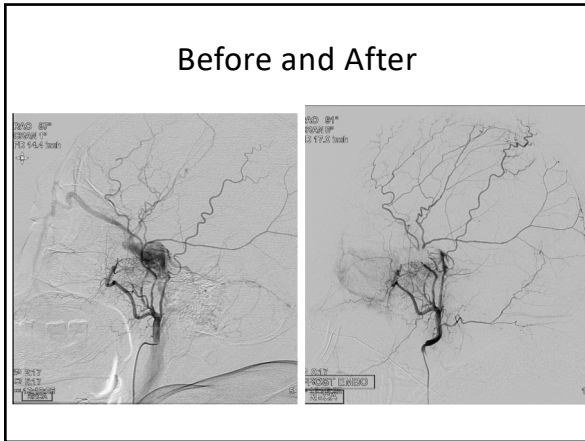- VA: 20/20 OD, OS
- Pupils: equal, round, 3+D/C, (-) RAPD
- Motility: abduction deficit OU
- Slit lamp:
 - L/L/L – normal
 - Conj – 4+ hyperemia with corkscrew vessels, chemosis
 - Clear cornea, AC
- IOP: 32mmHg OD 24mmHg OS
- DFE: Normal DMVP OU



Things to think about:

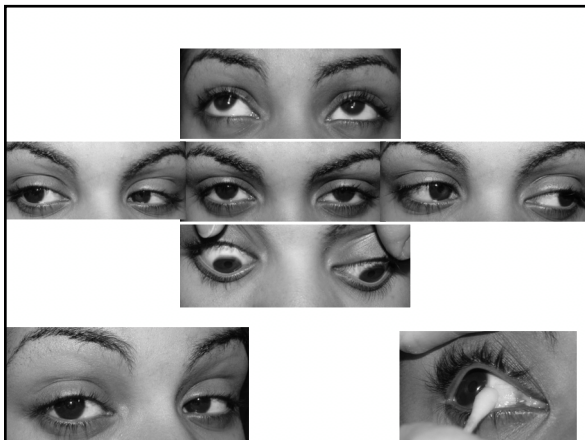
- 1) No pupil involvement
- 2) No lid involvement
- 3) (+) polyneuropathy (both CNVI)
- 4) No weakness/fatigue
- 5) New Headache

– IMAGE THIS PATIENT!



Case: “Periodic Diplopia”

- 30yo AAF c/o periodic diplopia
- Onset approx 1 week ago
 - Occurs only when she looks to the right
 - Very severe headache
- POH: unremarkable
- PMH: unremarkable



Things to think about:

- 1) No pupil involvement
- 2) No combo (pupils/lid/motility)
- 3) No polyneuropathy (simple CNVI)
- 4) No weakness/fatigue
- 5) PAINFUL

- Painful CN VI palsy in patient younger than 50, no vascular history
 - IMAGE THIS PATIENT!!!

Case: Double Since This Morning

- 67yo AAF with h/o horizontal diplopia since this morning
- Doesn't bother her when reading but is very bothersome when watching tv, driving
 - Disappears when she looks to the left
 - No fatigue, no weight loss/anorexia, no scalp tenderness/jaw claudication
- POH: cataract surgery 2 years ago
- PMH: DM2 x 14 years; HTN x 14 years

Case: Double Since This Morning

- BCVA: 20/20 OD, OS
- Pupils: EQUAL , 3mm OU, (-) RAPD
- CVF: FTFC OD, OS
- Motility: Restricted aBduction right eye
- SLE/IOP/DFE: Normal
- CN assessment: Intact I-V; VII-IX; XI-XII

Things to Think About:

- 1) No pupil involvement
- 2) No combo (lids/pupil/motility)
- 3) No polyneuropathy (all other CN intact)
- 4) No weakness
- 5) No pain/headache
- Older patient with strong vascular history: LIKELY ischemic CNVI; no imaging; monitor x 6 weeks, reassess

Case: Double Since This Morning

- 67yo WM with h/o horizontal diplopia since this morning
 - No fatigue, no weight loss/anorexia, no scalp tenderness/jaw claudication/HA
- POH:
 - Had monocular diplopia 5 years ago due to pterygium OD; pterygium surgery resolved diplopia
 - Pterygium OS but patient did not want surgery
- PMH: Depression, gout; had physical 2 weeks ago with standard labs; no HTN/DM

Case:

- Things to Think About:
 - Is this just MONOCULAR diplopia from the other pterygium?

No.
Cover Right Eye = No diplopia
Cover Left Eye = No diplopia

Case: Double Since This Morning

- BCVA: 20/20 OD, OS
- Pupils: EQUAL , 3mm OU, (-) RAPD
- CVF: FTFC OD, OS
- Motility: Restricted aBduction left eye
- SLE/IOP/DFE: Normal
- CN assessment: Intact I-V; VII-IX; XI-XII

Things to Think About:

- 1) No pupil involvement
 - 2) No combo (lids/pupil/motility)
 - 3) No polyneuropathy (all other CN intact)
 - 4) No weakness
 - 5) No pain/headache
- Older patient with NO vascular history:
UNLIKELY ischemic CNVI; MUST image

Summary

- Know what questions to ask initially:
 - Monocular vs binocular
 - Worse in one particular position of gaze
 - Variability/weakness
 - Other neurologic symptoms
 - Headache/jaw pain
- Know how to evaluate/localize
 - Versions/ductions (forced?)
 - Parks 3 step if vertical
- Know how to quickly evaluate other CN function
- Know when to order labs, radiology, refer, or follow

Thank you for your attention!

Questions?

Email me: Dmarrelli@uh.edu