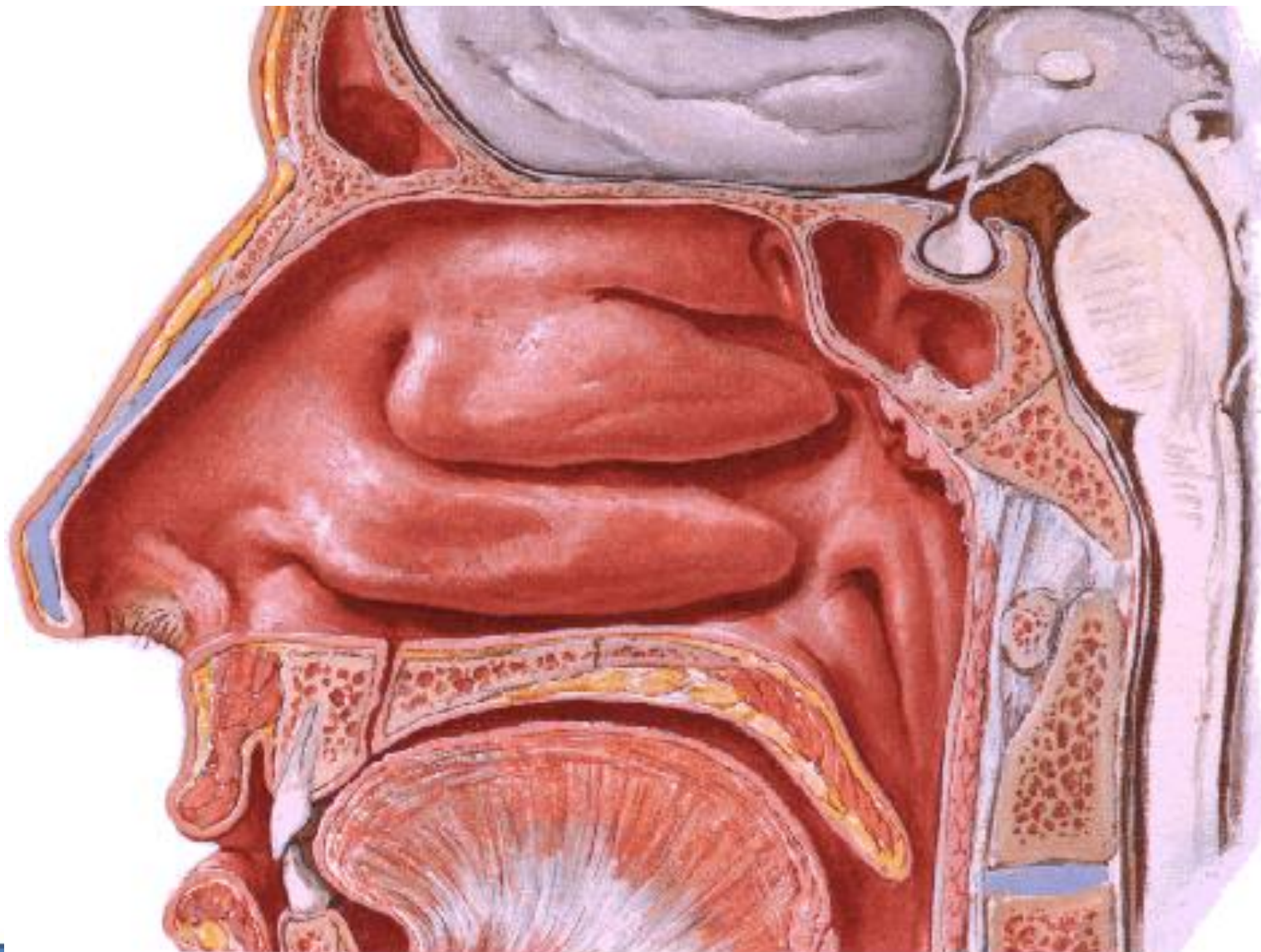


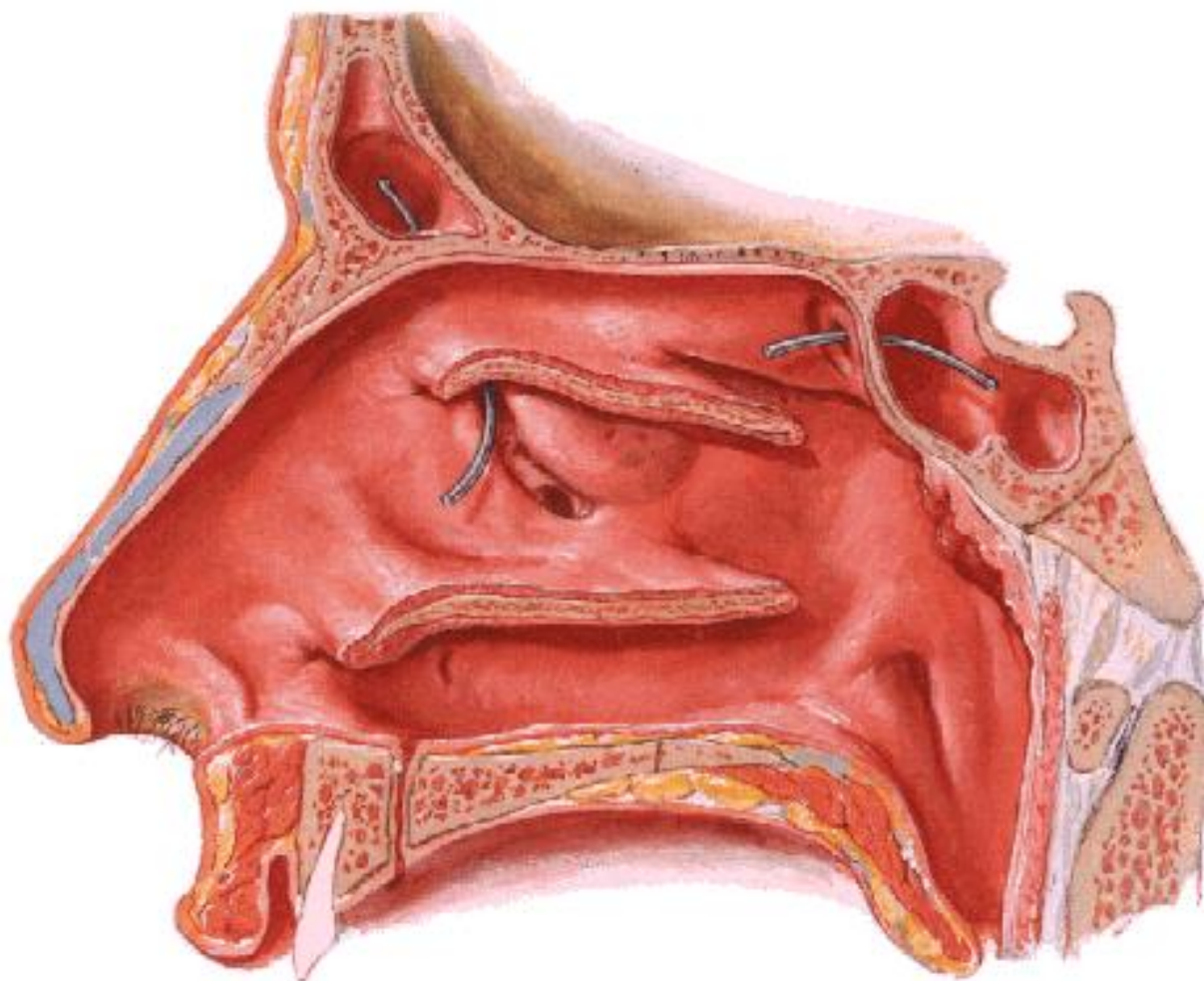
Aspectos gerais de: Nariz, cavidade nasal, seios paranasais.

M.Sc. Profa Viviane Marques

O olfato nos indica bons e maus sinais.

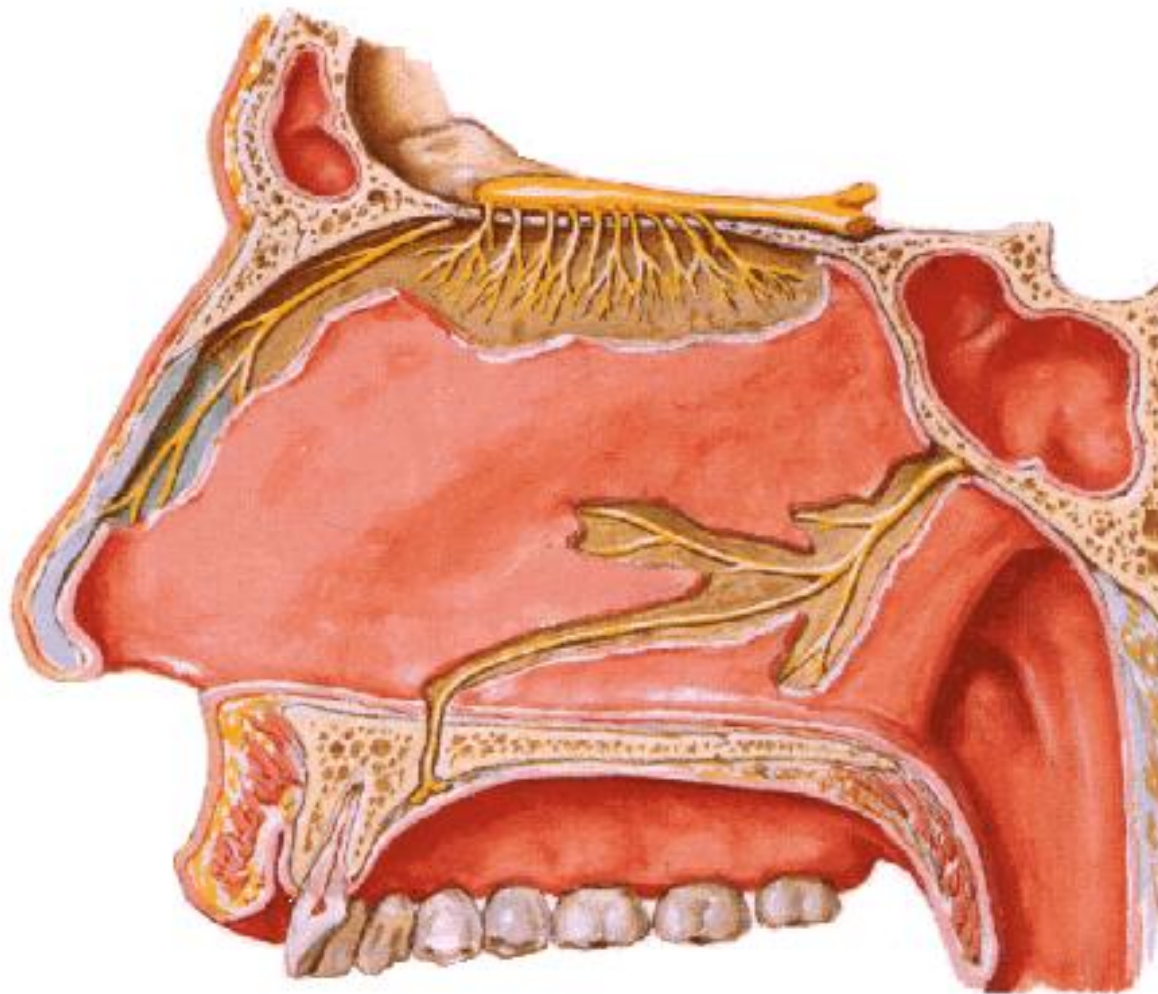


Parede Lateral do Nariz - Concha Nasal Removida

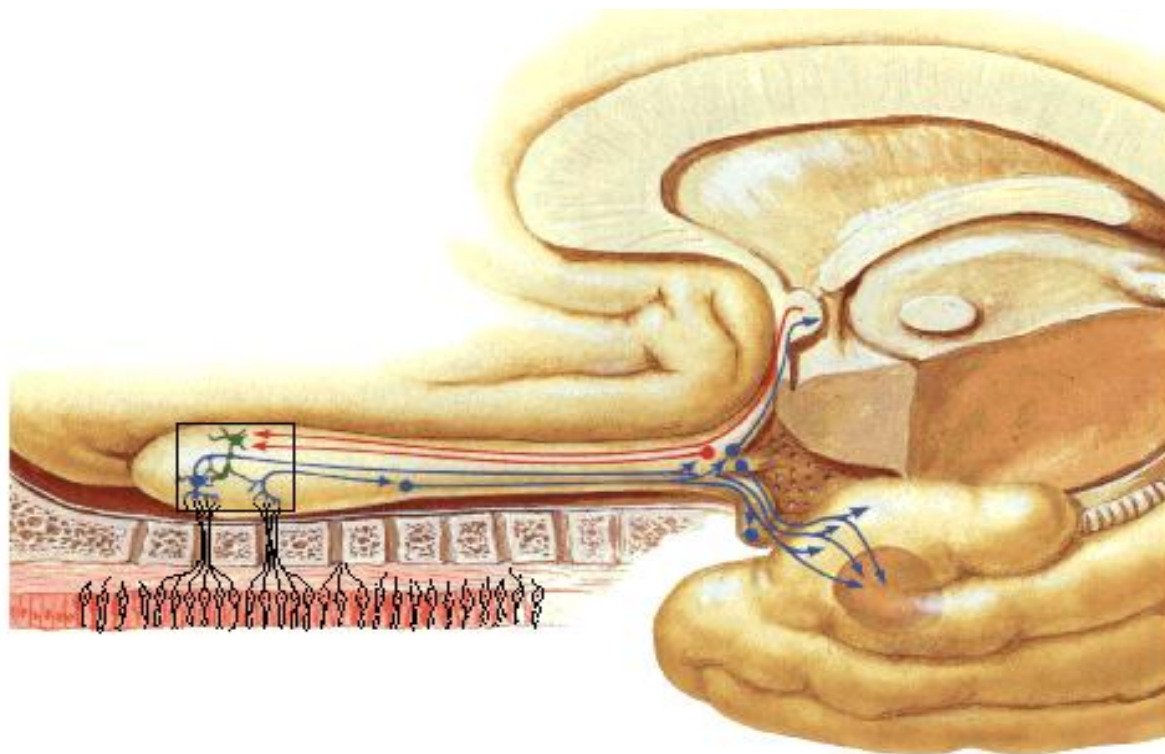


Nervos da Cavidade Nasal

Septo Nasal

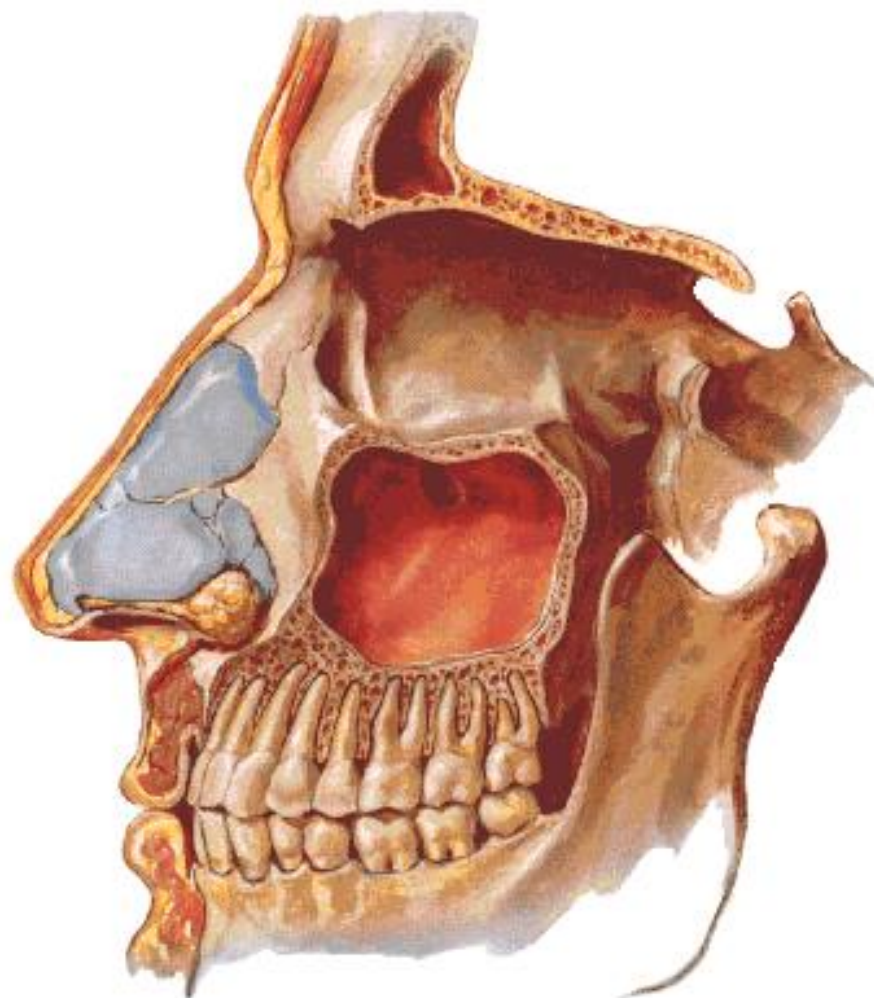


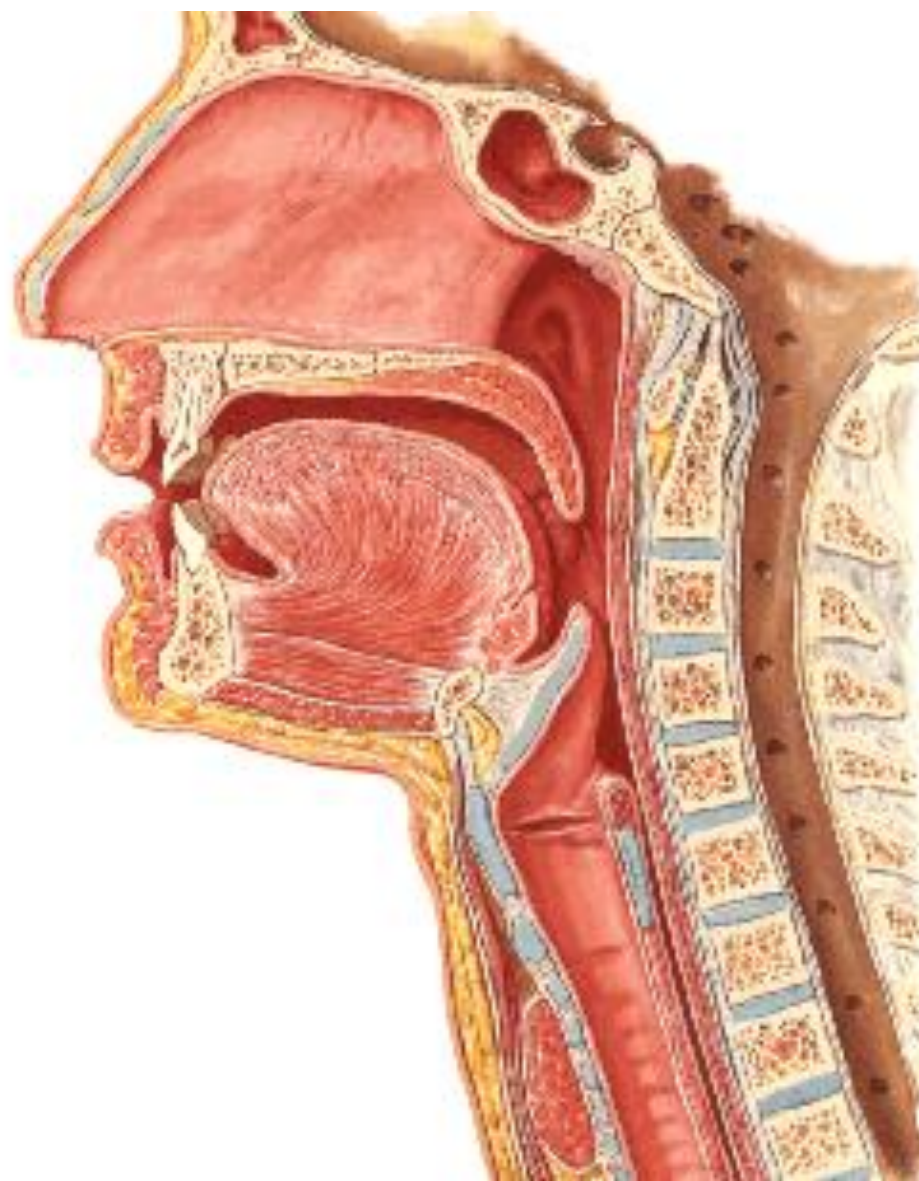Os receptores olfativos crescem continuamente, morrem e se regeneram em um ciclo que dura cerca de 4 a 8 semanas.

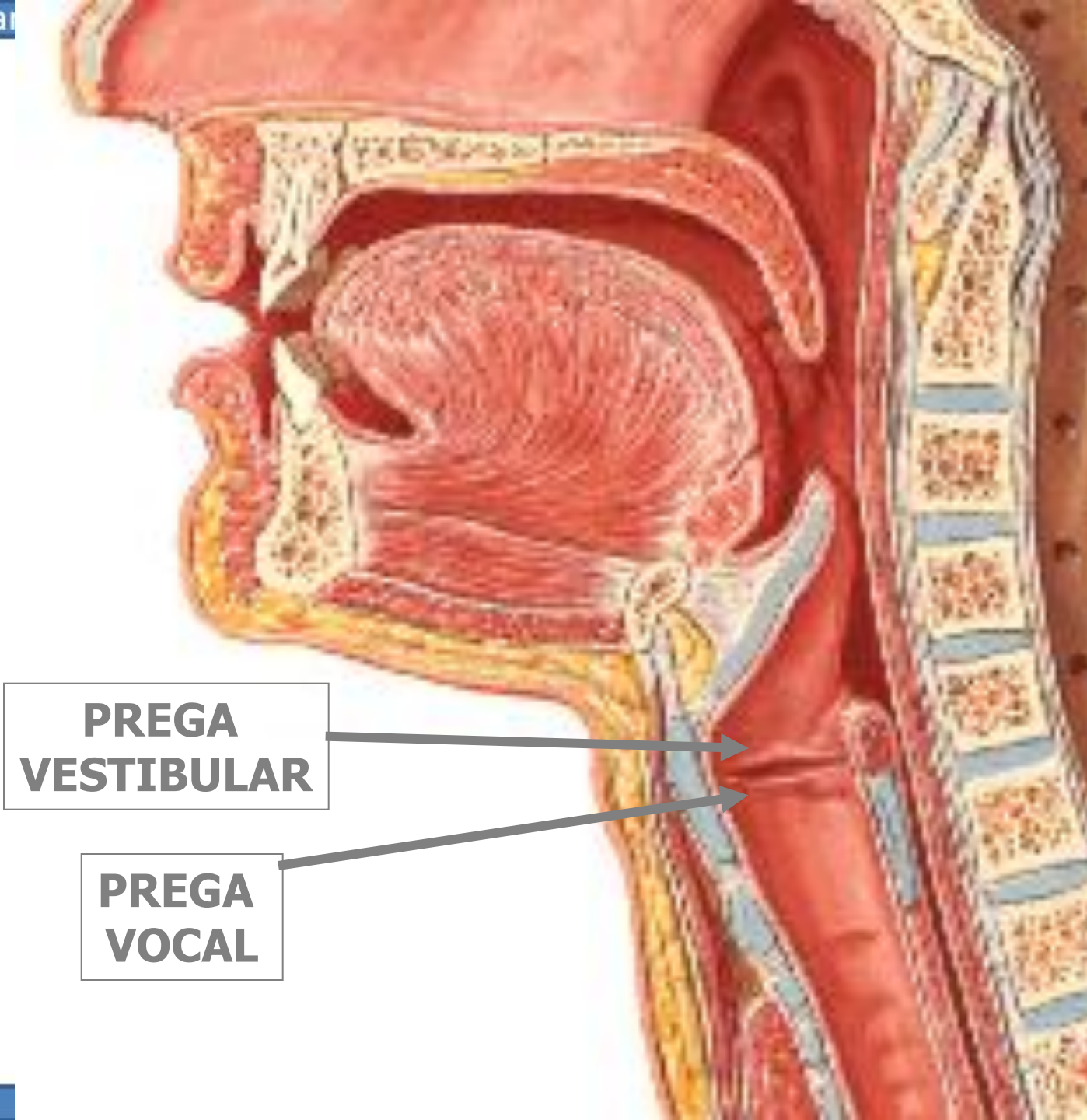


Seios Paranasais

Dissecação Lateral





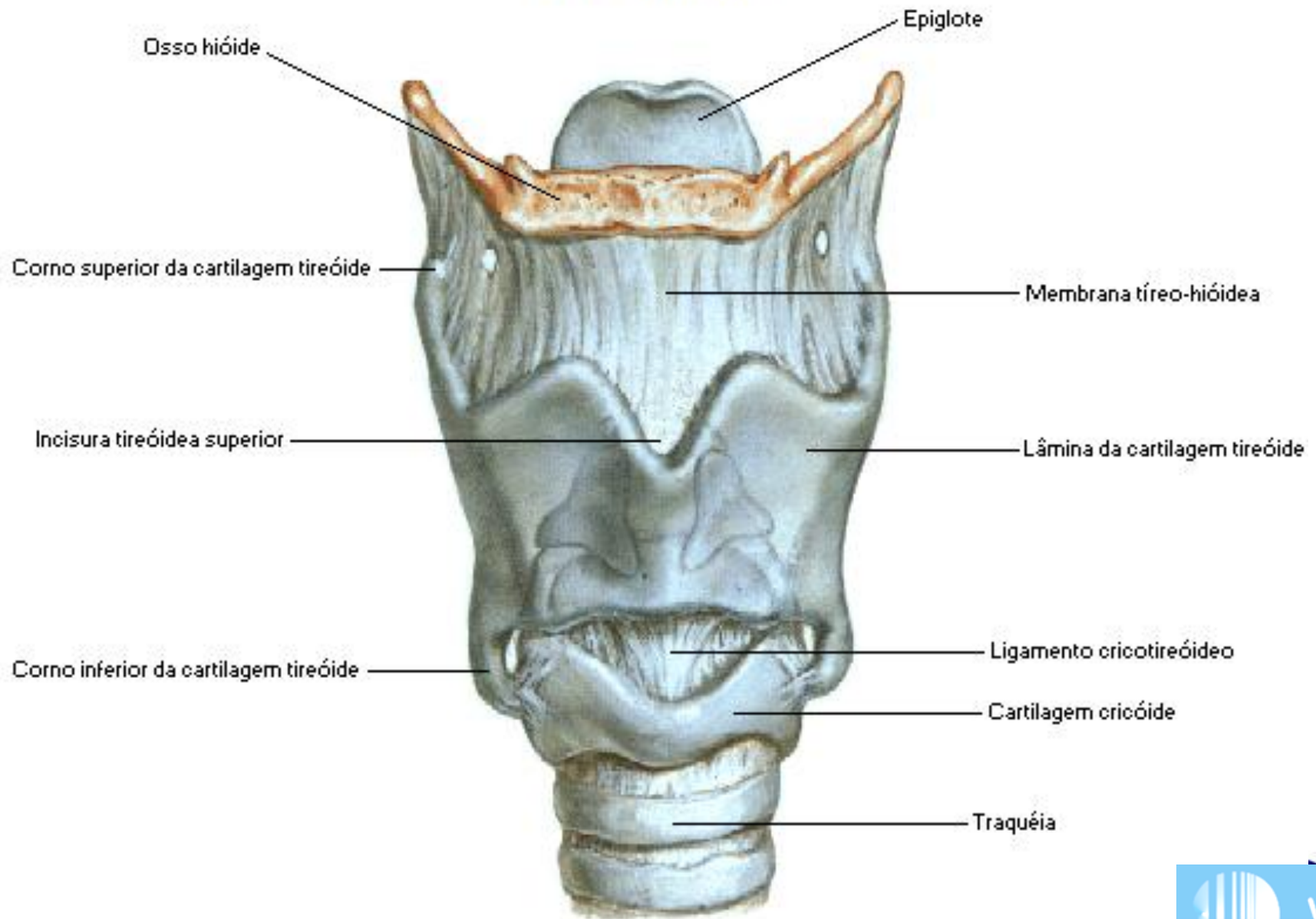


**PREGA
VESTIBULAR**

**PREGA
VOCAL**

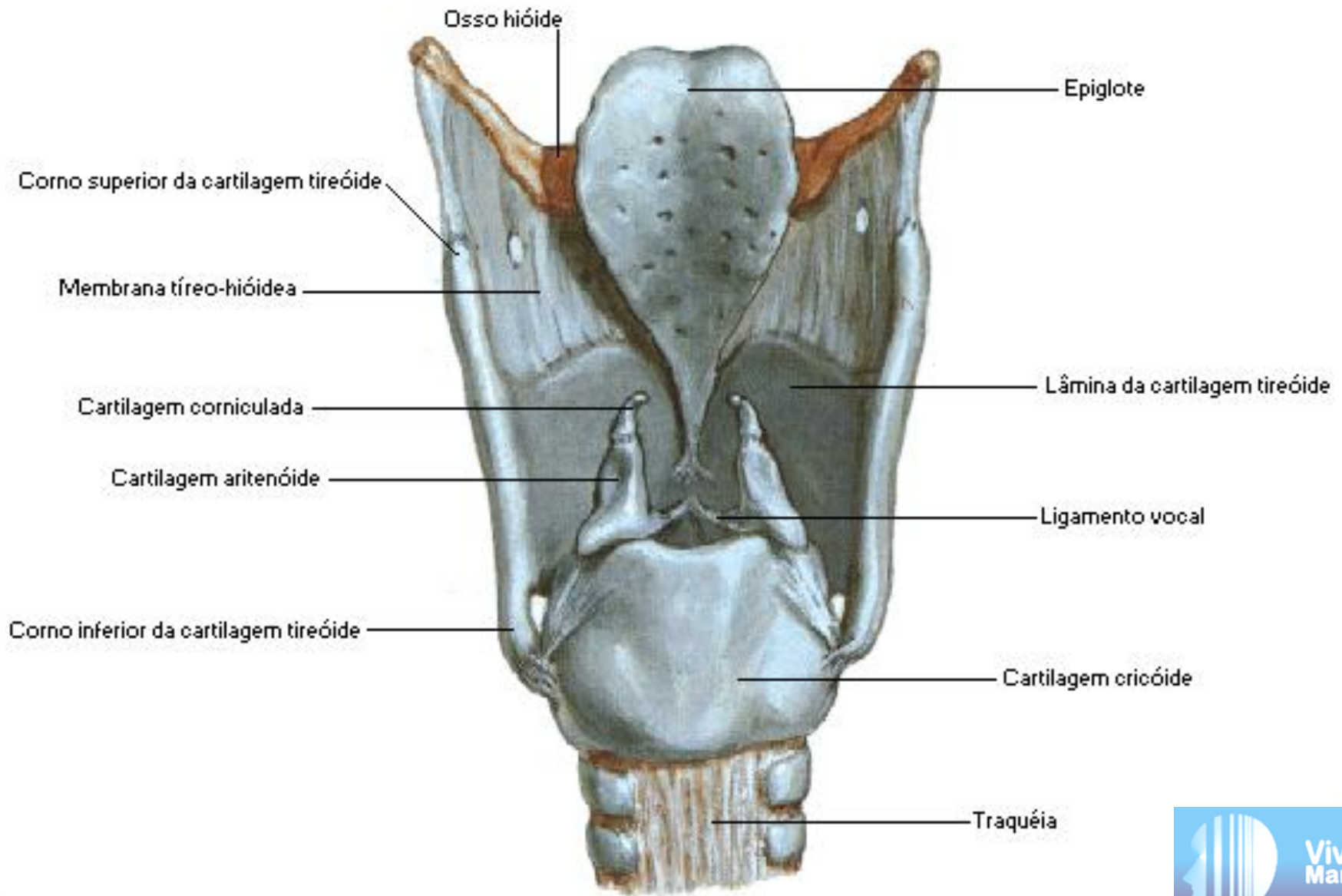
Cartilagens da Laringe

Vista Anterior



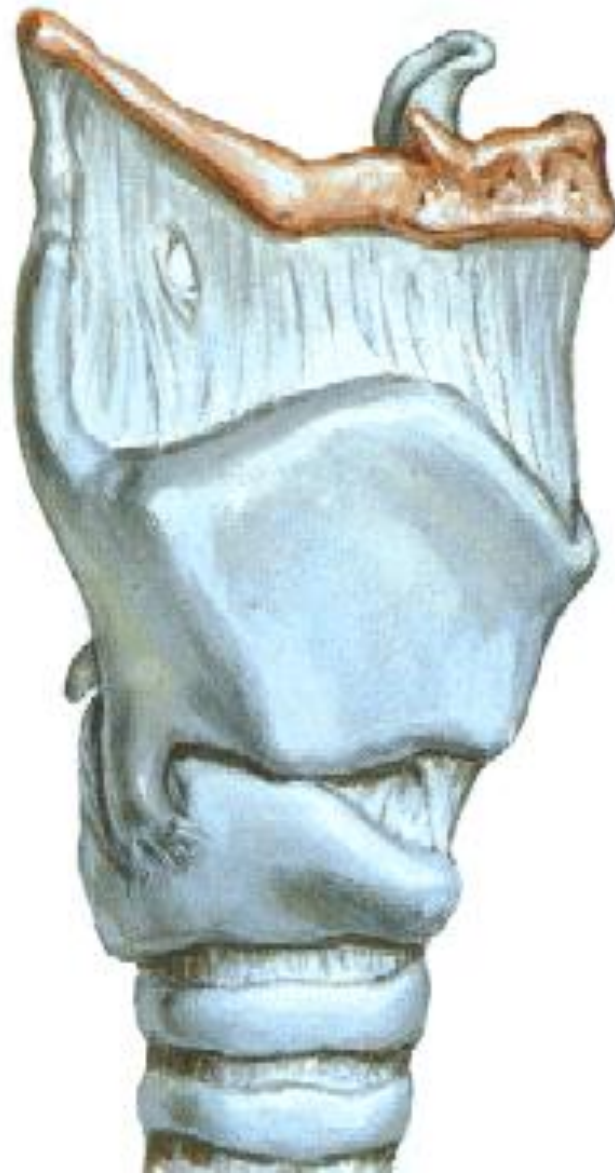Cartilagens da Laringe

Vista Posterior

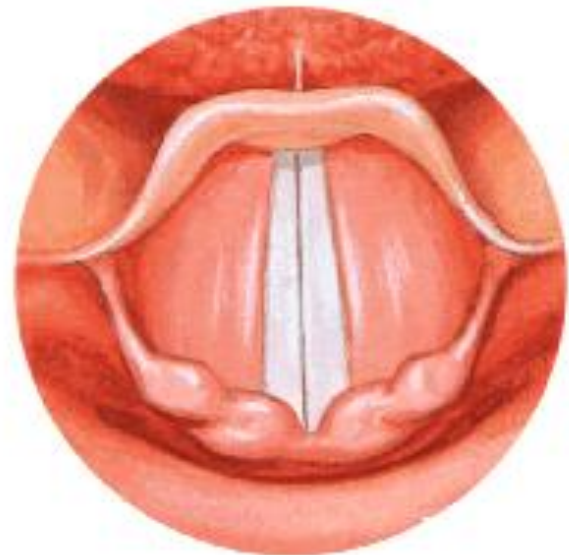
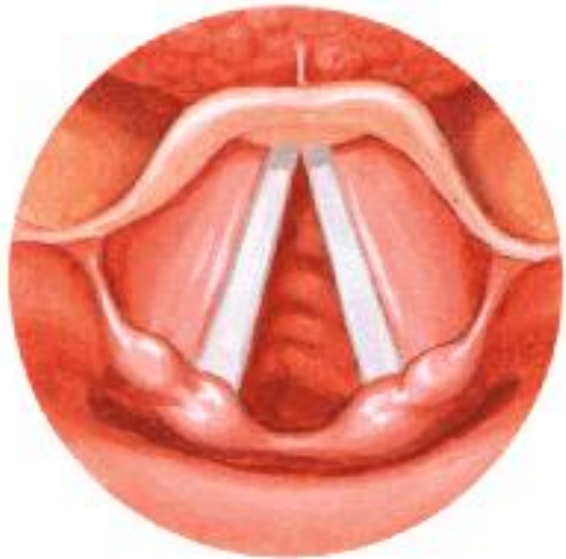


Cartilagens da Laringe

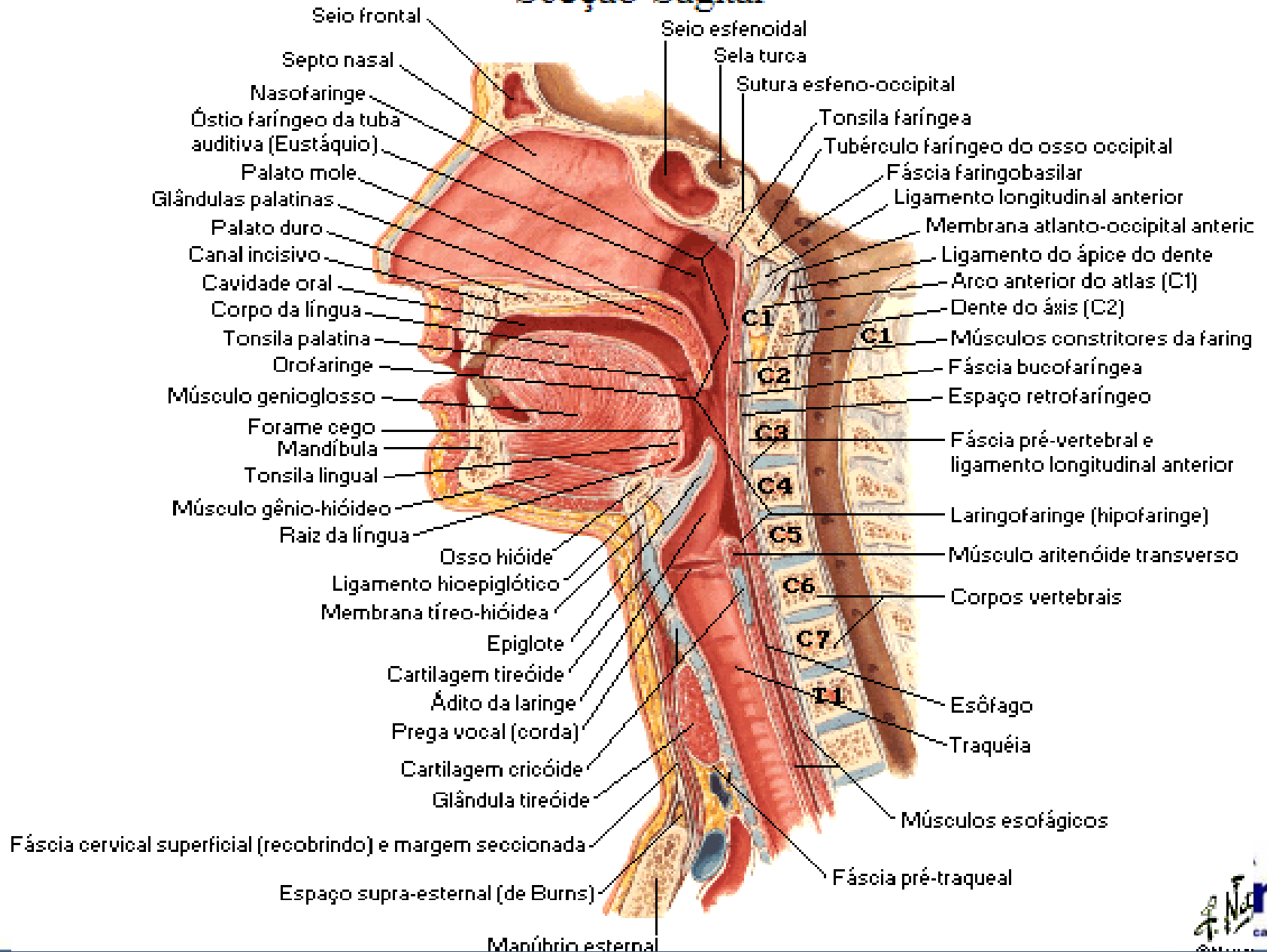
Vista Lateral Direita

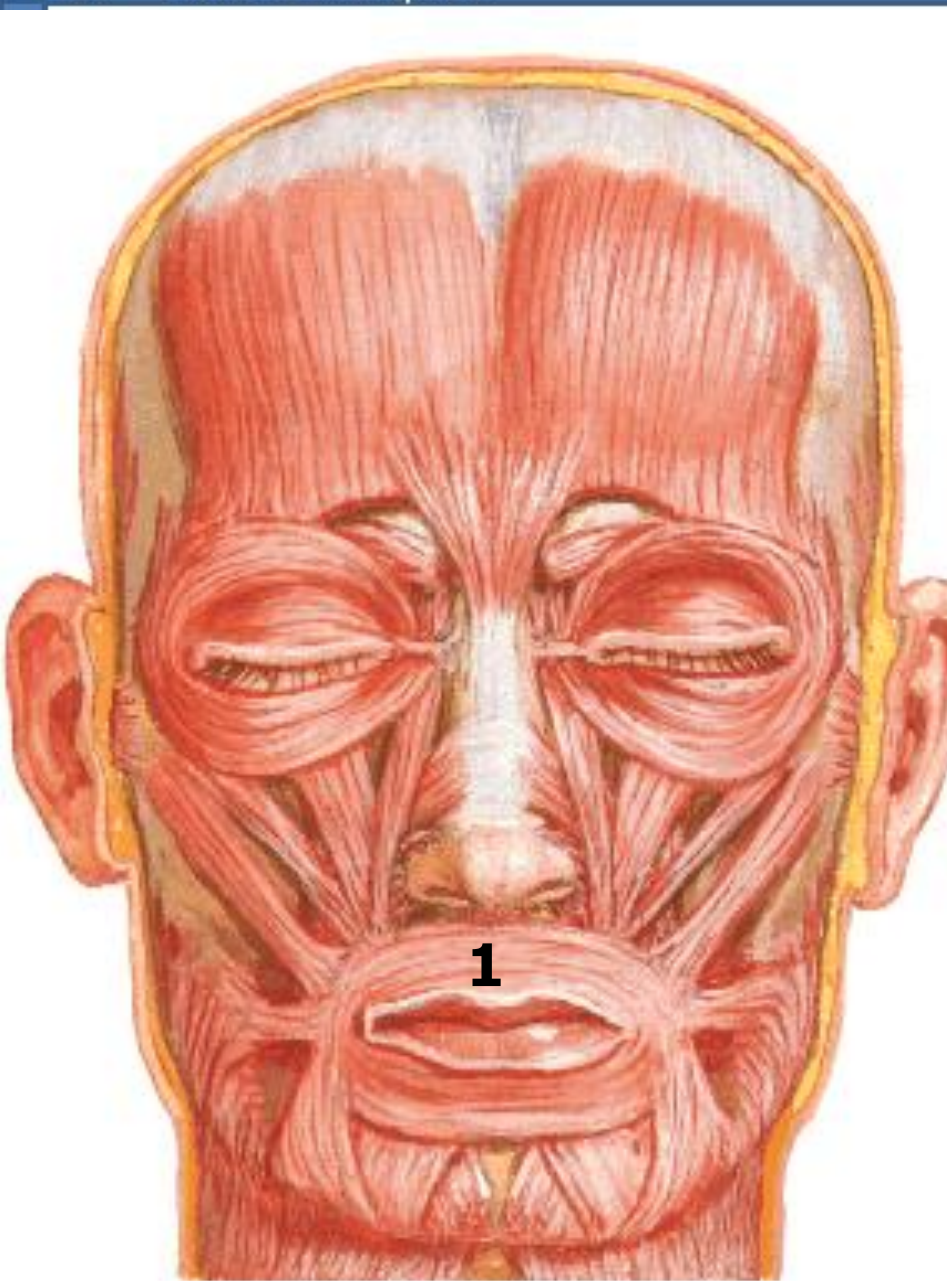


Inspiração e Fonação

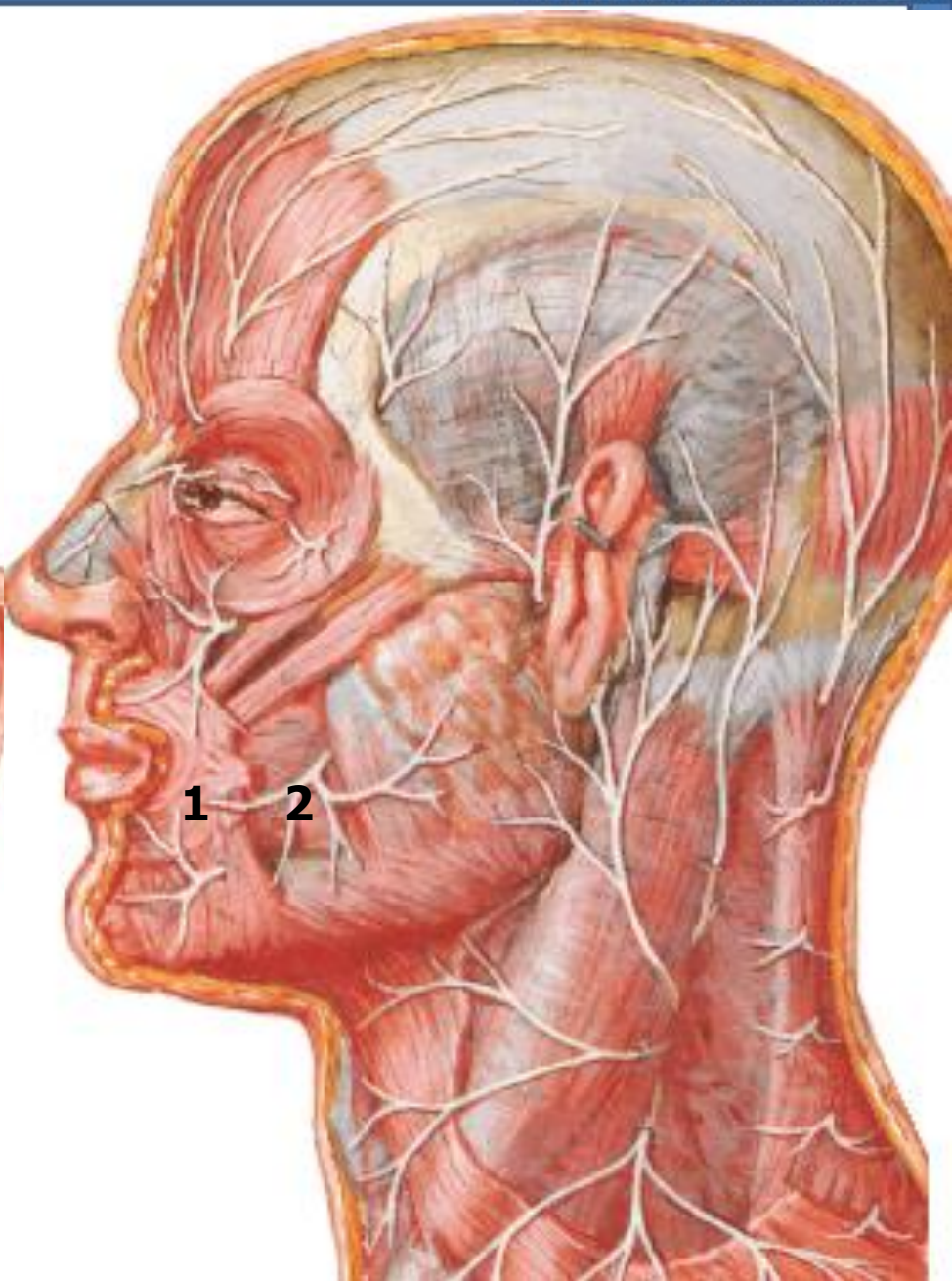


Secção Sagital

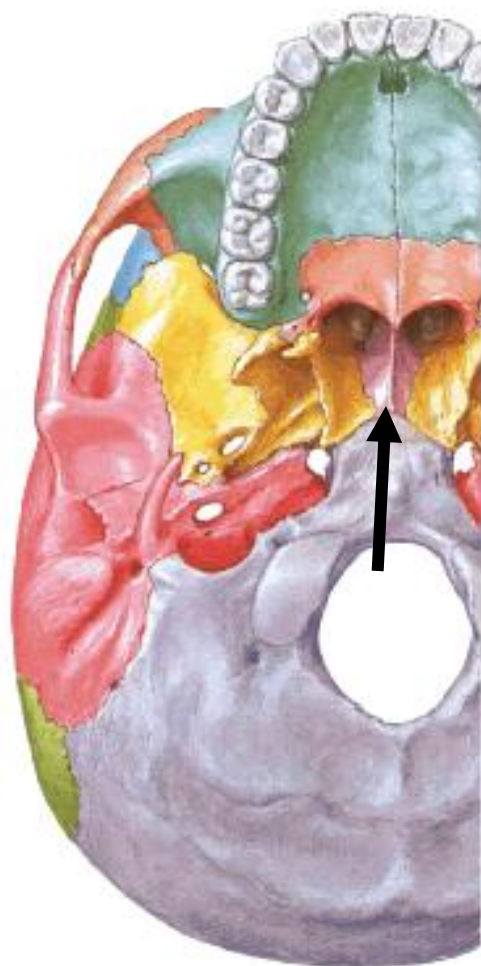



1 Músculo Orbicular da Boca

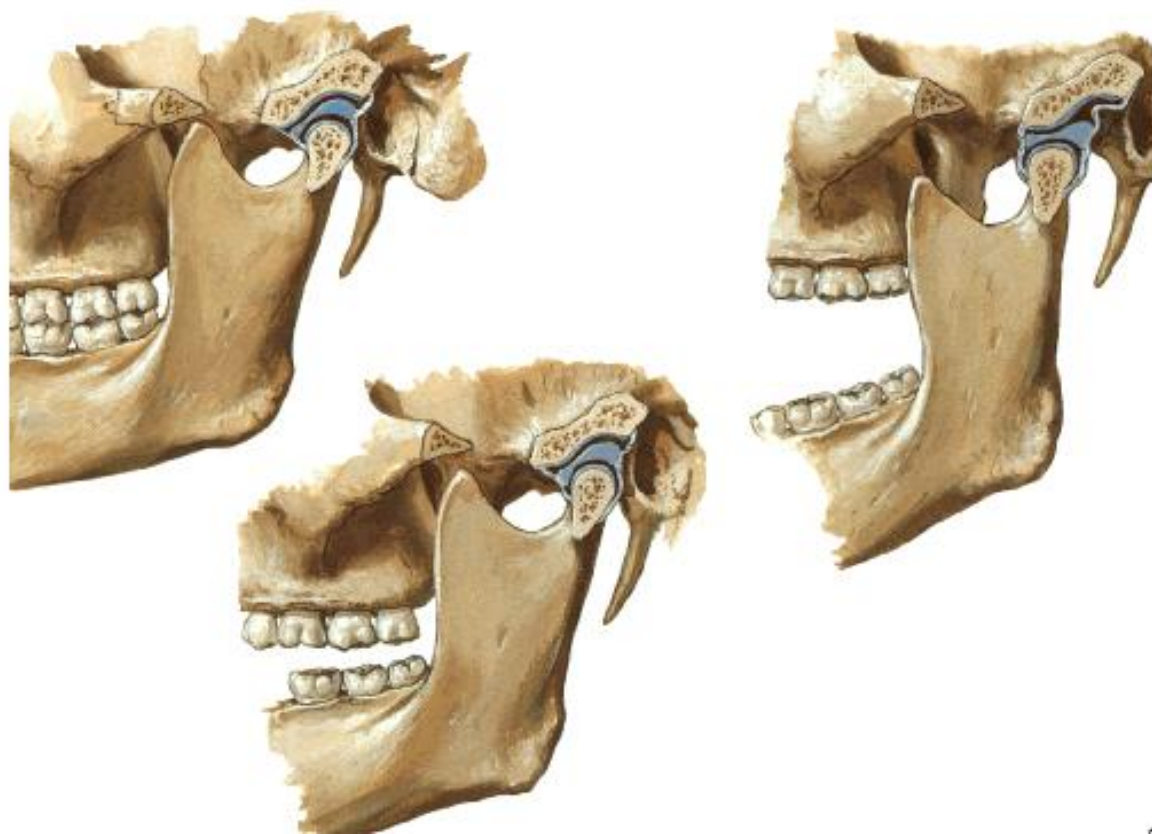


2 Músculo Bucinador

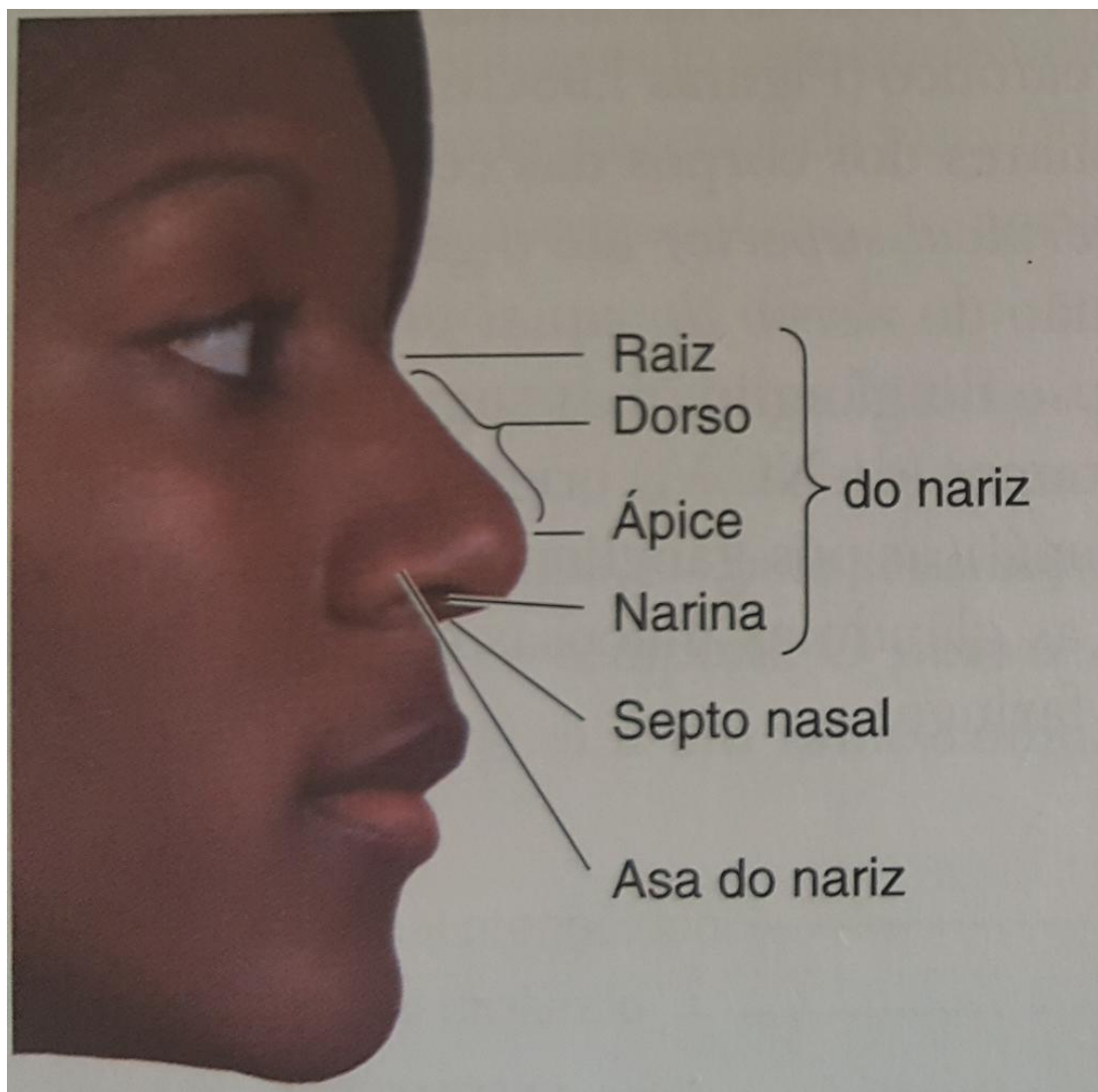


Articulação Temporomandibular

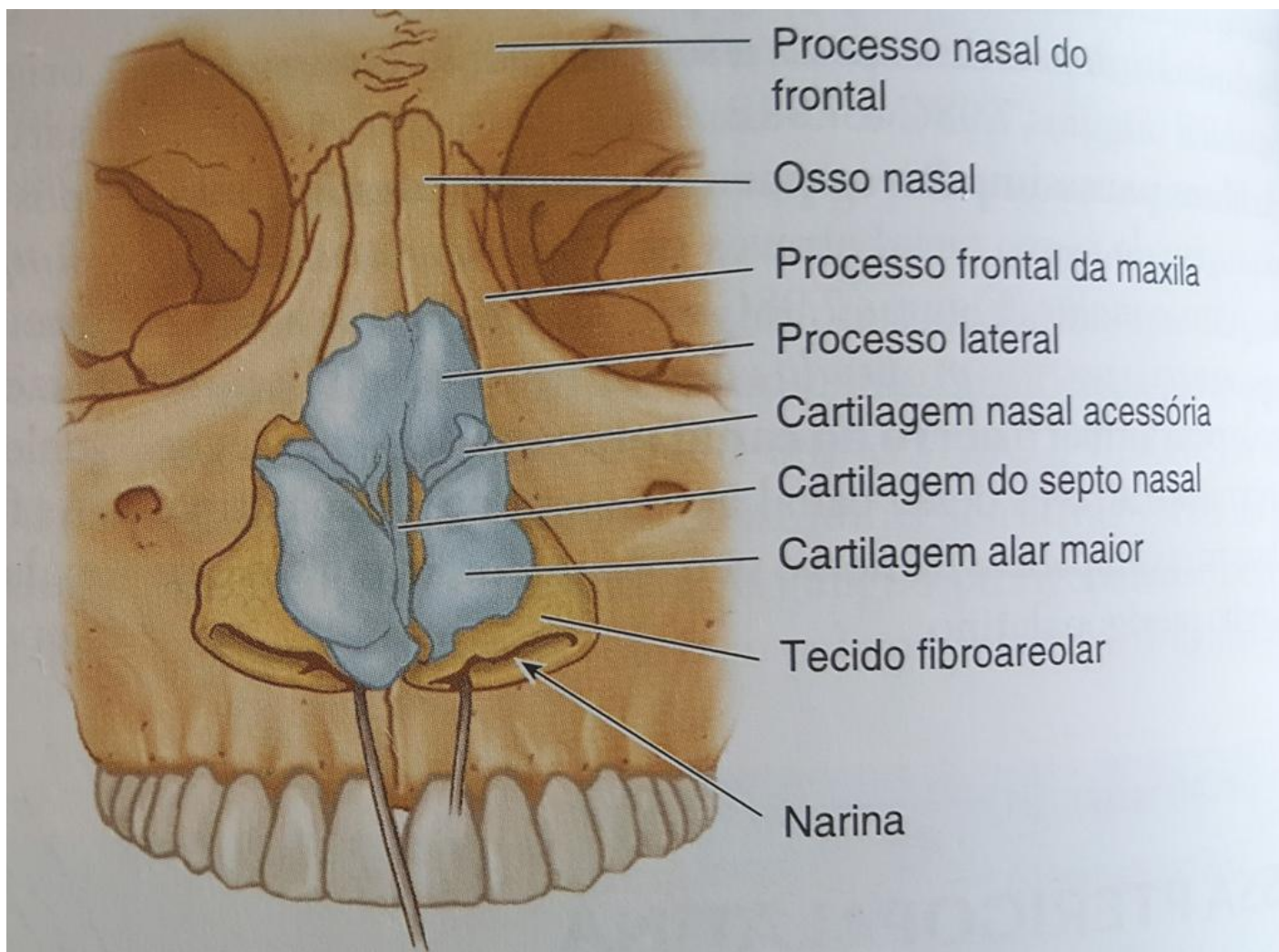
Ação Articular



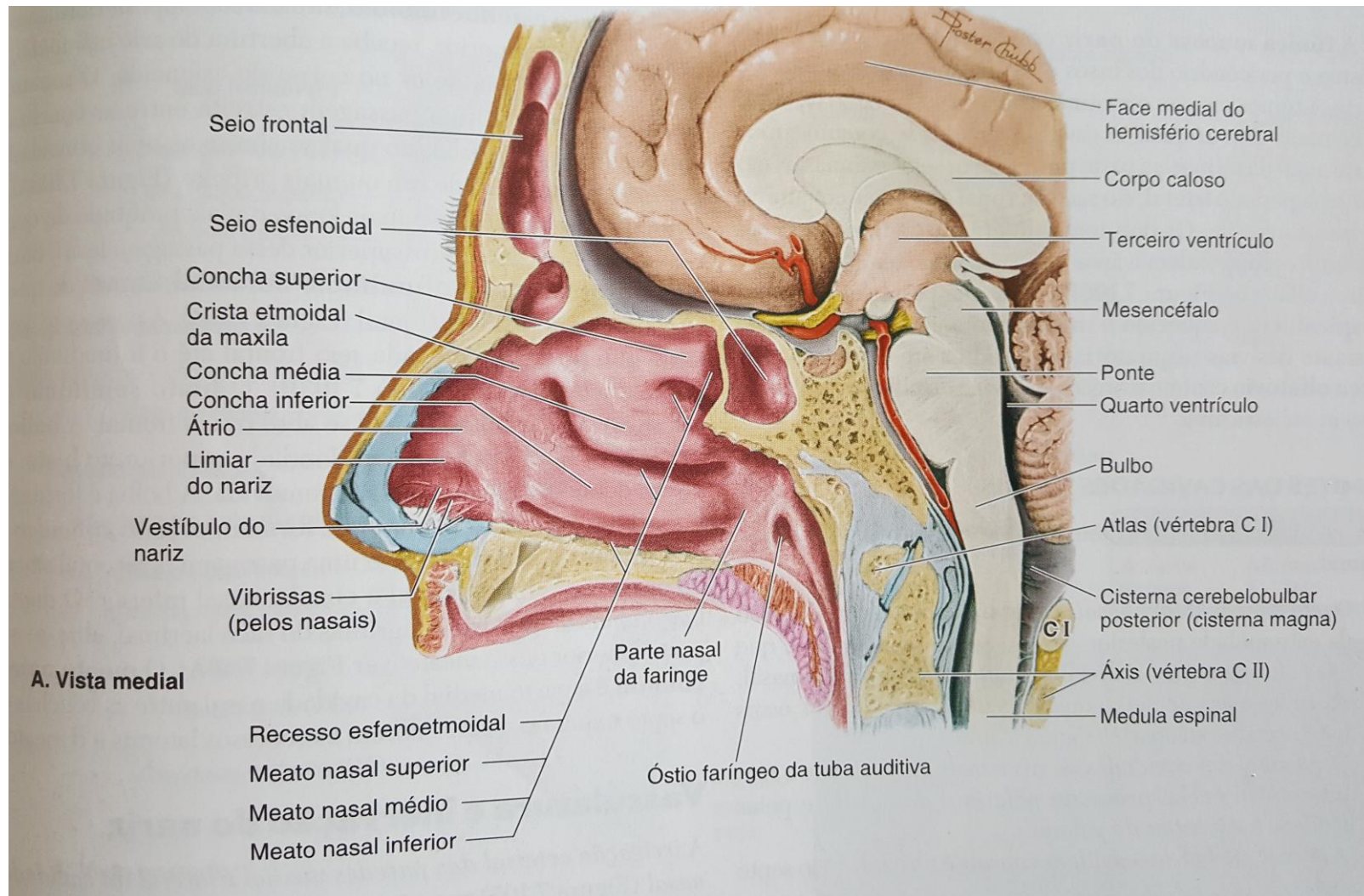
21



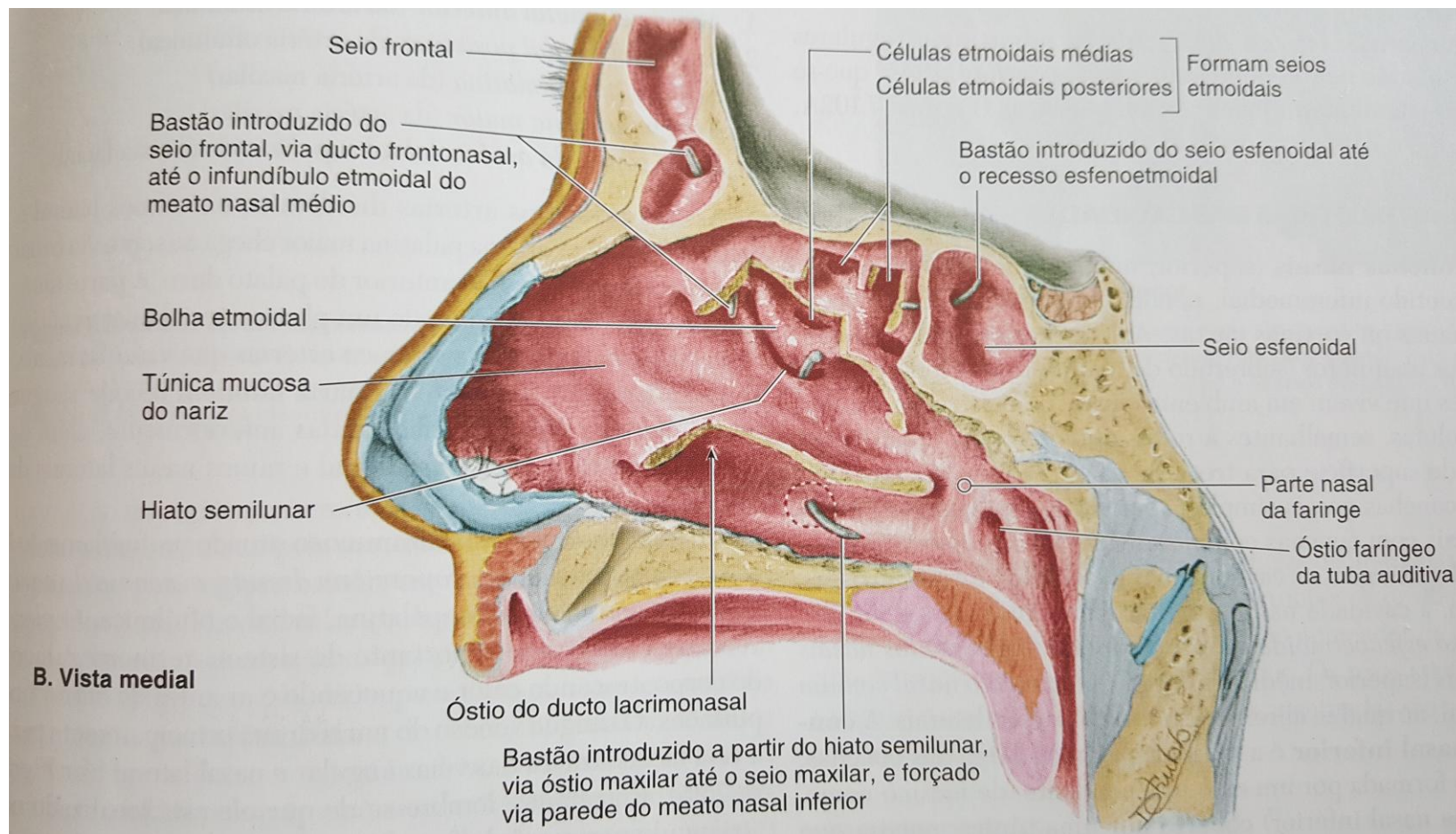
Fonte: Moore, k et al 2014



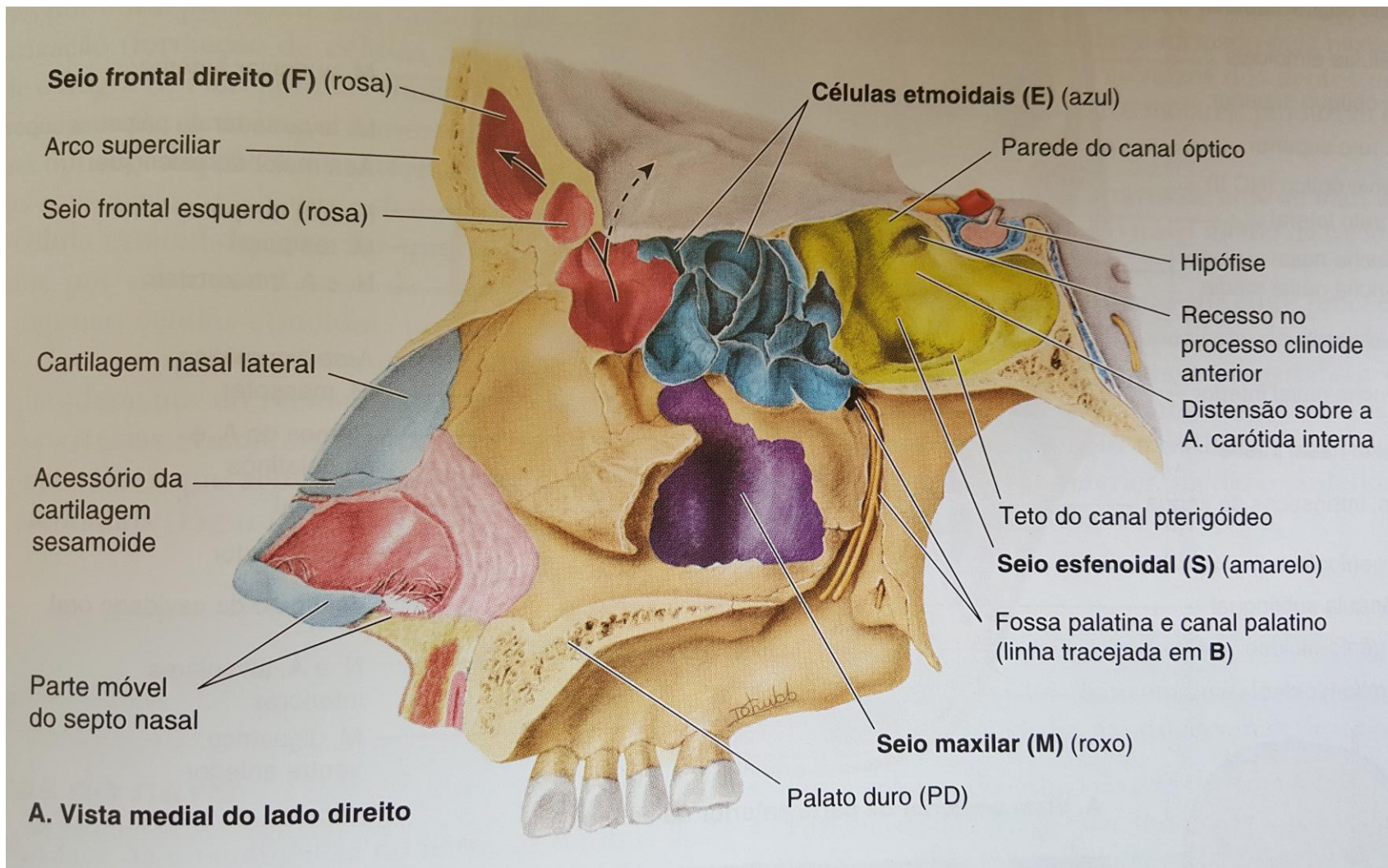
Fonte: Moore, k et al 2014



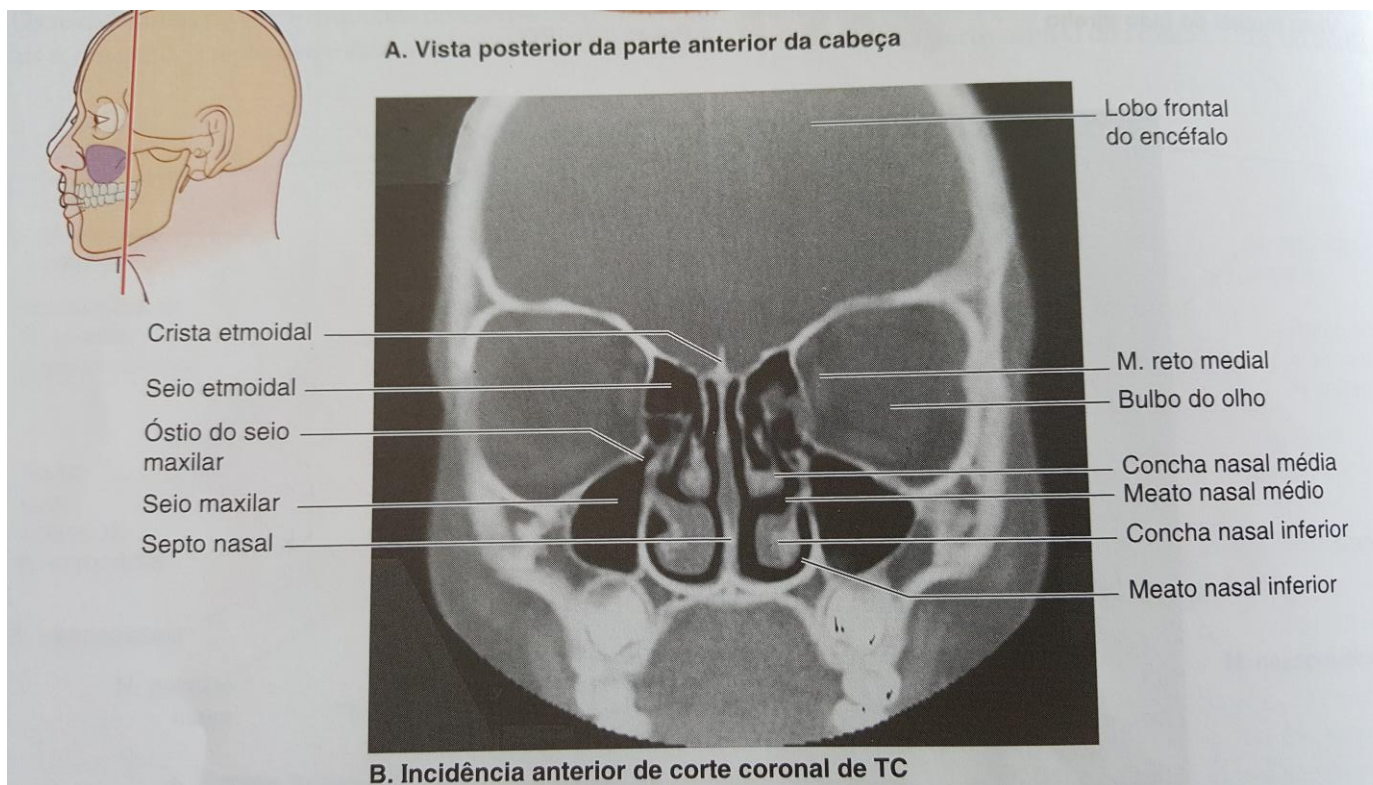
Fonte: Moore, k et al 2014



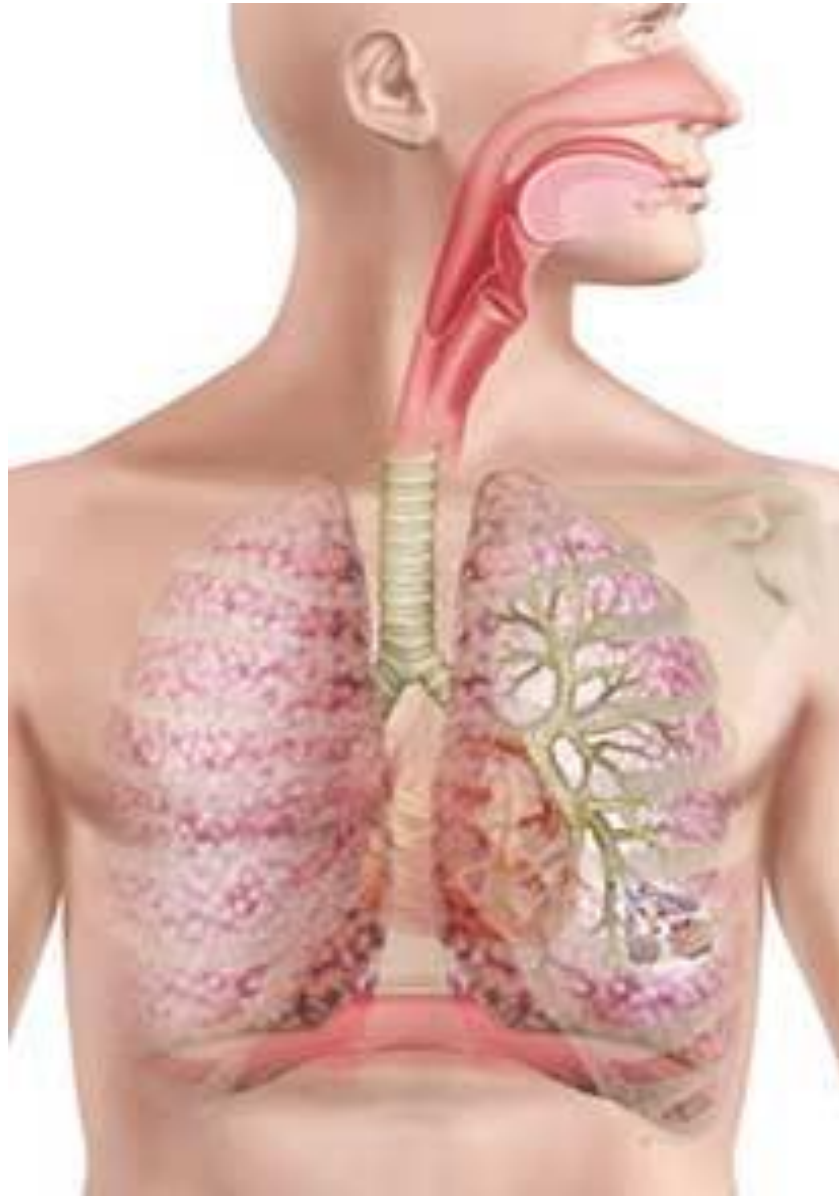Fonte: Moore, k et al 2014

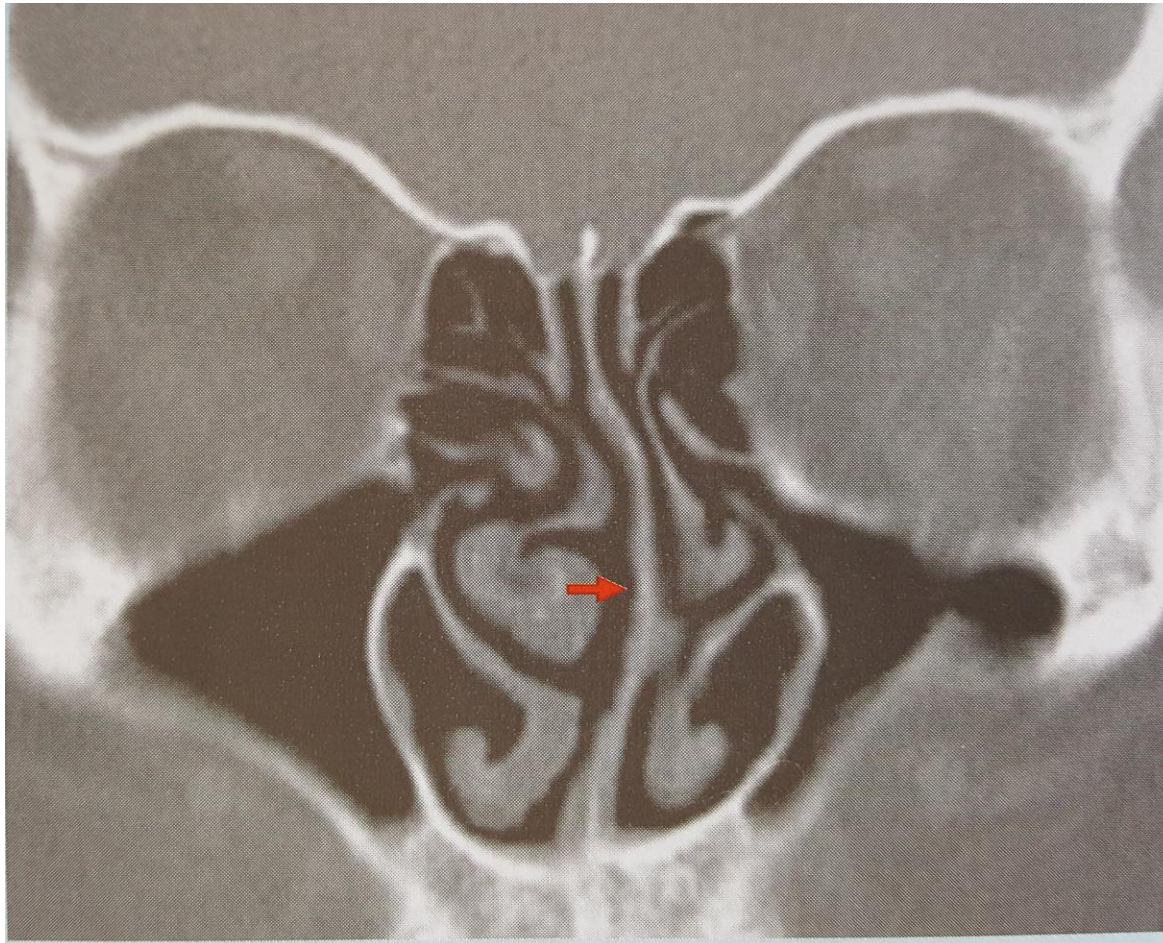


Fonte: Moore, k et al 2014




Fonte: Moore, k et al 2014





Fonte: Moore, k et al 2014

Referência Bibliográfica:



Bibliografia básica indicada:

- FRANK H. NETTER, MD - **Netter Atlas de Anatomia Humana** . Editora Elsevier.
- GRAY, Donald J. **Gray Anatomia**. 37ª Ed.; Rio de Janeiro: Guanabara Koogan, v.1 e 2, 1995.