



Research Article

Differential Diagnosis of Hirschsprungs Disease at a University Teaching Hospital in South-West, Nigeria

Nwokoro CC^{1*}, Olatunji AA², Adekambi AF³, Salami BA¹, Fatungase OM⁴, Jeminusi OA⁵, Olarenwaju AY⁶, Ogundele IO¹, Amosu LO¹

¹Department of Surgery, Olabisi Onabanjo University Teaching Hospital, Sagamu, Ogun State, Nigeria

²Department of Radiology, Olabisi Onabanjo University Teaching Hospital, Sagamu, Ogun State, Nigeria

³Department of Paediatrics, Olabisi Onabanjo University Teaching Hospital, Sagamu, Ogun State, Nigeria

⁴Department of Anaesthesia and Critical Care, Olabisi Onabanjo University Teaching Hospital, Sagamu, Ogun State, Nigeria

⁵Department of Community Medicine, Olabisi Onabanjo University Teaching Hospital, Sagamu, Ogun State, Nigeria

⁶Provlab, Foothills Medical Centre, 3030 Hospital Dr. NW, Calgary, AB T2N 4W4, Canada

*Corresponding author: Nwokoro CC, Department of Surgery, Olabisi Onabanjo University Teaching Hospital, Sagamu, Ogun State, Nigeria

Citation: Nwokoro CC, Olatunji AA, Adekambi AF, Salami BA, Fatungase OM, et al. (2022) Differential Diagnosis of Hirschsprungs Disease at a University Teaching Hospital in South-West, Nigeria. J Surg 7: 1572. DOI: 10.29011/2575-9760.001572

Received Date: 21 May, 2022; **Accepted Date:** 16 September, 2022; **Published Date:** 21 September, 2022

Abstract

Background: Hirschsprung's disease is a common abdominal condition managed by paediatric surgeons. It is responsible for about 25% of all newborn intestinal obstructions. Its diagnosis and recognition often pose serious challenges to the attending surgeon or physician because of the various modes of presentation and the symptoms may resemble other surgical or medical conditions in new-born, infants, childhood and adolescents.

Setting: Olabisi Onabanjo University Teaching Hospital, Sagamu, Ogun State.

Objectives: To discuss the differential diagnosis of hirschsprung's disease.

Materials and methods: Cases of intestinal obstruction, acute and chronic abdominal conditions admitted to the paediatric surgery unit on account of delayed passage of meconium, inability to pass meconium, vomiting, abdominal distension, irregular passage of faeces, recurrent or chronic constipation were recruited for this study between September 2008 and July 2018 prospectively. Their demographics, symptoms, signs, investigative modalities, provisional and definitive diagnosis were established and documented in a structured proforma. The obtained data were analysed using SPSS version 23, the results retrieved were presented in numbers, percentages, frequencies, bar charts and pie charts.

Results: Three Hundred and Seventy-nine suspected cases of hirschsprung's disease were recruited for this study. Out of these numbers of patients, 87 cases were confirmed histologically to have hirschsprung's disease and were further analyzed. 58 (66.6%) were males while 29 (33.4%) were females, a male to female ratio of 2-1. The patients were aged between 1 day and 16 years. 70 (80.4%) patients presented within one year of age. 17 (19.6%) patients presented beyond the age of one year. 68 (78.1%) had positive history of delayed passage of meconium at birth.

Keywords: Diagnostic challenges; Differential Diagnosis; Hirschsprung's disease; Institution; Nigeria; South-West; Tertiary

Introduction

Hirschsprung's disease is characterized by absence of ganglion cells in the mesenteric and submucosal plexuses of the large bowel most of the time. It is relatively common and occurs in 1:5000 – 1:7200 live births. [1] About 90% of infants with Hirschsprung's disease fail to pass meconium in the first 24 hours of life. [2] Although, most patients present in infancy and early childhood, some may not have symptoms until later in life. [2] The diagnosis is established in 15% within the first month of life, in 40-50% in the first 3 months, in 60% at one year of age and 85% by 4 years. [3] In developed countries, early presentation by patients ensure prompt diagnosis and intervention for the definitive treatment. [4] While in developing countries, late presentation with the attendant complications such as sepsis, intestinal perforation, necrotizing enterocolitis and intestinal obstruction further compound the diagnostic dilemma. [5] It is the most common cause of large bowel obstruction in the neonate as well as older children; occurring as an isolated condition in 70% of cases and may be associated with other congenital anomalies such as down's syndrome (trisomy 21) which is the most common chromosomal abnormality seen in about 10 percent of patients with hirschsprung's disease. [6,7] Other conditions that have been linked to hirschsprung's disease include congenital deafness, hydrocephalus, meckel's diverticulum, imperforate anus, ventricular septal defect, waardenburg's syndrome (pigment defects associated with deafness, neuroblastomas and ondine's curse (primary alveolar hypoventilation) [8,9].

Structural defects of the gastrointestinal tracts that resemble hirschsprung's disease include intestinal atresia, malrotation, volvulus, ano-rectal malformation and hypoplastic left colon syndrome. While functional and medical conditions with similar features as hirschsprung's disease are meconium ileus, meconium plug syndrome, drugs, electrolyte derangements, hypothyroidism and sepsis. [10] The differential diagnosis in newborn and older children pose serious clinical challenges in making a definitive diagnosis of hirschsprung's disease at presentation. A number of abdominal conditions which cause functional or mechanical intestinal obstruction could be easily excluded from hirschsprung's disease but conditions such as neonatal meconium ileus, meconium plug syndrome, distal ileal atresia and low imperforate anus often present diagnostic challenges in the first few days of life (Figure 1).

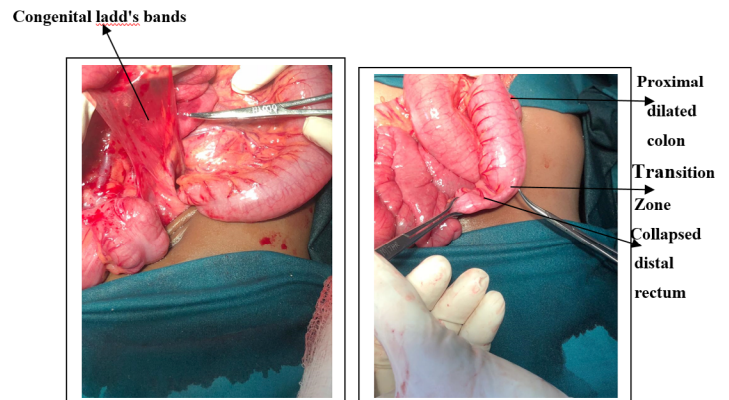


Figure 1: Showing hirschsprung's disease co-existing with malrotation.

Hirschsprung's disease is a possible differential diagnosis in any child with an history of constipation regardless of age. However older children with motility disorders generally referred to as chronic idiopathic intestinal pseudo-obstruction present with similar symptoms and radiographic findings as hirschsprung's disease. These disorders are classified according to their histological characteristics into visceral myopathy, visceral neuropathy and Intestinal Neuronal Dysplasia (IND). [11-13] To confirm the diagnosis of hirschsprung's disease and differentiate it from the above mentioned conditions, diagnostic modalities such as plain abdominal x-rays, contrast enema (water soluble), anorectal manometry and rectal biopsy are employed towards achieving a definitive diagnosis and excluding other congenital abdominal conditions whose presentations resemble that of hirschsprung's disease. [14,15] This study was undertaken to identify the common abdominal conditions in children that simulate the clinical presentation of hirschsprung's disease which make the definitive diagnosis of hirschsprung's disease challenging.

Methodology

Information obtained from the recruited patients who presented with features of intestinal obstruction during the study period were entered into a structured proforma. These data included age at presentation, presenting complaints, duration of complaints prior to presentation to the paediatric surgical unit, findings on physical examination and results of investigations carried out were also documented, provisional diagnosis and histologically confirmed cases of hirschsprung's disease. Diagnostic modalities used to investigate these patients were plain abdominal radiograph, abdominal ultrasonography, barium enema and full thickness rectal biopsy.

Study Population

Patients who presented to the paediatric surgical unit with complaints of delayed passage of meconium, irregular bowel movement, chronic or recurrent constipation, vomiting, abdominal distention and failure to thrive (Figures 2,3).

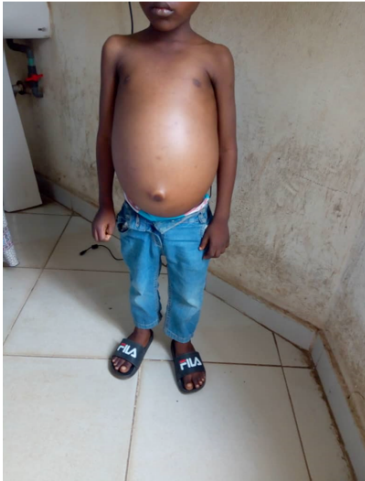

Figure 2: Showing abdominal distention from chronic constipation.

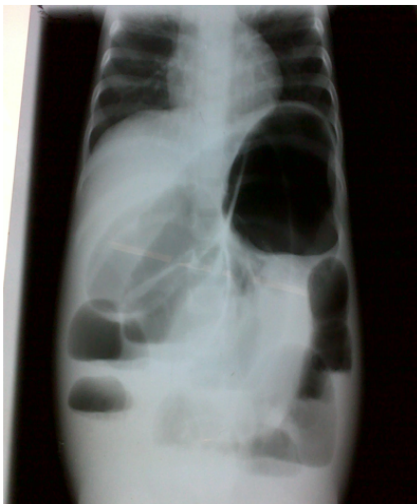


Figure 3: Showing features (step ladder pattern fluid air-level distribution) of intestinal obstruction.

Inclusion Criteria

- Patients aged between 1 day and 16 years
- All cases of childhood intestinal obstruction

- Acute and chronic abdominal conditions

Exclusion Criteria

- Patients aged above 16 years
- Patients who discharged against medical advice
- Patients who did not complete prescribed confirmatory investigations

Limitation of Study: Lack of facilities for frozen section.

Data Entry and Analysis: Data entry was done using word excel and analysis with SPSS version 23. The results were presented in the form of numbers and percentages, frequencies, bar charts and pie-charts.

Results

Three Hundred and Seventy-nine suspected cases of hirschsprung's disease were recruited for this study. Two hundred and ninety-two patients were due to other causes such as neonatal sepsis in 142 (48.6%) cases, intestinal atresia in 52 (17.8%) patients, anorectal anomalies in 42 (14.4%) patients, duodenal atresia 30 (10.3%) and pyloric stenosis 26 (8.9%) (Table 1).

S/N	Diagnosis	Frequency (n=292)	Percentage (%)
1.	Neonatal sepsis	142	48.6
2.	Intestinal atresia	52	17.8
3.	Anorectal anomalies	42	14.4
4.	Deodenal atresia	30	10.3
5.	Pyloric stenosis	26	8.9
	Total	292	100

Table 1: Showing the differential diagnosis of hirschsprung's disease.

Out of these number of patients, 87 cases were confirmed histologically to have hirschsprung's disease and were further analyzed. 58 (66.6%) were males while 29 (33.4%) were females, a male to female ratio of 2-1. The patients were aged between 1 day and 16 years. 70 (80.4%) patients presented within one year of age. 17 (19.6%) patients presented beyond the age of one year. The prominent presenting complaints in the confirmed cases of hirschsprung's disease were delayed passage of meconium at birth 60 (69.1%). Other features present were infrequent bowel motion 12 (13.8%), progressive abdominal distension 7 (8.0%), vomiting 5 (5.7%), and failure to thrive 3 (3.4%) (Figure 4).

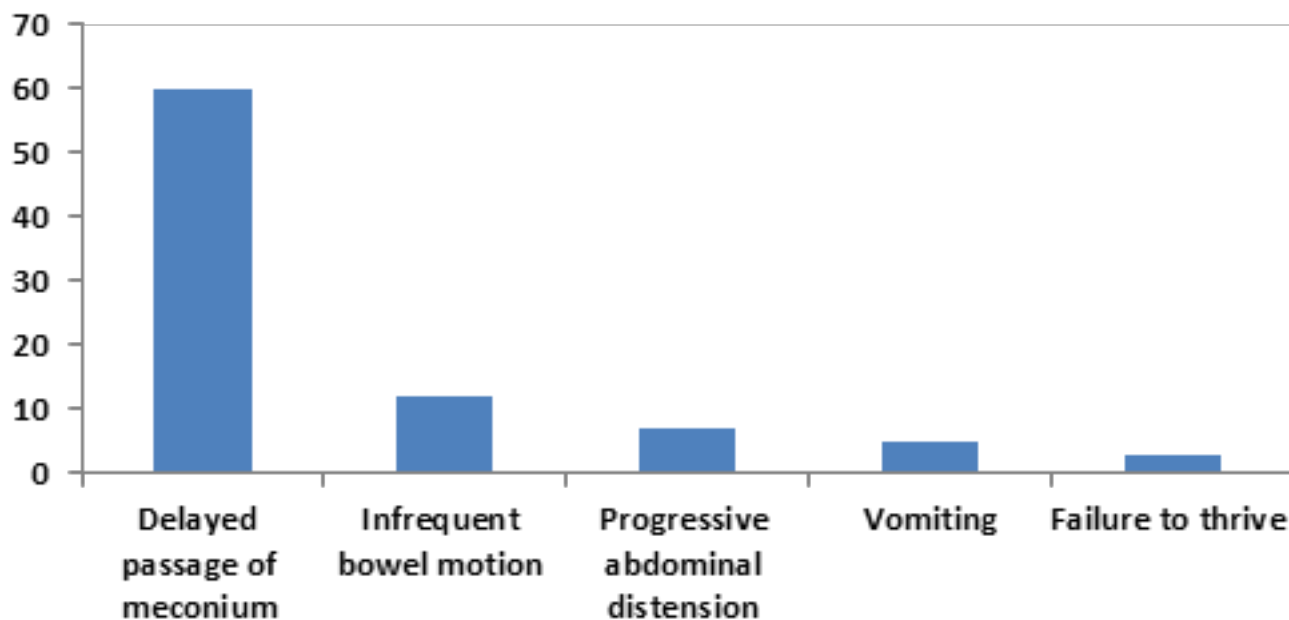


Figure 4: Showing distribution of symptoms in confirmed cases of hirschsprung's disease.

Eight patients presented with complicated disease such as necrotizing enterocolitis in 5 (62.5%) patients while 3 (37.5%) patients had intestinal perforation. Other congenital anomalies associated with hirschsprung's disease were down's syndrome in 4 patients, congenital heart disease in 2 patients and hypospadias in 1 patient (Figure 5).

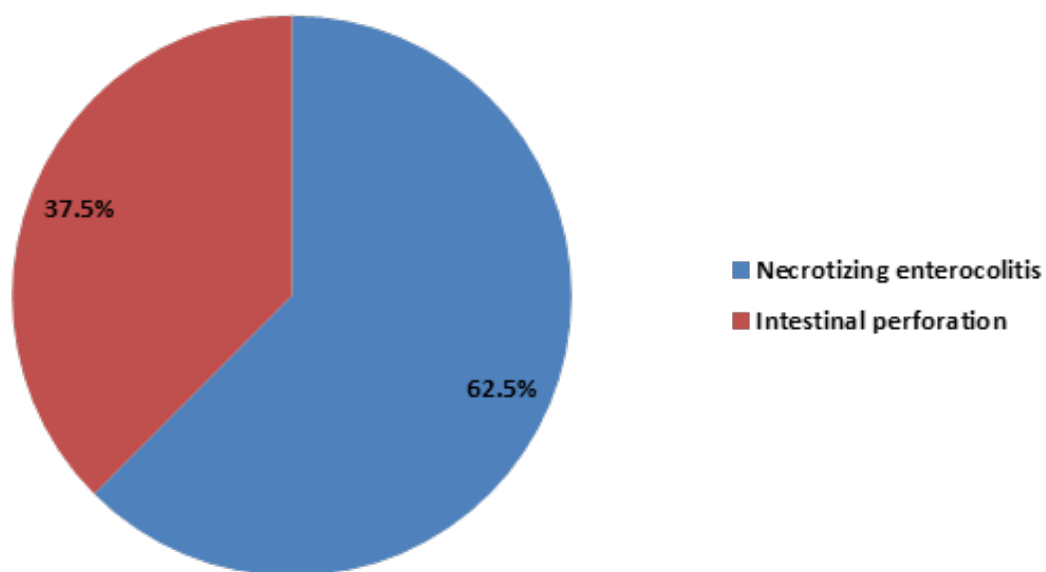


Figure 5: Showing distribution of complications of hirschsprung's disease.

Discussion

Hirschsprung's disease results from a disturbance of the nervous system. It is attributed to aganglionosis or arrest of the cranio-caudal migration of the neural crest cells within the gastrointestinal tract. Usually classified as ultra short segment which affects the sphincteric region and classic hirschsprung's disease which is limited to the recto-sigmoid segment and accounts for 80% of cases. Long-segment disease accounts for the remaining 20% of aganglionosis which extends proximal to recto-sigmoid region. Total colonic aganglionosis accounts for 3-10% of cases. Total intestinal aganglionosis may be seen in 1% of cases [10,16].

In our study, the most common differential diagnosis of hirschsprung's disease was neonatal sepsis, others were intestinal atresia, anorectal anomalies, duodenal atresia and pyloric stenosis. Similar observations to our findings have been made by some authors. [11,12] We had a predominance of male patients most of whom presented within one year of birth. This finding is in consonance with the reports of other researchers. [12,13] Most of our patients presented during infancy, however, some studies in Nigeria have reported predominant presentation of cases beyond the age of one year. [17,18] Complicated cases of hirschsprung's disease observed in our study were necrotizing enterocolitis, and intestinal perforation with peritonitis. Reports from other centres have found similar results. [19,20] The presence of associated congenital anomalies further worsened the diagnostic challenges as each anomaly presented with some typical features peculiar to that congenital malformation. The anomalies observed in our study were down's syndrome which has been reported as the commonest associated chromosomal anomaly of hirschsprung's disease, congenital heart disease and hypospadias. This is similar to the observations of other authors [20,21].

Misunderstanding of symptoms, findings on physical examination and diagnostic difficulties make hirschsprung's disease one of the most challenging diagnostic dilemmas in paediatric surgical practice. This is mainly due to different ways of interpreting the history, findings of physical examinations, results of investigative modalities and difficulties which arise as a result of its resemblance to other childhood acute and chronic abdominal conditions, complicated cases and associated congenital conditions especially those affecting the gastrointestinal tract which result to functional intestinal obstruction or mechanical intestinal

obstruction. [22,23] The predominant symptoms in our study was delayed passage of meconium and infrequent bowel movement. Symptoms range from neonatal intestinal obstruction to chronic progressive constipation in older children. Eighty percent of patients present in the first few months of life with difficult bowel movements, poor feeding and progressive abdominal distension. Rectal examination may demonstrate a tight anal sphincter and explosive discharge of stool and gas (fountain sign). Although most patients present in infancy and early childhood, some may not have symptoms until later in life and common symptoms in older children include chronic progressive constipation, recurrent fecal impaction, failure to thrive and malnutrition. One third of patients with Hirschsprung's disease present with enterocolitis associated with diarrhea rather than constipation.

However, a study carried out in Kenya discovered chronic constipation (90%) and abdominal distension (90%) as their most common symptoms. Other symptoms reported in this study included repeated vomiting (48% of children) and failure to thrive (29%). [24] The disease usually present in infancy, although some patients present with persistent severe constipation later in life. Symptoms in infants include difficult bowel movements, poor feeding, poor weight gain, and progressive abdominal distension. Early diagnosis is important to prevent complications such as enterocolitis and colonic rupture. A rectal suction or full thickness biopsy can detect hypertrophic nerve trunks and the absence of ganglion cells in the colonic submucosa thus confirming the diagnosis [25].

The diagnostic challenges or dilemma are worse in our environment where there are limited resources, funds and facilities needed for initial and early confirmation of diagnosis of hirschsprung's disease. Added to these are the challenges of late presentation with the attendant complications and the non-availability of facilities for frozen section which could improve the chances of achieving early and definitive diagnosis. [26] To resolve the diagnostic challenges and differential diagnosis, several diagnostic modalities were employed in our study to confirm the diagnosis of hirschsprung's disease and identify other conditions that simulate this disease. The diagnostic modalities employed were plain abdominal x-ray, barium enema using water soluble contrast medium, abdominal ultrasound, full thickness rectal biopsy and frozen section where available. Early presentation and diagnosis reduces the challenges caused by numerous differential diagnosis and improves outcome of management [27,28].

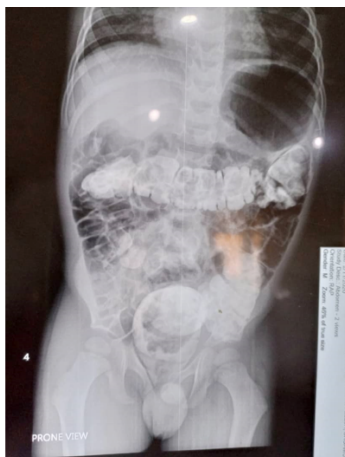

Figure 6: (barium enema) showing dilatation of proxima colon.

Conclusion

The peculiar ways of presentation of hirschsprung's disease and its resemblance to other acute and chronic abdominal conditions can pose a diagnostic dilemma to the surgeon. However, a high index of suspicion and use of the common imaging techniques and rectal biopsy would enhance early recognition, prompt diagnosis and quick intervention.

References

- Jennifer K (2006) Hirschsprung's Diseases. Diagnosis and management. *AM Fam physician* 74: 1319-1322.
- Moore SW, Zaahl MG (2008) A review of genetic mutation in familial Hirschsprung's disease in South Africa towards genetic counselling. *J pediatr surg* 43: 325-329.
- Chirdan LB, Uba AF (2006) Hirschsprung's disease presenting in the neonatal period in Jos, Nigeria. *Nig. J. of Surgical Research* 8: 62-64.
- Frykman, PK, Short SS (2012) Hirschsprung associated enterocolitis, prevention and therapy. *Semin pediatr surg* 21: 328-335.
- Donovan AN, Habra G, Somer S, Malone DE (1996) Diagnosis of Hirschsprung's disease. *AJR Am J Roentegenol* 167: 517-520.
- SOO YY (2002) Differential diagnosis of Hirschsprung's disease. *J Korean Assoc pediatr surg* 8: 54-61.
- Shu TC, Solomon CCC, Chin LL, Shew MS, Hsing CK (2016) Epidemiology of Hirschsprung's Disease in Taiwanese children: A 13-Year Nationwide population-based study. *Pediatr Neonatol* 57: 201-206.
- Savat F (2007) Diagnosis of constipation in children. *Ann Nestle* 65: 63-71.
- Leoning BVA (1993) Chronic constipation in children. *Gastroenterology* 105: 1557-1564.
- Liu S, Zou K, Song JA (2000) A study of ano-rectal manometry in patients with chronic idiopathic constipation. *J Tongji med univ* 20: 351-352.
- Bustor FF-Silva JM, Costa-Pinto EA, Fukushima E (2000) Role of anorectal manometry in the differential diagnosis of chronic constipation in children. *J pediatric* 76: 227-232.
- Sowande OA, Adejuyigbe O, Ademuyiwa O, Usang UE, Bakare TI (2006) Primary Swenson pull through in infants less than 4-months: preliminary report. *Niger J Surg* 8: 140-143.
- Ameh EH, Chirdan LB (2000) Neonatal intestinal obstruction in Zaria, Nigeria. *East Afr Med J* 9: 510-513.
- Colin R, Lee B (1995) Hirschsprung Disease. *Pediatrics in Review* 16: 1-11.
- Marielle RM, Carlos HMDS, Gustavo RF (2015) Late diagnosis of Hirschsprung's disease. *J coloproctol (Rio J)* 35: 178-181.
- K Ongeti, H Saidi, J Ogeng'o, M Tharao (2009) Experience with Hirschsprung's Disease at a Tertiary Hospital in Kenya. *Ann Afr Surg* 4: 8-12.
- Adesoji O, Christopher OB, Abdurazzak OL (2013) Primary Swenson's pull-through for adults Hirschsprung's disease: A report of two cases from Southwest Nigeria. *Arch Int Surg* 3: 169-172.
- Nasir AA, Adeniran JO, Abdur-Rahman LO (2007) Hirschsprung's disease: 8 years experience in a Nigerian Teaching Hospital. *J Indian Assoc Pediatr Surg* 12: 68-71.
- Amel A. Hashish (2005) Hirschsprung's disease in Adolescents and Adults. *Ann Pediatr Surg* 1: 72-78.
- Esayias W, Hawaz Y, Dejenje B, Ergente W (2013) Barium enema with reference to rectal biopsy for the diagnosis and exclusion of Hirschsprung's disease. *East cent. Afr. J. surg* 18: 141-145.
- Ogenti K, Saidi H, Ogengo J, Tharao M (2009) Experience with Hirschsprung's disease at a Tertiary Hospital in Kenya, *Ann Afr Surg* 4: 8-12.
- Chirdan LB, Uba AF (2010) Hirschsprung's disease presenting in the neonatal period in Jos, Nigeria. *Nigerian J Surg Res.*
- Tukasz S, Andrzej M (2014) Diagnosis of Hirschsprung's disease with particular emphasis on histopathology. A systematic review of current literature. *Prz Gastroenterol* 9: 264-269.
- Reda AZ (2019) Hirschsprung Disease: A Review. *Acad J Ped Neonatol* 8: 0015-0018.
- Emad G (1986) Hirschsprung's Disease: A Review. *Can Fam Physician* 32: 1521-1523.
- Chien-Ching L, Reyin L, Ming-Chou C, Peng-Hong Y, Shin-Ming C, et al. (2012) Clinical Impacts of Delayed Diagnosis of Hirschsprung's Disease in Newborn Infants. *J. Pedneo* 53: 133-137.
- Lawal S, Ibinaiye P.O, Olarinoye-Akorede S.A, Igashi J.B, Umdagas AH (2016) Late diagnosis of Hirschsprung's disease. *Sub-Saharan Afr J. Med* 3: 220-223.
- Reda AZ (2019) Hirschsprung Disease: A Review *Acad J Ped Neonatol* 2019.