

Treatment of Capillary Fragility in Subjects with Spontaneous Hematomas

Romano C¹, Costa M², Rapisarda M², Messina M² and Bertini M^{3*}

¹Department of Cardiology, Section of Angiology, Acireale Hospital, Provincial Health Centre of Catania, Catania, Italy

²Department of Cardiology, Acireale Hospital, Provincial Health Centre of Catania, Catania, Italy

³Laboratori Baldacci SpA, Department of Medicine, Via San Michele degli Scalzi, Pisa, Italy

Abstract

Introduction: The state of capillary fragility is characterized by an alteration of the normal endothelial function that can cause vessel rupture and the appearance of point haemorrhagic spots. The states of altered resistance definable as alterations in capillary fragility (ACF) can be determined by different causes; The use of aminaphthone normalizes the capillary resistance preventing the appearance of haemorrhagic pump.

Case presentation: An 18-year-old patient diagnosed with entry “widespread leg hematomas-suspected vasculitis” is treated with aminaphthone for a period of 3 months. The use of this drug has allowed a clear improvement in the clinical situation and disappearance of hematomas in the legs.

Conclusions: Therapy with aminaphthone, a powerful capillaroprotector used in the treatment and prevention of endothelial dysfunctions, has shown its effectiveness also in this case determining the absolute disappearance of spontaneous hematomas caused by a state of endothelial fragility.

Keywords: Microcirculation; Capillary fragility; Aminaphthone

Abbreviations: ACF: Alterations of Capillary Fragility; AMN: Aminaphthone

Introduction

The capillary and vascular fragility states are represented by alterations of the normal, physiological capillary resistance that can lead the subject, which is affected, to organic lesions such as vessel rupture or to para-physiological alterations of the vessel's function as altered plasma filtration, fluids or cells that cause edema or local inflammation. We can distinguish different forms of capillary fragility alterations (ACF) including: alterations of the capillary wall, alterations of the content (blood, plasma, thrombus, etc.), pressure alterations and alterations of vessel nutrition (pathologies or alterations of the vasa vasorum). Capillary fragility is manifested by the appearance of extensive point hemorrhagic spots (petechiae, bruises and hematomas), especially on the face and legs determined by the tendency of the capillaries to spontaneously break, releasing the blood content in the surrounding area. The states of altered resistance defined as alterations in capillary fragility (ACF) can be determined by different causes and be associated with many diseases; these can be congenital, alterations caused by drugs, microtraumas or other diseases such as collagen diseases.

At the capillary level there is an alteration of the normal endothelial function, which involves the loss of some structural and/or functional characteristics. The alterations of the capillary wall are determined by a series of mechanisms often associated each other in sequences not always easily defined. In physiological conditions, so that the capillaries are perfused, it is necessary a harmonic regulation between the various districts of the microcirculation. This regulation, besides, being affected by the residual energy of microcirculation downstream of the resistance vessels, is achieved thanks to a contraction-deconstruction mechanism of myocytes and capillary endothelial cells. The phenomenon occurs cyclically and determines the mechanism of vasomotility that is realized thanks to the participation of all the vessels of intracellular, hormonal, neurogenic control systems, etc. From a pathophysiological point of view the consequence of vasomotility is the cyclic variation of the quantity of blood present in the single micro-vessel and in the system, defined as flux variation.

As soon as the blood passes the resistance vessels (the arterioles), both due to the overall increase in the diameter of the vascular bed,

to the friction, and to the contraction-decontraction process, much of the mechanical energy present in macro circulation is lost, and the blood reaches the capillaries at low pressure and low speed, so that emotional exchanges are possible. The capillaries are not suitable to sustain by their nature a pulsatile flow (the pulsatility is not transmitted, normal conditions, at capillary level) for their structural characteristics. The mechanical action of the residual pulsatility, transmitted to the capillary, combined with a higher capillary pressure at the arteriolar level causes a “disruption” of the puzzle composition of the endothelium with openings of new fenestrations of the capillaries. The effects of this situation are of two types:

a) The capillary becomes glomerulized, like a renal capillary, increasing its exchange surface causing an abnormal increase in normal filtration and causes a “forced” filtration of elements that normally do not pass the capillary barrier, such as proteins, thrombotic and cell boundaries.

b) The capillary “ultra-filter” and the result is a pseudo-inflammatory agglomeration at the level of the extra capillary space that triggers a chain reaction, possibly resulting in fibrosis and micro thrombosis determined both by external compression of the capillaries and by the presence of thrombogenic substances in the interstitial tissue or inside the capillary itself.

The presence of a large quantity of liquids in the peri-capillary space causes an increase in the extra-tissue pressure and therefore significantly compresses the vasa vasorum (at the level of the larger vessels) and the capillaries, altering their nutrition and, subsequently, their functionality. This causes a series of significant and very similar microcirculatory alterations in different pathologies, for example in

***Corresponding author:** Bertini M, Laboratori Baldacci SpA, Department of Medicine, Via San Michele degli Scalzi 73, 56124 Pisa, Italy, Tel: 39050313271; E-mail: bertini@baldaccilab.com

Received May 16, 2018; Accepted July 30, 2018; Published July 31, 2018

Citation: Romano C, Costa M, Rapisarda M, Messina M, Bertini M (2018) Treatment of Capillary Fragility in Subjects with Spontaneous Hematomas. J Clin Case Rep 8: 1152. doi: [10.4172/2165-7920.10001152](https://doi.org/10.4172/2165-7920.10001152)

Copyright: © 2018 Romano C, et al. This is an open-access article distributed under the terms of the Creative Commons Attribution License, which permits unrestricted use, distribution, and reproduction in any medium, provided the original author and source are credited.

those defined as high perfusion microangiopathies. The capillary wall consists of a single layer of endothelial cells surrounded by the basement membrane.

The endothelium is responsible for varied and complex functions. First, endothelial cells act as a selective barrier to the passage of molecules and cells between blood and organs. Among its various tasks, the endothelium also participates in the regulation of the calibre of the vessels, the arterioles. Among the most important substances released by the endothelium there is undoubtedly nitric oxide (NO), a powerful vasodilator released by different stimuli, mechanical or chemical. Among the substances that induce a narrowing of the vessels (vasoconstrictors), there are the endothelin-1 and the angiotensin II, which are also able to modify the structure of the vessels by stimulating cell growth. Finally, the endothelium also plays a role in blood coagulation, a defense mechanism of the organism that allows to limit, until to stop them completely, the blood losses due to serious lesions of the blood vessels. This is a very complex mechanism, which involves many factors and it is regulated in a very fine manner. In this context, the endothelium has the task of recalling at the site of rupture the platelets, blood elements capable of accumulating and forming a real cap. In pathological conditions, the endothelium changes its characteristics: not only becomes more susceptible to damage, but also facilitates its worsening, promoting inflammatory processes and the formation of thrombi. In these conditions, the endothelium loses control of the permeability of vascular blood vessels and of the adhesion of circulating leukocytes [1,2].

This case-report is referred to the results obtained by using aminaphthone (2-hydroxy-3-methyl-1,4-naphthoquinone-2-aminobenzoate), a powerful capillary protector. The drug has been safely administered at two 75 mg cps/daily [3].

In a subject that presents capillary fragility, it is certain that the integrity of the vascular bed is essential to prevent the onset of so-called spontaneous haemorrhages. It has been studied, in the past, that aminaphthone is able to reduce the time of bleeding even in small vessels, for example it lowers the latter in rabbit ear already at a dose of 0.1 mg/kg [4].

Aminaphthone normalizes the capillary resistance preventing the appearance of the induced haemorrhagic phallus by the local administration of antiplatelet serum and reduces the capillary hyperpermeability caused by the local application of chloroform [5]. Aminaphthone reduces the time and the amount of capillary haemorrhage without exerting any direct or indirect effect on coagulation, in fact it does not modify the coagulation or the prothrombin time [6]. Therefore, aminaphthone significantly reduces the appearance of petechiae [7]. Aminaphthone has recently been demonstrated to reduced endothelial expression of VCAM and ELAM [8], of ET-1 [9-11] and of pro-inflammatory endothelial cytokines.

Case Presentation

A young woman shows up at the Angiology Department of the Department of Cardiology of Acireale Hospital in Catania from September 2015 to January 2016. The G.M. patient, 18-years-old (24/08/1997) Figure 1 shows up at this surgery on 16/09/2015 and performs the video capillaroscopic control whose indication is: "diffused hematomas in the legs - suspected vasculitis".

At the video capillaroscopic exam, arrangement of the palisade: regular with focal absences, number of capillaries: >9/mm, capillary length: >150 microns (Spilungone loops>400 microns), tortuosity:

<20%, complex dysmorphia: <10%, type of dysmorphism: (branched, eight-serpentine loops), ectasia (>20 microns): <20%, Mega capillaries (>50 microns): Absent, spontaneous microhemorrhages: SI (with pearls), thrombosed loops: No, Edema: Yes, transparency: Reduced, Visibility of sub-papillary venous plexus: No, Avascular Areas: SI (pseudo-vascular), Flow characteristics: slowed down (Figure 2). Conclusions: Non-specific framework compatible with microangiopathy.

The patient takes only aminaphthone (2-hydroxy-3-methyl-1,4-naphthoquinone-2-aminobenzoate) for 90 days according to the aforesaid protocol: 3 cps/day for 30 days and subsequently as maintenance 2 cps/day for 60 days. At 30 days the patient presented an improvement in the clinical situation (Figure 3).

On the video capillaroscopic exam, framework improved significantly compared to the previous one: Arrangement of the palisade: regular with focal absences, Number of capillaries:>9/mm, Capillary length: >150 microns (Spilungone loops>400 microns), Tortuosity: <20%, Complex dysmorphias: <10%, Type of dysmorphism: (branched, eight, serpentine loops), Ectasias (>20 microns): <20%, Megacapillaries (>50 microns): absent, spontaneous microhemorrhages: yes, thrombosed loops: No, Edema: No, Transparency: slightly reduced, Visibility of sub-papillary venous plexus: yes, Avascular Areas: no, Flow characteristics: slowed down (Figures 4 and 5). Conclusions: A specific framework.

After 90 days of therapy, only and exclusively, with aminaphthone it is highlighted:

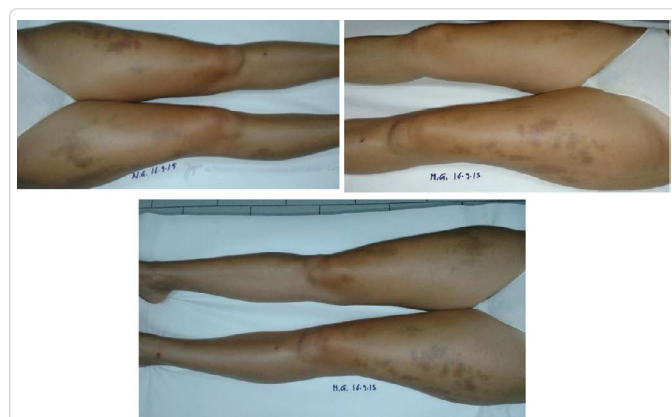


Figure 1: Diffused hematomas in the legs-suspected vasculitis.

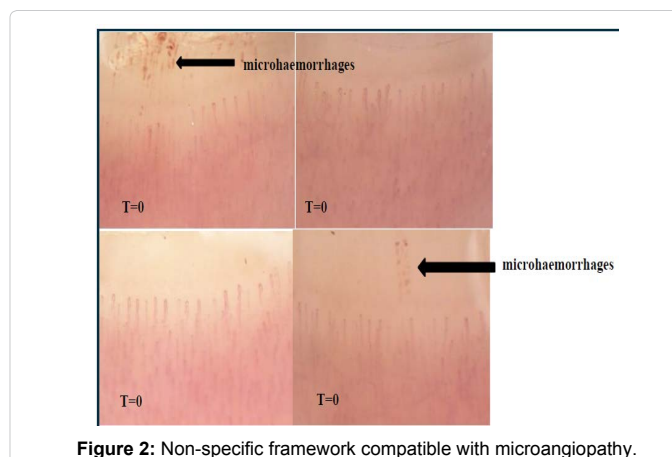


Figure 2: Non-specific framework compatible with microangiopathy.

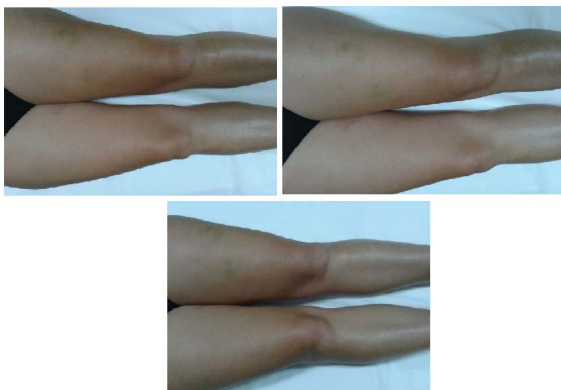

Figure 3: Patient presented an improvement in the clinical situation.

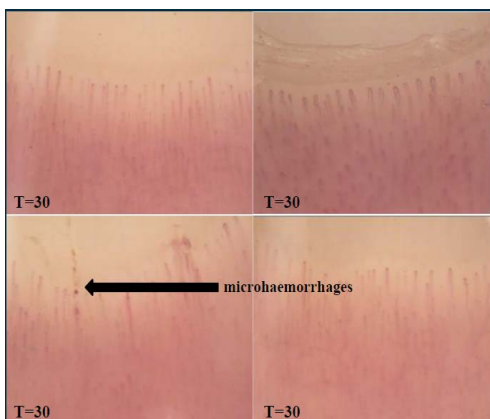


Figure 4: Aspecific framework.

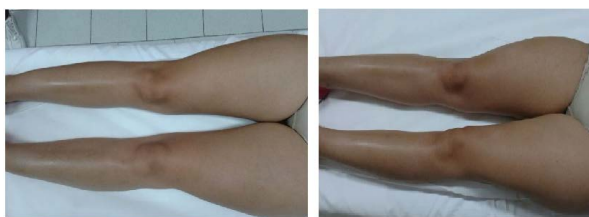

Figure 5: Clear reduction of edema.

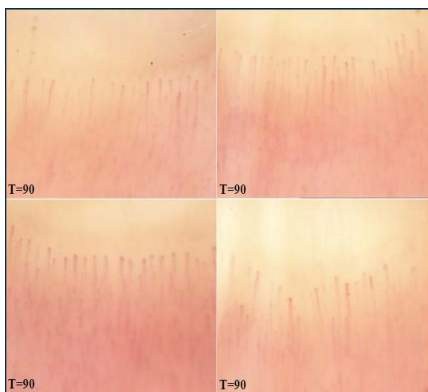


Figure 6: Framework within the limits of the norm.

- Clear reduction of edema.
- Disappearance of hematomas.
- Absence of new hematomas.

On the video capillaroscopic exam, framework improved significantly compared to the previous one: Arrangement of the palisade: regular with focal absences, Number of capillaries: >9/mm, Length of the capillaries: >150 microns (spilungone loops>400 microns), Tortuosity: <20%, Complex dysphorias: <10%, Type of dysmorphism: (loops at eight, serpigino), Ectasias (>20 microns): <of 20%, Mega capillaries (>50 microns): absent, Spontaneous microhaemorrhages: no, Thrombosed loops: No, Edema: no, Transparency: slightly reduced, Visibility of sub-papillary venous plexus: yes, Avascular Areas: no, Flow characteristics: slowed down (Figure 6). Framework within the limits of the norm.

Discussion

This clinical case demonstrates a significant reduction of spontaneous hematomas in the lower limbs in a young woman following the only administration of aminaphthone therapy. After 30 days of treatment (aminaphthone-3 capsules 75 mg a day), our patient shows a significant reduction of hematomas in the legs that can be assessed on the physical examination and on the microhaemorrhages visible on video capillaroscopic examination (Figure 1). The patient continued treatment with a maintenance dose for 60 days (aminaphthone-2 capsules 75 mg per day). At the 90-day examination, the patient shows no appreciable clinical signs for the objective examination; therefore, disappearance of the hematomas in the lower limbs and total regression of the microhemorrhage visible to the video capillaroscopic examination present at the beginning of the treatment.

Conclusion

Aminaphthone therapy shows to be useful in capillary fragility in young subjects. This study showed that taking only and exclusively aminaphthone, for 3 months, at the doses indicated above, without periods of suspension of therapy, a clear improvement of the clinical situation of the patient treated and disappearance of the visible microhaemorrhages to the video capillaroscopic exam examination was observed (Figure 6) and hematomas of the lower limbs present at the beginning of treatment (Figure 5). The effectiveness of an endothelial protector drug, such as Aminaphthone on capillary fragility seems to be clear.

If these results will be confirmed by further controlled, randomized, double-blind clinical trials aminaphthone long-term treatment according to a specific protocol (1 month for three cps/daily following by 2 months for 2 cps/daily) could be a useful therapeutic option for those patients. In conclusion, from this case report, it seems reasonable to understand a role for an endothelial protector drug such as aminaphthone in subjects with alterations affecting the vessel endothelium with a clinical control of edema and micro bleeding during the three months treatment.

References

1. Fulton GP, Akers RP, Lutz BR (1953) White thrombo-embolism and vascular fragility in the hamster cheek pouch after anticoagulants. *Blood* 8: 140-152.
2. Pratesi F (1990) Microcirculation and microangiology-ed minerva medica. Turin 1990.
3. Aliboni E, Amato G, Marini A (1975) Clinical evaluation of the activity of a capillary protector. *Pisa* 3: 59-60.
4. Laird J (2013) The right coat for effective protection. *Renew Energy Focus* 14: 20-22.

5. Bartoli C, Dell'Omodarme G (1975) Action of the amphetamine on the hemostasis altered by reserpine and on the formation of the thrombus. *Pisa Coagulation Notebooks* 1: 2-8.
6. Scorza R, Caronni M, Santaniello A, Toussan K, Beretta L (2009) Aminaphthone enhances iloprost beneficial effects in patients with systemic sclerosis and recurrent ulcers, Philadelphia. *ACR/ARHP* 1738.
7. Santaniello A, Latini R, Zambelli V, Beretta L, Scorza R (2009) Efficacy of aminaphthone in a monocrotaline rat model of pulmonary hypertension, Philadelphia. *ACR/ARHP* 1058.
8. Zambelli V, Santaniello A, Fumagalli F, Masson S, Scorza R, et al. (2011) Efficacy of aminaphthone in a rat model of monocrotaline-induced pulmonary hypertension. *Eur J Pharmacol* 667: 287-291.
9. Santaniello A, Vigone B, Caronni M, Beretta L, Scorza R (2013) Effect of aminaphthone on Raynaud's phenomenon secondary to systemic sclerosis: A double blind prospective, randomized, placebo-controlled pilot study, San Diego. *ACR/ARHP An Meeting* 49: 582-587.
10. Lotti T, Rossi R, Campolmi P (2006) *Minerva medica* copyright. *G Ital Dermatol Venereol* 141: 1-4.
11. Catalano S (1990) The significance and use of dream content in clinical practice with children and adolescents. In *Children's Dreams Clin Prac* pp: 7-15.