ANATOMY OF LIDS AND LACRIMAL APPARATUS

Dr L. Sarkar

HOD *department of ophthalmology*

VMMC and safdarjung hospital

INTRODUCTION

- An **eyelid** is a thin fold of skin that covers and protects an eye.

- The human eyelid features a row of eyelashes which serve to heighten the protection of the eye from dust and foreign debris, as well as from perspiration.

- Its key function is to regularly spread the tears and other secretions on the eye surface to keep it moist, since the cornea must be continuously moist.
- They keep the eyes from drying out when asleep.
- Moreover, the blink reflex protects the eye from foreign bodies.

GROSS ANATOMY

- Parts of Eyelids
- Position of Lids
- Canthi
- Palpebral Aperture
- Lidmargin

PARTS OF EYELIDS

- Each eyelid is divided by a horizontal furrow (sulcus) into an orbital and tarsal part.

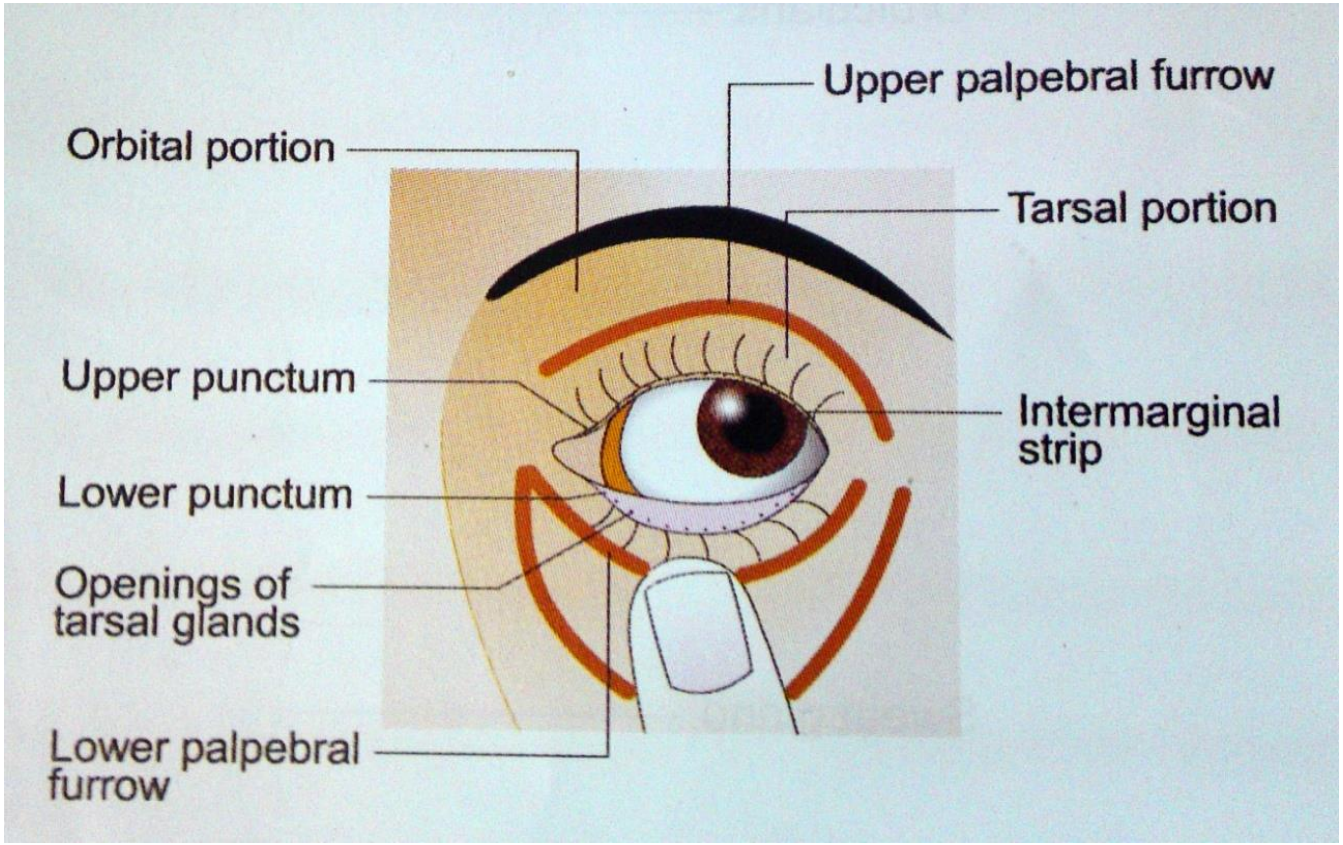

POSITION OF LIDS

- When eye is open, the upper lid covers about 1/6th of the cornea & the lower lid just touches the limbus.

CANTHI

- The two lids meet each other at medial and lateral angles(or outer & inner canthi).
- The medial canthus is about 2mm higher than the lateral canthus

PALPEBRAL APERTURE

- It is the elliptical space b/w the upper and the lower lid.
- When the eyes are opened, it measures about 10-11mm vertically in the centre and about 28-30mm horizontallly.

THE LID MARGIN

- It is About 2mm broad and is divided into two parts by punctum.
- The medial, lacrimal portion is rounded and devoid of lashes or glands.
- The lateral, ciliary portion consist of rounded anterior border, a sharp posterior border and an inter-marginal strip.

LAYERS (ANTERIOR TO POSTERIOR)

- Skin
- Subcutaneous fat
- Orbicularis muscle
- Levator palpebrae supireoris
- Tarsal plate
- Orbital septum
- Adipose tissue
- Conjunctiva and mullers muscle.

1.SKIN:

It is elastic having fine texture and is the thinnest of the body.

2.THE SUBCUTANEOUS AREOLAR TISSUE:

It is very loose and contain no fat. It is thus readily distended by oedema or blood.

3.The layer of striated muscle:-

- It consist of orbicularis muscle which forms an oval sheet across the eyelids.
- It comprises three portions:-

i. The orbital

ii. The palpebral

iii. The lacrimal

It closes the eyelids & is supplied by zygomatic branch of the facial nerve.

- In addition, the upper lid also contains levator palpebrae superioris muscle(LPS).
- It arises from apex of the orbit and is inserted by three parts on the skin of lid, anterior surface of tarsal plate and conjuctutiva of superior fornix.
- It raises the upper lid.
- It is supplied by a branch of occulomotor nerve.

4. Submuscular areolar tissue:

The layer of loose connective tissue.

- The nerve and vessels lie in this layer.
- Therefore, to anaesthetize lid, injection is given in this plane.

5.FIBROUS LAYER:- It is the framework of the lids and consist of two parts: the central tarsal plate and the peripheral septum orbitale.

a.) Tarsal plate: There are two plates of dense connective tissue, one for each lid, which give shape and firmness to the lids. The upper and lower tarsal plates join with each other at medial and lateral canthi; and are attached to the orbital margins through medial and lateral palperable ligaments. In the substance of the tarsal plates lie meibomian glands in parallel rows

b.) Septum orbitale (palpebral fascia). It is thin membrane of connective tissue perforated by nerves , vessels and LPS muscle, which enter the lids from the orbit.

6. Layer of non-striated muscle fibres: it consist of the palpebral muscle of muller which lies deep to the septum orbitale in both the lids. In the upper lid it arises from the fibres of LPS muscle and in the lower lid from prolongation of the inferior rectus muscle; and is inserted on the peripheral margins of the tarsal plate. It is supplied by sympathetic fibres

7) Conjuctiva:

The part which lines the lids is called palpebral conjuctiva. It consist of three parts” marginal, tarsal and orbital.

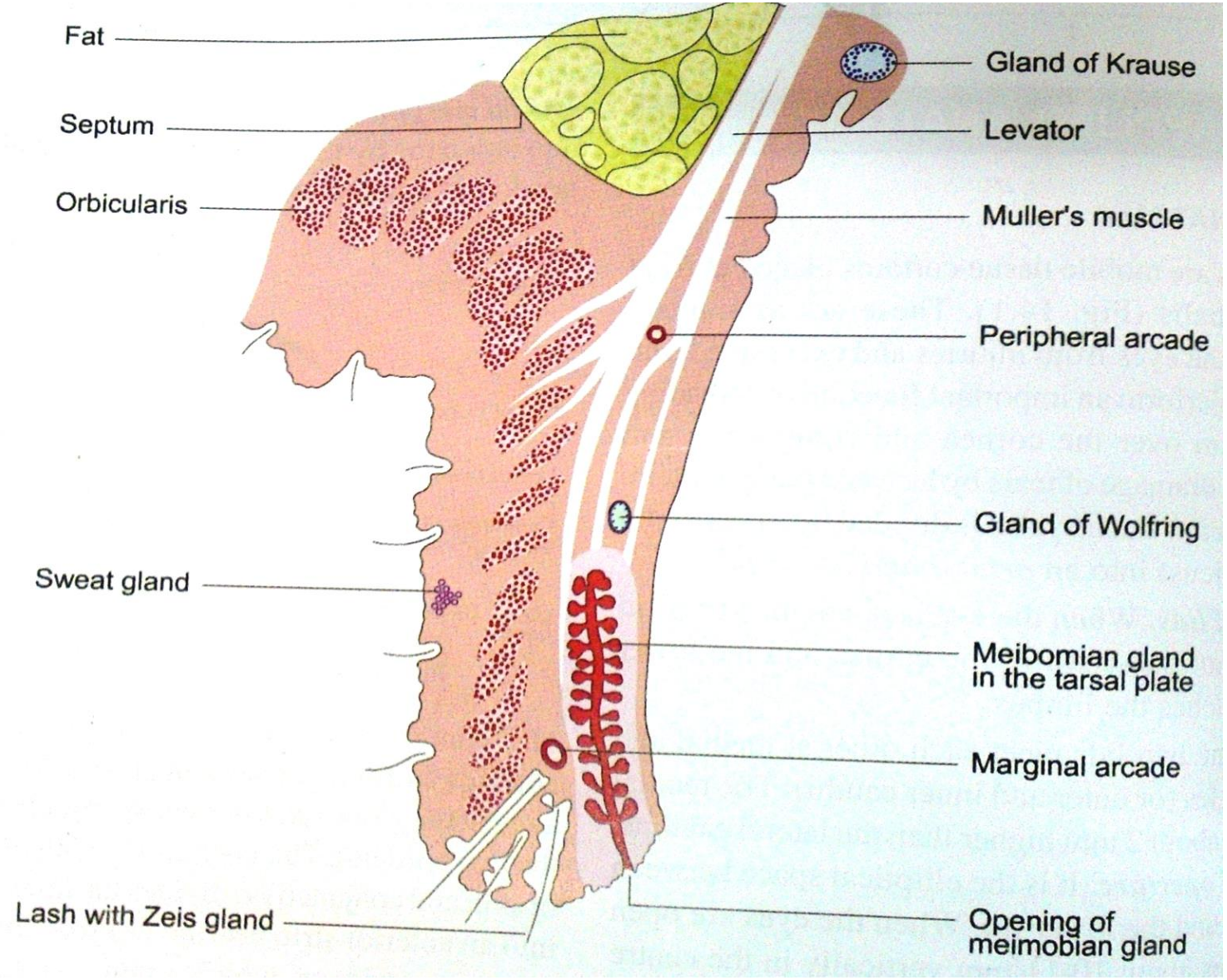
Fat
Septum
Orbicularis
Sweat gland
Lash with Zeis gland
Gland of Krause
Levator
Muller's muscle
Peripheral arcade
Gland of Wolfring
Meibomian gland
in the tarsal plate
Marginal arcade
Opening of
meimobian gland

Glands of eyelids

Meibomian glands: present in stroma of tarsal plate arranged vertically. About 30-40 in upper & 20-30 in lower lid. They are modified sebaceous glands & their ducts open

at lid margin

Glands of zeis: These are also sebaceous glands which open into the follicles of eyelashes.

Accessory lacrimal glands of Wolfring:

These are present near the upper border of tarsal plate.

Glands of Moll: Modified sweat gland situated near the hair follicles or into the duct's of Zeis glands. They do not open directly into the skin surface as elsewhere.

glands of eyelids

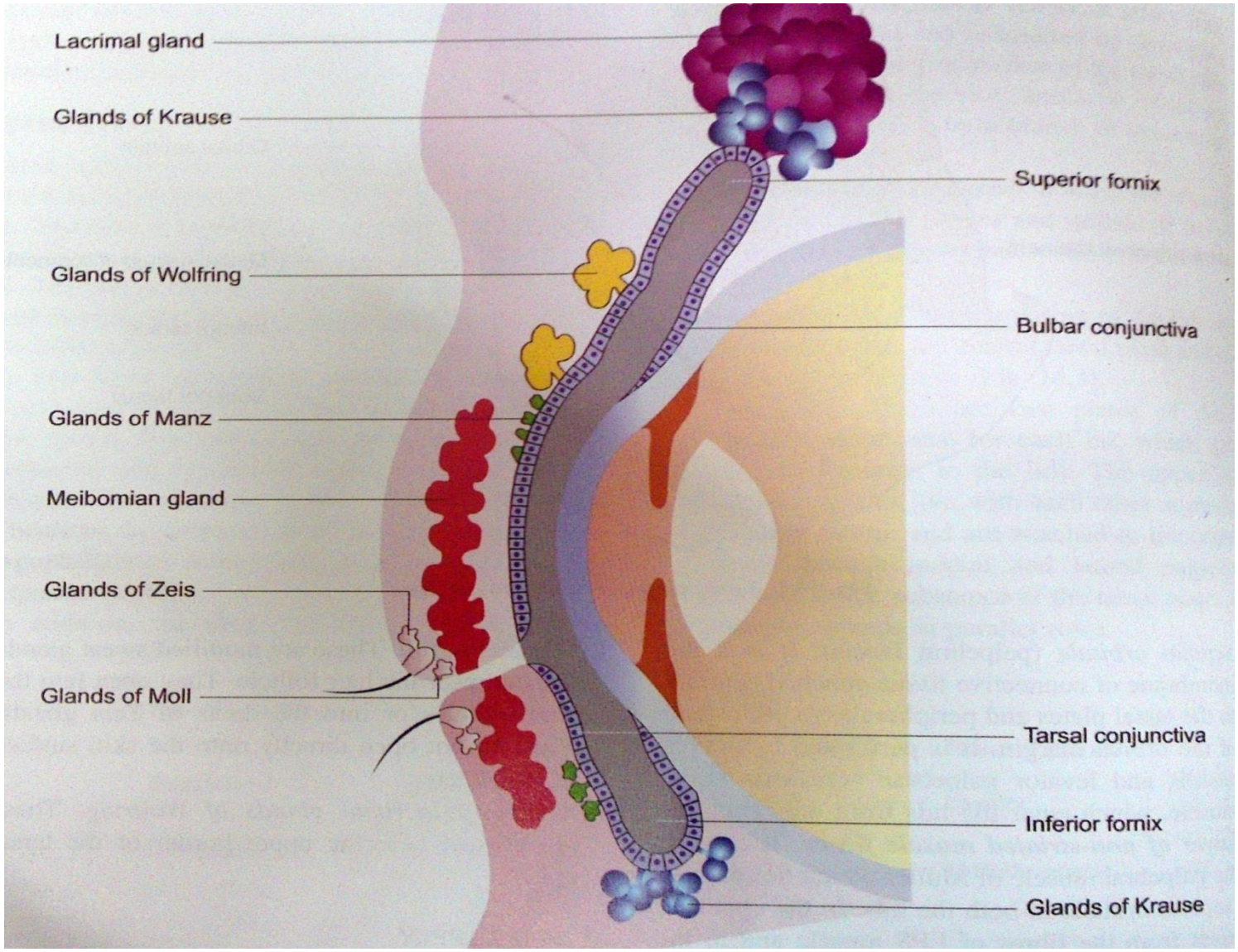

Blood supply

Two arches on each upper and lower lid. The arches are formed by anastamoses of the lateral palpebral arteries and medial palpebral arteries, branching off from the lacrimal artery and ophthalmic artery, respectively

venous drainaige mainly by ophthalmic vein and sub cutaneous veins

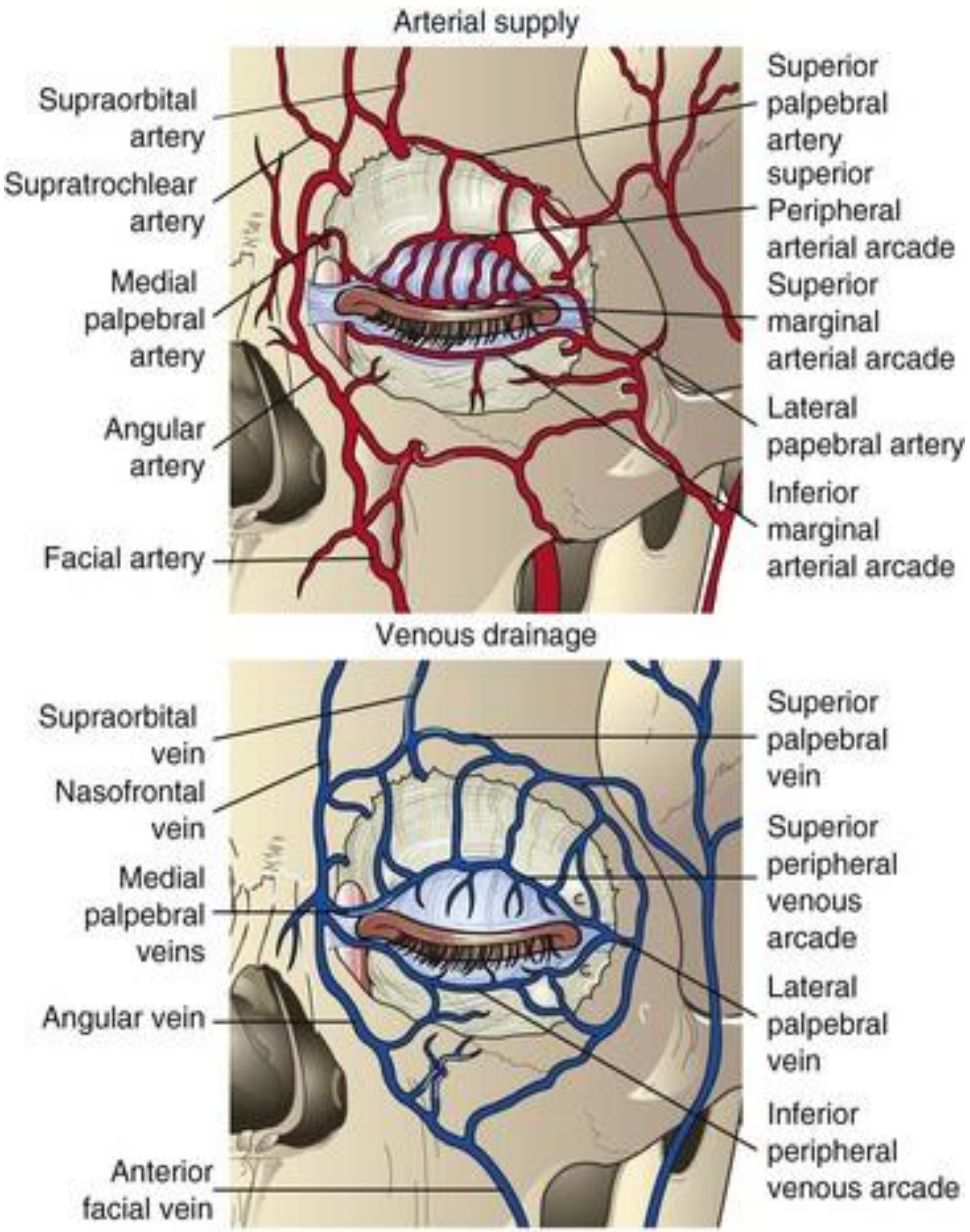

NERVE SUPPLY

- MOTOR NERVES are facial (which supplies orbicularis muscle), oculomotor (which supplies LPS muscle) and sympathetic fibres (which supply the muller's muscle).

- SENSORY NERVE supply is derived from branches of the trigeminal nerve.

Nerve supply:

Sensory Supply

- Lower lid:
  - infra-orbital (from V2)
  - Medial Aspect → infra-trochlear nerve (V1)
- Upper lid:
  - Supra-orbital nerve
  - Supra-trochlear nerve
  - Lacrimal nerve (v1)

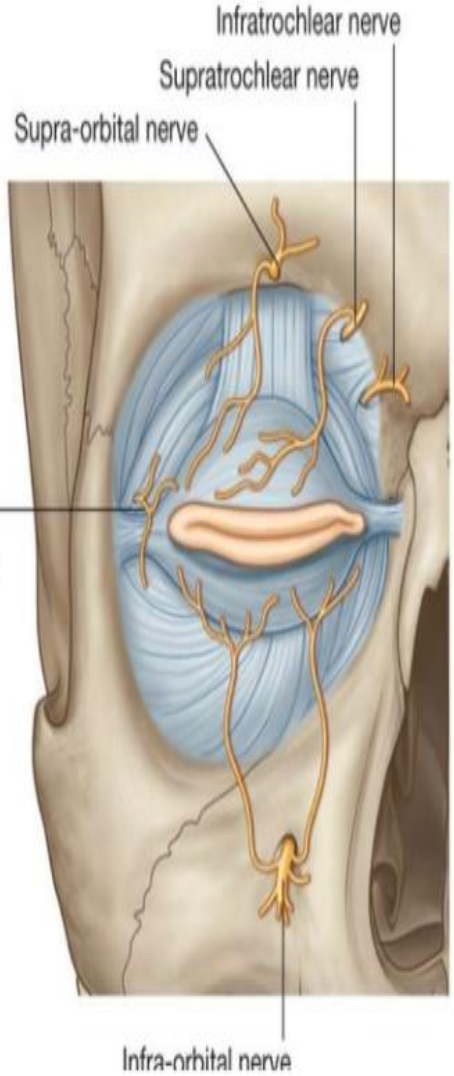

LYMPHATICS

- Those from lateral half of the lids drain into <u>preauricular/ superficial parotid</u> lymph nodes and those from the medial half of the eyelids drain into <u>submandibular</u> lymph nodes.

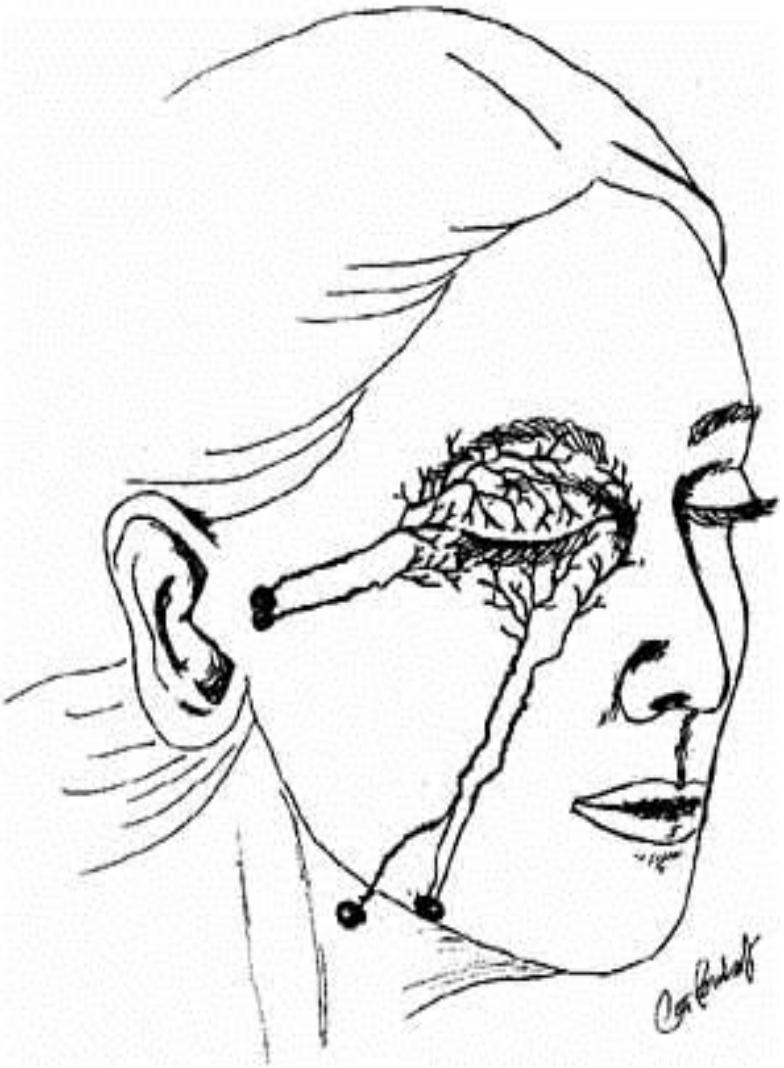

Lacrimal apparatus

1.Lacrimal gland
2.Lacrimal ducts
3.Conjunctival sac
4.Lacrimal puncta
5.Lacrimal canaliculi
6.Lacrimal sac and
7.Naso lacrimal duct

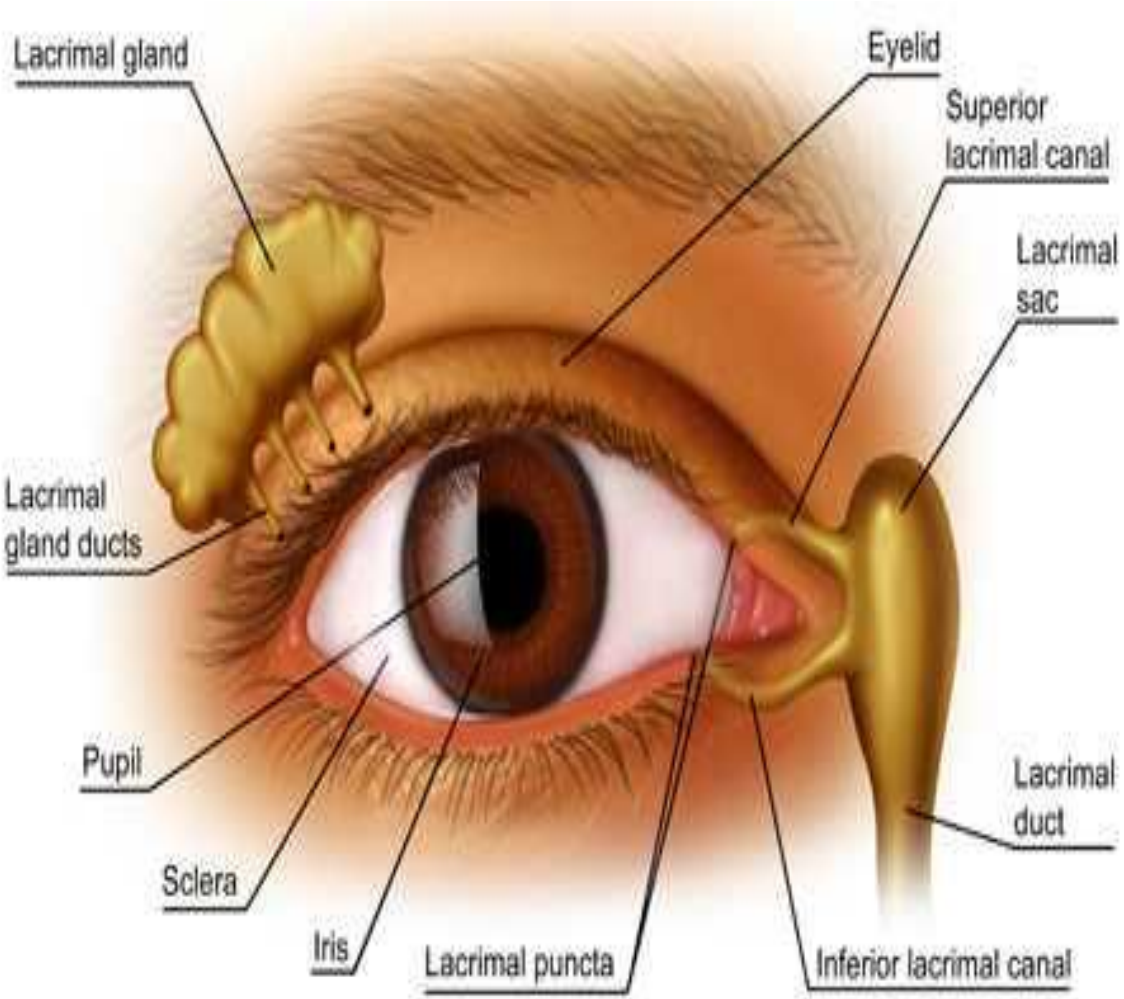

- Osteology
- Secretory system
- Excretory system

OSTEOLOGY

- The lacrimal sac fossa is a depression in the inferomedial orbital rim,
- Maxillary and lacrimal bones.
- Bordered by the anterior lacrimal crest (maxillary bone) & posterior lacrimal crest (lacrimal bone).
- The fossa is approximately 16-mm high, 4- to 9-mm wide, and 2-mm deep.

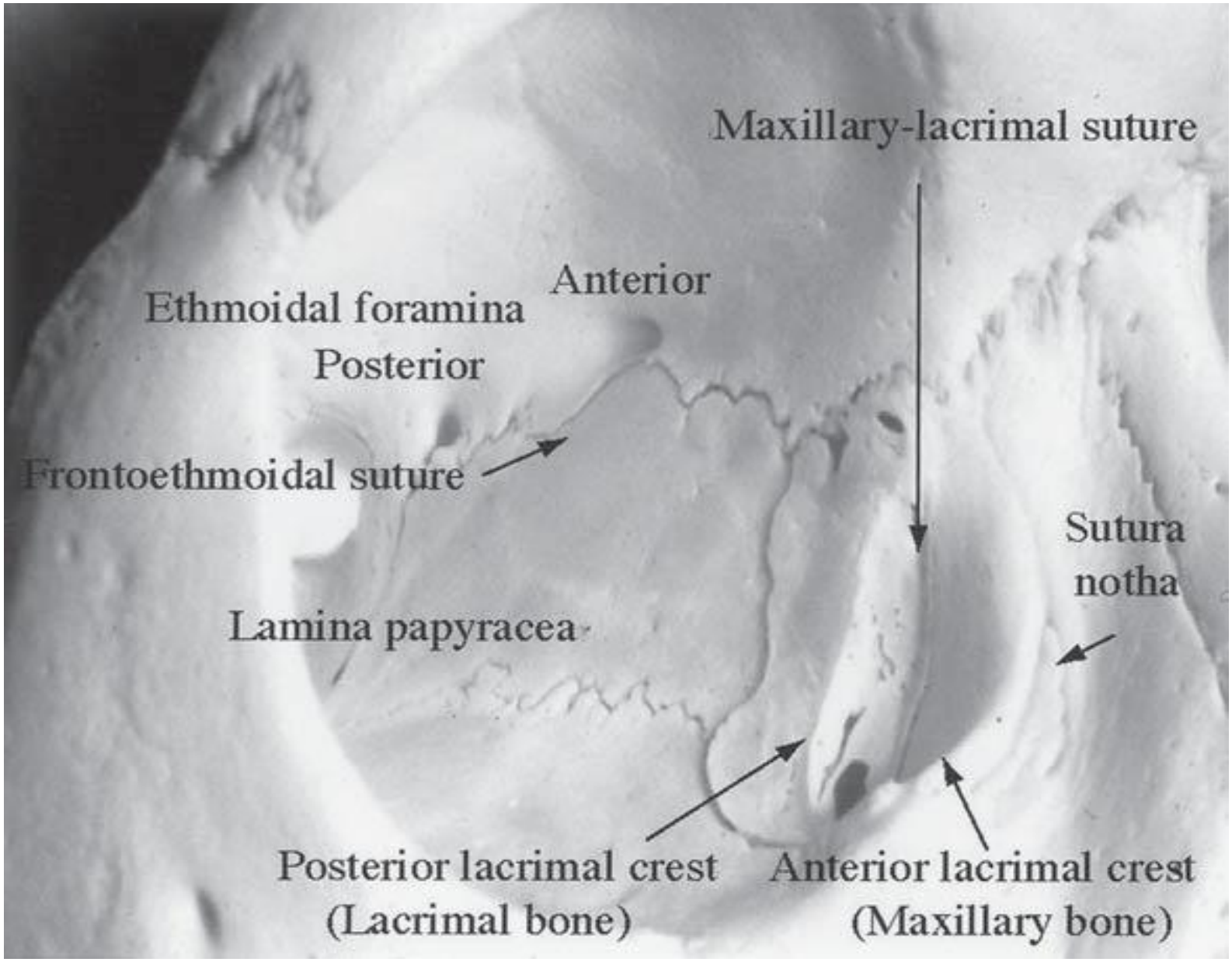
Maxillary-lacrimal suture
Anterior
Ethmoidal foramina
Posterior
Frontoethmoidal suture
Sutura
notha
Lamina papyracea
Posterior lacrimal crest
(Lacrimal bone)
Anterior lacrimal crest
(Maxillary bone)

- The nasolacrimal canal originates at base of lacrimal fossa.
- Formed by the maxillary bone laterally and the lacrimal and inferior turbinate bones medially.
- The width of superior opening is 4–6 mm.
- The duct courses posteriorly and laterally in the bone for 12 mm to drain into the inferior meatus of the nasal cavity.

SECRETORY SYSTEM

- It includes lacrimal gland, accessory glands
- Lacrimal gland is above & anterolateral to globe.
- Secretes tears into superior fornix.
- Tears moisten & lubricates the : cornea , conjunctiva.

Lacrimal gland

- Located in anterolateral part of the roof of orbit in fossa for lacrimal gland
- Divided in to large **orbital part** and small **palpebral part** which are continuous with each other around aponeurosis of LPS

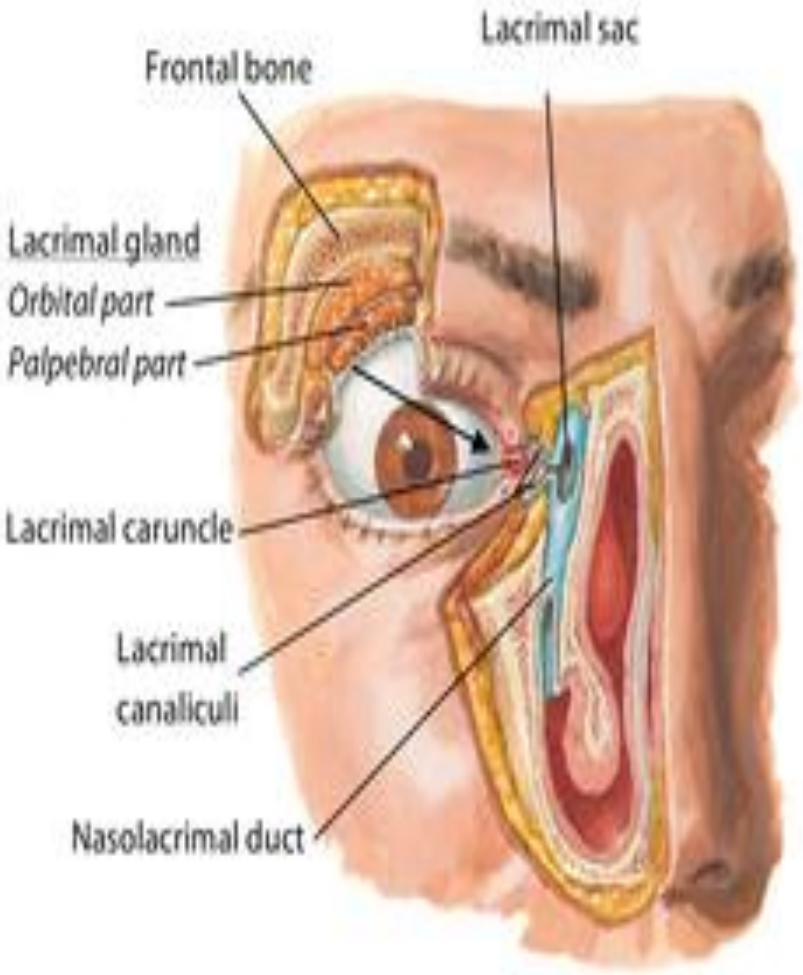

BLOOD SUPPLY-

Internal carotid artery

Ophthalmic artery

Lacrimal artery

Angular vein

Superior ophthalmic

Lacrimal vein

LYMPHATIC DRAINAGE-

Pre auricular group

NERVE SUPPLY

- Parasympathetic secretomotor fibres(efferent) from superior salivatory nucleus
- Sympathetic nerve supply from carotid plexus
- Sensory supply(afferent) from lacrimal nerve Br of ophthalmic division of fifth nerve

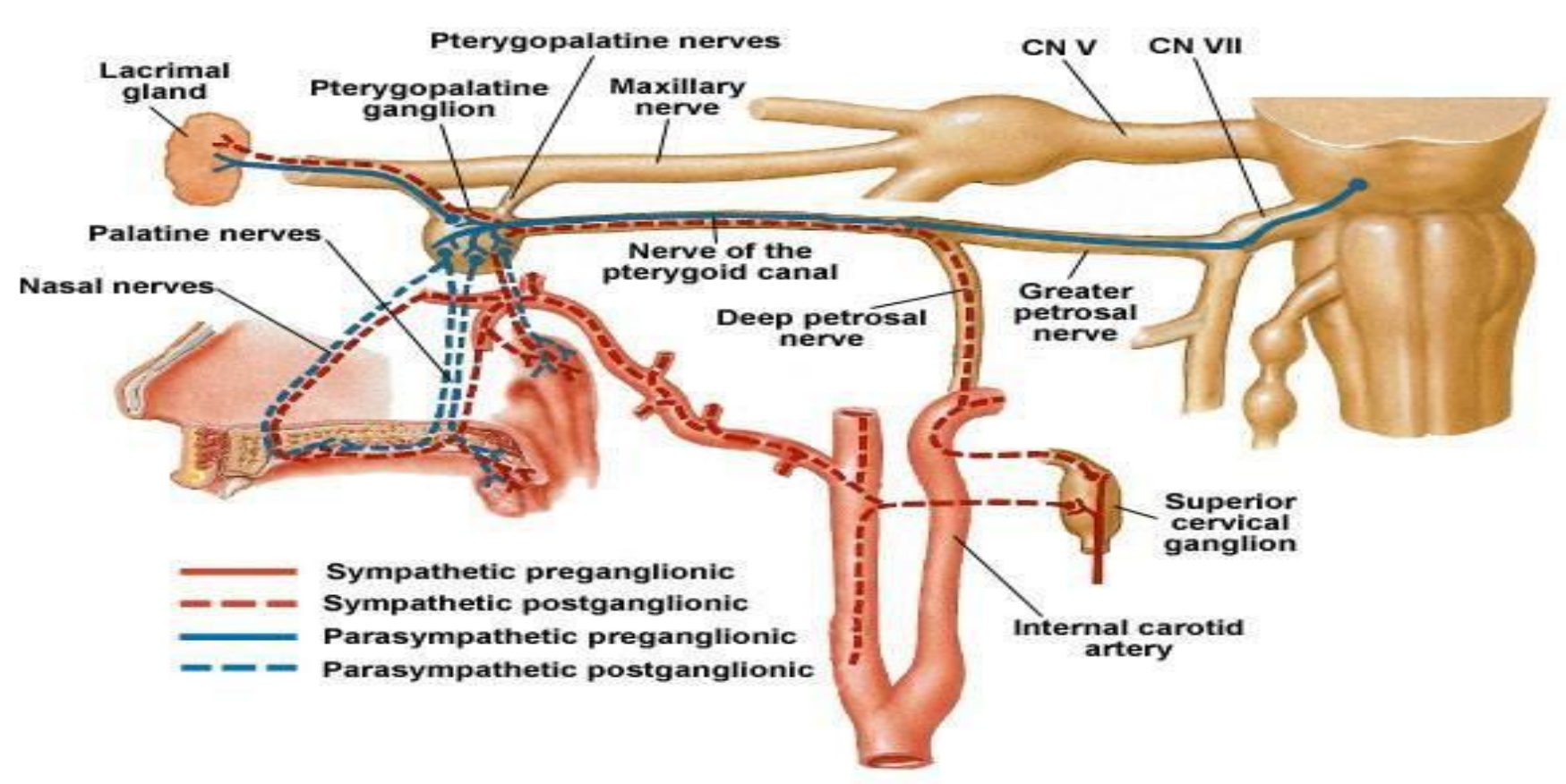

EXCRETORY SYSTEM

- CONJUNCTIVAL SAC
- Conjunctiva stretches from lid margin to limbus and encloses a potential space conjunctival sac which opens at palpebral fissure
- Sac is closed only when lids are approximated

LACRIMAL PUNCTA

- Two puncta situated in each lid margin at the **junction of ciliary and lacrimal parts** on elevtion called lacrimal papilla
- Upper punctum 6mm and lower 6.5 mm from medium canthus
- Surrounded by fibrous tissue which keeps them patent

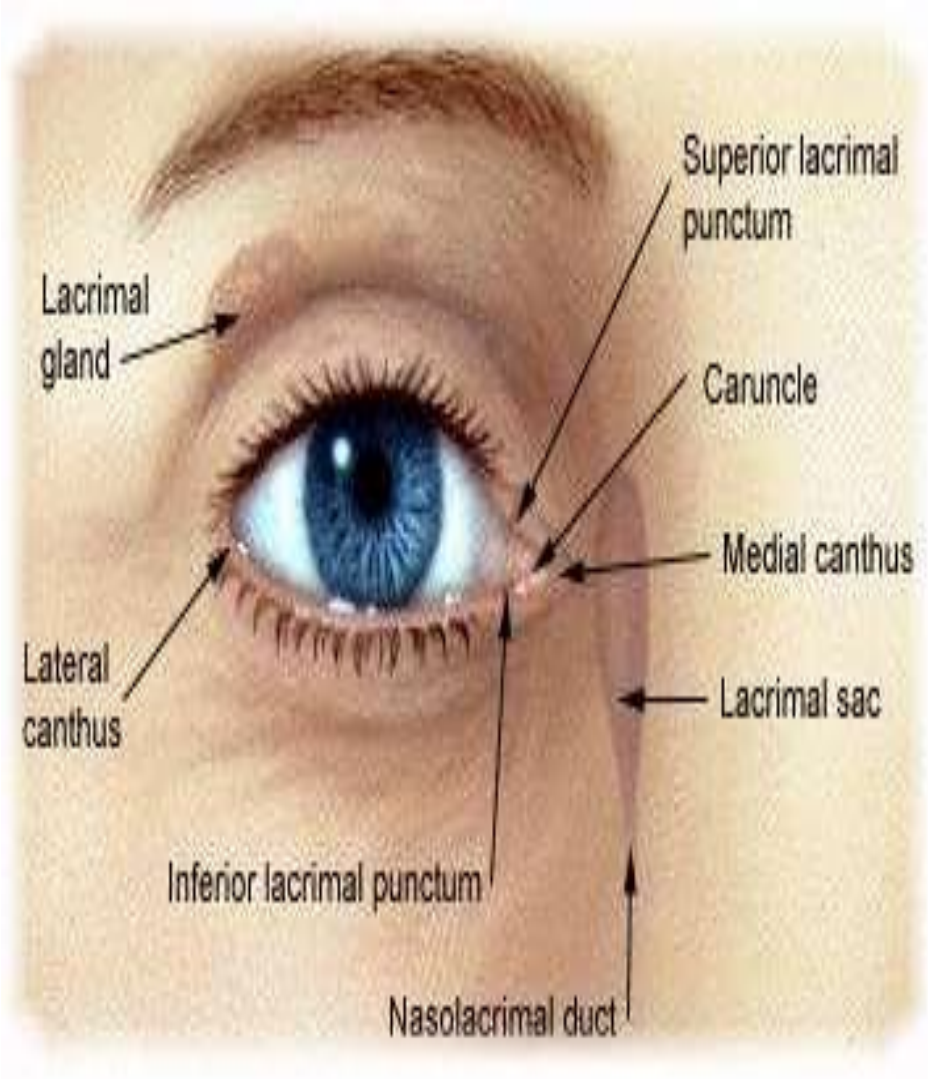

LACRIMAL CANALICULI

- 2 in number,Joins puncta to lacrimal sac
- Two parts vertical(2mm) and horizontal(8mm) at junction dilated to form ampulla
- Pierce lacrimal fascia and unite to form common canaliculi opens in to **lacrimal sinus of maier**
- At opening in to sac protected by **valve of rosenmuller**
- Surrounded by fibres of **pars lacrimalis** of orbicularis oculi muscle
- During blink canaliculi pulled medially,shortened and compressed by pars lacrimalis.also helps in dilatation of lacrimal sac

LACRIMAL SAC

- Lodged in lacrimal fossa(medial wall is lamina papyracea,formed by lacrimal bone and frontal process of maxilla)
- Surrounded by lacrimal fascia which results from splitting of periorbita
- Between sac and fascia are venous plexus
- Part of sac above MPL is fundus.At junction of **fundus and body** diverticulum called **sinus of maier**.lacrimal canaliculi open in to it

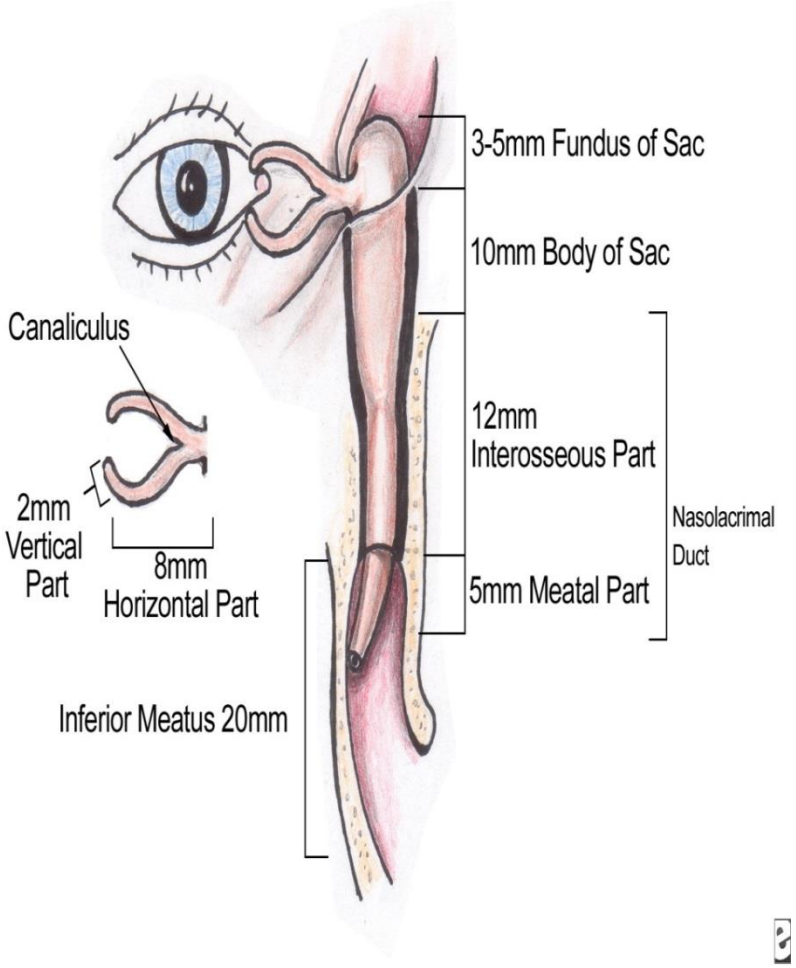

- ANGULAR VEIN and ANGULAR ARETRY crosses MPL about 8mm from the medial canthus.many times a tributary runs 3mm from medial canthus.so to avoid profuse bleeding during sac surgery incison should be made within 3mm medial to medial canthus

NASO LACRIMAL DUCT

- Extends from lacrimal sac to inferior meatus of nose
- 18 mm in length and 3mm diameter
- Upper end is the narrowest
- Runs downward,backward and laterally
- Lined by two layers of coloumnar epithelium
- Has **intraosseus and intra mural part**

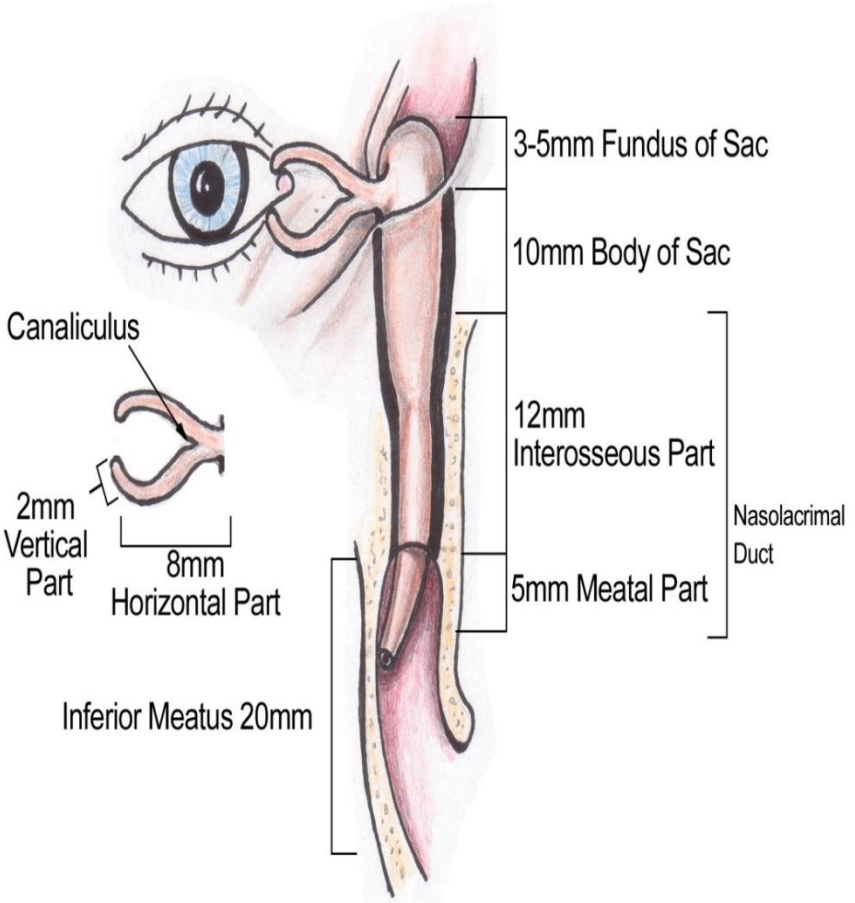

NASO LACRIMAL DUCT

- **Intraosseus part** lodged in naso lacrimal Canal formed by **maxilla anterolaterally,lacrimal bone and inferior nasal concha postero medially**
- **Intramural part** variable in length and lies in inferior meatus.
- NLD opens below in to anterior part of inferior meatus.
- opening guarded by a fold of mucosa-valve of hasner.prevents air from entering the sac when air blown out of closed nose
- In infants some times canalisation is delayed or do not occur causing epiphora and cong dacrocystitis
- Duct is surrounded by rich plexus of veins,forming a erectile tissue .engorgement leads to obstruction of NLD and epiphora

ELIMINATION OF TEARS

- Lacrimal fluid over the preocular surface→marginal tear strip→Lacus lacrimalis→inner canthus→ lacrimal passages → nasal cavity

- Lacrimal pump mechanism:- fibres of the pretarsal & preseptal portion of the Orbicularis which arise from the lacrimal fascia & posterior lacrimal crest.

- This LPM operates with the blinking movements of the eyelids as follows:-

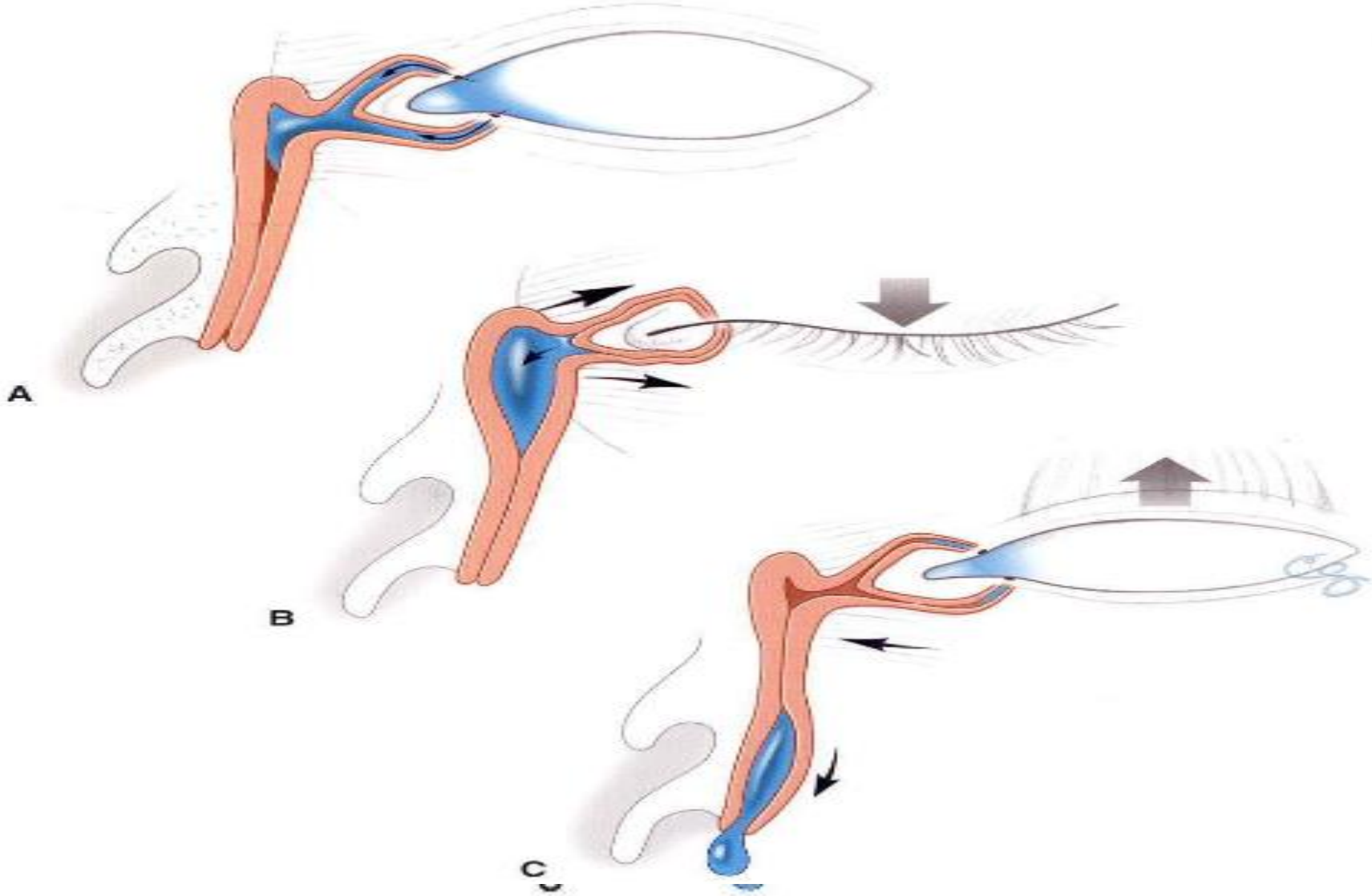

Figure 12-2 Lacrimal pump. **A,** In the relaxed state, the puncta lie in the tear lake. **B,** With eyelid closure, the orbicularis contracts. The pretarsal orbicularis squeezes and closes the canaliculi. The preseptal orbicularis, which inserts into the lacrimal sac, pulls the lacrimal sac open, creating a negative pressure that draws the tears into the sac. **C,** With eyelid opening, the orbicularis relaxes, and the elastic forces create a positive pressure in the sac that propels the tears down the duct. *(Illustration by Christine Gratepp.)*

(1) Start of blink

lids open, system filled with fluid

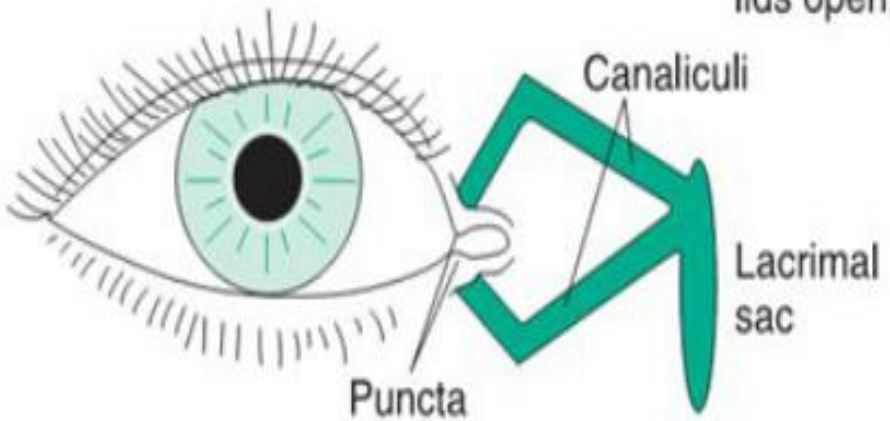

(2) Lids half-closed

lid closure squeezes canaliculi, and sac

(3) Complete closure

canaliculi squeezed maximum amount, all fluid expelled

(4) Lids half-open

release of pressure on canaliculi
puncta still occluded

(5) End of blink

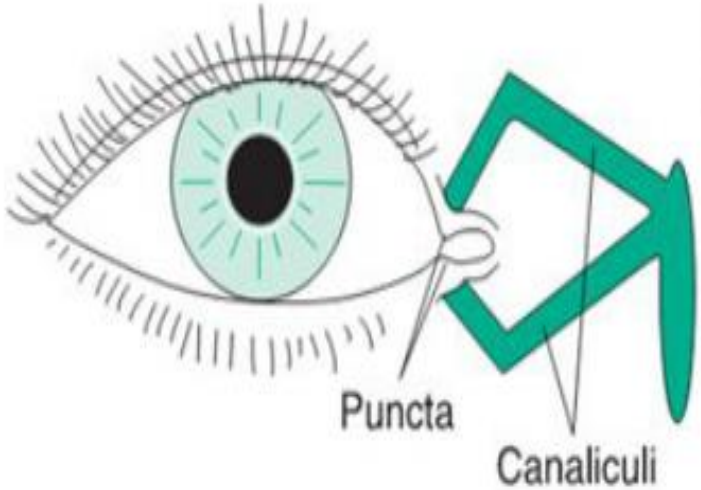

puncta now open, fluid drawn into
canaliculi from tear menisci

DRAINAGE OF LACRIMAL FLUID FROM NLD INTO NASAL CAVITY

- Gravity helps downward flow.
- Air currents in nose induce negative pressure within NLD draw the fluid down the potential lumen of the duct into the nose.
- Hasner's valve present at lower end of NLD, remains open as long as the pressure within nose is less than the NLD, allows the tears to flow from NLD to nose

THANK YOU