
CASE REPORT

Coats' Disease Mimicking Retinoblastoma in a Three-year-old Boy with Known Acute Lymphoid Leukaemia

DD Rasalkar, WCW Chu, BK Paunipagar

Department of Diagnostic Radiology and Organ Imaging, Faculty of Medicine, The Chinese University of Hong Kong, Prince of Wales Hospital, Shatin, New Territories, Hong Kong

ABSTRACT

Coats' disease and retinoblastoma are the two common types of orbital pathology in young children. These two conditions are prognostically different but have overlapping imaging features. We present a case of proven Coats' disease to illustrate the specific imaging features, which can help the readers differentiate it from retinoblastoma. This report is supplemented by a literature review.

Key Words: Eye diseases; Orbital neoplasms; Retinoblastoma; Tomography, X-ray computed

中文摘要

一名三歲急性淋巴白血病患者出現疑似視網膜母細胞瘤的Coats滲出性視網膜炎

DD Rasalkar、朱昭穎、BK Paunipagar

Coats滲出性視網膜炎和視網膜母細胞瘤是常見於兒童的兩種眼部疾病。雖然它們的預後不同，卻有類似的放射醫學影像特徵。本文以一宗確診Coats滲出性視網膜炎病例報告，描述其放射醫學影像的特性，從而區分它跟視網膜母細胞瘤不同之處，並輔以文獻回顧作補充分析。

INTRODUCTION

Retinoblastoma (22-24%) and Coats' disease (4-16%) are two common congenital intraocular lesions in children presenting with leukocoria. Both conditions can be associated with calcifications and therefore difficult to differentiate on imaging. The other group consists of persistent hyperplastic primary vitreous (19-28%), retrolental fibroplasias (5-13%), posterior cataract (13.5%), coloboma, congenital posterior choroidal defect (11.5%), larval endophthalmitis (6.5-16%).^{1,2} Abnormalities in this latter group can be diagnosed by imaging with higher confidence.

Coats' disease is a vascular malformation of the retina that produces lipoproteinaceous subretinal exudates.³ The formation of retinal telangiectasia leads to the breakdown of the retinal-blood barrier at the level of the endothelial cell, allowing leakage of blood products into the retina and subretinal space. This fluid contains cholesterol crystals and lipid-laden macrophages. Over time, the accumulation of this lipoproteinaceous fluid leads to thickening of the retina and causes massive, exudative retinal detachment.^{4,5} The peak prevalence of this condition is at 6 to 8 years of age,^{4,6} but the range of presenting ages can be quite wide (5 months to 71

Correspondence: Dr WCW Chu, Department of Diagnostic Radiology and Organ Imaging, Prince of Wales Hospital, Shatin, New Territories, Hong Kong.

Tel: 852 2632 2290; Fax: 852 2636 0012; Email: winnie@med.cuhk.edu.hk

Submitted: 21 Oct 2009; Accepted: 9 Nov 2009.

years).⁶ There is a male predominance (69-85%), and the disease is usually unilateral (83-95%). If bilateral, one eye is usually minimally affected.^{4,6-8} By far the most common presenting sign is leukocoria, but patients may also present with strabismus, painful glaucoma, or loss of vision.⁴ This condition affects a slightly older age-group than does retinoblastoma.

Retinoblastoma is the most common intraocular tumour in children. It arises from the retina in infancy, and manifests before the age of 5 years. Retinoblastoma accounts for 11% of all cancers in the first year of life. Bilateral or multifocal tumours occur in patients with hereditary retinoblastomas⁹ and account for 20 to 34% of all cases.¹⁰⁻¹² The proportion of bilateral tumours in patients less than a year old is higher. There are hereditary and non-hereditary forms. There is an association with a second malignancy, of which osteosarcoma is the most common. Bilateral inherited retinoblastoma is associated with pineal or parasellar tumours, and is also known as trilateral retinoblastoma.¹³

CASE REPORT

A 3-year-old boy with known acute lymphoid leukaemia presented with an early relapse in the testes in June 2009. Cerebrospinal fluid cytology was positive for leukaemic cells. Brain magnetic resonance imaging (MRI) was performed and showed partial retinal detachment with focal thickening at the lateral aspect which was T1 iso- to hyper-intense and T2 hypointense in signal (Figures 1a and b). Retrospective questioning revealed that the patient had leukocoria and visual impairment. A detailed ophthalmoscopic examination revealed a subretinal mass with exudative retinal detachment. Computed tomographic (CT) orbit confirmed retinal detachment and presence of subretinal fluid, and the presence of foci of calcification. Linear enhancement was demonstrated along the detached leaf of the retina. The differential diagnoses

included Coats' disease and retinoblastoma. The radiological features in this case were a smaller volume of the affected globe and a suspicious linear pattern of retinal enhancement that favours Coats' disease (Figures 1c and d). The patient underwent cryo-photocoagulation and responded successfully with stabilisation of the condition, thus confirming the diagnosis.

DISCUSSION

Retinoblastoma and Coats' disease, though prognostically different, can have overlapping clinical and imaging features, which makes diagnosis difficult. However, making a correct diagnosis is crucial to providing the necessary treatment. For retinoblastoma, it is important to avoid any risky prior intraocular procedure before the definitive enucleation, as this might accelerate tumour seeding.¹⁴⁻¹⁷ A confident diagnosis of benign Coats' disease may prevent unnecessary enucleation in early stages,^{18,19} although in advanced Coats' disease enucleation might still have to be performed when painful nonvascular glaucoma occurs in a blind eye.^{18,20} From previous studies, as many as 58% of the patients with Coats' disease underwent unnecessary enucleation,^{5,16} and as many as 16% with a retinoblastoma were misdiagnosed as Coats' disease.³ Therefore, specific diagnostic signs are of great value to guide radiologists and clinicians to differentiate the 2 conditions.

Overall, there remains an overlap of clinical and imaging features between these 2 entities. In the early stage of Coats' disease, imaging yields little or no information; findings vary with the disease progression.^{4,20} In the advanced stage, the diagnosis is suggested by evidence of partial or total retinal detachment, absence of an intraocular mass and homogeneously increased attenuation within the eye globe. By and large, Coats' disease has T1 and T2 hyperintensity, linear enhancement post-contrast, a smaller globe volume, and a lipid

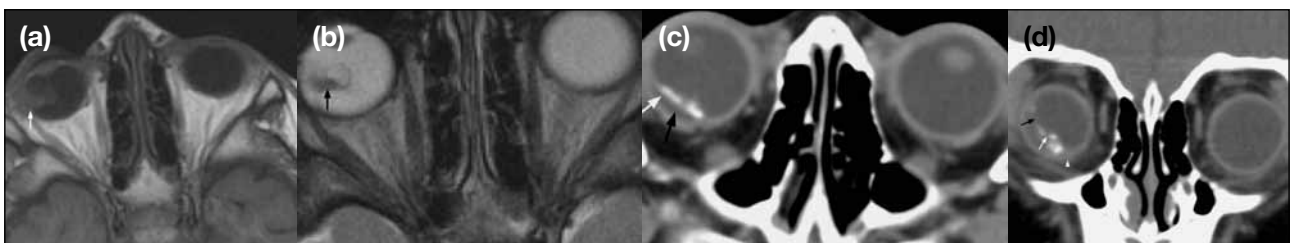


Figure 1. A 3-year-old boy with acute lymphoid leukaemia, who was incidentally found to have a right intraocular mass. Magnetic resonance imaging orbit: (a) T1-weighted and (b) T2-weighted axial images showing partial right retinal detachment with focal thickening at the lateral aspect which is T1 iso- to hyper-intense (white arrow) and T2 hypointense (black arrow). Computed tomographic orbit images: (c) axial image and (d) coronal image revealing calcified leaf (white arrow) of retina present within the right globe (white arrowhead), mimicking retinoblastoma. Subretinal fluid (black arrow) is present posterior to the enhancement. No mass-like enhancement is evident. The right globe is smaller than the contralateral one, and more easily appreciated on coronal imaging.

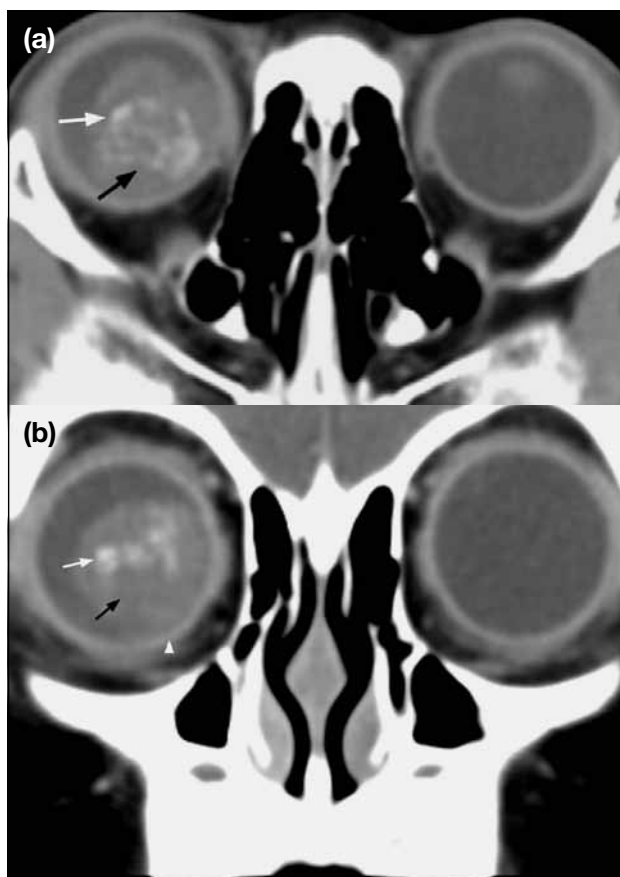


Figure 2. Computed tomographic orbit of a 2-year-old girl with proven retinoblastoma. (a) Axial image: calcified lesion (white arrow) with mass-like enhancement (black arrow). (b) Coronal image: comparable volumes of both affected (white arrowhead) and non-affected globes. Notably there was a calcified lesion (white arrow) with mass-like enhancement (black arrow).

peak on MR spectroscopy. Calcification is an uncommon radiographic feature in Coats' disease, it may be present when the disease is advanced. However, it is usually linear and along the detached leaf of the retina. On the contrary, the majority of retinoblastomas are T1 hyperintense and T2 hypointense, exhibit mass-like enhancement with a normal and symmetrical globe volume compared to the contralateral eye. In retinoblastoma, calcification is very common — thick and coarse (Figure 2). The following features provide some clues, which might help arrive at the correct diagnosis.

Age

Retinoblastoma is the most common intraocular tumour in children. It manifests before the age of 5 years and accounts for 11% of all cancers in the first year of life. The peak prevalence of Coats' disease is at the age of 6 to 8 years,^{4,6} though the age range at presentation is quite wide (5 months to 71 years).⁶ Whilst Coats' disease often becomes evident at an older age than

retinoblastoma, up to 40% of the patients with advanced disease present before the age of 2 years.^{17,18} Notably, retinoblastoma patients with diffusely infiltrating tumour usually present outside the typical age range, and show atypical ophthalmoscopic features simulating inflammatory or haemorrhagic conditions.²¹

Calcification

Intraocular calcifications in children younger than the age of 3 years should lead to a consideration of retinoblastoma, except in those with microphthalmos, colobomatous cysts and cytomegaloviral chorioretinitis.²² The main indication for CT is the search for intraocular calcification.^{18,23-25} Diffuse infiltrating retinoblastomas comprise 5% of these tumours, and are lacking in calcification. Thus absence of calcification does not exclude retinoblastoma. Furthermore, calcification has been reported in Coats' disease.^{5,26}

Contrast Enhancement

In Coats' disease, there is linear enhancement of the anterior margin of subretinal exudates, which corresponds to the thickened retina with telangiectatic and aneurysmal vessels noted at pathological examination. Since the retina is fixed posteriorly at the optic disc, this linear enhancement has a characteristic V-shaped configuration. However, sometimes when the retinal detachment is small (as in our case), the characteristic V shape may not be found. In retinoblastoma, the lesion enhances in a mass-like fashion. These features are best appreciated in gadolinium-enhanced MR images with or without the fat-suppression technique.^{20,24,27} Rarely, in an extreme case of advanced Coats' disease, a retrolental-enhancing gliotic mass may simulate a nodular retinoblastoma. On the other hand, the rare diffuse infiltrating type of retinoblastoma may not show nodularity in any kind of imaging studies.

Signal Intensity

Due to its high fat content, MRI in Coats' disease generally reveals subretinal exudates of uniform high-signal intensity on both T1- and T2-weighted images. The presence of haemorrhage or fibrosis may confer a heterogeneous appearance, especially on T2-weighted images. For retinoblastoma, the image is slightly hyperintense to the ipsilateral vitreous on T1-weighted imaging. In T2-weighted imaging, the tumour is most commonly dark compared to the vitreous.²⁸⁻³⁰ Calcification within the tumour may make it appear heterogeneous.

Globe Volume

A study by Galluzzi et al³¹ postulated that the retinal

vascular developmental abnormalities of Coats' disease disturbs the release of growth factors that regulate the further development of secondary vitreous, resulting in a significantly smaller volume of the affected globe. In retinoblastoma, the size of the globe is normal and symmetrical, and similar to the contralateral eye.³¹ Based on the smaller size of the affected globe in our case, Coats' disease was regarded as a more likely diagnosis.

Proton Magnetic Resonance Spectroscopy

In Coats' disease, the lipoproteinaceous subretinal exudates demonstrate a large peak at 1 to 1.6 ppm (parts per million).³² This technique can be employed in centres which have been equipped with high-quality MR scanners.

CONCLUSION

Specific diagnosis plays an important role in the management of the retinoblastoma and Coats' disease. The imaging features have been previously described. The purpose of this paper was to make use of our case to illustrate the diagnostic dilemma of making the correct diagnosis in a real clinical setting. An overview of the overlapping clinical features (leukocoria, age at diagnosis) and imaging (calcifications and enhancement), as well as more specific characteristics (globe volume and MR spectroscopy) are outlined for this review. In our case, there was great overlap in terms of age, presence of enhancement and calcification. Although our patient had no MR spectroscopy, the linear enhancement pattern, no enhancing solid component and small globe volume facilitated a correct diagnosis of Coats' disease before definitive surgery.

REFERENCES

- Howard GM, Ellsworth RM. Differential diagnosis of retinoblastoma. A statistical survey of 500 children. II. Factors relating to the diagnosis of retinoblastoma. *Am J Ophthalmol.* 1965;60:618-21.
- Smirniotopoulos JG, Bargallo N, Mafee MF. Differential diagnosis of leukocoria: radiologic-pathologic correlation. *Radiographics.* 1994;14:1059-79.
- Shields JA, Parsons HM, Shields CL, Shah P. Lesions simulating retinoblastoma. *J Pediatr Ophthalmol Strabismus.* 1991;28:338-40.
- Edward DP, Mafee MF, Garcia-Valenzuela E, Weiss RA. Coats' disease and persistent hyperplastic primary vitreous. Role of MR imaging and CT. *Radiol Clin North Am.* 1998;36:1119-31,x.
- Chang MM, McLean IW, Merritt JC. Coats' disease: a study of 62 histologically confirmed cases. *J Pediatr Ophthalmol Strabismus.* 1984;21:163-8.
- Woods AC, Duke JR. Coats's disease. I. Review of the literature, diagnostic criteria, clinical findings, and plasma lipid studies. *Br J Ophthalmol.* 1963;47:385-412.
- Shields JA, Shields CL. Review: coats disease: the 2001 LuEsther T. Mertz lecture. *Retina.* 2002;22:80-91.
- Egerer I, Tasman W, Tomer TT. Coats disease. *Arch Ophthalmol.* 1974;92:109-12.
- Knudson AG Jr. Mutation and cancer: statistical study of retinoblastoma. *Proc Natl Acad Sci U S A.* 1971;68:820-3.
- Pendergrass TW, Davis S. Incidence of retinoblastoma in the United States. *Arch Ophthalmol.* 1980;98:1204-10.
- Ozkan A, Pazarli H, Celkan T, et al. Retinoblastoma in Turkey: survival and clinical characteristics 1981-2004. *Pediatr Int.* 2006;48:369-73.
- Kopelman JE, McLean IW, Rosenberg SH. Multivariate analysis of risk factors for metastasis in retinoblastoma treated by enucleation. *Ophthalmology.* 1987;94:371-7.
- Bader JL, Miller RW, Meadows AT, Zimmerman LE, Champion LA, Voute PA. Trilateral retinoblastoma. *Lancet.* 1980;2:582-3.
- Singh AD, Shields CL, Shields JA. Prognostic factors in retinoblastoma. *J Pediatr Ophthalmol Strabismus.* 2000;37:134-41.
- Karcioglu ZA, Gordon RA, Karcioglu GL. Tumor seeding in ocular fine needle aspiration biopsy. *Ophthalmology.* 1985;92:1763-7.
- Shields CL, Honavar S, Shields JA, Demirci H, Meadows AT. Vitrectomy in eyes with unsuspected retinoblastoma. *Ophthalmology.* 2000;107:2250-5.
- Haik BG. Advanced Coats' disease. *Trans Am Ophthalmol Soc.* 1991;89:371-476.
- Char DH. Coats' syndrome: long term follow up. *Br J Ophthalmol.* 2000;84:37-9.
- Kiratli H, Eldem B. Management of moderate to advanced Coats' disease. *Ophthalmologica.* 1998;212:19-22.
- Potter PD, Shields CL, Shields JA, Flanders AE. The role of magnetic resonance imaging in children with intraocular tumors and simulating lesions. *Ophthalmology.* 1996;103:1774-83.
- Patel HK, Augsburger JJ, Eagle RC Jr. Unusual presentation of advanced Coats' disease. *J Pediatr Ophthalmol Strabismus.* 1995;32:120-2.
- Kaufman LM, Mafee MF, Song CD. Retinoblastoma and simulating lesions. Role of CT, MR imaging and use of Gd-DTPA contrast enhancement. *Radiol Clin North Am.* 1998;36:1101-17.
- Haik BG, Saint Louis L, Smith ME, Abramson DH, Ellsworth RM. Computed tomography of the nonrhegmatogenous retinal detachment in the pediatric patient. *Ophthalmology.* 1985;92:1133-42.
- Mafee MF, Goldberg MF, Greenwald MJ, Schulman J, Malmel A, Flanders AE. Retinoblastoma and simulating lesions: role of CT and MR imaging. *Radiol Clin North Am.* 1987;25:667-82.
- Mafee MF, Goldberg MF, Cohen SB, et al. Magnetic resonance imaging versus computed tomography of leukocoric eyes and use of in vitro proton magnetic resonance spectroscopy of retinoblastoma. *Ophthalmology.* 1989;96:965-76.
- Pe'er J. Calcifications in Coats' disease. *Am J Ophthalmol.* 1988;106:742-3.
- Haik BG, Saint Louis L, Smith ME, et al. Magnetic resonance imaging in the evaluation of leukocoria. *Ophthalmology.* 1985;92:1143-52.
- Lemke AJ, Kazi I, Mergner U, et al. Retinoblastoma — MR appearance using a surface coil in comparison with histopathological results. *Eur Radiol.* 2007;17:49-60.
- Barkhof F, Smeets M, van der Valk P, et al. MR imaging in retinoblastoma. *Eur Radiol.* 1997;7:726-31.
- Schueler AO, Hosten N, Bechrakis NE, et al. High resolution magnetic resonance imaging of retinoblastoma. *Br J Ophthalmol.* 2003;87:330-5.
- Galluzzi P, Venturi C, Cerase A, et al. Coats disease: smaller volume of the affected globe. *Radiology.* 2001;221:64-9.
- Eisenberg L, Castillo M, Kwock L, Mukherji SK, Wallace DK. Proton MR spectroscopy in Coats disease. *AJNR Am J Neuroradiol.* 1997;18:727-9.