

A novel mitochondrial DNA deletion in a Chinese girl with Kearns-Sayre syndrome

Eric KC Yau 丘健昌
KY Chan 陳國燕
KM Au 區鑑明
TC Chow 周達倉
YW Chan 陳恩和

Kearns-Sayre syndrome is a rare disorder often caused by mitochondrial DNA rearrangement. The most commonly reported mitochondrial DNA deletion is 4977 bp in size spanning nucleotides 8469 and 13447. The clinical signs of Kearns-Sayre syndrome include chronic progressive external ophthalmoplegia, retinitis pigmentosa, heart block and cerebellar ataxia, as well as other heterogeneous manifestations including neuromuscular problems and endocrine disorders. Cardiac conduction defects can develop insidiously, leading to sudden death sometimes if not promptly recognised. This report focuses on the diagnosis of Kearns-Sayre syndrome in a Chinese girl who presented initially with short stature, delayed puberty, insidious onset of ptosis and later with typical features of Kearns-Sayre syndrome including complete heart block. Genetic analysis disclosed a novel 7.2 kilobases deletion in muscle tissue. Mitochondrial diseases have heterogeneous phenotypes and mutational analysis has proven to be an effective tool for confirming the diagnosis.

Introduction

Kearns-Sayre syndrome (KSS) is a rare mitochondrial disorder with multisystem involvement affecting the eye, muscle, heart, endocrine, peripheral and central nervous systems. Typical clinical features include ptosis, ophthalmoplegia, pigmentary retinopathy, cardiac conduction defects and/or cardiomyopathy, sensorineural deafness, myopathy, ataxia, developmental delay or regression, and endocrine disorders.¹ Most deletions have been 4977 bp in size.² We report here a young Chinese girl with a clinical diagnosis of KSS associated with a novel large-scale mitochondrial DNA (mtDNA) deletion.

Case report

The patient was the only child of non-consanguineous Chinese parents. Her birth history was unremarkable and her development was normal during early childhood. There was no personal or family history of major illness or chronic disease.

She was noted to have short stature at the age of 7 years and was initially seen by a paediatrician in a local hospital at the age of 10 years. Her height and weight were well below the third percentile while her head circumference was normal, at the 50th percentile. Her full blood count, blood glucose, liver and renal functions, thyroid function and bone age were all normal. Karyotyping showed 46 XX, 15p- but the deletion in chromosome 15 had no clinical significance and would not affect her stature and intelligence. She failed to attend for follow-up at that time and was subsequently referred to our endocrine clinic by the Student Health Centre for management of her short stature and being underweight at the age of 12 years. At this juncture, her bone age was delayed, at 10 years when she was 12 years and 10 months. Her cortisol level was normal and a glucagon stimulation test showed no evidence of growth hormone deficiency.

Her school performance was poor and psychological assessment showed that she was functioning at a mild grade of mental deficiency (Hong Kong Wechsler Intelligence Scale for Children: verbal IQ – 60; performance IQ – 63; full-scale IQ – 57) for her age of 13 years, and was particularly weak in verbal expression, abstract thinking, and visual pattern analysis.

Bilateral partial ptosis and mild ophthalmoplegia were noted at age 14. An ophthalmologist examined her eyes and found pink optic discs with diffuse bilateral pigmentary retinitis. A gradual onset of clumsiness and hearing impairment were also noted. Physical examination showed lower limb muscle weakness, a mild ataxic gait, dysmetria, and dysdiadochokinesia. Brainstem-evoked potentials showed that the auditory click thresholds were 80 and 55 dBnHL in her left and right ears, respectively.

Her urine amino acid/organic acid levels, plasma amino acids, blood gases, fasting blood lactate and pyruvate were all normal, as was her serum creatine kinase. Motor and

Key words

DNA, mitochondrial; DNA, mutational;
Genetic predisposition to disease;
Kearns-Sayre syndrome

Hong Kong Med J 2009;15:374-7

Princess Margaret Hospital, Laichikok,
Kowloon, Hong Kong:
Department of Paediatrics and
Adolescent Medicine
EKC Yau, MRCP (UK), FHKAM (Paediatrics)
KY Chan, FRCPC, FHKAM (Paediatrics)
Department of Pathology
KM Au, MSc, ACB
TC Chow, MPhil
YW Chan, MD, FHKAM (Pathology)

Correspondence to: Dr EKC Yau
E-mail: yaukce@hotmail.com

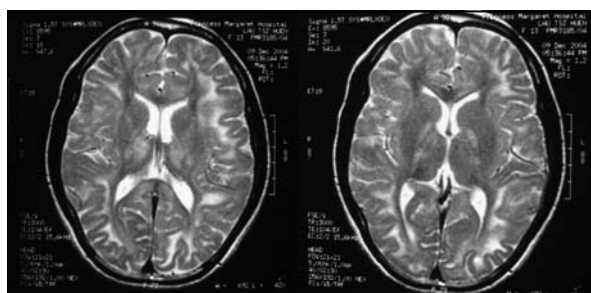


FIG 1. Magnetic resonance imaging of the brain showing bilateral, extensive and symmetrical areas with signal changes involving cerebral white matter, deep cerebellar white matter and deep grey matter

一名Kearns-Sayre氏症候群華籍女童患者的新型粒線體基因缺乏症

Kearns-Sayre氏症候群 (KSS) 很罕見，成因大多為粒線體DNA出現重組所致。最常見的粒線體DNA缺失的大小為4977 bp，涉及核苷酸8469和13447。KSS的臨床徵狀為慢性進行性的眼外肌麻痺、視網膜色素變性、心臟傳導障礙、運動失調，以及其他系統的異常，包括神經肌肉及內分泌疾病。心臟傳導障礙可能會在病人不知不覺的情況下產生，如果未能及時發現，有機會導致突然死亡。本文報告一名患有KSS的女孩，她個子矮小、生長遲緩、眼皮下垂，以及診斷後期出現KSS的一般臨床表徵，包括完全性房室傳導阻滯。基因研究分析肌肉組織發現新型的7.2 kb有缺失。粒線體疾病有多種不同的徵狀，基因突變分析可以是一種有效的確診工具。

sensory nerve conduction studies of her upper and lower limbs were normal but her cerebral spinal fluid (CSF) protein level was raised at 206 mg/dL (reference range, 20-50 mg/dL). Magnetic resonance imaging (MRI) of her brain (Fig 1) showed bilateral, extensive and symmetrical areas of signal changes involving the cerebral white matter (predominantly subcortical), deep cerebellar white matter and deep grey matter (thalami, globus pallidi, brainstem and cerebellar nuclei). Magnetic resonance imaging of her spine, performed to investigate her scoliosis and clumsy gait, showed abnormal signals in the posterior aspect of her cervical cord at C2 to C4.

In view of her evolving clinical presentations, KSS was suspected. Her first electrocardiogram (ECG), performed at the age of 14 years, showed sinus rhythm, a normal PR interval, but a prolonged corrected QT interval (QTc) at 0.48 seconds with left superior axis, right bundle branch block and occasional ventricular ectopics. An echocardiogram showed a normal heart with good ventricle contractility. A holter ECG performed later showed ventricular ectopics with a bigeminy pattern. No heart block or bradycardia was evident at this time. Despite being totally asymptomatic, she was found to have an irregular heartbeat of 45 beats per minute with complete heart block when assessed by paediatric cardiologists 2 weeks after the holter ECG had been performed. A transcatheter pacemaker was inserted.

A muscle sample was taken from her thigh and studied under light microscopy. Histochemical stains with ATPase (pH 9.4, 4.6 and 4.2) were unremarkable. NADH-TR, SDH and COX stains revealed a rare subsarcolemmal increase in enzyme activity. No negative staining of fibres was noted. Goldner's trichrome stain showed a normal fibre size and shape but rare subsarcolemmal aggregates of mitochondria were present. Typical ragged-red fibres (RRF) were noted. An examination using electron microscopy revealed that most of the mitochondria were abnormal, irregular-sized, and had abnormal cristae and central core-like structures. Paracrystalline inclusions and

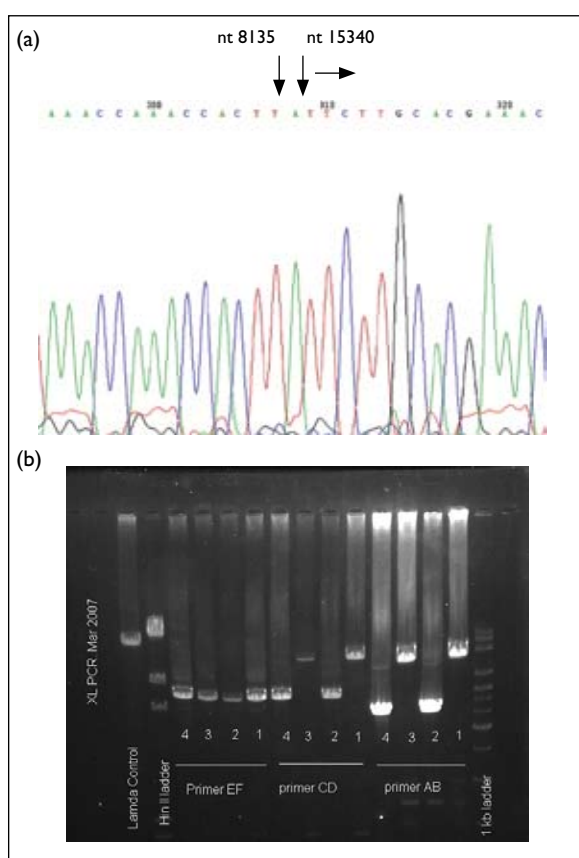


FIG 2. (a) Sequence analysis (forward) of polymerase chain reaction (PCR) product from primer AB showing deletion site of mitochondrial DNA nucleotide (nt) 8136-15339. (b) Analysis by long-range PCR using three primer pairs showed a gross deletion in primer AB and CD

1: a patient with no gross deletion; 2: the index patient; 3: negative QC; 4: positive QC of 7.3 kilobases deletion

occasional subsarcolemmal aggregates were also noted. All these findings were compatible with mitochondrial disorders. Based on this information, the MRI findings and the clinical manifestations, a diagnosis of KSS was made.

A blood test for mtDNA deletion was negative but a muscle biopsy for mtDNA deletion revealed a mitochondrial gross deletion of 7204 bp (7.2 kilobases [kb]) from nucleotide (nt) 8136 to nt 15339 (Fig 2). About one third of the functional loci of the mtDNA were deleted, including part of the cytochrome c oxidase II, cytochrome c oxidase III, cytochrome b, ATP synthase 6 and 8, 5 subunits of NADH dehydrogenase and 7 tRNAs. These findings support the notion that our patient's KSS was caused by this mtDNA deletion.

Discussion

Kearns-Sayre syndrome, first described by Kearns and Sayre in 1958, is characterised by a triad of chronic progressive external ophthalmoplegia and pigmentary retinopathy with an onset before the age of 20 years, along with at least one of the following features: a cardiac conduction defect, cerebellar ataxia and a raised CSF protein level (>100 mg/dL). Additional features may include myopathy, sensorineural deafness, short stature, dementia and other endocrine disorders like diabetes mellitus, hyperaldosteronism and hypoparathyroidism.^{1,3,4} Our patient presented with most of the typical features listed at different stages.

The cardiac manifestation is usually subtle but is one of the most important factors determining the disease prognosis. Development of a cardiac conduction defect may result in syncope, heart failure, and sudden cardiac death in up to 57% of patients, with a mortality of 20%.^{5,6} Conduction defects seen in KSS range from a prolonged intra-ventricular conduction time, all types of bundle branch blocks to a complete atrio-ventricular block. The interval between recognition of heart block and death varied from days or months up to 6 and 7 years in one study.⁵ In our patient, complete heart block developed only 6 months after her right bundle branch block was first recognised and sudden death was prevented by pacemaker implantation. A prolonged QT interval and congestive cardiomyopathy per se have also been reported as being associated with KSS.⁷ Patients with suspected KSS should be screened for cardiac conduction defects and referred to cardiologists promptly for further assessment and intervention.

High-signal foci in the subcortical cerebral white matter and in the brainstem, globus pallidus or thalamus are characteristic MRI findings in KSS. A literature review of MRI findings in 13 patients with typical KSS showed that 10 of them had bilateral subcortical white matter lesions on T2-weighted images and at least seven also had signal lesions in the brainstem, globus pallidus, thalamus or cerebellum.⁸ The typical MRI changes were present in our patient, but the brain MRI can also be normal in an initial KSS presentation.

The presence of RRF and aggregates of abnormal mitochondria in the muscle biopsy are usually regarded as histological hallmarks of mitochondrial myopathy. But the absence of RRF does not rule out a mitochondrial disorder. On the other hand, ultrastructural changes (such as increased numbers or enlarged and abnormally shaped mitochondria, sparse, concentric or bizarre cristae and paracrystalline inclusions) are not specific for mitochondrial disease. These changes may also be observed in some other conditions like myositis and muscular dystrophies.⁹

The mitochondrion contains its own DNA and human mtDNA is a circular double-stranded genome of 16.6 kb and codes for 13 proteins, 22 transfer and 2 ribosomal RNAs.¹⁰ Most reported cases of KSS are sporadic and are related to mtDNA rearrangements,⁴ often due to large-scale mtDNA deletions of 1.3 to 7.6 kb, varying in size and location. Not only are mtDNA deletions associated with KSS, they have also been described in patients with chronic progressive external ophthalmoplegia, Pearson's syndrome, MELAS (mitochondrial myopathy, encephalopathy, lactic acidosis and stroke), isolated diabetes and cardiomyopathy whereas the A3243G mutation is also found in patients with KSS. Furthermore, as mtDNA deletions exist in heteroplasmic form and the mutant load varies in different tissues and may change over time, correlation between genotypes and phenotypic expression is always difficult in mitochondrial disease.¹⁰ It is recommended that mutational analysis should be performed on tissues that are clinically relevant.¹¹

Although different therapies have been tried, no single treatment has been found to be effective for treating mtDNA deletion syndromes. Cerebral folate deficiency with normal blood folate status has been associated with mtDNA deletion. A remarkable clinical response and significant improvement in cerebral myelination was reported in a girl with KSS and low CSF folate after 1 year of treatment with folinic acid (1 mg/kg/day, increasing up to 2.5 mg/kg/day).¹² A ketogenic diet has also been tried as a potential treatment modality for heteroplasmic mtDNA disorders, as ketogenic treatment can reduce the level of deleted mtDNA in cultured human cells.¹³

One hundred and sixteen different mtDNA deletions have been recorded in the latest MITOMAP databases.¹⁴ A single deletion of 4977 bp, spanning nt 8469 and 13447, is the most commonly reported mtDNA deletion.² The muscle biopsy taken for molecular studies in our patient identified a novel 7204 bp mtDNA deletion causing KSS phenotypes.

Conclusion

Making a diagnosis of mitochondrial disease is

always difficult, particularly in children, because of its clinical heterogeneity and evolving clinical presentations. Mitochondriopathy should be considered in patients with a progressive course of an unexplained association of symptoms involving seemingly unrelated organs or tissues.¹⁵ Patients should be regularly followed up and screened for associated complications as most cases have

progressive evolving clinical manifestations.¹⁶ For mitochondrial disease with more specific and recognisable phenotypes like KSS, one should be aware of, and familiar with, the disease phenotypes and evolution of the clinical manifestations. Early diagnosis and recognition of the associated complications (eg complete heart block) may significantly reduce morbidity and mortality.

References

1. Borchert A, Wolf NI, Wilichowski E. Current concepts of mitochondrial disorders in childhood. *Semin Pediatr Neurol* 2002;9:151-9.
2. Remes AM, Majamaa-Voltti K, Kärppä M, et al. Prevalence of large-scale mitochondrial DNA deletions in an adult Finnish population. *Neurology* 2005;64:976-81.
3. Park SB, Ma KT, Kook KG, Lee SY. Kearns-Sayre syndrome—3 case reports and review of clinical feature. *Yonsei Med J* 2004;45:727-35.
4. Brockington M, Alsanjari N, Sweeney MG, Morgan-Hughes JA, Scaravilli F, Harding AE. Kearns-Sayre syndrome associated with mitochondrial DNA deletion or duplication: a molecular genetic and pathological study. *J Neurol Sci* 1995;131:78-87.
5. Chawla S, Coku J, Forbes T, Kannan S. Kearns-Sayre syndrome presenting as complete heart block. *Pediatr Cardiol* 2008;29:659-62.
6. Berenberg RA, Pellock JM, DiMauro S, et al. Lumping or splitting? "Ophthalmoplegia-plus" or Kearns-Sayre syndrome? *Ann Neurol* 1977;1:37-54.
7. Karanikis P, Korantzopoulos P, Kountouris E, et al. Kearns-Sayre syndrome associated with trifascicular block and QT prolongation. *Int J Cardiol* 2005;101:147-50.
8. Chu BC, Terae S, Takahashi C, et al. MRI of the brain in the Kearns-Sayre syndrome: report of four cases and a review. *Neuroradiology* 1999;41:759-64.
9. Patterson K. Mitochondrial muscle pathology. *Pediatr Dev Pathol* 2004;7:629-32.
10. Schapira AH. Mitochondrial disease. *Lancet* 2006;368:70-82.
11. Vallance H. Biochemical approach to the investigation of pediatric mitochondrial disease. *Pediatr Dev Pathol* 2004;7:633-6.
12. Pineda M, Ormazabal A, López-Gallardo E, et al. Cerebral folate deficiency and leukoencephalopathy caused by a mitochondrial DNA deletion. *Ann Neurol* 2006;59:394-8.
13. Santra S, Gilkerson RW, Davidson M, Schon EA. Ketogenic treatment reduces deleted mitochondrial DNAs in cultured human cells. *Ann Neurol* 2004;56:662-9.
14. MITOMAP: Reported mtDNA deletions. MITOMAP: A human mitochondrial genome database website: <http://www.mitomap.org/cgi-bin/tbl10gen.pl>. Accessed 27 Aug 2007.
15. Munnich A, Rötig A, Chretien D, Saudubray JM, Cormier V, Rustin P. Clinical presentations and laboratory investigations in respiratory chain deficiency. *Eur J Pediatr* 1996;155:262-74.
16. Finsterer J. Mitochondriopathies. *Eur J Neurol* 2004;11:163-86.