

Sonographic diagnosis of emphysematous pyelonephritis in a clinically stable patient

A 39-year-old woman presented to our hospital complaining of fever, polyuria and repeated vomiting for several days. She had no relevant medical history and had been in good health. A urinalysis found haematuria and proteinuria, and blood cultures grew Gram-negative rods. An abdominal ultrasound examination found a normal-looking liver and a right kidney with large amounts of non-dependent, high amplitude echoes with 'dirty' shadowing within the renal parenchyma (Fig 1). This appearance was highly suggestive of air inside the kidney. No renal mass or stone was seen and there was no perinephric fluid collection. Further examination showed an extension of pockets of air to the subcapsular region (Fig 2). Emphysematous pyelonephritis was diagnosed on the basis of these images.^{1,2} A non-enhanced computed tomographic examination of the abdomen was then performed, confirming that there was gas inside the renal parenchyma and renal pelvis (Fig 3). The patient responded poorly to antibiotics and required removal of her right kidney. She recovered from surgery uneventfully.

Discussion

Emphysematous pyelonephritis is a rare but life-threatening necrotising infection of the kidney caused by gas-forming bacteria. Although it can

present with a fulminant clinical picture of sepsis, relatively mild symptoms can be encountered. Our patient was in a stable condition with symptoms suggesting a urinary tract infection. Ultrasound is usually the first imaging investigation to be requested because of its simplicity, high diagnostic accuracy, and lack of radiation. Detection of renal parenchymal gas on ultrasound requires a high index of suspicion and the recognition of echogenic foci with 'dirty' shadowing in a non-dependent position.^{3,4} The appearance can also change with patient posture. It should be differentiated from renal stones, which are echogenic but have clean shadows, and from gas within a renal abscess. Gas can be present inside the collecting system in emphysematous pyelitis,⁵ a condition with a more benign clinical course. In our patient, the clear depiction of gas inside the renal parenchyma with extension to the subcapsular surface confirmed the diagnosis.

SY Hui, BSc, RDMS

Email: amy_huisy@hotmail.com

CW Cheung, MRCP, FHKAM (Radiology)

KT Hui, MB, BS, FRCR

HL She, MB, BS

Department of Radiology

Queen Mary Hospital

Pokfulam Road, Hong Kong

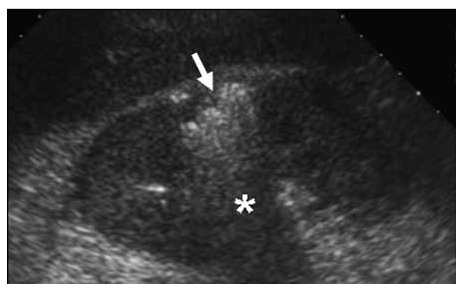

FIG 1. Longitudinal scan of the right kidney showing echogenic foci of air (arrow) inside the renal parenchyma. Note the 'dirty' shadow (*)

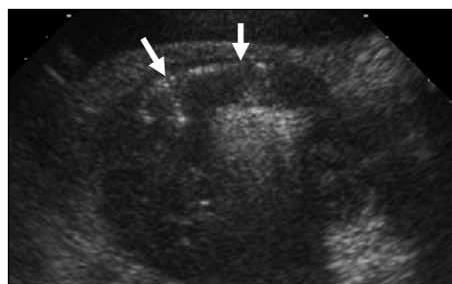


FIG 2. Transverse scan of the right kidney showing crescent-shaped echogenicity compatible with subcapsular air (arrows)

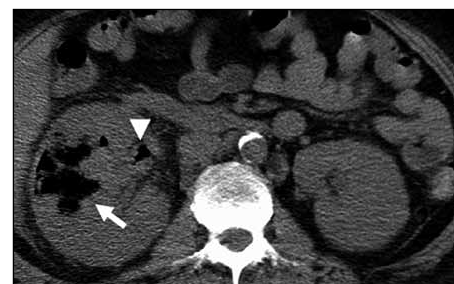


FIG 3. Axial non-enhanced computed tomographic scan of the kidneys showing right renal enlargement and presence of air in the renal parenchyma (arrow) and renal pelvis (arrowhead)

References

1. Grayson DE, Abbott RM, Levy AD, Sherman PM. Emphysematous infections of the abdomen and pelvis: a pictorial review. *Radiographics* 2002;22:543-61.
2. Wan YL, Lee TY, Bullard MJ, Tsai CC. Acute gas-producing bacterial renal infection: correlation between imaging findings and clinical outcome. *Radiology* 1996;198:433-8.
3. Craig WD, Wagner BJ, Travis MD. Pyelonephritis: radiologic-pathologic review. *Radiographics* 2008;28:255-77.
4. Allen HA 3rd, Walsh JW, Brewer WH, Vick CW, Haynes JW. Sonography of emphysematous pyelonephritis. *J Ultrasound Med* 1984;3:533-7.
5. Roy C, Pflieger DD, Tuchmann CM, Lang HH, Saussine CC, Jacq min D. Emphysematous pyelitis: findings in five patients. *Radiology* 2001;218:647-50.