

# Role of Multidetector Computed Tomography in the Assessment of Olfactory Fossa Depth among the South Indian Population: A Cross-sectional Study

CHANDRASEKHARA RAO KONDRAGUNTA<sup>1</sup>, SATISH KUMAR KESINAKURTHI<sup>2</sup>, SATYA CHOWDARY MORAMPUDI<sup>3</sup>, SREEJA GOGULA<sup>4</sup>, SATISH CHANDRA TRIPURANENI<sup>5</sup>



## ABSTRACT

**Introduction:** Functional Endoscopic Sinus Surgery (FESS) is one of the most commonly performed surgeries for sinusitis. The olfactory fossa is prone to injury during FESS and the risk of injury depends on the depth of the olfactory fossa.

**Aim:** To assess the depth of the olfactory fossa by multidetector Computed Tomography (CT) and to study the incidence and distribution of asymmetry of olfactory fossa depth.

**Materials and Methods:** A cross-sectional, observational study was conducted at Department of Radiology, Dr. Pinnamaneni Siddhartha Institute of Medical Sciences and Research Foundation, Gannavaram, Andhra Pradesh, India from November 2019 to October 2019. The sample size was 500 patients. All patients above the age of 18 years who were referred to the department of radiology for CT paranasal sinuses were included. Olfactory fossa depth was calculated from the CT scan and statistical analysis was done comparing it with the variables such as age, gender and side of fossa.

**Results:** Out of total 500 participants, 311 (74.2%) patients in the study were males. The mean age of patients was  $40.3 \pm 16.05$  years. There was no significant difference in the olfactory fossa depth on the right side ( $p$ -value=0.6) and left side ( $p$ -value=0.9) in both genders. A total of 400 (80%) patients of the cases had asymmetry of the olfactory fossa. In males, the most common ( $n=294$ , 79.2%) was type 2 Keros on the right and 280 (75.5%) patients on the left side. In females on the right side, type 1 Keros was more common (52 patients, 40.3%) and on the left side type 2 Keros was more common (60 patients, 46.5%) and there was a significant difference in the proportion of different types of Keros in both genders ( $p$ -value <0.001). There was no significant difference in the proportion of Keros types among the different age groups.

**Conclusion:** There was a significant difference in the proportion of Keros types among males and females and the majority of the patients had asymmetry. Prospective studies with intraoperative information from the surgeon can add further information on the utility of the Keros grade.

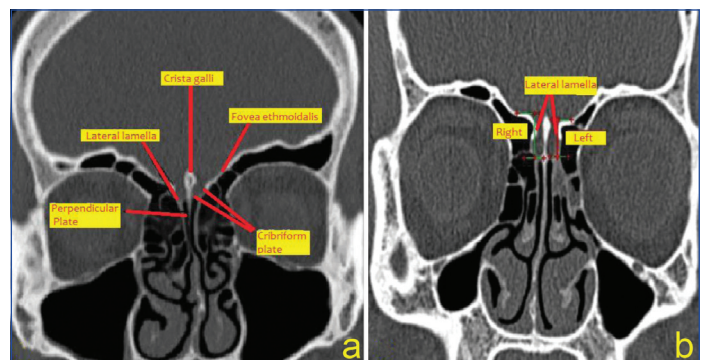
**Keywords:** Craniofacial trauma, Functional endoscopic sinus surgery, Keros classification, Sinusitis

## INTRODUCTION

Sinusitis is a common problem in today's world affecting the cost and productivity of the population [1]. It is caused due to chronic inflammation of the mucosa of the nose, and paranasal sinuses which are outpouchings of the nasal cavity. Apart from medical treatment, Functional Endoscopic Sinus Surgery (FESS) is one of the most commonly performed surgeries for the treatment of chronic rhinosinusitis [2]. Though it is one of the most commonly performed procedures by otorhinologists, this surgery is not without complications. Serious complications include injury to the skull base and orbital walls while operating, leading to cerebrospinal fluid leakage, meningitis and orbital injuries [3].

Most of the injuries in FESS occur while operating, due to the difficult anatomy of the nose and paranasal sinuses. The olfactory fossa is one such region that should be safeguarded while operating, as it forms the roof of the brain and shares a common wall with the orbit [4]. The olfactory fossa is a small depression in the ethmoid bone harbouring the olfactory mucosa for the smell. It is bounded above by the cribriform plate, medially by the perpendicular plate of the ethmoid, and laterally by the lateral lamella [Table/Fig-1a]. The depth of the olfactory fossa depends on the length of the lateral lamella [Table/Fig-1b] [2,4]. Keros P has proposed a classification based on the depth of the olfactory fossa [5].

As the depth of the olfactory fossa increases, the chance of injury to the ethmoid bone during surgery increases and so does the risk



**[Table/Fig-1]:** Coronal section of the computerised tomography image showing, a) Normal anatomy, b) Lateral lamella used for measuring the olfactory fossa depth.

of complications. Computed Tomography (CT) is the most common investigation used to study the depth of the olfactory fossa and other anatomical abnormalities of the olfactory fossa. Even though Keros P gave the classification long ago, with the widespread use of endoscopic surgery in the past decade for the treatment of chronic sinusitis, it has come to clinical relevance recently [5-7]. Type 1 is called the safe type and type 3 is called the dangerous type of olfactory fossa, as the incidence of injury increases during surgery with the increase in the depth of the olfactory fossa [7]. Even though there are several studies from different regions of the world regarding the assessment of the olfactory fossa depth, there is wide variation in the results among the studies due to the regional variation of the

population anthropometric data. In a large country like India which housed many different civilisations in different regions of the country in the past, a wide heterogeneity within the country is expected. Regional studies helps in bringing out these variations. Previous studies in their inference have raised this issue of discordant results, especially with respect to the extent of asymmetry of olfactory fossa depth on both the sides [7-12]. The aim of the present study was to assess the depth of the olfactory fossa by multidetector computed tomography and to study the incidence and distribution of asymmetry of olfactory fossa depth in the population of Andhra Pradesh, India which is located in the Southern part of India along the eastern coast.

## MATERIALS AND METHODS

A cross-sectional, observational study was conducted at Dr. Pinnamaneni Siddhartha Institute of Medical Sciences and Research Foundation, Gannavaram, Andhra Pradesh, India, from November 2019 to October 2021. The Institutional Ethics Committee approval was obtained prior to the commencement of the study (IEC no. PG/490/19). All patients were enrolled in the study after taking their written informed consent.

**Sample size calculation:** With a margin of error 5% and confidence interval of 99% taking study by Pawar A et al., as the reference which showed an olfactory fossa asymmetry prevalence of 11.5%, minimum sample size required was 271 patients calculated [7]. Sample size in the present study was 500 patients which is ahead of the required minimum sample size.

**Inclusion criteria:** Patients >18 years of age and with complaints suggestive of sinusitis advised for CT paranasal sinuses were included in the study.

**Exclusion criteria:** Patients with a history of craniofacial trauma, sinonasal malignancy, and with history of surgeries in the paranasal sinus region were excluded from the study.

## Study Procedure

The CT images were collected from the images obtained using coronal sections of paranasal sinuses by 16 slice CT SIEMENS SOMATOM (Siemens healthcare, Mumbai, India) and were analysed in bone window settings on OsiriX software (version OsiriX MD). Tube voltage used was kVp 130, mA 60, 0.6 mm continuous axial slices. For each set of images, a multiplanar view was created by the software to analyse the best coronal sequence showing clearly the cribriform plate and the lateral lamellae and olfactory fossa depth was measured.

The following established anatomical points were identified and used for measuring the olfactory fossa depth: 1. Fovea ethmoidalis 2. Cribriform plate 3. Lateral lamella.

The measurements of both the right and left lateral lamellae on the CT scan were measured. The height of the lateral lamella was measured to determine the depth of the olfactory fossa in the images in millimetres (mm) [Table/Fig-1b]. The olfactory fossae depth was graded according to Keros classification [7].

- Type 1: has a depth of <3.9 mm
- Type 2: has a depth of 4-7.9 mm
- Type 3: has a depth of >8 mm

In the present study, the asymmetry between olfactory fossa depths on both the sides was considered when there was a difference of  $\geq 0.1$  mm [8]. All the calculations were done by the same investigator to avoid interobserver bias.

## STATISTICAL ANALYSIS

Data obtained was entered in Microsoft excel software (Microsoft Corporation, Washington) and analysed by using Statistical Package for the Social Sciences (SPSS) software (International Business

Machines Corporation, New York). Descriptive statistics was represented with frequencies and percentages. If data followed normal distribution, parametric tests were done otherwise non parametric tests were done. Measurements between the right and left sides were compared. The p-value was calculated using Student's t-test for comparing between the mean depth on right and left-sides. A p-value of <0.05 was considered statistically significant.

## RESULTS

Out of 500 patients, 371 (74.2%) patients were males and 129 (25.8%) were females [Table/Fig-2]. The age of the patients ranged from 18-84 years. The mean $\pm$ Standard Deviation (SD) age of patients was 40.3 $\pm$ 16.05 years [Table/Fig-2].

Variables	n (%)
<b>Gender</b>	
Males	371 (74.2)
Females	129 (25.8)
<b>Age groups (in years)</b>	
<30	178 (35.6)
31-40	115 (23)
41-50	77 (15.4)
51-60	61 (12.2)
>60	69 (13.8)

[Table/Fig-2]: Table showing the gender and age distribution of the study population.

The depth of the olfactory fossa on the right side ranged from 1.9-10 mm. The mean $\pm$ SD depth on the right side was 5.26 $\pm$ 1.74 mm. The depth of the olfactory fossa on the left side ranged from 2-10 mm. The mean $\pm$ SD depth on the left side was 5.33 $\pm$ 1.77 mm. The mean $\pm$ SD depth of the olfactory fossa on both the sides together is 5.30 $\pm$ 1.76 mm. In the present study, the mean depth of olfactory fossa in males and females, on both the sides was not statistically significant [Table/Fig-3].

Side	Olfactory fossa depth (mm) (Mean $\pm$ SD)		p-value
Right	Males	5.31 $\pm$ 1.69	0.6 <sup>†</sup>
	Females	5.2 $\pm$ 1.8	
	Total	5.26 $\pm$ 1.74	
Left	Males	5.32 $\pm$ 1.69	0.9 <sup>†</sup>
	Females	5.35 $\pm$ 1.86	
	Total	5.33 $\pm$ 1.77	

[Table/Fig-3]: Comparison of olfactory fossa depth between males and females. SD: Standard deviation; <sup>†</sup>Independent t-test

Among 500 cases in this study, 400 patients had asymmetry and 100 patients had symmetry on both sides. Among 400 patients with asymmetry, 301 patients were males and 99 were females and among 100 patients with symmetry, 70 were males and 30 were females. Using Chi-square test, statistical analysis was calculated (p-value=0.28) and Chi-square value was 1.48 and showed no significant association between distribution of symmetry and asymmetry of olfactory fossa and gender.

Among the total 1000 sides, type 1 was seen in 229 (22.9%) sides, type 2 was seen in 682 (68.2%) sides, and type 3 was seen in 89 sides (8.9%). On the right side, type 1 was seen in 112 (22.4%) patients, type 2 was seen in 342 (68.4%) patients, and Keros type 3 was seen in 46 (9.6%) patients. On the left side, 117 (23.4%) patients were Keros type 1, 340 (68.0%) patients were type 2, and 43 (8.6%) patients were type 3.

Among a total of 371 males, on the right side, Keros type 1 was seen in 60 (16.2%) patients, type 2 was seen in 294 (79.2%) patients and type 3 was seen in 17 (4.6%) patients [Table/Fig-4]. Among a total of 129 females, Keros type 1 was seen in 52 (40.3%) patients,

type 2 was seen in 48 (37.2%) patients, and type 3 was seen in 29 (22.5%) patients [Table/Fig-4]. Using Chi-square test, p-value was <0.001. Among males, on the left side Keros type 1 was seen in 71 (19.1%) patients, type 2 was in 280 (75.5%) patients, and type 3 was seen in 20 (5.4%) patients. Among females, on the left side type 1 was seen in 46 (35.7%) patients, type 2 was seen in 60 (46.5%) patients, and type 3 was seen in 23 (17.8%) patients [Table/Fig-4]. Using Chi-square test, p-value obtained as <0.001. There was no significant association between age and Keros type on the right and left side [Table/Fig-5].

Keros types	Right		Left	
	Males n (%)	Females n (%)	Males n (%)	Females n (%)
Type 1	60 (16.2)	52 (40.3)	71 (29.1)	46 (35.7)
Type 2	294 (79.2)	48 (37.2)	280 (75.5)	60 (46.5)
Type 3	17 (4.6)	29 (22.5)	20 (5.4)	23 (17.8)
Total	371 (100)	129 (100)	371 (100)	129 (100)
p-value	<0.001*		<0.001*	

[Table/Fig-4]: Distribution of Keros types among males and females.

\*p-value <0.05 was considered statistically significant (Chi-square test)

Age group (Years)	Keros types						Total (n)
	Type 1		Type 2		Type 3		
	Right n (%)	Left n (%)	Right n (%)	Left n (%)	Right n (%)	Left n (%)	
<30	41 (11.5)	37 (10.4)	120 (33.7)	128 (35.95)	17 (4.8)	13 (3.65)	356
31-40	25 (10.85)	26 (11.3)	82 (35.65)	80 (34.8)	8 (3.5)	9 (3.9)	230
41-50	19 (12.35)	17 (11.05)	48 (31.15)	51 (33.1)	10 (6.5)	9 (5.85)	145
51-60	14 (11.5)	19 (15.55)	39 (31.95)	35 (23.7)	8 (6.05)	7 (5.75)	122
>60	13 (9.4)	18 (13.05)	53 (38.4)	46 (33.35)	3 (2.15)	5 (3.6)	138

[Table/Fig-5]: Distribution of Keros types among the different age groups in the present study.

Parameters of the study	Present study	Babu AC et al., [8]	Salroo IN et al., [9]	Pawar A et al., [7]	Nair S [10]	Ali A et al., [11]	Jacob TG and Kaul JM [12]
Place and year of the study	Andhra Pradesh, 2021	Kerala, 2016	Kashmir, 2015	Maharashtra, 2017	Karnataka, 2011	Tamil Nadu, 2004	Delhi, 2014
Sample size (N)	500	1200	100	200	180	75	32
Type 1 Keros	22.4%	17.5%	29%	18.5%	17.2%	20%	23.44%
Type 2 Keros	68.4%	74.6%	61%	74.5%	77.2%	59%	70.8%
Type 3 Keros	9.6%	7.9%	10%	7%	5.6%	2%	5.7%

[Table/Fig-6]: Comparison of the Keros classification of the present study with other Indian studies [7-12].

## DISCUSSION

The paranasal region is a complex anatomical region with a wide range of variations. These variations make FESS surgery a challenging task. To avoid complications one must be aware of the anatomical variations, with the olfactory fossa being one of the regions prone to complications. The integrity of the lamina papyracea may be violated during surgery. The optic nerve is in close proximity to both the sphenoid and ethmoid sinuses and may be injured directly during posterior ethmoidectomy and sphenoidectomy. Intracranial complications include Cerebrospinal Fluid (CSF) leak, intracranial haematoma, subarachnoid bleed, cerebritis, abscess, pneumocephalus and meningoencephalocele. It is now mandatory to evaluate peripheral nasal sinuses on CT before the surgery which provides a base to guide the head and neck surgeon during the operation and helps in the surgical approach correctly. If the depth of the lateral plate of the cribriform plate increases, the olfactory fossa will be narrower, and deeper and the roof of the ethmoid will be lower and hanging which increases the risk of operative injury.

The mean±SD age in the present study population was 36.76±13.82 years. In the study by Kaplanoglu H et al., 500 cases were studied and the mean age of the patients was 39.41 years with a median value of 38 years (Age range: 18-81 years) [6]. In a study done by Pawar A et al., type 2 (74.5%) olfactory fossa was the commonest in

the population of western Maharashtra, India [7]. This was followed by type 1 (18.5%) and type 3 (7%) Keros. In the present study, the findings were similar with Keros type 2 being the most common (68.2%), followed by type 1 (2.9%) and type 3 (8.9%). In another study done by Babu AC et al., on 1200 patients, type 2 Keros was the most common (74.6%) followed by type 1 (17.5%) and type 3 (7.9%) [8]. A comparison of the prevalence of Keros classification in different Indian studies is shown in [Table/Fig-6] [7-12].

In the present study, mean±SD olfactory fossa depth on the right side and left side was 5.26±1.74 mm and 5.33±1.77 mm, respectively. In a study done by Babu AC et al., mean olfactory fossa depth on the right side and on the left side was 5.27 mm and 5.25 mm respectively with no significant difference in the depth of olfactory fossa between the two sides [8]. In a study done by Srivastava S et al., the mean olfactory fossa depth on the right side and left side was 5.17 mm and 5.15 mm with no significant difference between the two sides [13]. In the study by Mikail I et al., the mean olfactory fossa depth on right and left side was 5.26 mm and 5.33 mm, respectively [Table/Fig-6] [14].

In the present study, there was a significant difference between males and females in the proportion of Keros types. No significant

correlation was seen in the distribution of Keros types between males and females in the study done by Salroo IN et al., [9]. However, in the study done by Srivastava S et al., particularly on the right side, there was a statistically significant link between sex and Keros type [13].

In the present study out of 500 patients, 400 (80%) patients showed asymmetry on both sides and 100 (20%) patients showed symmetry. In a study done by Babu AC et al., 75% of the subjects showed asymmetry in the depth on either side and its prevalence was almost similar in males (75.8%) and females (74%) [8]. In a study done by Pawar A et al., there was a statistically significant asymmetry in the depth of right and left olfactory fossae in males, right being deeper and no statistically significant asymmetry was seen in females [7]. In the present study on either sides, no significant correlation was found between sex and the distribution of symmetric and asymmetric olfactory fossa.

In a study by Karatay E and Avcı H mean olfactory fossa depth on the right side was 4.86 mm, and the mean depth was 4.91 mm on the left side [15]. In the same study statistically, a significant difference was found between males and females with respect to olfactory fossa depth on the left side but there was no statistical difference in the olfactory fossa depth on the right side [15]. In the study by Naidu L et al., in the South African population, the median



olfactory fossa depth was 5.75 mm and there was a statistically significant difference in the olfactory fossa depth among males and females [16]. However, the most common type of Keros type was type 2 in the study by Naidu L et al., as in the present study. In the present study, there was no statistically significant difference in the olfactory fossa depth between males and females on both right and left-side in contrast to the studies by Karatay E et al., and Naidu L et al., [15,16].

In the study by Costa ALF et al., on South American population, the most common Keros type was type 2 as in the present study [17]. There was no statistical difference between the gender and distribution of Keros types in the study by Costa ALF et al., as in the present study [17]. In a study by Keskek CO and Aytugar E on Turkish population the most common Keros type was type 2 [18]. In the same study, it was shown that there was no significant change in the olfactory fossa dimensions corresponding to the nasal deviation side [18]. However, in the study by Sahan MH et al., the olfactory fossa depth is significantly higher on the side, contralateral to the nasal septum deviation [19]. In a study by Fadda GL et al., there was a correlation between olfactory fossa depth and the extent of pneumatization of the frontal sinus [20].

### Limitation(s)

No prospective comparison has been made with the incidence of injuries during surgery and surgeon difficulty level while operating, with the olfactory fossa depth. The study may also have a centripetal bias because the present study institution is a tertiary care centre.

### CONCLUSION(S)

Olfactory fossa depth varies on the right and left sides as predominant number of patients have asymmetry. There was no significant variation in the olfactory fossa depth between males and females. Based on the most prevalent type of Keros, males can be considered to have intermediate risk for injury during surgery as type 2 Keros is common on both the sides. Females can be considered to have a lower risk on the right side than left side as type 1 Keros is more common on the right side in females. The proportion of dangerous type 3 Keros, is more common in females than males placing them at a greater risk of injury during surgery. Prospective studies with intraoperative information from the surgeon can add further information on the utility of the Keros grade and risk stratify patients. Also, there is some discoordination between the results from the various studies published worldwide, which can be explained due to the variation in the population composition due to ethnicity and race.

### REFERENCES

- [1] Rudmik L, Smith TL, Schlosser RJ, Hwang PH, Mace JC, Soler ZM, et al. Productivity costs in patients with refractory chronic rhinosinusitis. *Laryngoscope*. 2014;124(9):2007-12. Doi: 10.1002/lary.24630.

- [2] Murthy AV, Santosh B. A study of clinical significance of the depth of olfactory fossa in patients undergoing endoscopic sinus surgery. *Indian J Otolaryngol Head Neck Surg*. 2017;69(4):514-22. Doi: 10.1007/s12070-017-1229-8.
- [3] Koizumi M, Suzuki S, Matsui H, Fushimi K, Yamasoba T, Yasunaga H, et al. Trends in complications after functional endoscopic sinus surgery in Japan: A comparison with a previous study (2007-2013vs. 2013-2017). *Auris Nasus Larynx*. 2020;47(5):814-19. Doi: 10.1016/j.anl.2020.04.003.
- [4] Hamour AF, Kus L, Monteiro E, Scheffler P, Lee J, Vescan A, et al. Radiological anatomy of the olfactory fossa: Is skull base anatomy really ever "safe"? *J Neurotol Surg B Skull Base*. 2020;83(1):53-58. Doi: 10.1055/s-0040-1716690.
- [5] Keros P. On the practical value of differences in the level of the lamina cribrosa of the ethmoid. *Z Laryngol Rhinol Otol*. 1962;41:809-13. PMID: 14032071.
- [6] Kaplanoglu H, Kaplanoglu V, Dilli A, Toprak U, Hekimoglu B. An analysis of the anatomic variations of the paranasal sinuses and ethmoid roof using computed tomography. *Eurasian J Med*. 2013;45(2):115-25. Doi: 10.5152/eajm.2013.23.
- [7] Pawar A, Konde S, Bhole P. Assessment of depth of olfactory fossa in prefunctional endoscopic sinus surgery computed tomography scan of paranasal sinuses. *Int J Otorhinolaryngology Head Neck Surg*. 2017;4:83-86. Doi: 10.18203/ISSN.2454-5929.IJOHNS20174663
- [8] Babu AC, Nair MRPB, Kuriakose AM. Olfactory fossa depth: CT analysis of 1200 patients. *Indian J Radiol Imaging*. 2018;28(4):395-400. Doi: 10.4103/ijri.IJRI\_119\_18.
- [9] Salroo IN, Dar NH, Yousuf A, Lone KS. Computerized tomographic profile of ethmoid roof on basis of keros classification among ethnic Kashmiri's. *Int J Otorhinolaryngology Head Neck Surg*. 2016;2:01-05. Doi: 10.18203/issn.2454-5929.ijohns20151134.
- [10] Nair S. Importance of ethmoidal roof in endoscopic sinus surgery. *Sci Rep*. 2012;1:251. Doi: 10.4172/scientificreports.251.
- [11] Ali A, Kurien M, Shyamkumar NK. Anterior skull base: High risk areas in endoscopic sinus surgery in chronic rhinosinusitis: A computed tomographic analysis. *Indian J Otolaryngol Head Neck Surg*. 2005;57(1):05-08. Doi: 10.1007/BF02907616.
- [12] Jacob TG, Kaul JM. Morphology of the olfactory fossa—A new look. *J Anatomic Soc India*. 2014;63:30-35. Doi: 10.1016/j.jasi.2014.04.006.
- [13] Srivastava S, Sylvania SC, Ayoub I. Assessment of depth of olfactory fossa in prefunctional endoscopic sinus surgery computed tomography scan of paranasal sinuses. *European Journal of Molecular and Clinical Medicine*. 2021;8(4):935-93. Doi: 10.33545/26644436.2020.v3.i4b.143.
- [14] Mikail I, Nuray MB, Osman AK, Safa S. Is there a relationship between keros classification of olfactory fossae depth, septal deviation angle and the distance between infraorbital foramina? *Current Medical Imaging*. 2018;14(5):1382-88 Doi: 10.1097/SCS.0000000000001597.
- [15] Karatay E, Avci H. Evaluation of olfactory fossa anatomy by computed tomography and the place of keros classification in functional endoscopic sinus surgery. *South Clin Ist Euras*. 2021;32(1):47-52. Doi: 10.14744/scie.2020.88156.
- [16] Naidu L, Sibiya LA, Aladeyelu OS, Rennie CO. A computed tomography assessment of olfactory fossa depth in relation to functional endoscopic sinus surgery in a South African population. *Translational Research in Anatomy*. 2022;28:100219. Doi: doi.org/10.1016/j.tria.2022.10021.
- [17] Costa ALF, Paixão AK, Gonçalves BC, Ogawa CM, Martinelli T, Maeda FA, et al. Cone beam computed tomography-based anatomical assessment of the olfactory fossa. *Int J Dent*. 2019;2019:4134260. Doi: 10.1155/2019/4134260.
- [18] Keskek CO, Aytugar E. Radiological evaluation of olfactory fossa with cone-beam computed tomography. *J Oral Maxillofac Res*. 2021;12(3):e3. Doi: 10.5037/jomr.2021.12303.
- [19] Sahan MH, Inal M, Muluk NB, Simsek G. Cribriform plate, crista galli, olfactory fossa and septal deviation. *Curr Med Imaging Rev*. 2019;15(3):319-25. Doi: 10.2174/1573405614666180314150237.
- [20] Fadda GL, Petrelli A, Martino F, Succo G, Castelnovo P, Bignami M, et al. Anatomic variations of ethmoid roof and risk of skull base injury in endoscopic sinus surgery: Statistical correlations. *Am J Rhinol Allergy*. 2021;35(6):871-78. Doi: 10.1177/19458924211020549.

#### PARTICULARS OF CONTRIBUTORS:

1. Professor and Head, Department of Radiology, Dr. Pinnamaneni Siddhartha Institute of Medical Sciences and Research Foundation, Vijayawada, Andhra Pradesh, India.
2. Resident, Department of Radiology, Dr. Pinnamaneni Siddhartha Institute of Medical Sciences and Research Foundation, Vijayawada, Andhra Pradesh, India.
3. Resident, Department of Radiology, Dr. Pinnamaneni Siddhartha Institute of Medical Sciences and Research Foundation, Vijayawada, Andhra Pradesh, India.
4. Resident, Department of Radiology, Dr. Pinnamaneni Siddhartha Institute of Medical Sciences and Research Foundation, Vijayawada, Andhra Pradesh, India.
5. Professor, Department of Ear, Nose and Throat, Dr. Pinnamaneni Siddhartha Institute of Medical Sciences and Research Foundation, Vijayawada, Andhra Pradesh, India.

#### NAME, ADDRESS, E-MAIL ID OF THE CORRESPONDING AUTHOR:

Dr. Satya Chowdary Morampudi,  
Resident, Department of Radiology, Dr. Pinnamaneni Siddhartha Institute of Medical Sciences and Research Foundation, Gannavaram, Vijayawada, Andhra Pradesh, India.  
E-mail: satyachowdarym@gmail.com

#### AUTHOR DECLARATION:

- Financial or Other Competing Interests: None
- Was Ethics Committee Approval obtained for this study? Yes
- Was informed consent obtained from the subjects involved in the study? Yes
- For any images presented appropriate consent has been obtained from the subjects. Yes

#### PLAGIARISM CHECKING METHODS: [Jain H et al.]

- Plagiarism X-checker: Sep 20, 2022
- Manual Googling: Sep 27, 2022
- iThenticate Software: Oct 25, 2022 (24%)

#### ETYMOLOGY: Author Origin

Date of Submission: **Sep 17, 2022**  
Date of Peer Review: **Oct 10, 2022**  
Date of Acceptance: **Oct 27, 2022**  
Date of Publishing: **Jan 01, 2023**