

Chronic intestinal pseudo-obstruction due to eosinophilic myenteric ganglionitis: A report of two cases

Keith Cordner, Paul Tender, Ike Uzoaru

ABSTRACT

Eosinophilic myenteric ganglionitis (EMG) is a rare cause of chronic intestinal pseudo-obstruction (CIPO). While patients are typically in the first decade of life, and predominantly female, rare cases can be seen in adults. Patients present with constipation, abdominal distention, and tenderness with surgery as the mainstay of treatment. While outcomes are normally favorable after surgery, malnutrition, and surgical errors can lead to postoperative complications. A high index of suspicion for EMG, albeit rare, should be entertained in cases of CIPO since these patients usually have normal colonoscopy and/or biopsies due to the involvement of the myenteric plexus and sparing of the submucosal plexus. We report two cases of patients who underwent colon resection for CIPO complicated by sigmoid volvulus, and histologically characterized by colonic EMG and hypoganglionosis.

Keywords: Chronic intestinal pseudo-obstruction, Eosinophilic myenteric ganglionitis, Hypoganglionosis, Megacolon, Sigmoid volvulus

How to cite this article

Cordner K, Tender P, Uzoaru I. Chronic intestinal pseudo-obstruction due to eosinophilic myenteric ganglionitis: A report of two cases. *J Case Rep Images Pathol* 2022;8(1):100059Z11KC2022.

Keith Cordner¹, MS, Paul Tender^{1,2}, MD, Ike Uzoaru^{1,3}, MD
Affiliations: ¹Carle Illinois College of Medicine, 807 S. Wright Street, Champaign, IL 61820, USA; ²Department of Colorectal Surgery, Carle Foundation Hospital, 611 W. Park Street, Urbana, IL 61801, USA; ³Department of Pathology, Carle Foundation Hospital, 611 W. Park Street, Urbana, IL 61820, USA.

Corresponding Author: Ike Uzoaru, MD, Department of Pathology, Carle Foundation Hospital and Carle Illinois College of Medicine, 611 W. Park Street, Urbana, IL 61801, USA; Email: ike.uzoaru@carle.com

Received: 08 June 2021

Accepted: 19 July 2021

Published: 27 January 2022

Article ID: 100059Z11KC2022

doi: 10.5348/100059Z11KC2022CS

INTRODUCTION

Chronic intestinal pseudo-obstruction (CIPO) is a functional intestinal obstruction in the absence of any anatomical obstructive lesions, and may be due to neuropathic, myopathic, or disorders of Cajal cells [1, 2]. Chronic intestinal pseudo-obstruction may be classified as primary, secondary, or idiopathic [1]. Primary can then be subdivided into neuropathies, myopathies, and mesenchymopathies, based on the predominant involvement of enteric neurons, smooth muscle cells, or interstitial cells of Cajal (ICC), respectively.

Secondary CIPO may be due to metabolic, psychiatric, neurologic, or endocrinologic disorders. Furthermore, enteric neuropathies are divided into degenerative, with no inflammation, or inflammatory, referred to as myenteric ganglionitis which may be eosinophilic or lymphocytic based on the predominant inflammatory infiltrate [1].

Small and large bowel may be affected in CIPO and common presentations include abdominal pain, distended abdomen, diarrhea, constipation, and vomiting [2]. Chronic intestinal pseudo-obstruction does not have an obstruction in the intestinal lumen and is clinically diagnosed with imaging.

Eosinophilic myenteric ganglionitis (EMG) is a rare cause of CIPO and characterized by eosinophilic infiltrate in the myenteric plexus with variable hypoganglionosis and sparing the submucosal plexus [3–7]. Although EMG occurs in adults and children, most cases have been reported in children [5, 7, 8]. The small intestine is the organ involved in some of the children in reported cases [5, 7]. Most patients present with constipation, abdominal distention, and tenderness and subsequent surgery as the mainstay of treatment for resection of the affected colon [3, 4, 6]. Some pediatric patients show improvement with immunosuppressive therapy and corticosteroids with or without surgery [5, 7]. We report two cases of patients who presented with longstanding constipation,

abdominal discomfort, and sigmoid volvulus with EMG and hypoganglionosis associated with CIPO and megacolon.

CASE SERIES

Case 1

A 54-year-old man with body mass index (BMI) of 40.62, who had been experiencing constipation for several months, presented with a five-day history of abdominal pain and distension, with no bowel movements. His comorbid conditions included type 2 diabetes mellitus, hypertension, past history of pulmonary embolism on chronic anticoagulation, and sleep apnea syndrome. Upon examination, the abdomen was tender and distended.

An abdominal computed tomography (CT) scan showed dilated loops of large bowel and sigmoid volvulus (Figure 1). The sigmoid colon was 13 cm in diameter. A flexible sigmoidoscopy was performed for decompression and reduction of the sigmoid volvulus with a decompression tube in place. However, the patient's abdominal distension and pain persisted despite conservative measures and he underwent a total colectomy and ileorectostomy three days after admission. The colon and sigmoid were dilated intraoperatively (Figure 2) and his postoperative diagnosis was chronic megacolon with sigmoid volvulus. His Xarelto for pulmonary embolism prophylaxis was restarted on postoperative day 1.

The gross specimen consisted of a 146 cm long segment of colon with attached 2.5 cm terminal ileum. The diameter of the colon ranged from 4.0 to 10.5 cm progressively getting bigger distally. Histologic sections were taken at regular 10 cm intervals from terminal to the distal resection margin and showed increased infiltrate of eosinophils in the myenteric plexus with minimal spillover of eosinophils into the surrounding smooth muscle (Figure 3). There was an accompanying variable reduction of ganglion cells with foci of apparent ganglionic karyorrhexis (Figures 4–6).

The eosinophilic infiltrate was variable with up to 60 eosinophils per high-power field in the areas of greatest density. More distally in the colon, there was reduction in the density of the eosinophilic infiltrate with accompanying relative reduction in ganglion cells. No appreciable lymphocytic infiltrates were seen. Interstitial cells of Cajal highlighted with a CD-117 immunostain was not affected by this process. The submucosal plexus and ganglion cells were not involved in this process and appeared intact. No hypertrophic nerves were seen in the myenteric plexus.

The patient was managed routinely postoperatively and did well until postoperative day nine when he got up for ambulation and collapsed after a short walk. All efforts at resuscitation proved abortive. At autopsy, he had a saddle pulmonary embolism and died of acute cor pulmonale.

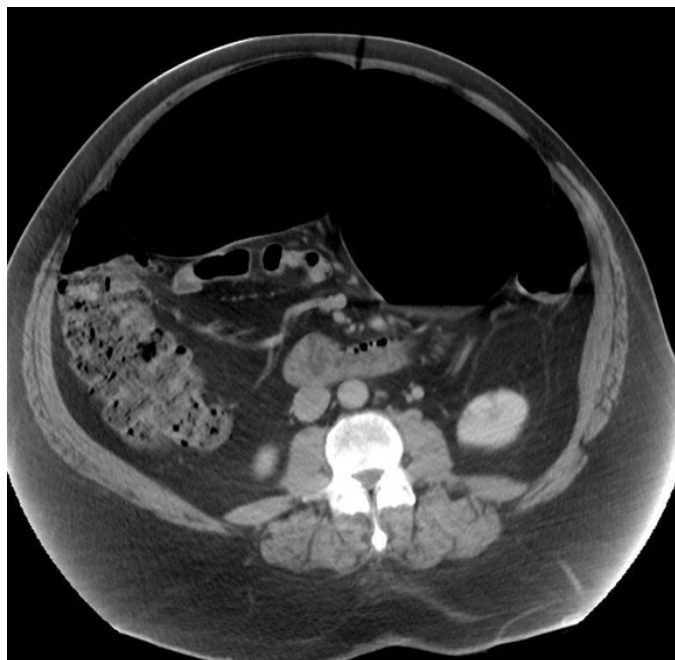


Figure 1: Case 1. CT scan showing dilated colon and sigmoid.

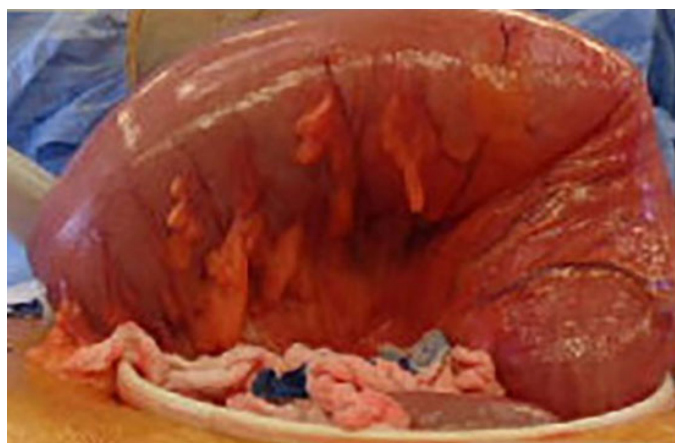


Figure 2: Case 1. Intraoperative finding of dilated colon.

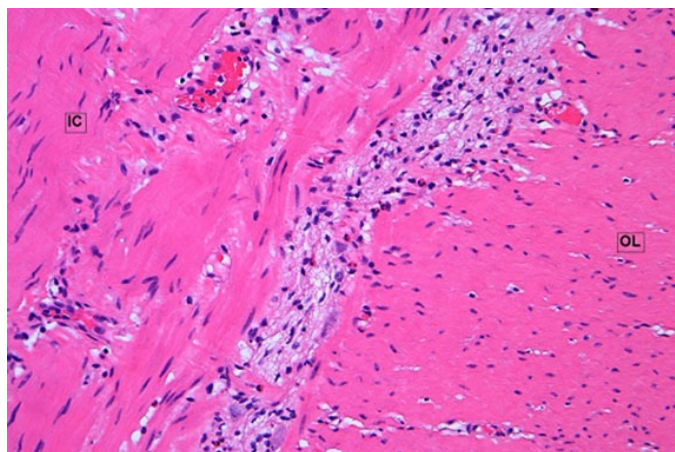


Figure 3: Case 1. Myenteric eosinophils up to 40 per hpf H&E $\times 200$

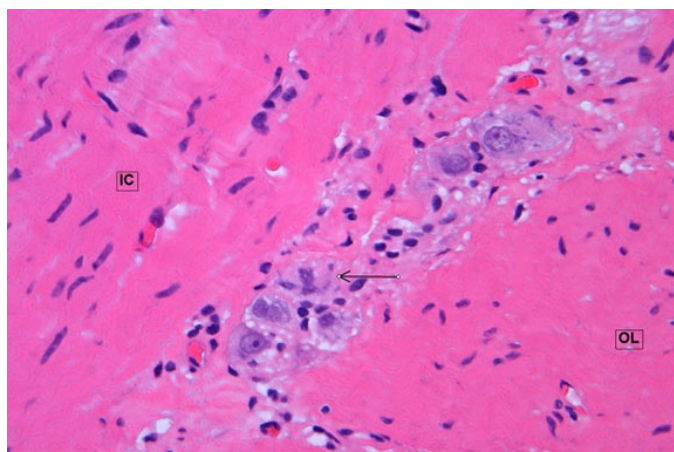


Figure 4: Case 1. Apparent ganglionic karyorrhexis. H&E \times 400. IC: inner circular muscle; OL: outer longitudinal muscle.

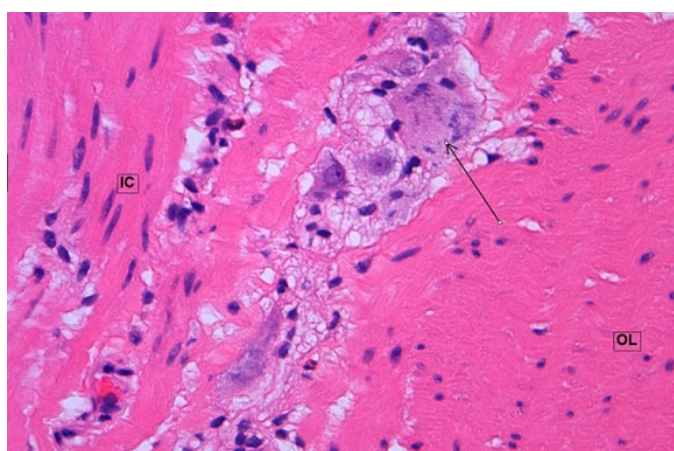


Figure 5: Case 1. Apparent ganglionic karyorrhexis. H&E \times 400.

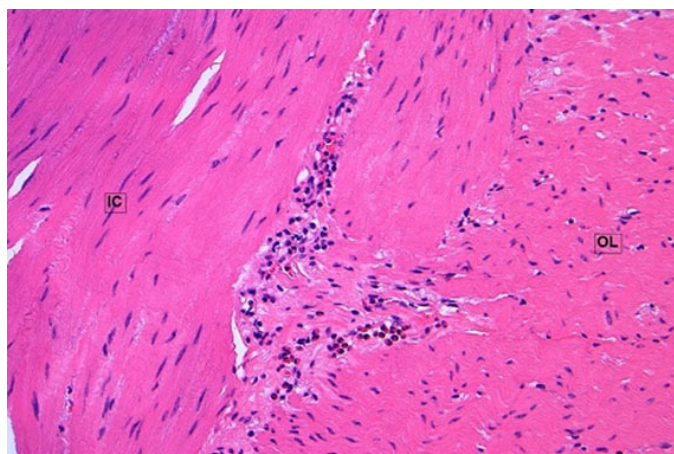


Figure 6: Case 1. Myenteric eosinophils and absence of ganglion cells. H&E \times 200.

Case 2

A 46-year-old man presented with a 12- to 13-month history of alternating constipation and diarrhea. His constipation was relieved with laxatives often leading to explosive diarrhea. The patient complained of pain in the upper abdomen and left lower quadrant. There was a remote history of enlarged colon on barium enema

20 years prior to presentation. His past medical history included hyperlipidemia and hypertension.

Upon physical examination the abdomen was soft with no tenderness or masses. A barium enema showed fixed narrowing in the sigmoid colon and a CT scan showed an enlarged colon. The patient's symptoms progressively worsened due to episodic bloating, cramping, and decreased bowel movements. He also had to pass large volumes of gas at the time. An upper gastrointestinal (GI) and colonoscopy were unremarkable.

However, only the transverse colon, descending colon, sigmoid colon, and rectum were examined as the proximal colon could not be reached/reviewed. After review of the radiologic images, the diagnosis of intermittent sigmoid volvulus was made. He subsequently underwent a laparoscopic sigmoid resection with anastomosis. The significant operative findings included sigmoid volvulus with a significantly dilated and redundant sigmoid colon that occupied virtually all four quadrants of the peritoneal cavity. The remaining course and caliber of the descending, transverse, ascending colon, and cecum were all normal. The small bowel was normal. The gross specimen consisted of a 29 cm long segment of colon designated sigmoid colon and anastomotic rings. The average diameter of the resected segment of colon was 4.5 cm. Histologic sections were taken at regular 2 cm intervals for a total of 18 blocks proximal to distal and showed increased infiltrate of eosinophils in the myenteric plexus with moderate spillover of eosinophils into the surrounding smooth muscle (Figure 7). There was an accompanying variable segmental reduction of ganglion cells and hypertrophic nerves ranging from 50 to 80 μ m in thickness (Figure 8). The eosinophilic infiltrate is variable with up to 12 eosinophils per high-power field in the areas of greatest density. No appreciable lymphocytic infiltrates were seen and ICC highlighted with a CD-117 immunostain was not affected by this process. The submucosal plexus and ganglion cells were not involved.

The patient was managed routinely postoperatively, did well, and was discharged a few days after surgery with no complications. He has continued to do well three months since surgery.

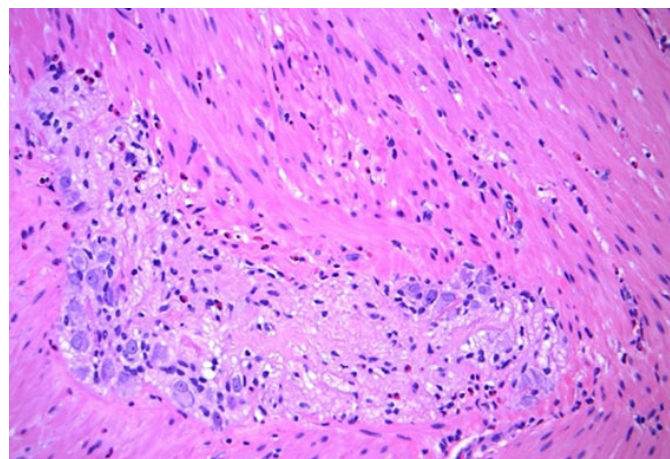


Figure 7: Case 2. Eosinophils in myenteric plexus. H&E \times 200.

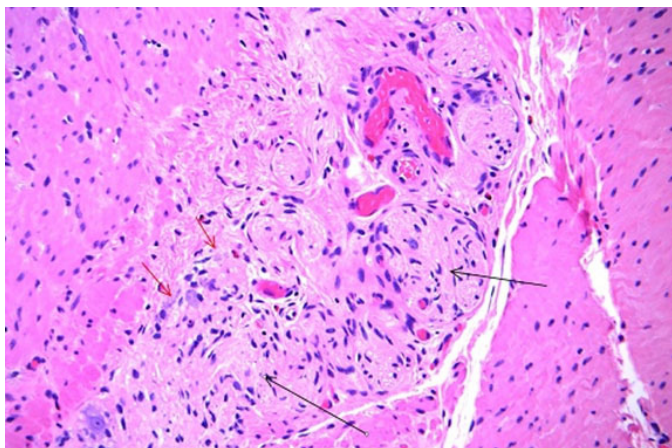


Figure 8: Case 2. Myenteric ganglionic karyorrhexis (red arrows) and hypertrophic nerves (black arrows). H&E × 200.

DISCUSSION

Eosinophilic myenteric ganglionitis is characterized by eosinophilic infiltration of the Auerbach (myenteric) plexus, typically sparing the submucosa and mucosa, and is a rare cause of CIPO [3, 7]. Eosinophilic myenteric ganglionitis differs from eosinophilic enteritis (EE), which has a similar clinical presentation [6, 9]. In EE, the eosinophilic infiltrate is mostly in the mucosa, while the neural plexus is predominantly involved in EMG. It typically presents in children during their first and second decades, raising the possibility of an allergic or infectious mechanism. There was no eosinophilic infiltrate in the mucosa or submucosa in our cases. Furthermore, our patients did not have eosinophilia.

Inflammatory myenteric ganglionitis may sometimes be associated with predominantly lymphocytic infiltrate in the myenteric plexus which is thought to be driven by either T helper or T suppressor cells [10–12] which target unknown antigens on the surface of enteric neurons leading to loss of neurons. Some of these patients have associated circulating autoantibodies and they respond clinically to corticosteroid/immunosuppressive therapy. Lymphocytic ganglionitis may also be associated with paraneoplastic syndromes [13] with attendant chronic intestinal pseudo-obstruction. This neuronal degeneration may lead to complete loss of the neuron. Our patients did not have any malignancy or history of malignancy and there was no significant lymphocytic infiltrate in the sections of the colon. Hypertrophic nerves were noted in the myenteric plexus of case 2 but were not seen in case 1. The significance of this finding is uncertain.

Because EMG typically affects the myenteric plexus in CIPO, an early diagnosis can be elusive which may lead to under representation of this entity in CIPO cases. However, a full-thickness biopsy of the colon, especially in children, may be diagnostic with proper intervention. Schäppi et al. [7] described three children who presented

with functional intestinal obstruction and EMG. These patients in addition had mucosal involvement by eosinophils and lymphocytes. The myenteric plexuses in these patients showed only eosinophilic infiltrate without lymphocytes. Two of the three patients had elevated serum IgE and one patient expressed the eosinophilic chemoattractant interleukin 5 in the ganglia and inflammatory cells in the myenteric plexus suggestive of a delayed type hypersensitivity reaction to food allergens. All three patients improved significantly with steroid/immunosuppressive therapy. We did not stain for interleukin 5 in our cases.

Kapur [8], in histologic evaluation of transition zone of pull-through colonic specimens in 59 patients (60 resection specimens) who had been diagnosed with Hirschsprung disease, found that 15% (9/60) showed diffuse or multifocal eosinophilic periganglionitis with variable eosinophilic intraganglionitis. In addition, rare ganglion cell degeneration was also noted in the midst of myenteric ganglionic eosinophils. We found foci of ganglion cell degeneration in our cases; however, the ICC was not affected. It is possible that some of these patients, especially adult patients, may clinically present with volvulus due to hypoganglionosis as observed in our cases, both of which showed sigmoid volvulus. A similar presentation was described in three patients by Akazawa et al. [3] with all the patients presenting with sigmoid volvulus and hypoganglionosis.

Diabetes mellitus is commonly associated with GI dysfunction and associated with enteric neuropathy [14]. Esophagus, stomach, and intestines may be affected leading to gastroparesis, diarrhea, and constipation. In a case controlled study, Chandrasekharan et al. [15] found that colonic motor dysfunction in human diabetes was associated with enteric neuronal loss and increased oxidative stress. They found that the diabetic ganglia showed decreased ganglion size due to enhanced apoptosis and loss of various neurons including neuronal nitric oxide, neuropeptide Y, choline acetyl transferase, and vasoactive intestinal polypeptide (VIP). They did not see eosinophilic infiltration of the myenteric plexus suggesting that one of our cases (case 1) may have had a different pathway in the disease progression. However, the effect of diabetes mellitus, if any, in our case is uncertain.

CONCLUSION

The pathogenesis of EMG is uncertain and obscure. However, a high index of suspicion should be entertained in cases of CIPO with or without volvulus to rule out this etiology. This is particularly important since EMG almost selectively affects the myenteric plexus and cannot be detected in routine colon biopsy that is not full thickness. The diagnosis is made usually after resection of the affected segments of colon. Surgery is the mainstay of treatment in these patients and the diagnosis is normally

made after histologic examination of the resected specimen.

with enteric neuronal loss and increased oxidative stress. *Neurogastroenterol Motil* 2011;23(2):131–8, e26.

REFERENCES

- De Giorgio R, Sarnelli G, Corinaldesi R, Stanghellini V. Advances in our understanding of the pathology of chronic intestinal pseudo-obstruction. *Gut* 2004;53(11):1549–52.
- Antonucci A, Fronzoni L, Cogliandro L, et al. Chronic intestinal pseudo-obstruction. *World J Gastroenterol* 2008;14(19):2953–61.
- Akazawa Y, Hayashi T, Saito T, et al. Histological characteristics of eosinophilic myenteric ganglionitis: An under-recognised cause of chronic intestinal pseudo-obstruction. *Virchows Arch* 2019;474(3):395–400.
- Lee H, Kang D, Kim H, Cho B, Jang J. Unusual histology of eosinophilic myenteric ganglionitis: A case report. *J Pathol Transl Med* 2017;51(3):320–4.
- Ooms AHAG, Verheij J, Hulst JM, et al. Eosinophilic myenteric ganglionitis as a cause of chronic intestinal pseudo-obstruction. *Virchows Arch* 2012;460(1):123–7.
- Chander B, Fiedler P, Jain D. Eosinophilic myenteric ganglionitis: A case of intestinal pseudo-obstruction in a 93-year-old female. *J Clin Gastroenterol* 2011;45(4):314–6.
- Schäppi MG, Smith VV, Milla PJ, Lindley KJ. Eosinophilic myenteric ganglionitis is associated with functional intestinal obstruction. *Gut* 2003;52(5):752–5.
- Kapur RP. Histology of the transition zone in Hirschsprung disease. *Am J Surg Pathol* 2016;40(12):1637–46.
- Pineton de Chambrun G, Dufour G, Tassy B, et al. Diagnosis, natural history and treatment of eosinophilic enteritis: A review. *Curr Gastroenterol Rep* 2018;20(8):37.
- De Giorgio R, Barbara G, Stanghellini V, et al. Clinical and morphofunctional features of idiopathic myenteric ganglionitis underlying severe intestinal motor dysfunction: A study of three cases. *Am J Gastroenterol* 2002;97(9):2454–9.
- De Giorgio R, Guerrini S, Barbara G, et al. Inflammatory neuropathies of the enteric nervous system. *Gastroenterology* 2004;126(7):1872–83.
- Smith VV, Gregson N, Foggensteiner L, Neale G, Milla PJ. Acquired intestinal aganglionosis and circulating autoantibodies without neoplasia or other neural involvement. *Gastroenterology* 1997;112(4):1366–71.
- Lennon VA, Sas DF, Busk MF, et al. Enteric neuronal autoantibodies in pseudoobstruction with small-cell lung carcinoma. *Gastroenterology* 1991;100(1):137–42.
- Lomax AE, Sharkey KA, Furness JB. The participation of the sympathetic innervation of the gastrointestinal tract in disease states. *Neurogastroenterol Motil* 2010;22(1):7–18.
- Chandrasekharan B, Anitha M, Blatt R, et al. Colonic motor dysfunction in human diabetes is associated

Acknowledgments

The authors acknowledge here individuals who contributed to the work but do not qualify for authorship.

Author Contributions

Keith Cordner – Conception of the work, Interpretation of data, Drafting the work, Final approval of the version to be published, Agree to be accountable for all aspects of the work in ensuring that questions related to the accuracy or integrity of any part of the work are appropriately investigated and resolved

Paul Tender – Conception of the work, Interpretation of data, Drafting the work, Final approval of the version to be published, Agree to be accountable for all aspects of the work in ensuring that questions related to the accuracy or integrity of any part of the work are appropriately investigated and resolved

Ike Uzoaru – Conception of the work, Interpretation of data, Drafting the work, Final approval of the version to be published, Agree to be accountable for all aspects of the work in ensuring that questions related to the accuracy or integrity of any part of the work are appropriately investigated and resolved

Guarantor of Submission

The corresponding author is the guarantor of submission.

Source of Support

None.

Consent Statement

Written informed consent was obtained from the patient for publication of this article.

Conflict of Interest

Authors declare no conflict of interest.

Data Availability

All relevant data are within the paper and its Supporting Information files.

Copyright

© 2022 Keith Cordner et al. This article is distributed under the terms of Creative Commons Attribution License which permits unrestricted use, distribution and reproduction in any medium provided the original author(s) and original publisher are properly credited. Please see the copyright policy on the journal website for more information.

Access full text article on
other devices



Access PDF of article on
other devices





INTERNATIONAL JOURNAL OF
CASE REPORTS AND IMAGES



VIDEO JOURNAL OF
CLINICAL RESEARCH



VIDEO JOURNAL OF
BIOMEDICAL SCIENCE



INTERNATIONAL JOURNAL OF
HEPATOBIILIARY AND
PANCREATIC DISEASES




INTERNATIONAL JOURNAL OF
BLOOD TRANSFUSION AND
IMMUNOHEMATOLOGY



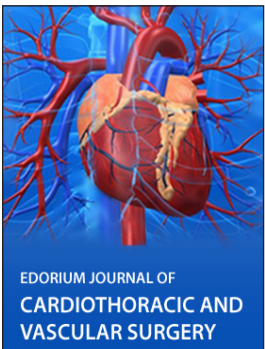
EDORIUM JOURNAL OF
OPHTHALMOLOGY



Submit your manuscripts at
www.edoriumjournals.com



EDORIUM JOURNAL OF
MEDICINE



EDORIUM JOURNAL OF
CARDIOTHORACIC AND
VASCULAR SURGERY



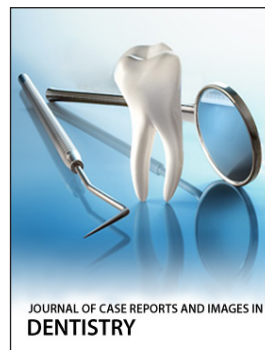JOURNAL OF CASE REPORTS
AND IMAGES IN ORTHOPEDICS
AND RHEUMATOLOGY



EDORIUM JOURNAL OF
PSYCHOLOGY




EDORIUM JOURNAL OF
CELL BIOLOGY



JOURNAL OF CASE REPORTS AND IMAGES IN
DENTISTRY



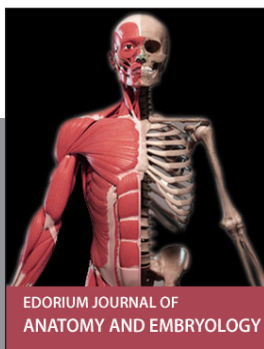EDORIUM JOURNAL OF
CANCER



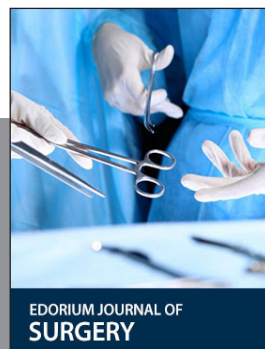
EDORIUM JOURNAL OF
PSYCHIATRY



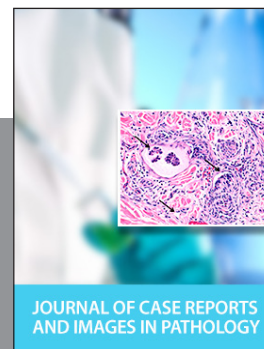JOURNAL OF CASE REPORTS AND
IMAGES IN INFECTIOUS DISEASES



EDORIUM JOURNAL OF
ANATOMY AND EMBRYOLOGY



EDORIUM JOURNAL OF
SURGERY



JOURNAL OF CASE REPORTS
AND IMAGES IN PATHOLOGY



EDORIUM JOURNAL OF
ANESTHESIA