

# Cervical Lymphadenopathy: A Review

Rupali Verma<sup>1</sup>, Shriya Khera<sup>2</sup>

<sup>1</sup>M.D.S- Oral Medicine and Radiology,

<sup>2</sup>Senior Research Associate, Maulana Azad Institute of Dental Sciences, New Delhi

Corresponding Author: Rupali Verma

## ABSTRACT

Cervical lymph node enlargement may be an incidental finding on examination in a patient seeking oral health care, or may be associated with a patient's complaint. The condition is generally not a disease by itself; rather, it may be a symptom of one of many possible underlying problems. It may be localized, limited or generalized in location and/ or acute, subacute or chronic in duration. The etiologies for cervical lymphadenopathy fall under a wide range of spectrum and usually history and physical examination alone may lead to diagnosis. But, unexplained cervical lymphadenopathy is a cause of concern for the physician as it could be a manifestation of an underlying malignancy. However, a methodological approach to lymphadenopathy can disclose the accurate diagnosis causing minimal discomfort to the patient and also less time consuming for the physician.

This article reviews the common causes of lymphadenopathy and presents a methodical clinical approach to a patient with cervical lymphadenopathy.

**Key Words-** Cervical lymphadenopathy, Clinical Evaluation, Differential Diagnosis, Benign, Malignant.

## INTRODUCTION

The human body has about 600 lymph nodes which play the role of filtering the lymph fluid as it circulates throughout the body. The prime function of lymph node is to deal with antigen, whether this is in the form of organisms or other particulate material, or even soluble antigen. The lymph nodes contain T and B cells along with Antigen Presenting Cells which are called the dendritic cells. They form the part of the immune system and function to fight off disease and infections.<sup>3,6,11.</sup>

Lymphadenopathy (LAP) refers to the lymph nodes that are abnormal in size (usually greater than 1 cm) consistency or number.<sup>4,11</sup> In general, there are two mechanisms of lymphadenopathy-hyperplasia and infiltration. The former occurs in response to immunologic or infectious stimuli, and the latter is the result of infiltration by various cell types, including cancer cells, lipid cells, or

glycoprotein-laden macrophages. When this occurs, lymph nodes may be detected clinically. Thus, lymphadenopathy is the term used to describe the clinical sign of swelling of the lymph nodes. Lymphadenitis is the pathologic term for inflammation of the lymph nodes.<sup>1</sup>

The lymph nodes are strategically placed along the drainage of tissue and body fluids with neck containing nearly 2/3<sup>rd</sup> of the total lymph nodes of the body. Cervical lymphadenopathy is quite significant in that there are numerous etiological agents and is an index of spread of infection and malignancy.<sup>6</sup> When cervical lymphadenopathy is detected, a cause can sometimes be determined by careful medical history, thorough physical examination, judicious selection of laboratory tests and, if necessary, a lymph node biopsy.<sup>1</sup>

**EPIDEMIOLOGY-**

The exact incidence of lymphadenopathy is unknown, due to inadequate literature but the number varies from 38-45%. In tropical areas, tuberculosis is the main cause of benign LAP with vast social and massive economic implications. Additionally, increasing cases of HIV in TB patients has increased the incidence of extrapulmonary

TB to 50%. In general practice, less than one percent of patients with LAP have malignant disease, often due to leukemia in younger children and Hodgkin's disease in adolescents. It has been reported that the prevalence of malignancy is 0.4% in patients under 40 years and 4% in those over 40 years of age in the primary care setting.<sup>3,11.</sup>

**DEFINITION AND CLASSIFICATION-**

Pathologic lymph node	>1 cm in adults. >2 cm in pediatric patients, is considered abnormal.
-----------------------	--

Generalized	Enlargement of more than two noncontiguous lymph node groups.
Localized	Limited to one group; cervical involved more than others.
Dermatopathic	Lymphadenopathy associated with skin diseases.

Acute	<2 weeks in duration.
Subacute	2-6 weeks in duration.
Chronic	>6 weeks in duration.

**ETIOLOGY-** The etiologies of lymphadenopathy can be remembered by MIAMI mnemonic-

MALIGNANCIES	Kaposi's Sarcoma, leukemias, lymphomas, multiple myelomas with amyloidosis, skin neoplasms, metastatic from primary sites.
INFECTIONS Bacterial Viral Fungal Granulomatous Others	Brucellosis, Cat-scratch disease, Chancroid, Cutaneous infections (staphylococcus or streptococcus), Lymphogranuloma venerum, primary and secondary Syphilis, Tuberculosis, Tuleremia, Typhoid fever. Adenovirus, Cytomegalovirus, Hepatitis, Herpes Zoster, Human Immunodeficiency Virus, Infectious Mononucleosis, Rubella. Histoplasmosis, Coccidiomycosis, Paracoccidioidomycosis. Berylliosis, Silicosis. Helminthic, Rickettsial, Lyme disease, Scrub typhus, Toxoplasmosis.
AUTOIMMUNE DISORDERS	Dermatomyositis, Rheumatoid Arthritis, Sjogrens Syndrome, Stills Disease, Systemic Lupus Erythematosus.
MISCELLANEOUS/ UNUSUAL	Angiofollicular lymph node hyperplasia (Castleman disease), Histiocytosis, Kawasaki disease, Kikuchi lymphadenitis, Kimura disease, Sarcoidosis, Silicosis, Lipid Storage diseases, Endocrine disease (hyperthyroid, adrenal insufficiency, thyroiditis), Severe hypertriglyceridemia.
IATROGENIC	Medications, Serum Sickness.

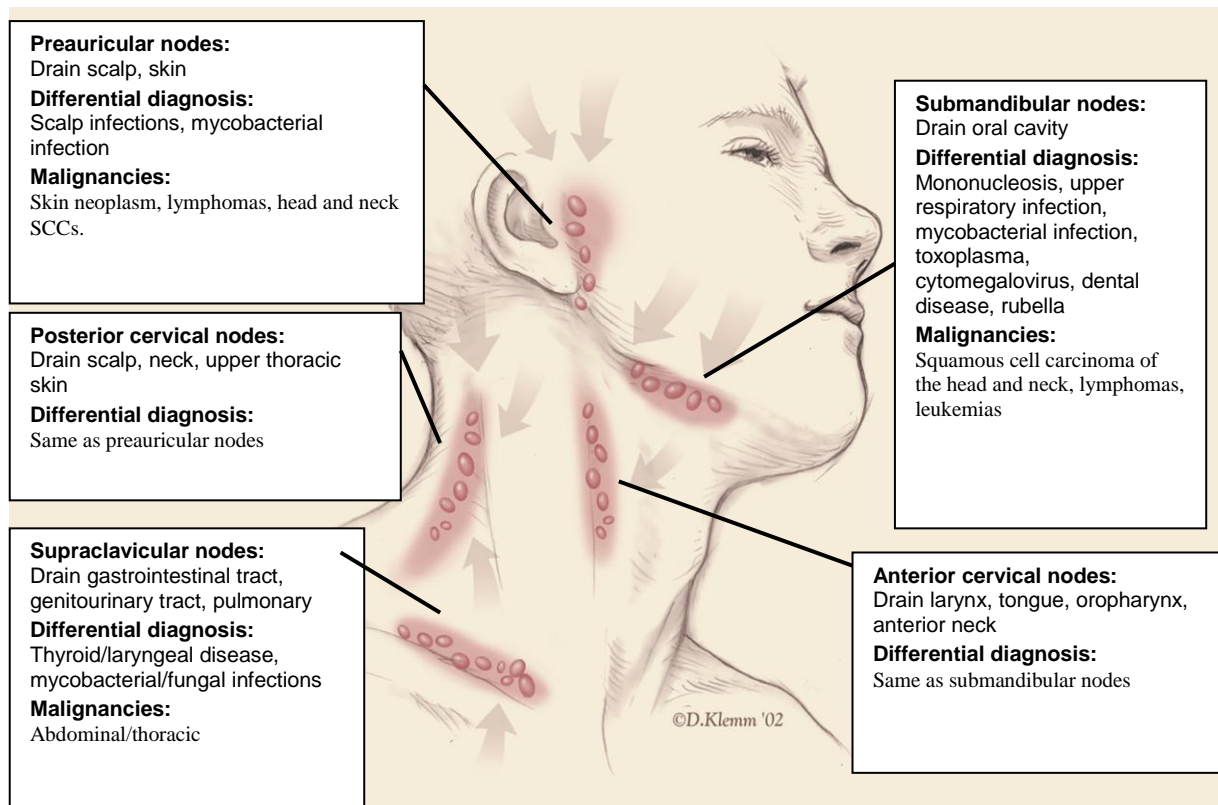
Medications causing Lymphadenopathy:-

Allopurinol	Phenytoin
Atenolol	Primidone
Captopril	Pyrimethamine
Carbamazepine	Quinidine
Gold	Trimethoprim/ Sulfamethoxazole
Hydralazine	Sulindac
Penicillins	

**CLASSIFICATION-**

**Localized Lymphadenopathy-**

**Head and Neck-** Infection is a common cause of head and cervical lymphadenopathy. In children, acute and self-limiting viral illnesses are the most common etiologies of lymphadenopathy. Supraclavicular adenopathy in adults and children is associated with high risk of intra-abdominal malignancy and must be evaluated promptly.



Infraclavicular lymphadenopathy	Highly suspicious of Non- Hodgkin Lymphoma.
Epitrochlear lymphadenopathy	>5 mm is pathologic Suggestive of lymphoma or melanoma; infections of upper extremity, sarcoidosis and secondary syphilis.
Axillary lymphadenopathy	Infectious or granulomatous; breast adenocarcinomas, skin neoplasms, lymphomas, leukemias, Kaposi's sarcoma.
Inguinal lymphadenopathy	Infections, sexually transmitted diseases, penile and vulvar SCCs, melanoma.

**Generalized Lymphadenopathy-** It is defined as the enlargement of more than two non-contiguous lymph node groups. It is more likely than localized lymphadenopathy to result from serious infections, autoimmune diseases, and disseminated malignancy. It usually merits specific testing to determine the diagnosis.<sup>4</sup>

Generalized LAP is rarely seen in malignancies; however, it is usually seen in non- Hodgkin's lymphoma, whereas Hodgkin's disease is distinguished by the localized involvement of the lymph nodes.

The Epstein-Barr virus typically involves the bilateral posterior cervical, axillary, and inguinal lymph nodes, distinguishing it from the other causes of pharyngitis. LAP appears in the first week of exposure and then gradually subsides over two to three weeks. Low-grade fever,

fatigue, and prolonged malaise are the other symptoms.

HIV infection is frequently associated with generalized LAP. It may also increase the risk of TB. The HIV initially involves the cervical, axillary, and occipital nodes and is not tender. In this situation, lymph nodes enlargement may last for more than 2-3 months. Drug reaction is characterized by fever, rash, arthralgia and generalized LAP.

Generalized lymph node enlargement is common and is usually a non-specific aspect of systemic lupus erythematosus. It is frequently detected in the cervical, axillary, and inguinal regions. Whereas lymph node necrosis is the characteristic histological finding, reactive follicular hyperplasia is the most frequent histopathologic finding in lymph node

lesions in systemic lupus erythematosus patients.

### DIFFERENTIAL DIAGNOSIS

Three models are available to categorize peripheral LAP.

1) Using the acronym "**CHICAGO**" helps to consider all causes.

C→ Cancers: *Hematologic malignancies*: Hodgkin's disease, Non Hodgkin's lymphoma, Leukemia

*Metastatic*: Breast tumor, Lung, Kidney, others

H→ Hypersensitivity syndromes: Serum sickness, Drugs

I→ Infections: Viral (EBV, CMV, HIV), Bacterial (TB,) Fungal, Protozoan, Rickettsial (Typhus), Helminths

C→ Connective Tissue disorders: SLE, RA, Dermatomyositis

A→ Atypical lymphoproliferative disorders: Castleman's Disease, Wegener's.

G→ Granulomatous: Histoplasmosis, Mycobacterial infections, Cryptococcus, Berylliosis, Cat scratch disease, Silicosis

O→ Others

2) Using the letters of alphabet, although it makes the categorization too long.

3) Using the region of lymph node enlargement and its localization provides useful information about causes.

### DIFFERENTIAL DIAGNOSIS ON BASIS OF PALPATION-

Cystic soft	Cold Abscess
Firm	Syphilis
Rubbery	Hodgkin's Lymphoma
Matted	Tuberculosis
Stony hard	Carcinoma

### HISTORICAL CLUES-

A clinician's diagnostic skills are strongly based on his/ her ability to elicit a complete history of present illness. Age, time of presentation, duration of symptoms, underlying diseases, and circumstances in which LAP was detected are of great value.

Environmental, travel-related, animal and insect exposure, tobacco and alcohol use as well as occupational history should be ascertained. Chronic medication use, infectious exposures, immunization status should also be reviewed. The family history may also be helpful in identifying the familial causes such as Li-Fraumeni Syndrome or lipid storage diseases.

The patient's past medical history should reveal the setting in which lymphadenopathy is present. A history of malignancy or infection could point to a recurrence.

A family history of malignant disorders may raise the physician's suspicion to distinct etiologies of LAP such as breast carcinomas, melanoma, and dysplastic nevus syndrome. Also, if LAP lasts less than two weeks or over one year without increasing in size, the probability of malignancy is quite low.

### ASSOCIATED SIGNS AND SYMPTOMS-

A thorough review of systems is important in the evaluation of peripheral lymphadenopathy. Constitutional symptoms such as fatigue, weight loss, malaise and fever, rapid enlargement or tenderness of the mass, or overlying erythema should be noted to find a possible etiology.<sup>8,9</sup>

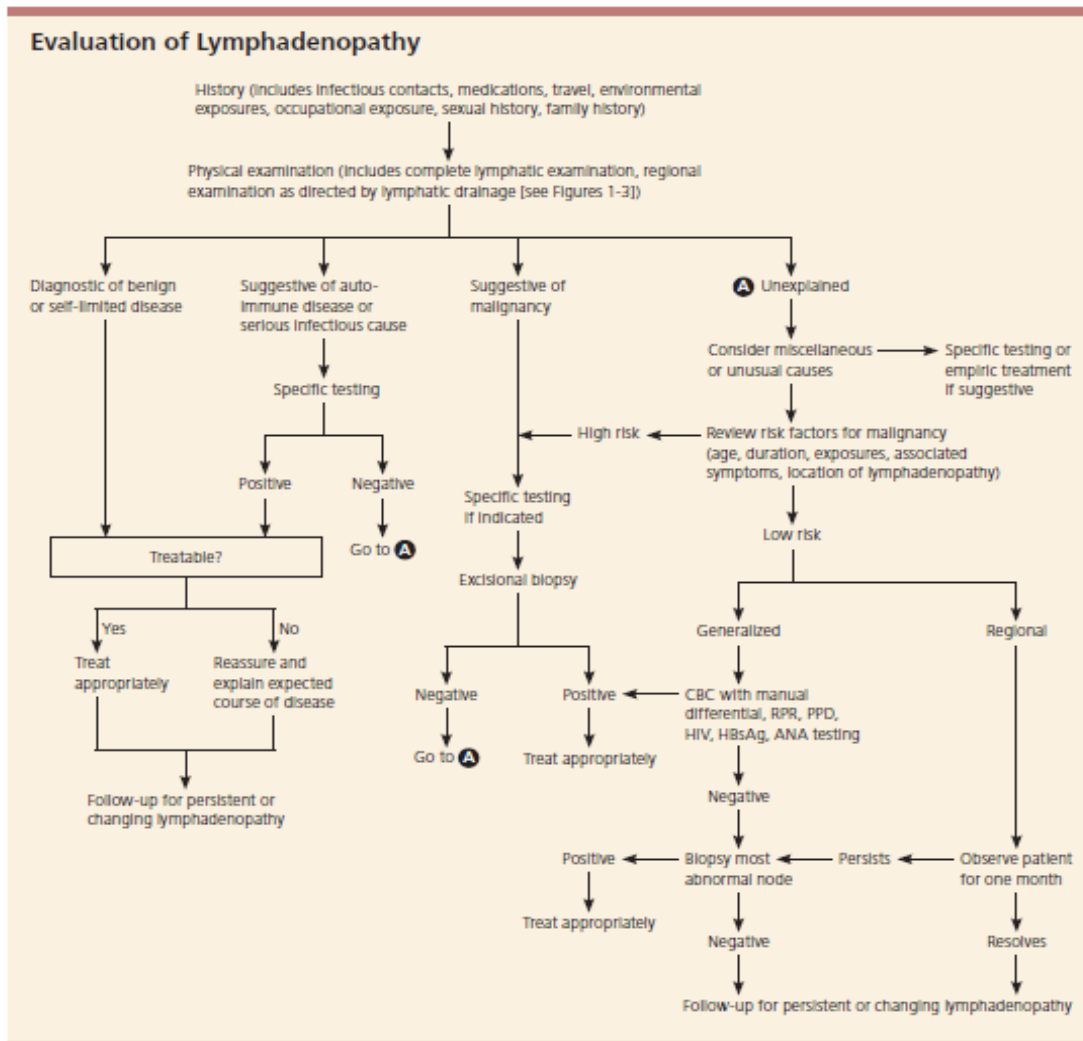
Most malignant neck masses in children are asymptomatic and are not painful. However, acute infection in a necrotic, malignant lymph node can also occur. An upper respiratory tract infection preceding the onset of the mass suggests possible reactive lymphadenopathy or a secondary infection of a congenital cyst. Constitutional type B symptoms such as fever, malaise, weight loss, and night sweats suggest a possible malignancy. Lymphadenopathy with high fever, bilateral conjunctivitis, and oral mucosal changes with a strawberry tongue likely represents Kawasaki disease.

**CLINICAL FEATURES-**

LOCATION	Identify the anatomical location (cervical, submandibular, submental, supraclavicular, occipital, preauricular, auricular, axial inguinal.)
	Single or multiple nodes
	Localized or disseminated nodes
	If palpable; unilateral or bilateral
CONSISTENCY	
	Firm
	Soft
	Rubbery
	Rock hard
	Movable
	Fixed
SIZE	
	<1 cm <sup>2</sup> , >1 cm <sup>2</sup>
	If bilateral; check for symmetry
SYMPTOMS	
	Asymptomatic
	Tender
	Associated with systemic symptoms

**DIAGNOSIS-**

Following comprehensive history taking and physical examination, the existing algorithm can guide the physicians for further evaluation of patients with peripheral LAP.



**1) LABORATORY INVESTIGATIONS-** If additional information is required, then CBC and specific markers may also be needed.

Evaluation of Suspected Causes of Lymphadenopathy		
DISORDER	ASSOCIATED FINDINGS	TEST
Mononucleosis-type syndromes	Fatigue, malaise, fever, atypical lymphocytosis	
Epstein-Barr virus*	Splenomegaly in 50% of patients	Monospot, IgM EA or VCA
Toxoplasmosis*	80 to 90% of patients are asymptomatic	IgM toxoplasma antibody
Cytomegalovirus*	Often mild symptoms; patients may have hepatitis	IgM CMV antibody, viral culture of urine or blood
Initial stages of HIV infection*	"Flu-like" illness, rash	HIV antibody
Cat-scratch disease	Fever in one third of patients; cervical or axillary nodes	Usually clinical criteria; biopsy if necessary
Pharyngitis due to group A streptococcus, gonococcus	Fever, pharyngeal exudates, cervical nodes	Throat culture on appropriate medium
Tuberculosis lymphadenitis*	Painless, matted cervical nodes	PPD, biopsy
Secondary syphilis*	Rash	RPR
Hepatitis B*	Fever, nausea, vomiting, icterus	Liver function tests, HBsAg
Lymphogranuloma venereum	Tender, matted inguinal nodes	Serology

**2) IMAGING-** Imaging can evaluate LAP more accurately than physical examination.

- Chest radiography.
- Ultrasonography is a useful imaging tool in the assessment of the number, size, site, shape, margins, and internal structure in patients with peripheral LAP.
- Color Doppler ultrasonography has been used in the assessment of lymph node enlargement since the beginning of the 1970s. It can evaluate the vascular pattern, displacement of vascularity, vascular resistance, and pulsatility index; which can help differentiate between old and new LAP.
- CT scan and magnetic resonance imaging (MRI) are more useful in the evaluation of the retropharyngeal, thoracic and abdominopelvic cavity or suspected malignancy and their accuracy mainly depends on the size of the lymph nodes.
- ECG/ECHO based on clinical findings if Kawasaki is suspected to rule out any complications.<sup>3,11.</sup>

The American College of Radiology recommends ultrasonography as the initial imaging choice for cervical lymphadenopathy in children up to 14 years of age and CT for persons older than 14 years.

**3) INVASIVE-**

Tissue diagnosis is the gold standard in the evaluation of LAP.<sup>11</sup>

Fine Needle Aspiration and Core Needle Biopsy can aid in the diagnostic evaluation of lymph nodes when etiology is unknown or enlarged lymph nodes have not responded to antibiotic and has been present for 2-6 weeks' duration.<sup>3,4.</sup>

Excisional Biopsy to be performed if the FNAC results are negative, however the clinical findings are strongly suggestive of malignancy.<sup>3</sup>

**RISK FACTORS FOR MALIGNANCY-**

these should be considered as guidelines for early referral for biopsy to rule out malignancy.

- Age older than 40 years.
- Duration of LAP greater than 4-6 weeks.

- Generalized LAP.
- Male sex.
- Supraclavicular location.
- Node not returned to baseline after 8-12 weeks.
- Lymph nodes are non-tender, firm or hard; >2 cm in size or are progressively enlarging.
- Axillary nodes are involved (in absence of local infection or dermatitis).
- Systemic signs- fever, night sweats, weight loss, hepatosplenomegaly.
- White race.<sup>4,3.</sup>

### CONCLUSION-

Lymphadenopathy is a common occurrence and should be duly noted and a systemic approach should be followed to diagnose the cause which further helps in determining a proper treatment course for the patient. Mostly, history and physical examination can reveal the etiology for the same and hence should be taken into consideration while examination. Diagnosis of less obvious causes can often be made after considering the patient's age, duration and all other risk factors, and whether constitutional signs are present. When the cause of lymphadenopathy remains unexplained, a three- to four- week observation period is appropriate when the clinical setting indicates a high probability of benign disease. Once biopsy has been chosen, ideally the largest, most suspicious, and most accessible node is selected, taking into account differing diagnostic yields by site. Although the advent of new techniques has increased the sensitivity and specificity of FNAC, excisional biopsy remains the diagnostic procedure of choice. Thus, a case with cervical lymphadenopathy has to be evaluated carefully to prevent any misdiagnosis.

### REFERENCES

1. Sachin Darne, Trusha Rajda. Cervical lymphadenopathy in children- a clinical approach. International Journal of

- Contemporary Medical Research 2016; 3(4):1207-1210.
2. Mohan Kumar Mili, Jyotirmoi Phookan. A clinico-pathological study of cervical lymphadenopathy. Int J Dent Med Res 2015; 1(5):24-27.
3. Shahrzad Mohseni, Abolfazl Shojaiefard, Zhamak Khorgami, Shahriar Alinejad, Ali Ghorbani, Ali Ghafouri. Peripheral Lymphadenopathy: Approach and Diagnostic Tools. Iran J Med Sci. 2014;39(2):158-170.
4. Heidi L. Gaddey, Angela M. Riegel. Unexplained Lymphadenopathy: Evaluation and Differential Diagnosis. Am Fam Physician. 2016; 94(11):896-903.
5. T. Sambandan, R. Christeffi Mabel. Cervical Lymphadenopathy- A Review. JIADS 2011; 2(1):31-33.
6. Prasadrao Dasari, Satyanarayanamurthy Varanasi, Surjkumar Pattnayak, Nagababu, Nandini. Cervical Lymphadenopathy: A Prospective Study in Rajiv Gandhi Institute of Medical Sciences, Srikakulam, Andhra Pradesh. International Journal of Scientific Study. 2016; 4(5):233-238.
7. Ernesta Parisi, Michael Glick. Cervical lymphadenopathy in the dental patient: A review of clinical approach. Quintessence Int 2005; 36: 423-436.
8. Jeremy D. Meier, Johannes F. Grimmer. Evaluation and Management of Neck Masses in Children. Am Fam Physician. 2014; 89(5):353-358.
9. Andrew W. Bazemore, Douglas R. Smucker. Lymphadenopathy and Malignancy. Am Fam Physician 2002;66:2103-10.
10. Dong Gyu Na, Hyo Keun Lim, Hong Sik Byun, Hong Dae Kim, Young Hyeh Ko, Jeong Hwan Baek. Differential Diagnosis of Cervical Lymphadenopathy: usefulness of Color Doppler Sonography. American Journal of Roentgenology 1997; 168:1311-1316.
11. Robert Ferrer. Lymphadenopathy: Differential Diagnosis and Evaluation. Am Fam Physician. 1998;58(6):1313-1320.
12. Athira Aruna Ramadas, Renju Jose, Beena Varma, Marina Lazar Chandy. Cervical Lymphadenopathy: Unwinding the hidden truth. Dent Res J (Isfahan).2017;14(1):73-78.

How to cite this article: Verma R, Khara S. Cervical lymphadenopathy: a review. Int J Health Sci Res. 2020; 10(10):292-298.

\*\*\*\*\*