

A STUDY ON THE INCIDENCE AND SIZE OF THE SUPRATROCHLEAR FORAMEN OF THE HUMERUS IN SOUTH INDIAN DRY ADULT HUMERI WITH ITS CLINICAL IMPORTANCE

Ephraim Vikram Rao K, *¹, Shiny Vinila B H ².

*¹ Associate professor, Department of Anatomy, Deccan College of Medical Sciences, Hyderabad, Telangana, India.

² Senior lecturer, Department of Anatomy, Panineeya Mahavidyalaya Institute of Dental Sciences and Research Centre, Hyderabad, Telangana, India.

ABSTRACT

Introduction: Supratrochlear foramen of the humerus is usually not mentioned in most of the anatomy and orthopaedics literature. Knowledge of supratrochlear foramen is important in the treatment of supracondylar fractures of the humerus, intramedullary humeral nailing, and preventing misinterpretation of X-Rays at the elbow joint, alteration of fracture patterns.

Materials and Methods: The present study was carried out on 132 dried human humeri of unknown sex and age. Incidence, shape, and size of the supratrochlear foramen was recorded. Vertical and transverse diameters were measured by using a double tipped compass and sliding calipers.

Results: Out of the 132 bones studied, 34 bones showed the presence of supratrochlear foramen. It was observed that the incidence was more on the left side than on the right. The most common shape observed was oval in 19.69%, round in 3.03%, bilobed in 1.51% and irregular in 1.51% of the specimens. Mean transverse diameter of the supratrochlear foramen on the left and right sides were 7.25mm and 8.1mm respectively. The mean vertical diameter of supra trochlear foramen on the left and right sides were 5.3mm and 5.4mm respectively.

Conclusion: Knowledge of supratrochlear foramen of the humerus helps clinicians in diagnosis and treatment strategies, while dealing with the elbow pathologies, fractures of the lower end of the humerus and supracondylar fractures of the humerus.

KEY WORDS: Humerus, Supratrochlear Foramen, Fracture, Septal aperture.

Address for Correspondence: Dr Ephraim Vikram Rao K, Associate Professor, Department of Anatomy, Deccan College of Medical Sciences, Santoshnagar, Hyderabad, Telangana, India.
Contact number: 9949353025 **E-Mail:** drvikram.anat@gmail.com

Access this Article online	Journal Information
Quick Response code  DOI: 10.16965/ijar.2018.301	International Journal of Anatomy and Research ICV for 2016 90.30 ISSN (E) 2321-4287 ISSN (P) 2321-8967 https://www.ijmhr.org/ijar.htm DOI-Prefix: https://dx.doi.org/10.16965/ijar 
	Article Information
	Received: 27 Jun 2018 Peer Review: 27 Jun 2018 Revised: None
	Accepted: 31 Jul 2018 Published (O): 05 Sep 2018 Published (P): 05 Sep 2018

INTRODUCTION

At the lower end of the humerus, a thin plate of compact bone lined by synovial membrane, known as supratrochlear septum [1-4], separates the olecranon fossa and coronoid fossa. Occasionally this septum may get perforated to form a foramen called supratrochlear foramen

or septal aperture [5-7]. The supratrochlear foramen (septal aperture) was first described by Meckel in 1825 [8]. Various shapes of supratrochlear foramen were observed by researchers in previous studies, the most common among those were oval, round, triangular, sieve-like, and irregular [2,9]. The incidence of

septal aperture or supratrochlear foramen varies from 6 to 60% in different ethnic groups [10]. Supratrochlear foramen is not present in embryonic period. According to Hirsh (1927) the thin plate of bone between the olecranon and coronoid fossa is always present until the age of seven years, after which the bony septum occasionally becomes absorbed to form the Supratrochlear foramen (STF) [11]. This perforation may be formed as a consequence of hyperflexion of the elbow joint which resorbs the humeral septum when the coronoid process of ulna makes contact with it [1].

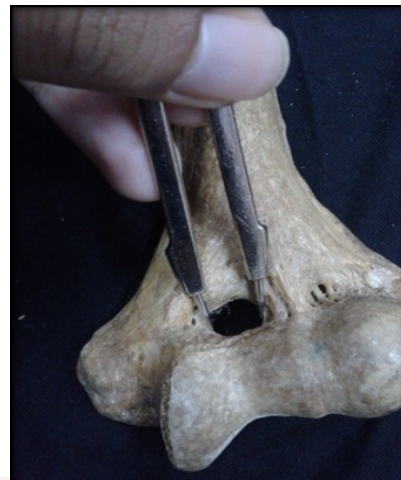Supratrochlear foramen plays important role in anthropology by establishing the similarity between humans and other primates and also has much clinical importance [12]. It may predispose to low impact fractures of the distal Humerus [13]. The presence of septal aperture leads to a narrow medullary humeral canal and extreme anterior angulation at the distal part of the humerus which causes difficulty at the entry point of a retrograde intramedullary nail fixation in the management of supracondylar fracture and fractures of the lower end of humeri, than in humeri without a septal aperture [14,15]. The Supratrochlear foramen appears radiolucent on X-ray which can be mistaken for and misinterpreted as an osteolytic or cystic lesion [16,17]. The present study was undertaken to describe the incidence of and different sizes and shapes of supratrochlear foramen in the humeri of South Indian population which will be of valuable information to anthropologists, radiologists and orthopaedic surgeons.

MATERIALS AND METHODS

The present study was conducted on 132 adult human humeri of unknown sex, collected from the department of Anatomy, Deccan College of Medical Sciences, Hyderabad, Out of which 72 were of the left side and 60 were of the right side. The incidence of the supratrochlear foramen was observed side wise and noted. The shape of the supratrochlear foramen was observed and classified into four types: Oval, round, bilobed and irregular. The incidence of the different shapes of the supratrochlear foramen were observed and noted. The transverse

and vertical diameters of the supratrochlear foramen were measured using double tipped compass and sliding calipers (Figure 1).

Fig. 1: Measurement of transverse diameter of STF with double tipped compass.



Out of the 132 bones studied, 34 (25.76%) bones showed the presence of supratrochlear foramen. The incidence was observed to be more on the left side than on the right side. Out of 72 left sided humeri, 21 (29.17 %) were bearing supra-trochlear foramen and out of 60 right sided humeri 13 (21.6%) were bearing supratrochlear foramen. The different shapes of supratrochlear foramen observed were Oval, round, bilobed and irregular (Figure 2, 3, 4 and 5). The most common shape observed was oval in 19.69%, round in 3.03%, bilobed shape in 1.51% and irregular in 1.51% of the specimens (Figure 6). The incidence of the shapes of supratrochlear foramen was tabulated in Table 1.

Table 1: Showing the incidence of supratrochlear foramen in relation to the shape.

Shape	Number of humeri (n=34)
Oval	26 (19.69)
Round	04 (3.03)
Bilobed	02 (1.51)
Irregular	02 (1.51)

Fig. 2: Showing the oval shaped supratrochlear foramen.

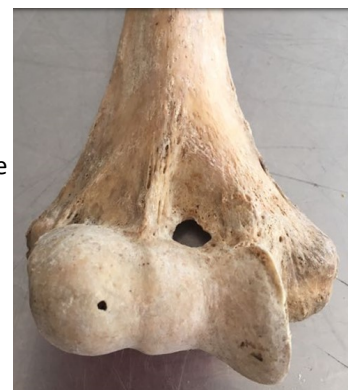

Fig. 3: Showing the round supratrochlear foramen.

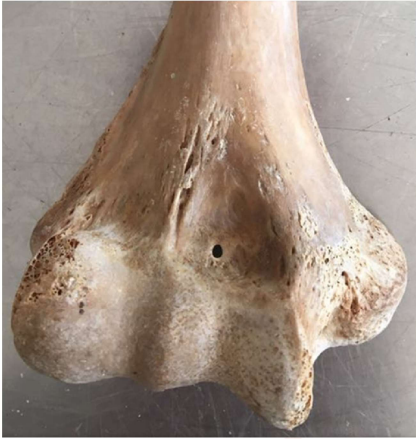

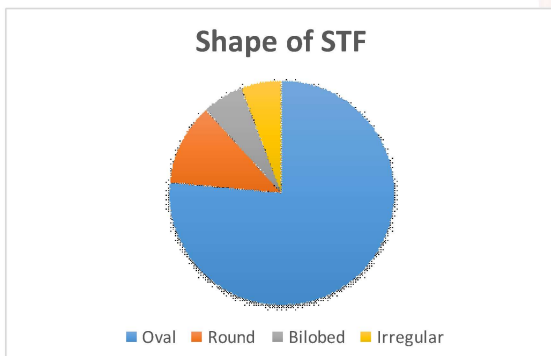
Fig. 4: Showing the irregular shaped supratrochlear foramen.

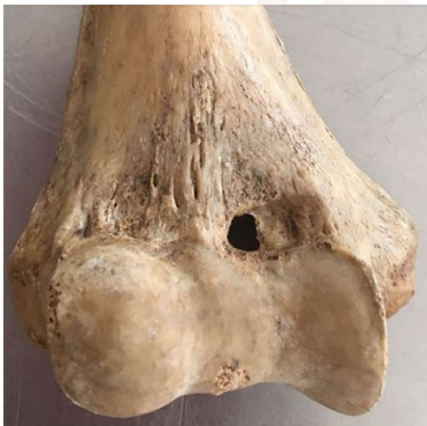

Fig. 5: Showing the bilobed supratrochlear foramen.

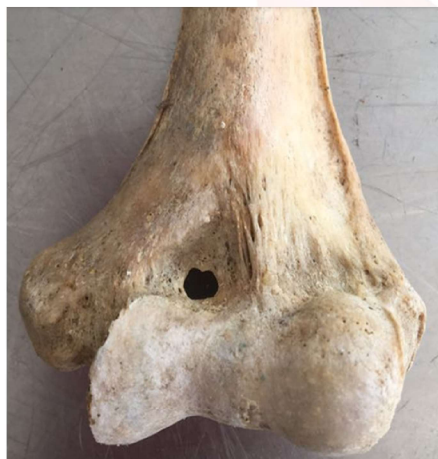

Fig. 6: Pie chart showing the incidence of various shapes of the supratrochlear foramen.

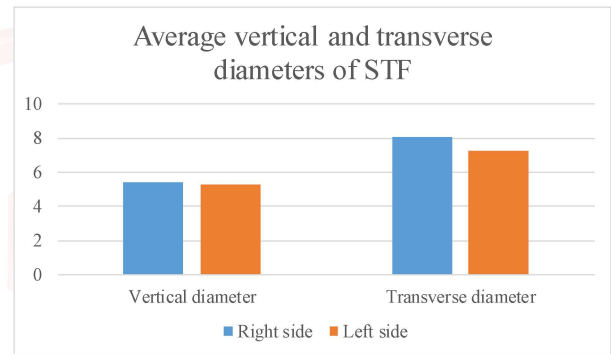


The average transverse diameter of supratrochlear foramen of humerus was 7.53 ± 2.48 mm and Vertical diameter was 5.33 ± 1.79 mm. The average transverse and vertical diameters on the right side were 8.1 ± 1.88 mm and 5.4 ± 1.52 mm respectively and on the left side were 7.25 ± 2.78 mm and 5.3 ± 2.00 mm respectively (Table 2 and Figure 7).

Table 2: Showing average vertical and transverse diameters of STF.

Diameters	Right	Left
Vertical	5.4 ± 1.52 mm	5.3 ± 2.00 mm
Transverse	8.1 ± 1.88 mm	7.25 ± 2.78 mm

Fig. 7: Bar diagram showing the average vertical and transverse diameters of STF on the right and the left sides.



The STF could be formed due to an epigenetic cause or a mechanical pressure during hyper extension, disturbance in calcium metabolism in adults and in child hood from excessive cancellous bone resorption and also due to impingement of coronoid and olecranon processes on the intercondylar septum [12]. According to Hirsh (1927) the thin plate of bone between the olecranon and coronoid fossa is always present until the age of seven years after which the bony septum, becomes absorbed occasionally to form the supratrochlear foramen which has much clinical and anthropological importance [11].

In the present study, it was found that out of 132 humeri of unknown sex and age, the incidence of supratrochlear foramen was found to be 25% of cases. The occurrence of the supratrochlear foramen in left sided humeri was 64 % whereas in right sided humeri it was 36 %, which shows that it occurs more on the left side as compared to the right, and corresponds to the findings of several recent studies [10,18]. This however is contrary to the finding of Nayak

et.al, who found higher incidence of supratrochlear foramen on the right than on the left side [15].

The supratrochlear foramen was observed to be oval in 18.93%, round in 3.03%, bilobed shape in 1.51% and irregular in 1.51% specimens which is similar to the study by Senem Erdogmus, where they had reported the incidence of oval, round, triangular, and sieve-like shapes in 13 (7.8%), 2 (1.2%), 2 (1.2%), and 1 (0.6%), respectively, the oval shape being the commonest. In the present study sieve like supratrochlear foramen was not observed and the bilobed shape was not reported by Senem Erdogmus [12]. Lamb observed that the formation of the supratrochlear foramen was more common in ancient people and occurred more frequently on the left side and in adolescents, as well as in mature individuals [20].

In the present study, the vertical diameter for supratrochlear foramen was 5.4 ± 1.52 mm and 5.3 ± 2.00 mm on the right and left sides respectively. The transverse diameter was 8.1 ± 1.88 mm and 7.25 ± 2.78 mm on the right and left sides respectively which is more than that found in the study by Senem Erdogmus where the vertical diameter was 4.12 ± 0.98 mm on the right side and 4.04 ± 0.9 mm on the left side and the transverse diameter was 5.63 ± 0.97 mm on the right side and 6.01 ± 1.86 mm on the left side [12].

Presence of supratrochlear foramen of the humerus is associated with a narrow intramedullary canal. This has a surgical importance in case of supracondylar fractures of humerus. Special attention may be required during intramedullary nailing procedures as the incidence of supratrochlear foramen in Indian population is high [21,22]. The supracondylar fracture of the distal humerus is the most common pediatric fracture in the elbow region which accounts for 75% of all injuries in children [23].

CONCLUSION

The results of the present study may be considered in anthropological evaluations and clinical or surgical procedures. A comprehensive knowledge of the occurrence, shapes, side predisposition of supratrochlear foramen may

help in the treatment of supracondylar fractures, Intramedullary humeral nailing and also in preventing misinterpretation of X-Rays at the elbow joint

Conflicts of Interests: None

REFERENCES

- [1]. Mays S: Septal aperture of the humerus in a mediaeval human skeletal population. *Am J Phys Anthropol*, 2008; 136: 432–40.
- [2]. Bhanu PS, Sankar KD: Anatomical note of supratrochlear foramen of humerus in south costal population of Andhra Pradesh. *Narayana Medical Journal*, 2012; 1(2): 28–34.
- [3]. Diwan RK, Rani A, Chopra J et al. Incidence of Supratrochlear foramen of Humerus in North Indian Population. *Biomedical Research*, 2013; 24(1): 142–45.
- [4]. Singh S, Singh SP: A study of the supratrochlear foramen in the humerus of North Indians. *J Anat Soc India*, 1972; 21: 52–56.
- [5]. Benfer RA, McKern TW: The correlation of bone robusticity with the perforation of the coronoid-olecranon septum in the humerus of man. *Am J Phys Anthropol*, 1966; 24(2): 247–52.
- [6]. Das S: Supratrochlear foramen of the humerus. *Anat Sci Int*, 2008; 83(2): 120.
- [7]. Ndou R, Smith P, Gemell R et al: The supratrochlear foramen of the humerus in a South African dry bone sample. *Clin Anat*, 2013; 26(7): 870–74.
- [8]. Singhal S, Rao V: Supratrochlear foramen of the humerus. *Anat Sci Int*, 2007; 82: 105.
- [9]. Mahajan A: Supratrochlear Foramen; Study of humerus in North Indians. *Professional Medical Journal*, 2011; 18(1): 128–3.
- [10]. Jadhav Mayuri, Tawte Apama, Pawar Pradeep, Mane Smitha. Anatomical study of supratrochlear foramen of humerus. *Journal of Research in Medical and Dental Sciences*. 2013; 1(2): 33-35.
- [11]. Hirsh SI. Cited in Morton SH, Crysler WE. Osteochondritis dissecans of the supratrochlear septum. *Journal of Bone Joint Surgery*. 1945; 27: 12–24.
- [12]. Senem Erdogmus, Munevver Guler, Serpil Eroglu, Aizami Duran. The Importance of the Supratrochlear Foramen of the Humerus in Humans: An Anatomical Study. *Medical science monitor*. 2014; 20: 2643-2650.
- [13]. Sahajpal DT, Pichora D: Septal aperture: an anatomic variant predisposing to bilateral low-energy fractures of the distal humerus. *Can J Surg*, 2006; 49(5): 363–64.
- [14]. Hima BA, Narasinga RB: Supratrochlear foramen-a phylogenetic remnant. *International Journal of Basic and Applied Medical Sciences*, 2013; 3(2): 130–32 14.
- [15]. Nayak SR, Das S, Krishnamurthy A et al: Supratrochlear foramen of the humerus: An anatomico-radiological study with clinical implications. *Ups J Med Sci*, 2009; 114(2): 90–94.

- [16]. De Wilde V, De Maeseneer M, Lenchik L et al: Normal osseous variants presenting as cystic or lucent areas on radiography and CT imaging: a pictorial overview. *Eur J Radiol*, 2004; 51(1): 77–84.
- [17]. Papaloucas C, Papaloucas M, Stergioulas A: Rare Cases of Humerus Septal Apertures in Greeks. *Trends in Medical Research* 2011; 6(3): 178–83.
- [18]. Rakesh KD, Archana R, Anitha R, Jyothi C, Srivastava AK, Sharma PK, Incidence of Supratrochlear foramen of Humerus in North Indian Population. *Bio-medical Research*. 2013; 24 (1): 142-145.
- [19]. Soubhagya R N. Supratrochlear foramen of the Humerus - An anatomico radiological study with clinical implications. *Upsala Journal of medical sciences*. 2009; 114: 90-94.
- [20]. Lamb DS: The olecranon perforation. *Am Anthropol*, 1890; 3: 159–74.
- [21]. Brauer CA, Lee BM, Bae DS et al: A systematic review of medial and lateral entry pinning versus lateral entry pinning for supracondylar fractures of the humerus. *J Pediatr Orthop*, 2007; 27: 181–86.
- [22]. Ananthi S, Manickam S, Vaithianathan G et al: Study of Intercondyloid foramen of humerus. *Intercondyloid Foramen. Rev Arg de Anat Clin*, 2011; 3(1): 32–3.
- [23]. Venkatesh Gobi V, Suba Ananthi, Narayanan GK, Prabhu S and Karthikeyan. Anatomical and Radiological Study of Supratrochlear Foramen of Humerus. *World Journal of Pharmacy and Pharmaceutical sciences*. 2013; 2: 313-20.

How to cite this article:

Ephraim Vikram Rao K, Shiny Vinila B H. A STUDY ON THE INCIDENCE AND SIZE OF THE SUPRATROCHLEAR FORAMEN OF THE HUMERUS IN SOUTH INDIAN DRY ADULT HUMERI WITH ITS CLINICAL IMPORTANCE. *Int J Anat Res* 2018;6(3.3):5647-5651. **DOI:** 10.16965/ijar.2018.301