

Hepatoprotective Effect of *Anisotes trisulcus* on Thioacetamide-induced Hepatic Cirrhosis in Male Albino Mice

Daklallah Ahmed Almalki

Department of Biology, Faculty of Science and Arts (Qelwah), Albaha University-Saudi Arabia

Abstract: Histologically, thioacetamide (TAA) is a well-known toxic compound that induces liver cirrhosis and other metabolic disorders which may lead to serious complications. The potential of *Anisotes trisulcus* as a hepatoprotective herb was evaluated in experimentally-induced, TAA-mediated liver cirrhosis in mice model. Healthy male mice were employed in the current study and randomly assigned into four groups. The first group was the normal control, while the second groups were exposed to TAA by intraperitoneal injection. Mice of the third group orally received *A. trisulcus* leaves extract alongside the TAA intraperitoneal injection. The fourth group was only supplemented with *A. trisulcus* leaves extract. After three months of experimental treatments, histopathological examination of liver tissue sections from TAA-treated mice with revealed shown increase in the deposition of extracellular collagen and fibrosis. Alterations of tissue architecture and large fibrous septae were observed as a result of collagen condensation around the lobules. Obtained result of the current study showed that the leave extract of *A. trisulcus* possess hepatoprotective effect against TAA-induced liver cirrhosis by preventing the histopathological alterations. Supplementation of *A. trisulcus* aqueous extract may confer antioxidant effect and could be an excellent supportive component in the treatment of liver cirrhosis.

Keywords: Intraperitoneal, Saudi Arabia, Liver injury, Histopathological examination

1. Introduction

Liver is the largest complex gland in body that play pivotal functions in metabolism of vital biomolecules such as carbohydrates, proteins and lipids. It is also a critical site for blood detoxification, metabolism of many chemicals and drugs leading to their elimination along with the normal waste metabolites. In developing countries, the main causative factors of liver diseases are viral or parasitic infections, environmental toxins, and hepatotoxic drugs (Williams, 2006). Indeed, chronic liver injury results in a response characterized by continuous and gradual wound healing that culminates in liver fibrosis recognized by great alteration of hepatic extracellular matrix, ECM (Lang et al., 2011). Moreover, liver injury induces hepatic stellate cells to trans-differentiated into extracellular matrix myofibroblasts (Friedman, 2008). Consequently, liver is one of the most commonly body damaged organs (Sivaraj et al., 2011). In spite of increases in the burden of liver cirrhosis, successful treatment options remain very limited.

Traditionally, numerous plants have been used to treat hepatic diseases in various countries (Qadrie et al., 2015). According to WHO definition which includes herbal remedy, traditional medicine is any therapeutic practice that have been existed hundred years ago before the advancement of current medicine and still in use nowadays (Kashaw et al., 2011). Certain plants are rich sources of biologically-active phytochemicals most of which confer a desirable health benefits such as prevention of diseases (Yogalakshmi et al., 2010). Herbal preparations have been shown to possess protective effects in liver cirrhosis and other hepatic injuries (Al-Attar and Shawush, 2015).

Thioacetamide (TAA) is a potent hepatotoxic compound. *In vivo*, activation of TAA occurs by mixed-function oxidases

to its S-dioxide state that is highly reactive when interact with proteins and lipids (Hajovsky et al., 2012).

Anisotes genus harbors 23 shrub or climber species (El-Shanawany et al., 2011). *Anisotes trisulcus* is a shrub herb within the family Acanthaceae known traditionally in Saudi Arabia as Modaid, Modh, and Moze. Its aerial parts are used in traditional medicine in the Arabian Peninsula for treatment of several hepatic conditions (Collenette, 1999). The herb is also used to treat diabetes, asthma, hypertension, and also as a local anesthetic (El-Shanawany et al., 2014). Crude extracts of *A. trisulcus* have been found to possess antibacterial, anti-inflammatory, and antioxidant activities (Ali et al., 2001; Shanawany et al., 2014). Phytochemically, *A. trisulcus* is rich in alkaloids and steroids (Shanawany et al., 2011; Shanawany et al., 2014). The plant is also known to have antibacterial, cytotoxic, bronchodilator, hypotensive, antidiabetic, and hepatoprotective activities (Al-Rehaily et al., 2011). This study aimed at evaluation of the hepatoprotective effect of *A. trisulcus* against thioacetamide-induced hepatotoxicity in albino mice.

2. Materials and Methods

Animals

A total of forty (40) males albino mice of the SWR strain, ranging in weight from 15.0 to 25.0 g were employed in the present study. The mice were obtained from King Fahd Medical Research Center at the Experimental Animal Unit at King Abdulaziz University, Jeddah, Saudi Arabia. Ten days have been allocated to mice to be acclimatized to laboratory conditions before initiating the experimental processes. In the laboratory, the animal model was kept and maintained in trivial plastic cages under controlled settings of humidity (65%), temperature ($20 \pm 1^\circ\text{C}$) and 12:12 h light: dark cycle. Free access to water and diet *ad libitum* was guaranteed during the experiments period. All experimental treatments

were strictly adhered to the ethical guidelines of the Animal Care and Use Committee of King Abdulaziz University.

***Anisotes trisulcus* leaf extraction**

The *A. trisulcus* aerial parts were collected from the suburbs of Albaha region of Saudi Arabia- Qelwah province. The plant was identified in Biology department, Albaha University. Only the leaves were thoroughly cleansed with water and dried at ambient temperature. The methods of extract preparation were done according to Sakr and Lamfon (2012) with some modifications. Briefly; dried *A. trisulcus* leaves (50 g) were grinded and mixed with 2 liters of hot water. Six hours later, the mixture was gradually boiled for additional 1 h. Thereafter, at room temperature the mixture was allowed to cooled and gently shaken in an electrical blender for 10 minutes. Finally, the mixture was filtered and evaporated in an oven at 40°C. The average yield of the *A. trisulcus* extract was 19.65%. The extract was prepared twice monthly and kept in 4°C for subsequent experiments.

Experimental design

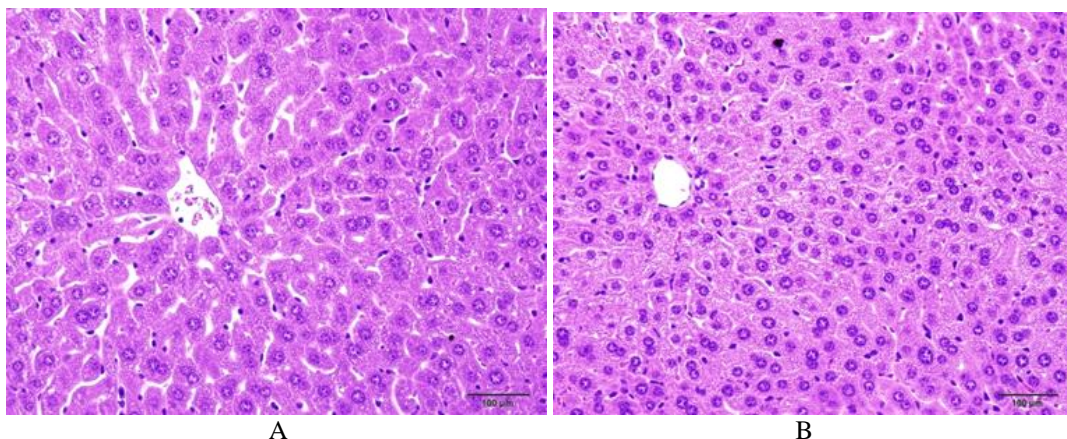
Randomly, the mice were allocated into four groups of ten mice per each. Mice of the first group served as controls and injected with physiological saline solution (0.9% NaCl) into the peritoneum twice weekly for twelve weeks. Mice of the second group received 150 mg/kg body weight of TAA (Sigma–Aldrich, USA) by intraperitoneal injection twice weekly for the same period. Mice of the third group were intraperitoneally injected with TAA at the same dose given to group 2 and orally supplemented with *A. trisulcus* leaves extract at a dose of 200 mg/kg body for twelve weeks. Finally, mice of the fourth group received intraperitoneal saline injections at the same dose given to the first group in addition to oral supplementation of *A. trisulcus* leaves extract at the same dose given to the third group for the same period.

Histopathological examinations

Mice were dissected and the liver tissues were preserved in 10% buffered formalin immediately after removal from the animals followed by embedding with paraffin. Livers of dissected mice were sliced and fixed in 10% buffered formalin immediately after removal from the body. Tissues were embedded in paraffin wax and processed by conventional methods. Paraffin sections of livers were cut into thin sections (4 µm in thickness) and stained with hematoxylin-eosin. Additionally, tissue sections were stained by Masson's trichrome stain. All tissues were examined microscopically by conventional light microscope. Photographs of the best sections were taken.

3. Results

Histopathological examination revealed a normal hepatocellular morphology in tissues of the control mice (Fig.1 A-B). Administration of TAA for twelve weeks resulted in a uniform nodularity of the surface of the mice livers in the second group. On the other hand, TAA administration resulted in nodular changes in liver parenchyma resembling the nodules found in human liver cirrhosis (Fig.1 C-D). Furthermore, hepatic pseudolobules were observed due to the formation of fibrous septae around the parenchymal nodules. Additionally, features of centrilobular degeneration processes (swelling, hydropic degeneration, and necrosis) were detected around the central vein. On the other hand, livers sections of mice treated with TAA plus *A. trisulcus* (3rd group) revealed a noticeable histological regeneration (Fig.1 E-F) compared to those of TTA treated mice (2nd group). This group showed a lower degree of fibrosis and extension of normal hepatic parenchyma, and in no case led to the transformation of nodular parenchyma in response to the cirrhotic process. Lastly, mice treated only with the extract of *A. trisulcus* retained normal hepatic lobular structures with central veins and the surrounding hepatocytes (Fig.1 G-H).



A

B

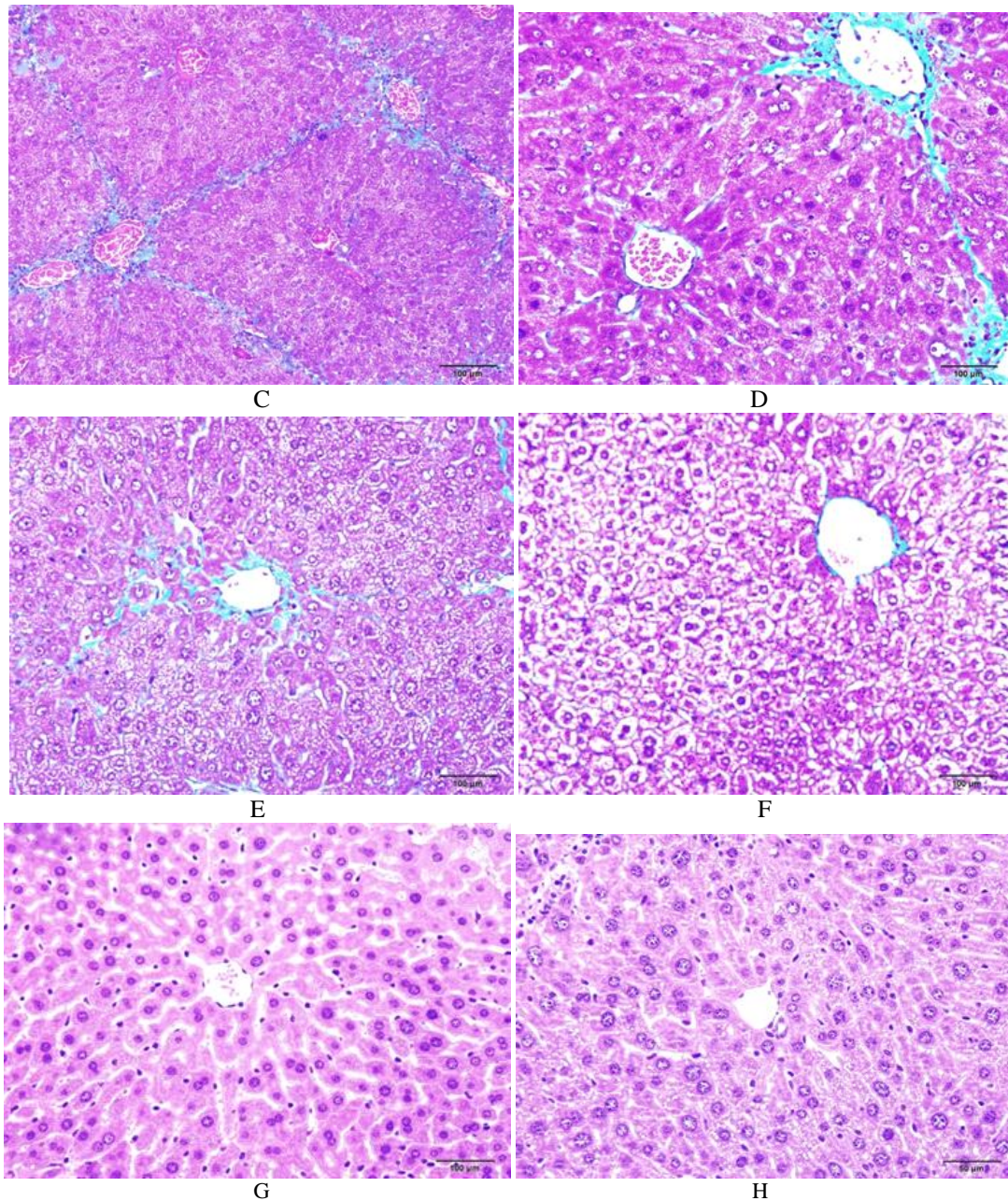


Figure 1: Micrographs of liver sections. Sections from normal control mice reveal a normal histology (A, X400 and B, X400). While sections from TAA treated mice (C, X200 and D, X400) show a severe liver damage marked by pseudolobules formation with fibrotic septae (arrows) and necrotic areas (head arrows). However, liver sections from mice treated with TAA plus *A. trisulcus* (E, X400 and F, X400) show disturbance of hepatic strands and an absence of fibrotic septae. In contrast, liver sections from *A. trisulcus* treated mice (G, X400 and H, X400) sustained a normal hepatic structure.

4. Discussion

The liver is a delicate organ at potential risk of chemical assault due to its central role in metabolism of various chemicals and drugs (Ghosh et al., 2011). Several phytochemicals showed hepatoprotective effects in experimentally induced liver injury in animal models (Adewusi & Afolayan, 2010; Ghosh et al., 2011). In the current study, TAA was employed to produce liver injury in mice model. Histopathological profile of TAA-treated liver samples showed nodular transformation in the parenchyma surrounded by fibrous septae. The protective effect of *A. trisulcus* was confirmed by histological evaluation. Oral administration of extract to the experimental animal (200

mg/kg for twelve weeks) showed significant improvement of the hepatic architecture over the TAA-treated control group.

A literature search retrieved only a single study (Fleurentin et al., 1986) that investigated and confirmed the hepatoprotective effect of *A. trisulcus* extract against Carbon tetrachloride-induced hepatic injury in mice model. Such observation is in good agreement with the finding of the present study. Indeed, co-administration of TAA with aqueous extract of *A. trisulcus* reduces the damage of hepatic architectures and normal physiology of liver as inferred by histological evaluation. However, the major chemical(s) in *A. trisulcus* responsible for the hepatoprotective effect is still unknown. This hepatoprotective activity is mostly owing to bioactive

compounds that *A. trisulcus* shares with other Acanthaceae members.

The family Acanthaceae harbors a number of herbs (*Andrographis* spp., *Asteracantha longifolia*, *Hygrophila auriculata*, *Hypoestes triflora*) that have shown hepatoprotective activities (Adewusi & Afolayan, 2010; Kumar et al., 2011). Aqueous and alcohol extracts of aerial and whole plant have revealed, in many cases, a dose-dependent hepatoprotective effects in different animal models intoxicated by different hepatotoxic chemicals. The hepatoprotective effects of such species are inferred by decrease in levels of serum enzymes, mostly, aspartate transaminase (AST), Alanine transaminase, alkaline phosphatase (ALP), accompanied by histological evaluation (Kumar et al., 2011).

The chemical nature of the hepatoprotective compounds isolated from Acanthaceae family are diterpenes and quiazoline alkaloids (Adewusi & Afolayan, 2010; Ghosh et al., 2011). Of note, Andrographolide and Neoandrographolide are the best characterized diterpene hepatoprotectants from Acanthaceae herbs. The underlying mechanism of such effects could be due to their antioxidant and free radical scavenging activities by donating the allylic hydrogen of the unsaturated lactone ring (Kamdem et al., 2002). Additionally, alkaloids, flavonoids and phenolic acids from *A. trisulcus* have been characterized chemically and found to have potent antioxidant activities (Al-Rehaily et al., 2002; El-Shanawany et al., 2011; El-Shanawany et al., 2014). Moreover, other chemicals from different groups may be effective in hepatic protection. For example, a polysaccharide molecule isolated from *Tarphochlamys affinis* showed a dose-dependent hepatoprotective effect against CCl₄-induced liver injury in rats (Lin et al., 2012). Strikingly, this polysaccharide reduced the oxidative stress and inhibited pre-inflammatory mediators at molecular and genetic levels.

5. Conclusion

In conclusion, the results demonstrated, for the first time, that aqueous extract of *A. trisulcus* provided a hepatoprotective effect in mice model intoxicated by thioacetamide experimentally. *A. trisulcus* worth a further study to explore the pharmacological potential in treating liver injury.

References

- Adewusi, E.A., & A.J. Afolayan (2010). A review of natural products with hepatoprotective activity. *J. Med. Plants Res.* 4(13): 1318-34.
- Al-Attar, A.M., & N.A. Shawush (2015). Influence of olive and rosemary leaves extracts on chemically induced liver cirrhosis in male rats. *Saudi J. Biol. Sci.* 22(2): 157-63.
- Ali, N.A.A., W.D. Julich, C. Kusnick, U. Lindequist, (2001). Screening of Yemeni medicinal plants for antibacterial and cytotoxic activities. *J. Ethnopharmacol.* 74: 173-9.
- Al-Rehaily, A.J., K.A. EL-Sayed, M.S. Al-Said, & B. Ahmed (2002). Trisulcusine: A novel spiro quinazoline alkaloid from *Anisotes trisulcus*. *Indian J. Chem.* 41B: 2385-9.
- Al-Rehaily, A.J., M.S. Al-Said, & K.E.H. ELTahir (2011). Peganine isolated from *Anisotes trisulcus* as a smoking deterrent and anorexigenic agent. *African J. Pharm. Pharmacol.* 5(11): 1342-8.
- Collenette S. (1999). Wild flowers of Saudi Arabia, National Commission for Wild life Conservation and Development (NCWCD), Kingdom of Saudi Arabia. King Fahd National Library; Riyadh. 2 p.
- El-Shanawany, M.A., H. M. Sayed, S.R. Ibrahim, & M.A. Fayed (2011). 5-hydroxy vasantine, a new pyrroloquinazoline alkaloids from *Anisotes trisulcus* (Forssk.) Nees. *J. Nat. Prod. Plant. Resour.* 1: 80-5.
- El-Shanawany, M.A., H.M. Sayed, S.R. Ibrahim, & M.A. Fayed (2014). Chemical constituents, anti-inflammatory, and antioxidant activities of *Anisotes trisulcus*. *Bull. Fac. Pharm. Cairo Univ.* 52(1): 9-14.
- Fleurentin, J., C. Hoefler, A. Lexa, F. Mortier, & J.M. Pelt (1986). Hepatoprotective properties of *Crepis rueppellii* and *Anisotes trisulcus*: two traditional medicinal plants of Yemen. *J. Ethnopharmacol.* 16(1): 105-11.
- Friedman, S.L (2008). Hepatic stellate cells: protean, multifunctional, and enigmatic cells of the liver. *Physiol. Rev.* 88(1): 125-72.
- Ghosh, N., R. Ghosh, V. Mandal, & S.C. Mandal (2011). Recent advances in herbal medicine for treatment of liver diseases. *Pharm. Biol.* 49(9): 970-88.
- Hajovsky, H., G. Hu, Y. Koen, D. Sarma, W. Cui, D.S. Moore, J.L. Staudinger, and R.P. Hanzlik (2012). Metabolism and toxicity of thioacetamide and thioacetamide S-oxide in rat hepatocytes. *Chem. Res. Toxicol.* 25(9): 1955-63.
- Kamdem, R.E., S. Sang, & C.T. Ho (2002). Mechanism of the superoxide scavenging activity of neoandrographolide—a natural product from *Andrographis paniculata* Nees. *J. Agr. Food Chem.* 50(16): 4662-5.
- Kashaw, V., A.K. Nema, & A. Agarwal (2011). Hepatoprotective prospective of herbal drugs and their vesicular carriers—a review. *Int. J. Res. Pharma. Biomed. Sci.* 2(2): 360-74.
- Kumar, C.H., A. Ramesh, Kumar, J.S. Kumar, & B.M. Ishaq (2011). A review on hepatoprotective activity of medicinal plants. *Int. J. Pharm. Sci. Res.* 2(3): 501-15.
- Lang, Q., Q. Liu, N. Xu, K.L. Qian, J.H. Qi, Y.C. Sun, L. Xiao, & X.F. Shi (2011). The antifibrotic effects of TGF-β1 siRNA on hepatic fibrosis in rats. *Biochem Biophys Res Commun.* 409(3): 448-453.
- Lin, X., X. Liu, Q. Huang, S. Zhang, L. Zheng, L. Wei, M. He, Y. Jiao, J. Huang, S. Fu, Z. Chen, Y. Li, L. Zhuo, R. Huang (2012). Hepatoprotective effects of the polysaccharide isolated from *Tarphochlamys affinis* (Acanthaceae) against CCl₄-induced hepatic injury. *Biol. Pharm. Bull.* 35(9): 1574-80.
- Qadrie, Z.L., B. Raj Kapoor, & S. Kavimani (2015). Hepatoprotective medicinal herbs and animal models for their screening—a review. *Int. J. Pharm. Sci. Res.* 6(12): 5006-28.
- Sakr, S.A., & H.A. Lamfon (2012). Protective effect of rosemary (*Rosmarinus officinalis*) leaves extract on carbon tetrachloride-induced nephrotoxicity in albino rats. *Life Sci. J.* 9(1): 779-85.
- Sivaraj, A., P. Vinothkumar, K. Sathiyaraj, S. Sundaresan, K. Devi, & B. Senthilkumar (2011). Hepatoprotective potential of *Andrographis paniculata* aqueous leaf extract on ethanol induced liver toxicity in albino rats. *J. Appl. Pharma. Sci.* 1(6): 204-8.
- Williams, R. (2006). Global challenges in liver disease. *Hepatology.* 44(3): 521-6.
- Yogalakshmi, B., P. Viswanathan, & C.V. Anuradha (2010). Investigation of antioxidant, anti-inflammatory and DNA-protective properties of eugenol in thioacetamide-induced liver injury in rats. *Toxicol.* 268(3): 204-12