

# Computed Tomography Assessment of the Olfactory Fossa Depth in the Patients Presenting in Indira Gandhi Institute of Medical Sciences, Patna

Amit Kumar<sup>1</sup>, Samiullah Hasan<sup>2</sup>, Deepak Kumar<sup>1</sup>, Chandra Bhushan<sup>2</sup>, Umakant Prasad<sup>1</sup>, S K Suman<sup>3</sup>

<sup>1</sup>Associate Professor, Department of Radiodiagnosis, Indira Gandhi Institute of Medical Sciences, Patna, Bihar, India, <sup>2</sup>Senior Resident, Department of Radiodiagnosis, Indira Gandhi Institute of Medical Sciences, Patna, Bihar, India, <sup>3</sup>Professor and HOD, Department of Radiodiagnosis, Indira Gandhi Institute of Medical Sciences, Patna, Bihar, India

## Abstract

**Background:** Olfactory fossa (OF) is the most inferomedial portion of the anterior cranial cavity harboring the precious olfactory nerve and bulb. Its floor is formed by cribriform plate of ethmoid and bounded laterally by the lateral lamella, which is a thin plate of bone and is at risk of iatrogenic injury during functional endoscopic sinus surgery, especially when fossa is deep or asymmetric.

**Aims and Objectives:** The objectives of the study were to evaluate the variations in the depth of OF as per the Keros classification using computed tomography (CT) and determine the incidence and degree of asymmetry in the height of the ethmoid roof in the population of Bihar.

**Materials and Methods:** This was a retrospective cross-sectional observational study conducted on 200 patients referred to IGIMS, Patna, for CT evaluation of paranasal sinuses (PNS) during the period of 1 year between December 2019 and November 2020. Patients with the age group of 16 and above 16 years of age undergoing CT scan of PNS were included and all patients with any pathology involving the OF were excluded from the study. The depth of OF was measured from vertical height of lateral lamella.

**Results:** The mean age of our patients was  $38 \pm 12$  years. The right lateral lamella height ranges from 1.5 mm to 10 mm while the left lateral lamella height ranges from 0.80 mm to 9.0 mm. Keros Type 1 was seen in 25.5%, Type II in 70%, and Type III in 4.5%. Asymmetry in the ethmoid roof height was found in 12% of cases.

**Conclusion:** The majority of patient showed Keros Type II (74.5%) OF followed by Type I and Type III. There was no significant gender predilection as far as type and asymmetry were considered.

**Key words:** Computed tomography, Ethmoid roof, Keros, Lateral lamella, Olfactory fossa

## INTRODUCTION

Computed tomography (CT) is routinely performed for the evaluation of the paranasal sinuses (PNS) before functional endoscopic surgery. High-resolution CT scan of PNS provides excellent bony anatomic details and soft-tissue mapping for surgical planning.<sup>[1]</sup> Various anatomical variants detected on pre-functional endoscopic sinus

surgery (FESS) CT scan help to decide the optimal surgical approach and to minimize intraoperative complications. Most of major complications are related to surgical manipulation of the ethmoidal and frontal sinuses.<sup>[2,3]</sup>

In this article, we evaluate the depth of olfactory fossa (OF) in the population of Bihar, as no such study has been undertaken so far in this region. This is important as several reports have shown diverse configurations of the ethmoid roof in various ethnic populations.<sup>[4-6]</sup>

## MATERIALS AND METHODS

Our study was a retrospective cross-sectional observational study performed on 200 patients (males: 116, females: 84)

Access this article online



www.ijss-sn.com

Month of Submission : 06-2021  
Month of Peer Review : 07-2021  
Month of Acceptance : 07-2021  
Month of Publishing : 08-2021

**Corresponding Author:** Dr. Umakant Prasad, Department of Radiodiagnosis, Indira Gandhi Institute of Medical Sciences, Patna, Bihar, India.

done at our hospital between December 2019 and November 2020. All patients above the age of 10 years who underwent CT scan for PNS were included in this study as sinuses are well pneumatized and skull bones are well mineralized. All patients with a previous history of nasal or paranasal trauma, surgeries, congenital anomalies of face, sinonasal polyposis, tumors, or conditions involving bone destruction were excluded as these pathologies disturbed the visualization of the skull base.

CT scans were performed on Toshiba Aquilion CXL 128 slice CT scanner. Technique used was as follows: Tube voltage: kVp 120; 120–150 mA; field of view: 150 mm; high resolution: 1.0 mm contiguous axial slices. For each CT scan images set, a multiplanar view created by the software was used to determine the best coronal cut showing clearly the cribriform plate and the lateral lamellae. The following were the established anatomical points which were identified and used for measurements.

1. Fovea ethmoidalis
2. Cribriform plate
3. Lateral lamella.

The heights of both the right and left lateral lamella were recorded separately. The height of the lateral lamella corresponds to the depth of OF. Horizontal lines were drawn along the cribriform plate and at the medial ethmoid roof point. The vertical height of lateral lamella was measured between these two horizontal lines using the distance measuring tool [Figure 1]. The OF depth was then grouped according to Keros' classification. OF depth of 1–3.9 mm was categorized as Keros type I, 4–7.9 mm as type II, and  $\geq 8$  mm as type III.

## RESULTS

The incidence of types of OF [Table 1] and sex-wise distribution of the OF [Table 2].

### Male-Female

Type I OF was found in 102 patients (25.5%), of which 56 (28%) were found on the right side and 46 (23%)

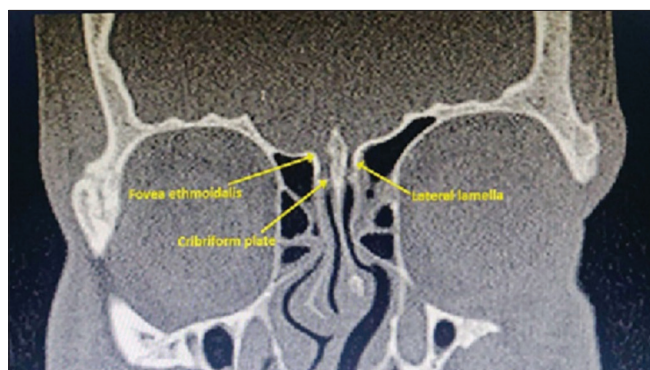


Figure 1: Depth of the olfactory fossa measurement

on the left side. Type II OF was found in 280 patients (70%), of which 134 (67%) were found on the right side and 146 (73%) on the left side. Type III OF was found in 18 patients (4.5%), of which 10 (5%) were found on the right side and 08 (4%) on the left side. The sex-wise distribution of the depth of OF I is provided in Table 2.

Although minor variations in dimensions were present in nearly all patients, most of them fell in the same subtype of the Keros classification ( $n = 177/200$ ). Asymmetry for the anatomical subtype to fall in different categories was found in 24 patients. Of these, the right OF was of a higher subtype in 12 patients (50%) and the left OF was of a higher subtype in 12 patients (50%) [Table 3].

## DISCUSSION

The OF is a depression in the anterior cranial cavity whose floor is formed by the cribriform plate of ethmoid. This delicate bony plate separates the anterior cranial fossa from the nasal cavity. OF is bounded laterally by the lateral lamella of cribriform plate and medially by crista galli.<sup>[7]</sup> It contains the olfactory bulbs and tracts. The lateral lamella is the thinnest bone in the anterior skull base. It is dehiscent in up to 14% of patients.<sup>[8]</sup>

The levels of the ethmoid roof/fovea ethmoidalis and cribriform plate may differ even in the same person depending on the vertical extent of the lateral lamella.

Table 1: The incidence of types of olfactory fossae

Keros type	Right (%)	Left (%)	Total (%)
I	56 (28)	46 (23)	102 (25.5)
II	134 (67)	146 (73)	280 (70.0)
III	10 (5)	08 (4)	18 (4.5)
Total	200	200	

Table 2: Sex-wise distribution of the olfactory fossae

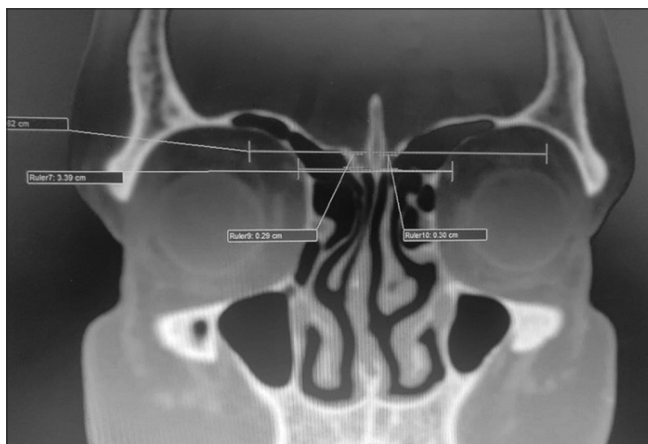
Keros type	Right	Left	Right	Left
I	20	22	36	24
II	72	82	62	64
III	4	5	6	3

Table 3: Asymmetry in the depth of the olfactory fossae

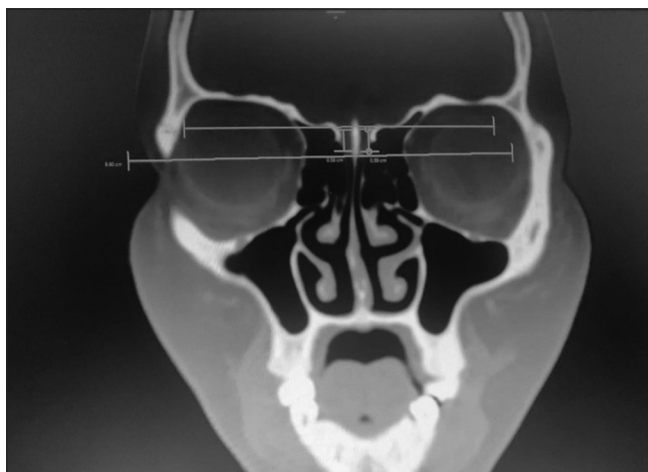
Types	Number	Percentage
Same subtype	176	88
Asymmetry	24	12
Higher subtype on right	12	6
Higher subtype on left	12	6

The relationship between the OF and the ethmoid roof was studied by Keros in 450 skulls in 1962. He created a three-category classification system for depth of the OF in relation to the ethmoid roof. The depth of OF is measured by the vertical height of the lateral lamella of the cribriform plate (LLCP), that is, the difference between the height of the cribriform plate and ethmoid roof.<sup>[9-11]</sup> In Keros Type I, depth is 1–3 mm, Type II 4–7 mm, and Type III 8–16 mm.

In Keros Type I, the OF is flat. The ethmoid roof is almost in the same plane as the cribriform plate [Figure 2]. In Type II relationship, the lateral lamella is higher and the OF is deeper than type I [Figure 3]. In Type III, lateral lamella is higher with a deeper OF. The ethmoid roof lies significantly above the level of cribriform plate.<sup>[4,12]</sup>



**Figure 2: Coronal high-resolution computerized tomography image of paranasal sinuses showing Keros Type I olfactory fossa depth where fossa is shallow as ethmoid roof is very near to cribriform plate**



**Figure 3: Coronal high-resolution computerized tomography image of paranasal sinuses showing Keros Type II olfactory fossa depth where fossa is deeper than Figure 1 as ethmoid roof is away from cribriform plate**

Type III relationship is the most dangerous type for endoscopic sinus surgeries. Therefore, Keros type III is called dangerous ethmoid.<sup>[7,13]</sup> There is high chance of penetration through the LLCPC. Asymmetry in the OF depth or the height of ethmoidal roof is also associated with higher risk of intracranial penetration during surgeries such as FESS.<sup>[12,14]</sup> Iatrogenic injury can lead to various complications including ascending meningitis, intracranial hypotension from cerebrospinal fluid leak, meningocele, or meningoencephalocele.<sup>[15]</sup> Therefore, pre-operative evaluation of OF depth is of paramount importance in a successful FESS.

Various studies have showed that various ethnic groups have different configurations of the OF.<sup>[14-6,12,16]</sup> Thus, knowledge of the configuration and asymmetry of OF in the ethnic population of a particular geographical area are of paramount importance.

Our study has showed that type II (74.5%) OF was the most common in the population of Bihar. This was followed by type I (18.5%) and type III (7%). In our study, the fact that most patients had higher prevalence of Keros type II makes them more susceptible to the risk of operative complications. This is in concurrence with the study done by Salroo *et al.* for the North Indian population.<sup>[17]</sup> Furthermore, there was statistically significant asymmetry in the depth of right and left OF in males, right being deeper, which is in concurrence with the previous studies. There was no statistically significant asymmetry in females in our study.

As described in the initial study performed by Keros, the ethmoid roof configuration may present asymmetry in the height and angulation between sides in the same individual.<sup>[10]</sup> Souza *et al.* and Shama *et al.* have demonstrated that the LLCPC is symmetrical in <50% of individuals, and this is also in many cases related to flattening of the fovea ethmoidalis, angulation of the LLCPC, causing intraoperative difficulties, and complications.<sup>[5,16]</sup>

## CONCLUSION

CT scan imaging has allowed detailed assessment of the sinonasal diseases and characterization of paranasal sinus anatomy. Understanding the complex anatomic relationship of ethmoid roof and its variability is crucial to avoid potential intracranial complications during endoscopic sinus surgery. Hence, evaluation of the depth of the OF and presence of ethmoidal roof asymmetry represent a significant aspect in tomographic studies, and should be included in the routine description of tomographic reports.

## REFERENCES

1. Kushwah AP, Bhalse R, Pande S. CT evaluation of diseases of paranasal sinuses a histopathological studies. *Int J Med Res Rev* 2015;3:1306-10.
2. Schnipper D, Spiegel JH. Management of intracranial complications of sinus surgery. *Otolaryngol Clin North Am* 2004;37:453-72.
3. Stankiewicz JA. Complications of endoscopic intranasal ethmoidectomy. *Laryngoscope* 1987;97:1270-3.
4. Paber JE, Cabato MS, Villatra RL, Hernandez JG. Radiographic analysis of the ethmoid roof based on Keros classification among Filipinos. *Philipp J Otolaryngol Head Neck Surg* 2008;23:15-9.
5. Souza SA, Souza MM, Idagawa M, Wolosker AM, Ajzen SA. Computed tomography assessment of the ethmoid roof:A relevant region at risk in endoscopic sinus surgery. *Radiol Bras* 2008;4:143-7.
6. Solares CA, Lee WT, Batra PS, Citardi MJ. Lateral Lamella of the cribriform plate. Software-enabled computed tomographic analysis and its clinical relevance in skull base surgery. *Arch Otolaryngol Head Neck Surg* 2008;134:285-9.
7. Jacob TG, Kaul JM. Morphology of the olfactory fossa a new look. *J Anatomic Soc India* 2014;63:30-5.
8. Vaid S, Vaid N. Normal anatomy and anatomic variants of the paranasal sinuses on computed tomography. *Neuroimag Clin* 2015;25:527-48.
9. Som PM, Lawson W, Fatterpekar GM, Zinreich J. Embryology, Anatomy, physiology and imaging of the sinonasal cavities. In: Som PM, Curtin HD, editors. *Head and Neck Imaging*. 5<sup>th</sup> ed. St. Louis, MO: Elsevier; 2011. p. 119-28.
10. Keros P. On the practical value of differences in the level of the lamina cribrosa of the ethmoid. *Z Laryngol Rhinol Otol* 1962;41:809-13.
11. Reddy UD, Dev B. Pictorial essay: Anatomical variations of paranasal sinuses on multidetector computed tomography how does it help FESS surgeons? *Indian J Radiol Imag* 2012;22:317.
12. Erdem G, Erdem T, Miman MC, Ozturan O.A radiological anatomic study of the cribriform plate compared with constant structures. *Rhinology* 2004;42:225-9.
13. Savvateeva DM, Güldner C, Murthum T, Bien S, Teymoortash A, Werner JA, *et al.* Digital volume tomography (DVT) measurements of the olfactory cleft and olfactory fossa. *Acta Otolaryngol* 2010;130:398-404.
14. Dessi P, Moulin G, Triglia JM, Zanaret M, Cannoni M. Difference in the height of the right and left ethmoidal roofs:A possible risk factor for ethmoidal surgery. Prospective study of 150 CT scans. *J Laryngol Otol* 1994;108:261-2.
15. Hoang JK, Eastwood JD, Tebbit CL, Glastonbury CM. Multiplanar sinus CT:A systematic approach to imaging before functional endoscopic sinus surgery. *Am J Roentgenol* 2010;194:W527-36.
16. Shama AM, Montasser M. Variations of the height of the ethmoid roof among Egyptian adult population: MDCT study. *Egyptian J Radiol Nuclear Med* 2015;46:929-36.
17. Salroo IN, Dar NH, Yousuf A, Lone KS. Computerised tomographic profile of ethmoid roof on basis of Keros classification among ethnic Kashmiri's. *J Otorhinolaryngol Head Neck Surg* 2016;2:1-5.

**How to cite this article:** Kumar A, Hasan S, Kumar D, Bhushan C, Prasad U, Suman SK. Computed Tomography Assessment of the Olfactory Fossa Depth in the Patients Presenting in Indira Gandhi Institute of Medical Sciences, Patna. *Int J Sci Stud* 2021;9(5):101-104.

**Source of Support:** Nil, **Conflicts of Interest:** None declared.