

Clinical-Medical Image

Asymptomatic Bochdalek's Hernia in Adults

Drissi Maniani Abdelilah*, Asaad El-Bakkari, Hounayda Jerguigue, Rachida Latib, and Youssef Omor

Department of Radiology, Faculty of Medicine and Pharmacy of Rabat, Oncology National Institute, Ibn Sina University Hospital, Rabat, Morocco

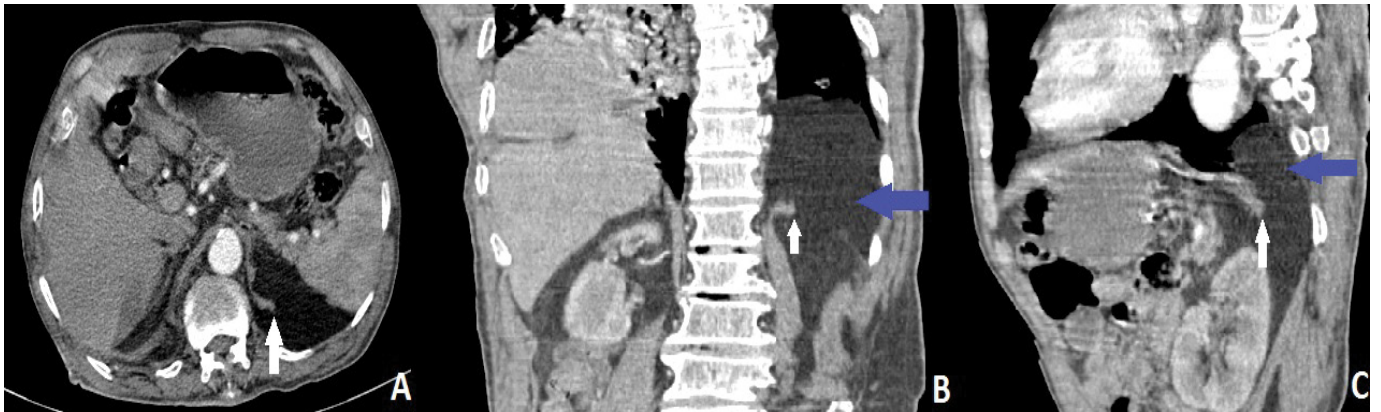


Figure 1: Axial (A) coronal (B) and sagittal views of an abdominal enhanced CT scan in arterial phase showing a large defect in the left dome of diaphragm (white arrow) with mental fat herniation into the thoracic cavity (blue arrow). The hernia orifice was located in the postero-lateral aspect of the left hemi-diaphragm which was in keeping with a late presenting Bochdalek type congenital diaphragmatic hernia.

Clinical Image

Bochdalek Hernia (BH) is a form of congenital diaphragmatic hernia, arises due to a defect of fusion of the diaphragmatic folds involving the posterolateral region most often on the left, unlike the Morgagni hernia type which arise anteriorly. The BH is seen in approximately 1 in 2500 live births. In 1848 Vincent Alexander Bochdalek described for the first time a form of herniation in the posterolateral region of the diaphragm.

The BH is usually evident during the neonatal period with acute onset of respiratory distress. Unlike the elderly, it may be asymptomatic or responsible for specific symptoms such as chest or abdominal pain, breathing difficulties or gastrointestinal symptoms. Chest x-ray can mimic a pneumothorax or pleural effusion, while multiplanar CT or MRI can better detect the small and asymptomatic diaphragmatic defects in adults. The treatment is surgical by thoracotomy or laparotomy; it can be performed days to years later depending on the patient's condition (Figure 1).

Keywords: Bochdalek hernia; Chest X-ray

Declaration of Interests: The authors declare that they have no competing interests.

*Corresponding author: Drissi Maniani Abdelilah, Department of Radiology, Faculty of Medicine and Pharmacy of Rabat, Oncology National Institute, Ibn Sina University Hospital, Rabat, Morocco, Tel: + 212694666260; E-mail: abdelilah1991drissi@gmail.com

Citation: Abdelilah DM, Bakkari AE, Jerguigue H, Latib R, Omor Y (2020) Asymptomatic Bochdalek's Hernia in Adults. *Int J Clin Med Imaging* 7:746.

Copyright: © 2020 Abdelilah DM, et al. This is an open-access article distributed under the terms of the Creative Commons Attribution License, which permits unrestricted use, distribution, and reproduction in any medium, provided the original author and source are credited.