

CONJOINED TWINS

M.L. Kulkarni
C. Sureshkumar
V.G. George
V. Venkataramana

Since ancient times the entity of conjoined twins has fascinated both lay and medical people alike. The most well known conjoined twins were Chang and Eng Bunker who were born in Siam in 1811(1). They lived unseparated for 63 years and at the age of 31 they married two sisters who bore 21 children. They died within hours of each other, Chang from bronchitis and Eng from "fright" soon thereafter(1). Rosalia and Josepha Blazek were born in 1878 joined together at the buttocks, Rosalia being the first such twin to mother a normal infant. At the age of 43 they died within minutes of each other of an unidentified illness(2).

From the Department of Pediatrics, J.J.M. Medical College, Davangere 577 004, Karnataka.

Reprint requests: Prof. M.L. Kulkarni, 2373, M.C.C. "A" Block, Davangere 577 004, Karnataka.

Received for publication: April 6, 1994;

Accepted: May 18, 1994

Incidence

Conjoined twins represent one of the rarest forms of congenital anomalies. The incidence of conjoined twinning is estimated to be 1 in 50,000 to 1 in 1,00,000 deliveries(3,4). The incidence appears remarkably similar throughout the world, although an incidence as high as 1 per 20,000 births has been reported from Atlanta(5). In all reports females predominate over males approximately three to one(3,4). Approximately 40-60% of conjoined twins are still born and an additional 35% survive only one day(4,6).

Classification

The anatomic sites shared by conjoined twins can be complex, the current nomenclature being derived from the most prominent site of conjunction(7) (*Fig. 1*).

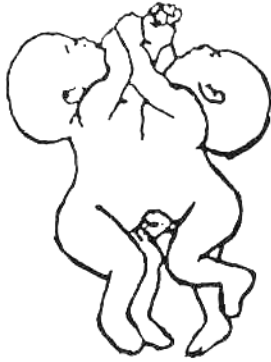
Thoracopagus

Thoracopagus infants face one another and have the major junction at the level of the chest with a common sternum, thoracic cage, diaphragm and abdominal walls down to umbilicus. Thoracopagus constitute 40% of conjoined twins(6). In these twins, 75% have conjoined hearts, 50% have fusion of intestinal tracts and virtually all have a shared liver(6,8,9).

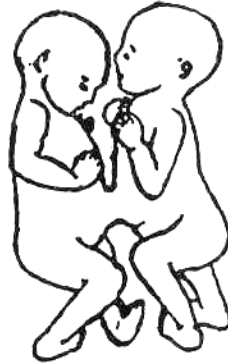Omphalopagus or Xiphopagus (*Figs. 2-4*)

In omphalopagus the twins face each other and are usually joined anteriorly from the xiphoid to the umbilicus. The peritoneal cavities are in communication with varying degrees of fusion of the liver and gastrointestinal tracts. Two third of the patients have a bridge of liver connecting them and a bridge of bladder may also be

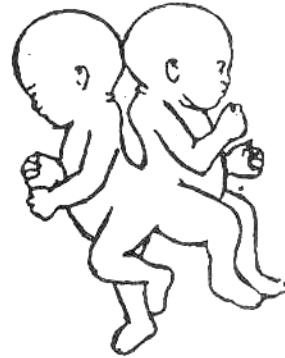CONJOINED TWINS - SYMMETRIC FORMS



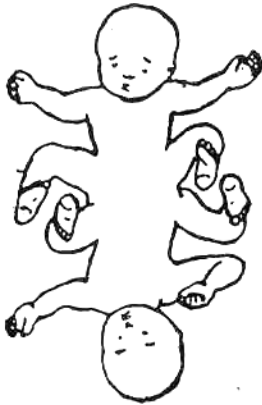
THORACOPAGUS



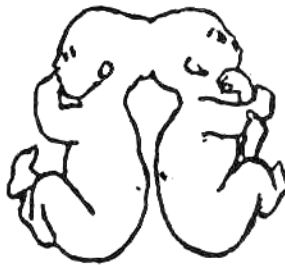OMPHALOPAGUS



PYGOPAGUS



ISCHIOPAGUS



CRANIOPAGUS



JANICEPS TWINS

CONJOINED TWINS - ASYMMETRIC FORMS (HETEROPAGUS)

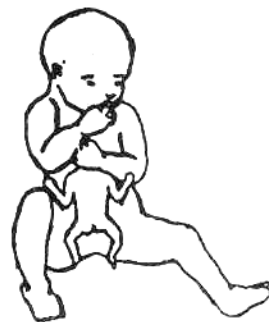

Fig. 1. Types of Conjoined Twins.

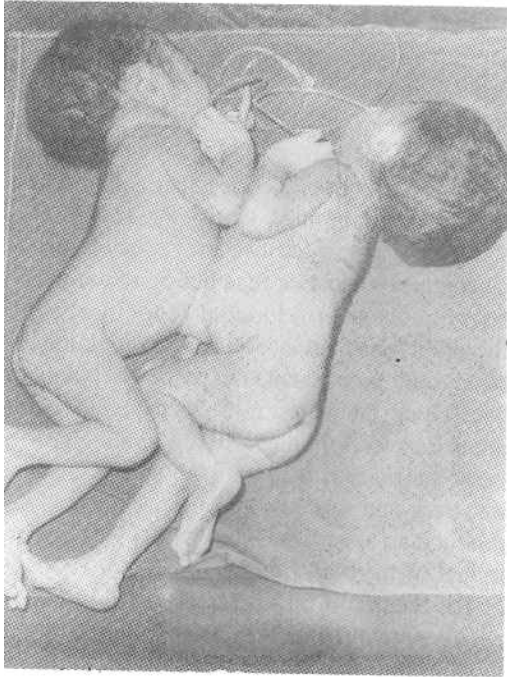

Fig. 2. Omphalopagus.

common(6,8). Harper *et al.* have published an extensive review of xiphopagus conjoined twins(10).

Pygopagus

The twins are joined at the gluteal region with fusion of the sacrum. As a result, these twins face away from each other and usually have a common sacral spinal canal as well as a single anus and rectum. The lower genital tract and external genitalia are also shared. The incidence is approximately 18% of all conjoined twins(6).

Ischiopagus (Fig. 5)

There is a junction at the pelvic level with sharing of genitourinary structures, rectum and liver. There may be either three or four lower extremities. The incidence is 6% of all conjoined twins(6).

Craniopagus

In craniopagus twins, the fusion is at the skull involving the brow, vertex or parietal

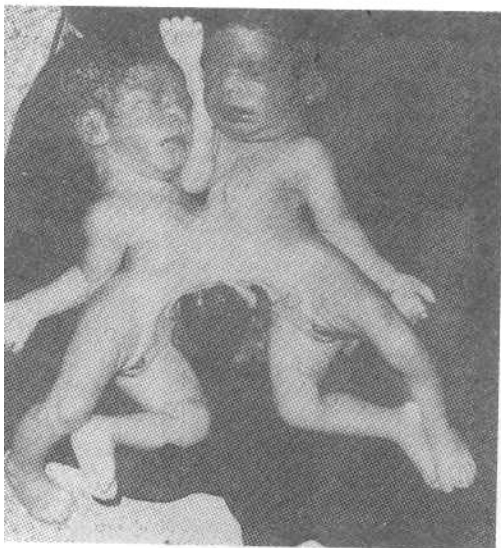

Fig. 3. Thoraco omphalopagus (Tetrapus).

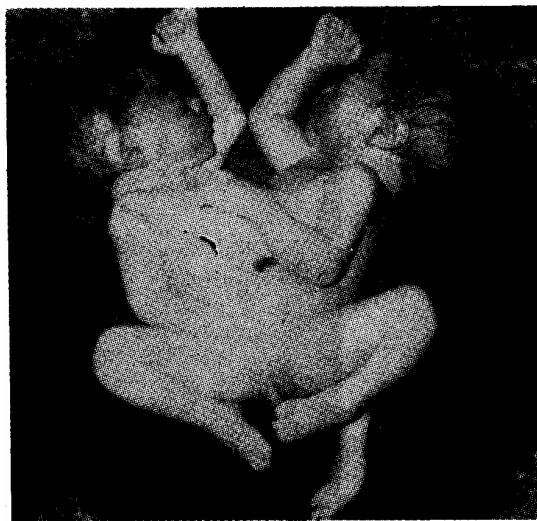


Fig. 4. Thoraco omphalopagus (Tripus).

bone. In the partial form of craniopagus, the brain is separated by bone or dura, whereas the total form has an extensive connection of brain tissue or separation only by the arachnoid layer. Craniopagus has an incidence of approximately 1-2% of all conjoined twins(6). Craniothoracopagus, a rare variety with a single fused head and two faces looking in opposite direction is referred to as Janiceps twins(11).

Heteropagus (Figs. 5 & 6)

These are asymmetric forms. There may be parasitic attachment in non-duplicated fashion to any portion of the body or even within the body as a fetus in fetus(8). Sometimes one may be less complete and depend on the other(12).

Apart from junction at one anatomical site, conjoined twins can result from joining of multiple sites like, xiphomphaloischio- pagus, craniothoracopagus, *etc.*(11,13). Tetrapus and tripus are subtypes in all the groups. Tetrapus refers to twins in which

four lower extremities are present whereas in tripus two adjacent lower extremities are fused to one(6).

Etiology

There are two theories explaining the etiology of conjoined twins(14): (i) Collision theory by which two previously duplicated embryonic axis fuse before tissue differentiation; and (ii) Fission theory in which the embryonic tissue divides incompletely, remaining fused at some point or points. The latter theory is more acceptable. At about 2nd week in the normal twinning process, the inner cell mass splits into 2 separate and nearly equal halves each usually producing a single individual(14). Conjoined twins result from an arrest in division of the inner cell mass that occur in monozygotic twins(6). Conjoined twins are monozygous and therefore will be of the same sex and usually with a monochorionic and monoamniotic placenta(6). Two cases of monochorionic, diamniotic conjoined twins have been reported in literature(15).

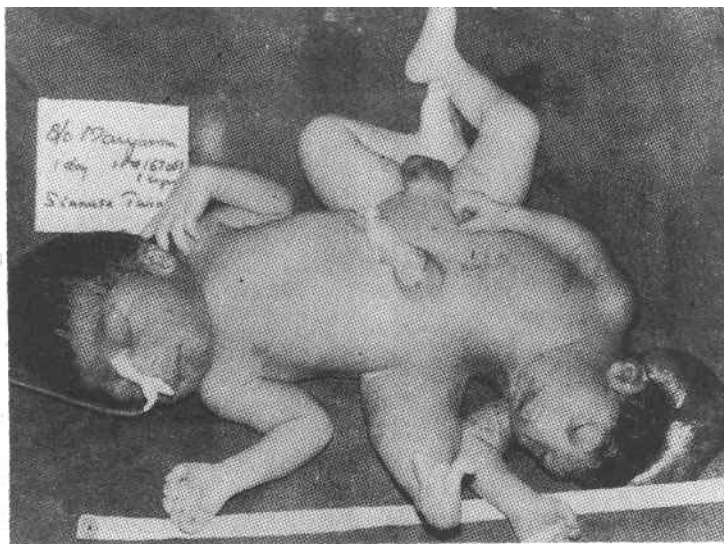


Fig. 5. Ischiopagus.

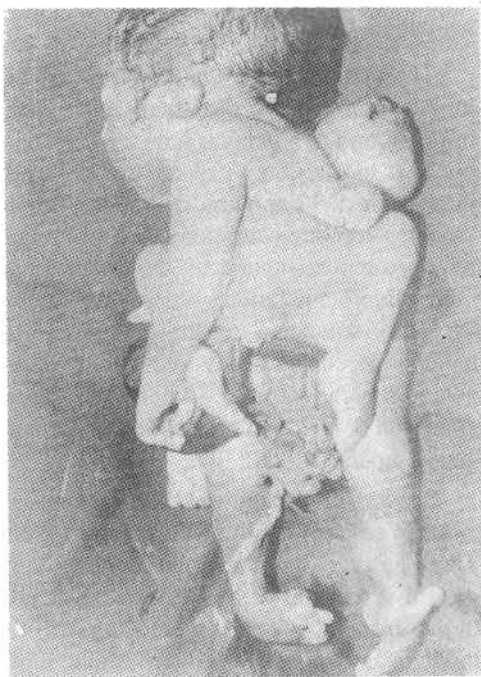


Fig. 6. Heteropagus.

The incidence of congenital anomalies in monozygotic twins are markedly more when compared to singleton fetuses or dizygotic fetuses. Conjoined twins have even more malformations than separate monozygotic twins(16). Some of them are related to the junction site. But even if these are excluded, almost half of conjoined twins have an anatomically unrelated malformation(16). Even though the majority of conjoined twins are externally symmetrical, their viscera are often, neither identical nor mirror images of each other(17).

Evaluation

The identification of associated anomalies is important in postnatal evaluation of conjoined twins. With regard to the cardio-

vascular system, in thoracopagus there is a common pericardium in 90% and the hearts are joined in 75%(6,8). Cardiovascular anomalies reported include atrial fusion with separate ventricles, atrial and ventricular fusion, single atrium with a large atrial septal defect, a single atrioventricular valve, single ventricle and a large ventricular septal defect, pulmonary atresia, truncus arteriosus and fusion or transposition of great vessels(11,17). Cardiac anomalies are seen not only in thoracopagus type, but there is high incidence in all forms of conjoined twins(8).

Preoperative evaluation of cardiovascular system may have to be done by ECG, Echocardiography and rarely by radionuclide, cardiography and angiography(8).

The evaluation of gastrointestinal tract should be from top to bottom. Contrast gastrointestinal X-ray films help to determine where gastrointestinal structures are shared. Ultrasonography can provide information regarding liver, gallbladder and pancreas. Radionuclide excretion scanning permits noninvasive evaluation of biliary tree(8).

Urinary tract in conjoined twins need to be evaluated for number and status of the kidneys, number of urethra, bladder, in case of females the number of vagina, whether cervix is seen with each vagina, etc.(8,11). Ultrasonography, conventional pyelography, cystourethrography and computed tomography can be used for evaluation of urinary tract.

Prenatal Diagnosis

A prenatal diagnosis of conjoined twinning is essential for appropriate obstetric management. The possibility of diagnosing conjoined fetuses by simple X-ray film is generally estimated as poor today(18).

Ultrasonographic examination is used as a screening method for diagnosis of these malformations. If doubt remains reontgenographic examination may be followed. The first report of successful antenatal diagnosis of conjoined twins by ultrasonography was reported in 1977. Prenatal ultrasonography has detected conjoined twins as early as 12 weeks of gestation(18).

Ultrasonographic findings that suggest the presence of conjoined twins include, bibireech or bicephalic position, single inseperable trunk with continuous external skin contour, face to face position of fetuses, hyperextension of both cervical spines, constant relative fetal position, fetal extremities in unusual proximity, solitary large liver and heart, solitary umbilical cord with more than 3 vessels, fetal body parts at the same level, etc.(10,14,19,20).

Another technique that has been extremely useful in the evaluation of conjoined twins *in utero* particularly those of the thoracopagus is echocardiography(10).

Amniography and fetoscopy are two confirmatory procedures(14). Amniography was once useful but it has been superceded by newer techniques. In fetography an oil contrast medium is used which dissolves in the vernix and, therefore, can demonstrate much after details as compared to amniography(14). In addition, because of the lower diffusion of the material, the amniotic fluid is much less opacified, hence there is better visualization. This examination, however, has the risk of premature labor, bleeding from, coed or placenta and infection(14). High solution real time ultrasonography can replace amniography and fetography (14,18). Magnetic resonance imaging is a valuable complementary imaging modality, that has limited availability(21).

Management

The separation of conjoined twins has long been a surgical challenge. The timing of separation as a general principle is probably best to plan on an elective basis when infants are 9-12 months of age(8). Sometimes emergency conditions such as intestinal obstruction, rupture of an omphalocele, congestive heart failure, obstructive uropathy and intractable respiratory embarrassment do occur and may necessitate emergency separation(6,8). Sometimes critical condition of one twin may necessitate emergency separation(22,23).

Successful separation of thoracopagus twins in cases of conjoined heart is difficult. There has been only a single report of successful separation of a conjoined heart and in that instance it was conjoined atria(8). In thoracopagus category without cardiac junction, separation is feasible(8). In omphalopagus a large omphalocele is usually present. Separation is delayed until the omphalocele sac can be made to epithelialize(10). The bridge connecting omphalopagus twins does not tend to grow in diameter, whereas the abdominal cavities do(10). So easier abdominal wall closure can be performed around the age of one year.

In ischiopagus twinning, there will be complicated forms of conjunction at the lower gastrointestinal tracts as well as of pelvic skeletal structures(8,11). Fortunately, in pygopagus twins, the structures that require separation are not generally essential for survival, although frequently there is a single rectum and anus and occasionally common genitourinary structures(8). In the majority of instances, the spinal cords are separate even though there is sacral junction. The outlook for craniopagus forms of conjoined twins relates to whether the brain junction is complete or incomplete(8).

Thus, the separation of even complicated forms of twinning may be faced with optimism(6,8,13) with the availability of newer imaging modalities.

Many ethical issues arise when separation of twin is considered especially when there are insufficient parts for two individuals. If one twin is healthy or physically impaired compared with the other, the allocation of the organs can be tilted towards the better twin(8).

Sacrificing of one of the twins is inevitable in the event of conjoined heart or when there is a single extrahepatic biliary system.

Analysis of all the data available and a thorough consultation with the parents are needed before making a decision especially when there is no difference between twins. Some of the twins are non separable under which circumstances the parents need a great deal of support. Early prenatal diagnosis will allow the parents the option of interrupting pregnancy, when it is evident that anatomic reparation will not be possible.

Prognosis

Majority of conjoined twins are dead born or die soon after birth. Attempt at surgery is done in only a few cases and probably a large number of unsuccessful operations are not reported in the literature(23). The results of surgery depend on the type of conjoined twin, the degree and type of organs shabby the twin, associated malformations general condition of the twins and finally on the medical and surgical treatment available.

Most successful cases are reported in omphalopagus twins. Of the 55 operated cases from 1689 to 1972, separation with survival of both twins was possible only 13 times(23).

In thoracopagus, results are generally very poor because of sharing of hearts in many cases. Similarly the results of separation in craniopagus are poor; in 12 attempted pairs till 1972, 4 pairs have survived(23).

In ischiopagus although separation has been reported few times, the children are left with severe handicaps.

REFERENCES

1. Wallace IW, Wallace A. *The Two*. New York, Simon and Schuster Inc, 1978.
2. Guttmacher AF. Biographical notes on some famous conjoined twins. *In: Birth Defects Original Article Series*. Ed Bergsma D, New York, The National Foundation - March of Dimes 1967, III: pp 10-17.
3. Hanson JW. Incidence of conjoined twins. *Lancet* 1975, ii: 1257.
4. Edmunds LD, Layde PM. Coinjoined twins in the United States, 1970-1977. *Teratology* 1982, 25: 301-308.
5. Compton HL. Conjoined twins. *Obstet Gynecol* 1971, 37: 27-33.
6. Shapiro E, Fick WR, Ternberg JL, Siegel MJ, Bell MJ, Manley CB. Ischiopagus tetrapus twins: Urological aspects of separation and 10 year follow up. *J Urology* 1991, 145: 120-125.
7. Votteler TP. Conjoined twins. *In: Pediatric Surgery*. Eds Welch KJ, Randolph JG, Ravitch MM, *et al*. Chicago, Year book Medical Publishers, 1986, pp 829-836.
8. O'Neill JA, Holcomb HW, Schnauffer L, *et al*. Surgical experience with thirteen conjoined twins. *Ann Surg* 1988, 208: 299-312.
9. Fitzgerald EJ, Toi A, Cochlin DL. Conjoined twins: Antenatal ultrasound diagnosis and a review of the literature. *J Radiol* 1985, 58: 1053-1056.
10. Harper RG, Kenigsberg K, Sia CG, Horn D, Stern D, Bongiovi V. Xiphopagus conjoined twins: A 300 year review of the obstetric, morphopathologic, neonatal and

CONTINUING MEDICAL EDUCATION

- surgical parameters. *Am J Obstet Gynecol* 1980, 137: 617-629.
11. Nolan R, Lond F, Langlotz H, Fletcher A. Cephalothoracopagus janiceps disymmetros twinning. *J Ultrasound Med* 1990, 9: 593-598.
 12. Biswas SK, Gangopadhyay AN, Bhatia BD, Bandopadhyay D, Khanna S. An unusual case of heteropagus twinning. *J Pediatr Surg* 1992, 27: 96-97.
 13. Spitz L, Capps SNJ, Kiely EM. Xi-phoomphaloischiopagus tripus conjoined twins: Successful separation following abdominal wall expansion. *J Pediatr Surg* 1991, 26: 26-29.
 14. Wedberg R, Kaplan C, Leopold G, Porreco R, Resnik R, Benirschke K. Cephalothoracopagus (Janiceps) twinning. *Obstet Gynecol* 1979, 54: 392-396.
 15. Weston PJ, Ives EJ, Honors RLH, Lees GM, Sinclair DB, Schiff D. Monochorionic diamniotic minimally conjoined twins—A case report. *Am J Med Genet* 1990, 37: 558-561.
 16. Seller MJ. Conjoined twins discordant for cleft lip and palate. *Am J Med Genet* 1990, 37: 530-531.
 17. Gore RM, Filly RA, Parer JT. Sonographic antepartum diagnosis of conjoined twins. It's impact on obstetric management. *JAMA* 1982, 247: 3351-3353.
 18. Schmidt W, Heberling D, Kubli F. Antepartum ultrasonographic diagnosis of conjoined twins in early pregnancy. *Am J Obstet Gynecol* 1981, 139: 961-963.
 19. Wilson RL, Shaub MS, Cetrulo CJ. The antepartum findings of conjoined twins. *J Clin Ultrasound* 1977, 5: 35-37.
 20. Austin E, Schiffrin BS, Pomerance JJ, Gans SL, Komaiko MS. The antepartum diagnosis of conjoined twins. *J Pediatr Surg* 1980, 15: 332-334.
 21. Turner RJ, Hankins GDV, Weinreb JC, *et al.* Magnetic resonance imaging and ultrasonography in the antenatal evaluation of conjoined twins. *Am J Obstet Gynecol* 1986, 155: 645-649.
 22. Dorig AT. Successful separation of ischiopagus tripus conjoined twins with one twin suffering from brain damage. *J Pediatr Surg* 1993, 28: 965-968.
 23. Stauffer WJ. Conjoined twins. *In: Neonatal Surgery*, 3rd edn. Eds Lister J, Irving IM, London, Butterworths, 1990, pp 153-162.