

## Aberrant Pancreatic Tissue Causing Gastric Ulcer and Pyloric Obstruction

**Poonam U. Patil**  
**Vijaya Shenoy**  
**P.L.N.G. Rao**

Aberrant pancreas causing pyloric obstruction is extremely rare; only fifteen cases(1-5) have been reported in the literature so far. There are no reported associated congenital anomalies. We report a 5 year old boy with ectopic pancreatic tissue presenting as gastric outlet obstruction with associated patent ductus arteriosus.

### Case Report

A 5-year-old boy was admitted for recurrent episodes of upper abdominal pain and vomiting for the past two years associated with loss of weight. The vomiting was non projectile, occurred shortly after meals, and was never blood or bile stained. On examination there was visible gastric peristalsis and mildly enlarged liver. The cardiovascular system examination revealed a continuous murmur in the pulmonary area suggestive of patent ductus arteriosus.

---

*From the Department of Pediatrics, Kasturba Hospital, Manipal, Karnataka.*

*Reprint requests: Dr. Poonam Patil, Department of Pediatrics, Kasturba Hospital, Manipal, Karnataka 576 119.*

*Received for publication: August 4, 1994;*

*Accepted: October 6, 1994*

The laboratory studies were all essentially normal. The endoscopic examination of the stomach revealed an edematous stomach filled with ingested food and the pylorus could not be visualized. The barium studies showed a narrowed pyloric canal with gastric outlet obstruction and delayed emptying of the stomach. Echocardiography confirmed the clinical diagnosis of patent ductus arteriosus.

Laparotomy revealed a growth in the pylorus adherent posteriorly to pancreas and transverse mesocolon with enlarged nodes in the greater omentum along with right gastro epiploic artery. After releasing the adhesions, involvement of the pancreatic head was ruled out. The mass was resected 5 cm proximal to the palpable margin of growth and a partial gastrectomy and gastrojejunal anastomosis was done. Per operative diagnosis was a leiomyoma of the stomach.

The resected specimen showed a perforated ulcer at the pylorus measuring 1.5 cm x 2.5 cm with normal rugosities in the rest of the mucosa. Microscopic examination revealed marked hypertrophy of muscularis propria with gastric mucosal and Brunners glands buried deep within the muscle fibres along with lobules of pancreatic acini and dilated ducts (*Fig. 1*). The lymph nodes and resected ends of the stomach did not show any significant pathology.

Postoperative recovery was uneventful with relief from symptoms and satisfactory weight gain. Follow up of the patient showed adequate weight gain with no recurrence of symptoms.

### Discussion

The role of nodular pancreatic rests

in the production of gastrointestinal complaints remains controversial and pathology obscure. Lesions of large size can obliterate the lumen and give rise to intermittent obstruction or serve as a lead point for intussusception. Overlying ulceration may result in hemorrhage. The aberrant pancreatic tissue may incite pylorospasm due to proximity and/or localized secretions. This in turn can cause delayed gastric emptying and gastric distention with resultant symptoms. In a series of nine children with ectopic pancreatic tissue studied by Molitt and Golladay(5), it was seen that younger children (6 months, 8 months, 4 years) presented with vomiting and failure to thrive, which was also seen in our case,

whereas older children (11,12,13 years) had chronic mid-abdominal pain. In three cases, these lesions were incidental findings at the time of unrelated surgery. Vomiting was a presenting feature in other cases reported(2).

Preoperative diagnosis is difficult and a reliable diagnosis can be made only by endoscopic biopsy(5). In our case also, we could not find a definite cause for the gastric outlet obstruction preoperatively, which was also experienced by others(1-4) who had kept the preoperative diagnosis as gastric tumor of hypertrophic pyloric stenosis. In the series of cases published by Molitt and Golladay(5), the diagnosis was arrived

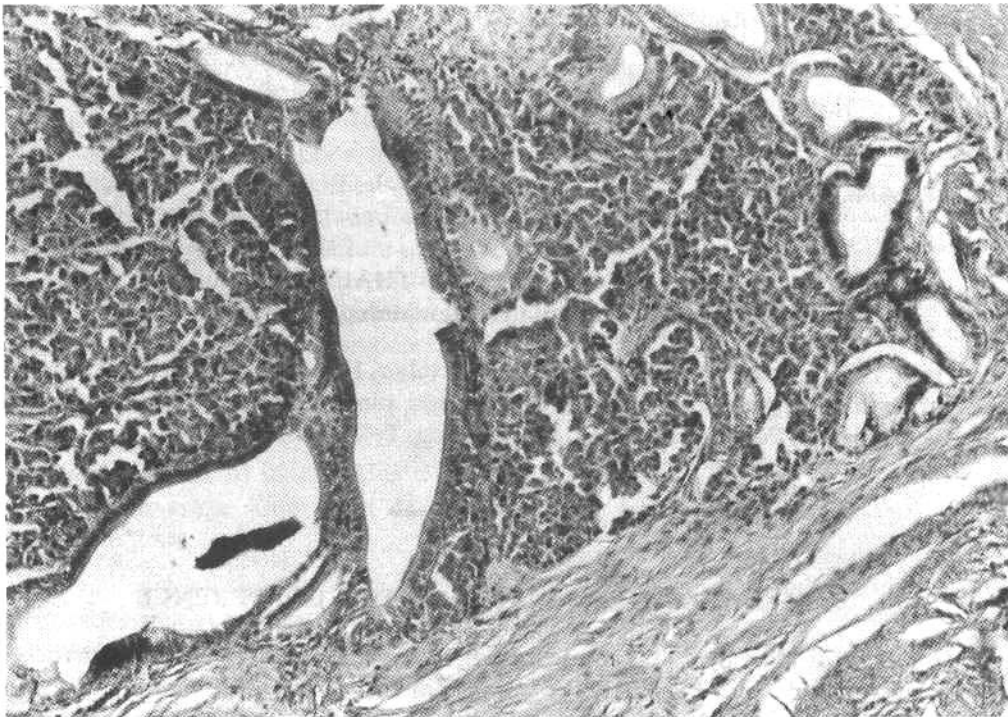


Fig. 1. Section of resected specimen of the pylorus showing pancreatic acini suggestive of ectopic pancreatic rest.

at preoperatively, by endoscopic examination and biopsy. Histologic examination of the resected specimen showed evidence of a perforated ulcer along with ectopic pancreatic tissue in the pylorus. This association, though described in literature has not been reported in other pediatric cases. The treatment is surgical resection of the mass. Ramstedt procedure was performed in two cases(2), but the obstruction persisted in both the children and they died. Rest of the children underwent resection and survived. In our case, partial gastrectomy and gastro-jejunal anastomosis was done with favorable results. Association of ectopocic pancreatic tissue with other congenital anomalies has not been reported in literature. Our case had a patent ductus arteriosus in association

with ectopic pancreatic tissue in the pylorus of the stomach.

#### REFERENCES

1. Eklof O, Lassrich A, Stanley P. Ectopic pancreas. *Pediatr Radiol* 1973,1: 24-27.
2. Ishihara M, Yamazaki T, Ariwa R, Imura S, Maezawa M. Aberrant pancreatic tissue causing pyloric obstruction. *Pediatr Surg Int* 1990, 5:140-141.
3. Kernohan RJ, Morison JE. Symptomatic pancreatic heterotopia of pylorus associated with bilateral renal necrosis in an infant. *Arch Dis Child* 1956, 31: 276-279.
4. Matsumoto Y, Kawai Y, Kimura K. Aberrant pancreas causing pyloric obstruction. *Surgery* 1974, 76: 827-829.
5. Molitt DL, Golladay ES. Symptomatic gastroduodenal rest in children. *J Pediatr Surg* 1984,19: 449-450.