

Intestinal obstruction and the double bubble sign

Intestinal obstruction in a newborn infant is associated with numerous aetiologies. Following a careful clinical examination, gastrointestinal imaging can reveal the presence of the 'double bubble' sign on an abdominal X-ray. Various conditions can result in a double bubble; being aware of these conditions and recognising their imaging pattern will help in early diagnosis and timely and appropriate management.

Bilal A. Sethi

Gydytojas (Lithuanian Medical Degree),
Msc Diagnostic Imaging
Specialist Registrar Radiology
b.sethi@nhs.net

Karen A. Duncan

FRCR, MRCP, DCH
Consultant Radiologist

Chris P. Driver

FRCS (Paed), FFSTEd
Consultant Paediatric Surgeon

Royal Aberdeen Children's Hospital, Scotland

The double bubble sign in newborn infants is seen on plain abdominal radiographs in a variety of conditions. It depicts two air-filled structures in the upper abdomen and represents a gas-distended dilated stomach and proximal duodenum, implying congenital proximal bowel obstruction.

The specific anomaly causing the obstruction will determine the appearance and presence of air distal to the obstruction. A neonate with a double bubble and no distal bowel gas (complete obstruction) can be presumed to have duodenal atresia and in most cases no further imaging is required. However, if double bubble is present with distal bowel gas (partial obstruction) the differential diagnosis includes duodenal stenosis, duodenal web, annular pancreas and midgut volvulus. In these cases usually an upper gastrointestinal (GI) contrast study is performed to distinguish between midgut volvulus, which requires emergent surgery, and other causes that can be repaired electively.

Duodenal atresia

The most common upper intestinal obstruction in neonates is duodenal atresia, in which the duodenum does not develop properly during embryogenesis resulting in a closed off tube that does not allow the passage of the stomach contents (FIGURE 1). It is associated with additional anomalies in >50% of cases, for example VACTERL association (vertebral defects, anal atresia, cardiac defects, tracheo-oesophageal fistula, renal anomalies, and limb abnormalities), shunt vascularity cardiac lesions (atrial septal defect, ventricular septal defect, patent ductus

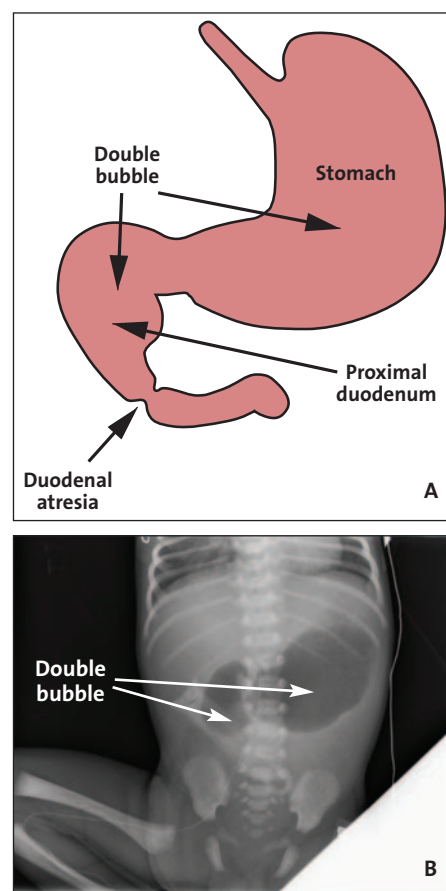


FIGURE 1 (A) Duodenal atresia and the double bubble. (B) A plain X-ray of a two-day-old infant born at 36 weeks' gestation showing the double bubble appearance in the upper abdomen with no gas seen distally. The baby had respiratory distress, sepsis and jaundice.

arteriosus) and annular pancreas. Thirty per cent of babies with duodenal atresia have Down's syndrome.

Infants with duodenal atresia present early in the neonatal period with abdominal distension, vomiting and absent bowel movements. If atresia is distal to the ampulla of Vater the vomiting is bilious.

Keywords

gastrointestinal imaging; double bubble; neonate; duodenal obstruction

Key points

Sethi B.A., Duncan K., Driver C. Intestinal obstruction and the double bubble sign. *Infant* 2016; 12(5): 175-78.

1. Infants presenting with vomiting, aspiration, abdominal distension and/or feeding intolerance in the neonatal period should be investigated for intestinal obstruction.
2. The classic 'double bubble' sign is seen on an abdominal X-ray in a number of obstructive anomalies.
3. The help of a radiologist will be necessary. Identifying these conditions promptly will ensure timely diagnosis and management.

If the atresia is proximal to the ampulla, the vomiting is non-bilious. With surgical treatment the survival rate is >90%.

GI imaging

- Plain radiographs reveal the double bubble sign without distal bowel gas (**FIGURE 1**). Rarely, a small amount of gas may be seen in the distal GI tract in the presence of biliary/pancreatic duct variations

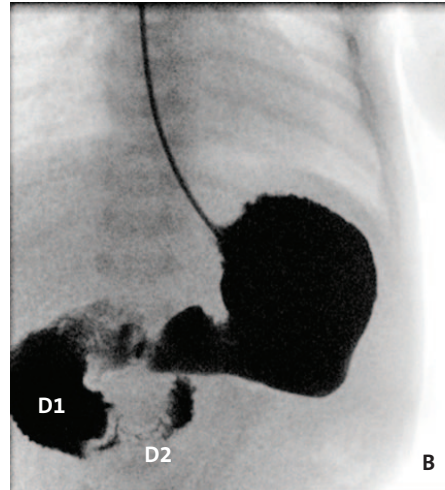
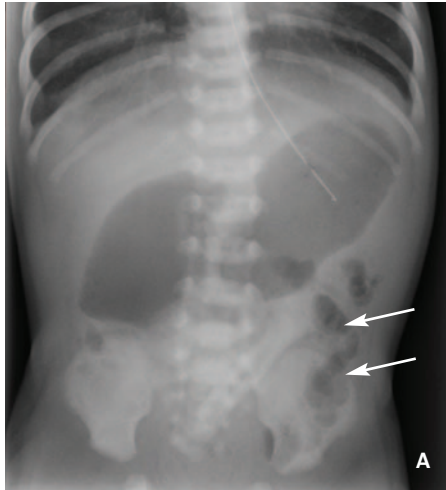


FIGURE 2 A one-day-old baby born at term with bilious vomiting and suspected sepsis. (A) A plain X-ray showing the double bubble appearance with gas seen in the jejunal loops (arrows). (B) An upper GI contrast study with contrast opacification of the stomach and dilatation of the first part of the duodenum (D1). There is circumferential narrowing of the second part of the duodenum (D2) and the duodenum crosses the midline (this excludes malrotation).

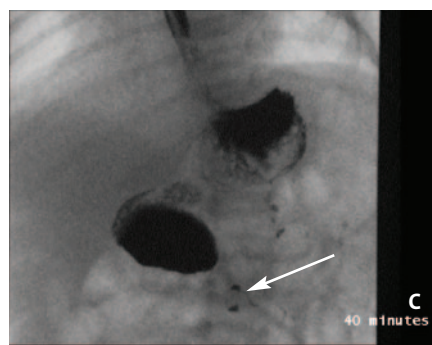
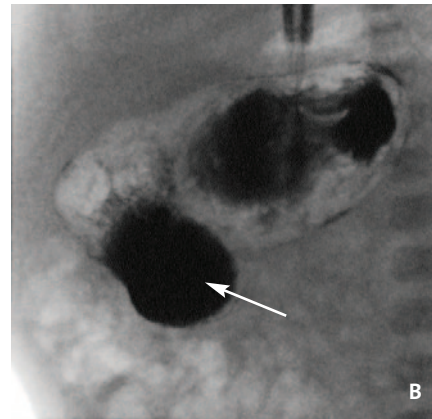
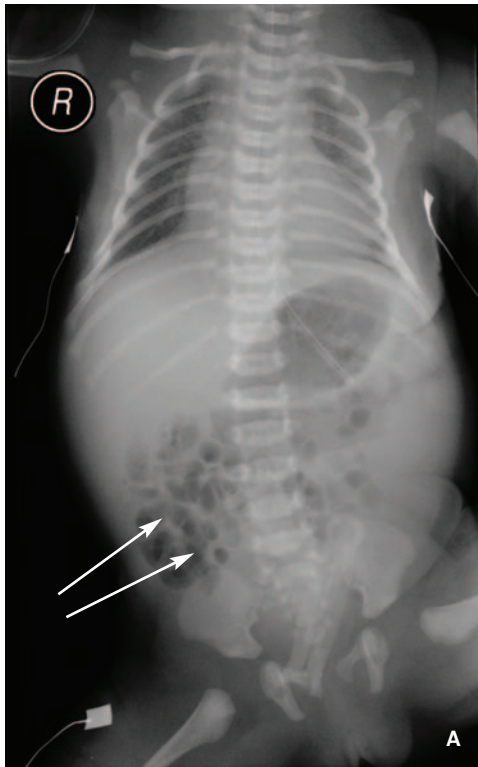

FIGURE 3 A term baby with morphological features of trisomy 21; an atrioventricular septal defect and the double bubble sign were seen on antenatal scans. (A) A plain X-ray showing a moderately dilated stomach and duodenum, with gas in the distal loops (arrows). (B) An upper GI contrast study with ballooning and dilatation of the proximal duodenum (the windsack sign, arrow) with (C) only a very small trickle of contrast seen passing into the distal duodenum after approximately 40 minutes (arrow).

allowing bowel gas to travel through the ampulla of Vater and enter the distal bowel. If the stomach or duodenum is decompressed by a nasogastric tube or vomiting, the double bubble may not be seen on initial radiographs.

- Ultrasound reveals a dilated fluid- and gas-filled stomach and duodenum.
- An upper GI contrast study shows contrast within the distended stomach and

proximal duodenum with no contrast seen distally, however, the study is not usually performed because radiographs are essentially diagnostic.

Duodenal stenosis

Duodenal stenosis is a less severe variant of a duodenal anomaly in which there is partial recanalisation of the duodenum during embryogenesis and fixed narrowing of the duodenal lumen. As with duodenal atresia, duodenal stenosis is associated with additional anomalies in >50% of cases.

Duodenal stenosis results in a variable and often delayed clinical presentation due to the incomplete nature of the obstruction. Infants may present with recurrent episodes of vomiting, aspiration or failure to thrive.

GI imaging

- Plain radiographs reveal the double bubble sign with distal bowel gas (**FIGURE 2**).
- Ultrasound reveals a dilated fluid- and gas-filled stomach and duodenum.
- An upper GI contrast study shows a focal or longer segment of fixed circumferential narrowing (**FIGURE 2**).

Duodenal web

A duodenal web refers to a membranous web or intraluminal diverticulum resulting in complete or incomplete obstruction at the duodenum. It is associated with Down's syndrome, malrotation and annular pancreas. It presents clinically as feeding intolerance, vomiting (bilious more than non-bilious), weight loss and dehydration. There is an excellent prognosis with treatment.

GI imaging

- Plain radiographs reveal the double bubble sign with distal bowel gas (**FIGURE 3**).
- Ultrasound reveals a dilated fluid- and gas-filled stomach and duodenum. Fluid may outline a thin web or show a hypo-echoic intraluminal diverticulum.
- An upper GI contrast study typically gives the windsack sign (**FIGURE 3B**), which represents an intra-duodenal barium contrast-filled sac surrounded by a narrow lucent line (web or intraluminal mucosal diverticulum).

Annular pancreas

An annular pancreas is a developmental anomaly in which a ring of pancreatic tissue surrounds the second portion of the

duodenum. It can be complete if the pancreatic parenchyma surrounds the duodenum or incomplete when the duodenum is not completely surrounded. It is associated with additional anomalies such as Down's syndrome, pancreas

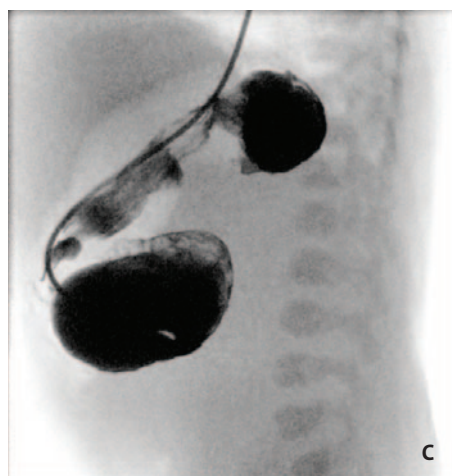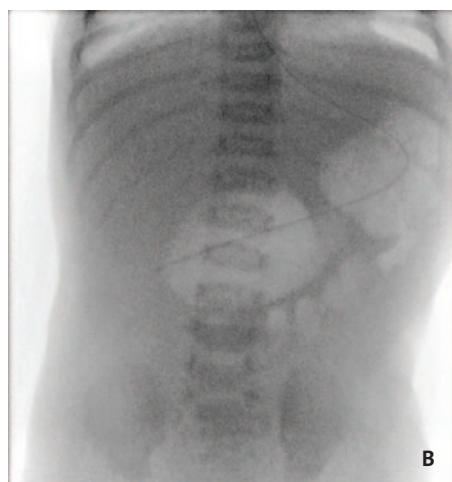

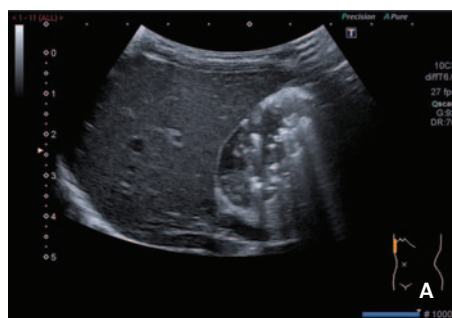
FIGURE 4 An eight-day-old baby with persistent non-bilious vomiting since birth and dehydrated with metabolic alkalosis. (A) Ultrasound of the abdomen, performed to rule out pyloric stenosis, showing a normal pylorus. The distended fluid-filled viscus in the region of the pylorus/duodenum raised the suspicion of duodenal obstruction. (B) The upper GI contrast study: on initial screening there was a double bubble sign with dilatation of the first part of the duodenum and a tiny amount of gas in the distal bowel. On injecting contrast, the stomach and dilated first and second portions of the duodenum are outlined with no drainage distally (C).

divisum, duodenal stenosis and malrotation. Newborn infants present with signs of duodenal obstruction with typically non-bilious vomiting, feeding intolerance and abdominal distension.

GI imaging

- Plain radiographs reveal the double bubble sign with distal bowel gas.
- Ultrasound reveals a dilated fluid-filled duodenum passing through the pancreas (**FIGURE 4**).
- An upper GI contrast study gives a dilated stomach and first portion of the duodenum, with delayed emptying (**FIGURE 4**). Circumferential narrowing of the second portion of the duodenum is seen.
- Magnetic resonance cholangiopancreatography (MRCP: a scan that specifically images the pancreatic and bile ducts) shows the pancreatic duct encircling the duodenum.

Malrotation and midgut volvulus

Malrotation is an abnormality of the bowel – a failure of the normal rotation of the bowel during embryogenesis. Midgut

volvulus is a complication of a malrotated bowel in which the intestine twists so that the blood supply to that part of the bowel is cut off; it is a surgical emergency with a high mortality rate and a delay in diagnosis can result in diffuse bowel necrosis and death. The newborn infant often appears entirely normal for a period of time before suddenly presenting with bilious vomiting.

GI imaging

- Plain radiographs may be normal but most commonly reveal multiple dilated loops of bowel. Less commonly they may show a double bubble, however, the dilated proximal duodenum is not markedly enlarged as usually seen in a longstanding obstruction such as duodenal atresia.
- Ultrasound reveals a clockwise whirlpool sign, seen when a structure twists on itself. In this instance, the bowel rotates around its mesentery with the mesenteric vessels creating the whirls (best seen on Doppler). An inverted superior mesenteric artery (SMA)-superior mesenteric

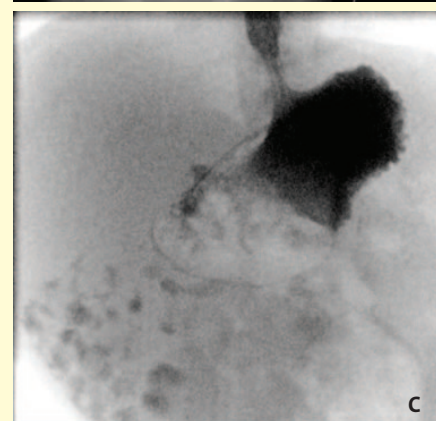
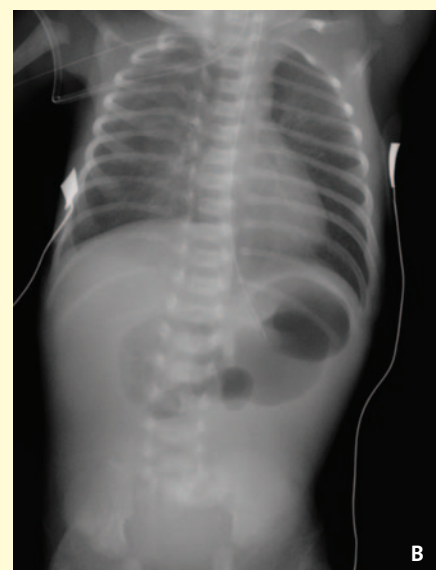
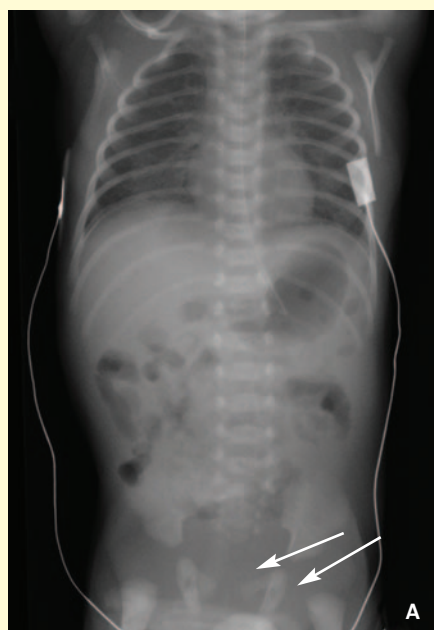
FIGURE 5 A one-day-old baby born at 36 weeks' gestation with bilious vomiting and very poor feeding. (A) A plain radiograph pre-malrotation showing a non-specific bowel gas pattern with gas seen within the distal bowel (arrows). (B) A plain radiograph post-malrotation: the double bubble sign is seen with no gas distally. (C) An upper GI contrast study: contrast is confirmed in the small bowel in the right side of the abdomen with no evidence of crossing the midline to the left. The appearance is in keeping with malrotation.

vein (SMV) relationship is seen, with the SMV present to the left of the SMA.

- An upper GI contrast study is the investigation of choice if malrotation/midgut volvulus is suspected. The aim of the study is to exclude or demonstrate findings of malrotation (with or without volvulus) in newborn infants with bilious vomiting. On anteroposterior projection, the duodenojejunal flexure is seen to the right of the left sided vertebral body pedicle and inferior to the duodenal bulb. On lateral projection, the second-third portion of the duodenum is not located

posteriorly in the retroperitoneal position. In the presence of volvulus there is a spiral appearance of the distal duodenum and proximal jejunum – the corkscrew sign – and this is diagnostic for midgut volvulus.

Conclusion

Various conditions can result in a double bubble sign and management differs from one condition to another. Recognising these conditions by their imaging pattern will ensure an early diagnosis and subsequent timely management.

Further reading

1. **Mandell J.** *Core Radiology: A Visual Approach to Diagnostic Imaging.* Cambridge University Press; 2013.
2. **Radiopaedia.org.** *Duodenal Atresia.* [Online]. Available from: <http://radiopaedia.org/articles/duodenal-atresia>.
3. **Radiopaedia.org.** *Duodenal Web.* [Online]. Available from: <http://radiopaedia.org/articles/duodenal-web>.
4. **Radiopaedia.org.** *Annular Pancreas.* [Online]. Available from: <http://radiopaedia.org/articles/annular-pancreas>.
5. **Radiopaedia.org.** *Midgut volvulus.* [Online]. Available from: <http://radiopaedia.org/articles/midgut-volvulus>.

The British Association of Perinatal Medicine (BAPM) presents BASIC MULTI-PROFESSIONAL CLINICAL RESEARCH SKILLS TRAINING

Monday 17 October 2016
RCPCH, London, WC1X 8SH

Who should attend?

This training is suitable for any neonatal professional (medical, nursing, allied professions) wanting an introduction to research skills.


Overview

This one-day training workshop will provide delegates with an understanding of why research is important, methods of how to develop a research culture and information on how to bring a clinical trial to the unit. Delegates will also learn how to approach parents about research and ask for research consent. The workshop will include presentations from clinicians and parents and the chance to participate in role-play scenarios with feedback.

Fees and payment

Medical Members £70, Nursing and Allied Health Members £25

Book at: www.bapm.org/meetings/trainees-meeting-neonatal.php



BAPM Office: 5-11 Theobalds Road, London, WC1X 8SH • Registered Charity: 285357

www.bapm.org • +44 (0)207 092 6085 • bapm@rcpch.ac.uk