

Dermocystidium sp. infection in cultured juvenile southern catfish *Silurus meridionalis* in China

Qizhong Zhang^{1,2,*}, Zhijian Wang¹

¹School of Life Sciences, Southwest China Normal University, Chongqing 400715, PR China

²Institute of hydrobiology, Jinan University, Guangzhou 510632, PR China

ABSTRACT: A species of *Dermocystidium* was discovered on the skin and fins of reared southern catfish *Silurus meridionalis* Chen. The parasite only appeared and caused disease in juvenile catfish at a water temperature of 18 to 23°C. Marked external macroscopical clinical signs of the disease were sluggish movement of the fish, and the appearance of white filiform dermal cysts varying in size (3–20 mm in length and 0.15–0.35 mm in width). Examination of both fixed and fresh mounts for light microscopy and of samples for transmission electron microscopy (TEM) showed spherical spores (3.2–15 µm in diameter) with a peripheral nucleus (1.1–1.8 × 0.5–1.6 µm in diameter) and a prominent refractile body (2.08–10.83 µm in diameter) which occupied most of the volume of a mature spore. Three types of spore were identified, and are presumed to represent various developmental stages. Meanwhile, TEM showed the remnant nuclei in the residual plasmodium of a cyst, revealing its degenerative process. This paper represents the first observation and description of *Dermocystidium* sp. parasitizing catfishes.

KEY WORDS: *Dermocystidium* · Protozoa · Histology · *Silurus meridionalis*

Resale or republication not permitted without written consent of the publisher

INTRODUCTION

Dermocystidium is a genus comprised of unicellular parasites of fish and amphibians, with an uncertain taxonomic position. The minute spherical organisms have been assigned to the protozoa (Nash et al. 1989) or to lower fungi (Pauley 1967, Allen et al. 1968, Dykova & Lom 1992) by different researchers. Ragan et al. (1996) allocated the taxon to a novel clade (provisional name 'DRIPs' clade) near the animal-fungal divergence. Herr et al. (1999) established a new clade called Mesomycetozoa for *Rhinosporidium* and DRIPs. Although controversy still exists about the taxonomic affinity of the species in the genus *Dermocystidium*, it is believed that the common feature of the genus is the existence of a spherical spore with a peripheral nucleus and a refractile body or large central vacuole as a stage of the developmental cycle (Höglund et al. 1997, Lotman et al. 2000). *Dermocystidium* spp. are occasionally found in amphibians (Pascolini et al. 2003), but most commonly occur in fishes, especially in juveniles, and they produce diseases which have been

associated with fish mortalities (Pauley 1967, Allen et al. 1968, Hedrick et al. 1989, Nash et al. 1989, Olson & Holt 1995). The genus *Dermocystidium* is known to include ca. 20 species (Lotman et al. 2000), but just 4 species have been reported in China, i.e. *Dermocystidium koi* Hoshina-Sahara, 1950, *D. percae* Reichenbach-Klinke, 1950, *D. kwangtungensis* Chen, 1956 and *D. sinensis* Xiao et Chen, 1993 (Xiao & Chen 1993, Zhang et al. 1999). Although the genus is known from a wide variety of freshwater or marine fishes, to our knowledge no species has been reported from catfishes. This paper deals with a *Dermocystidium* species parasitizing juvenile southern catfish, *Silurus meridionalis* Chen.

MATERIALS AND METHODS

Fish. Juvenile catfish (8.2 to 15.3 cm in total length) for this study were sampled from net cages in Jialing River, Beibei, Chongqing, China. Fish were dissected and skin, including affected tissues, were sampled.

*Email: zhangqzdr@sohu.com

Light microscopy. Spore morphology was examined in unstained fresh and/or formalin-fixed wet mounts in an Olympus BH-2 light microscope. The cysts were removed from the fish skin and immediately fixed and preserved in 5% buffered formalin. Affected skin, kidney, liver, spleen, gills and gonads were fixed with 5% buffered formalin or Bouin's fixative for at least 48 h before transferring them to 70% ethanol and embedding them in paraffin-wax blocks, sectioning at 6 to 8 μm and staining with haematoxylin and eosin (H&E), before finally examining them by light microscopy.

Electron microscopy. Cysts for transmission electron microscopy (TEM) were fixed in 2.5% glutaraldehyde in 0.1 M phosphate buffer (pH 7.2) at 4°C for 24 h, and postfixed in 2% OsO_4 (in the same buffer) for 1 h, dehydrated in graded series of ethanol, and embedded in Epon 812 resin. Ultra-thin sections were stained with uranyl acetate and lead citrate prior to examination with a Phillips transmission electron microscope.

RESULTS

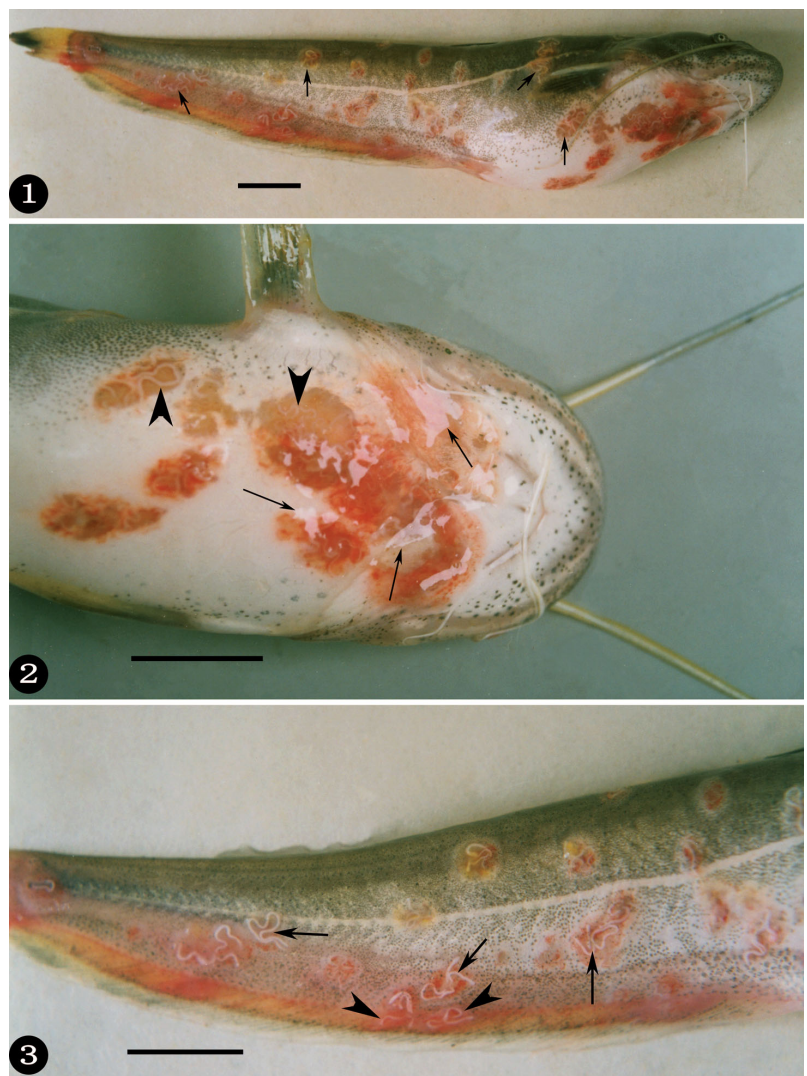
Clinical and gross pathology

Infected juvenile southern catfish were emaciated, and swam sluggishly on the water's surface of net cages in the river. The infected catfish were covered with structures looking at first sight like white worms or winding white threads, which were subcutaneous (Figs. 1 to 3). Closer examination showed these structures to be cysts of the *Dermocystidium* sp., which were only observed in skin and fins of the catfish, and were not found in other organs. Cysts of different sizes (3 to 20 mm in length and 0.15 to 0.35 mm in width) were located in the dermis in an irregular way (Figs. 1 to 3). The anal fin was often found to bear cysts (Fig. 3). The infected sites of the fish skin displayed hyperaemia and oedema (Figs. 1 to 3). The epidermis at some parasitized locations was ruptured and had been shed (Fig. 2).

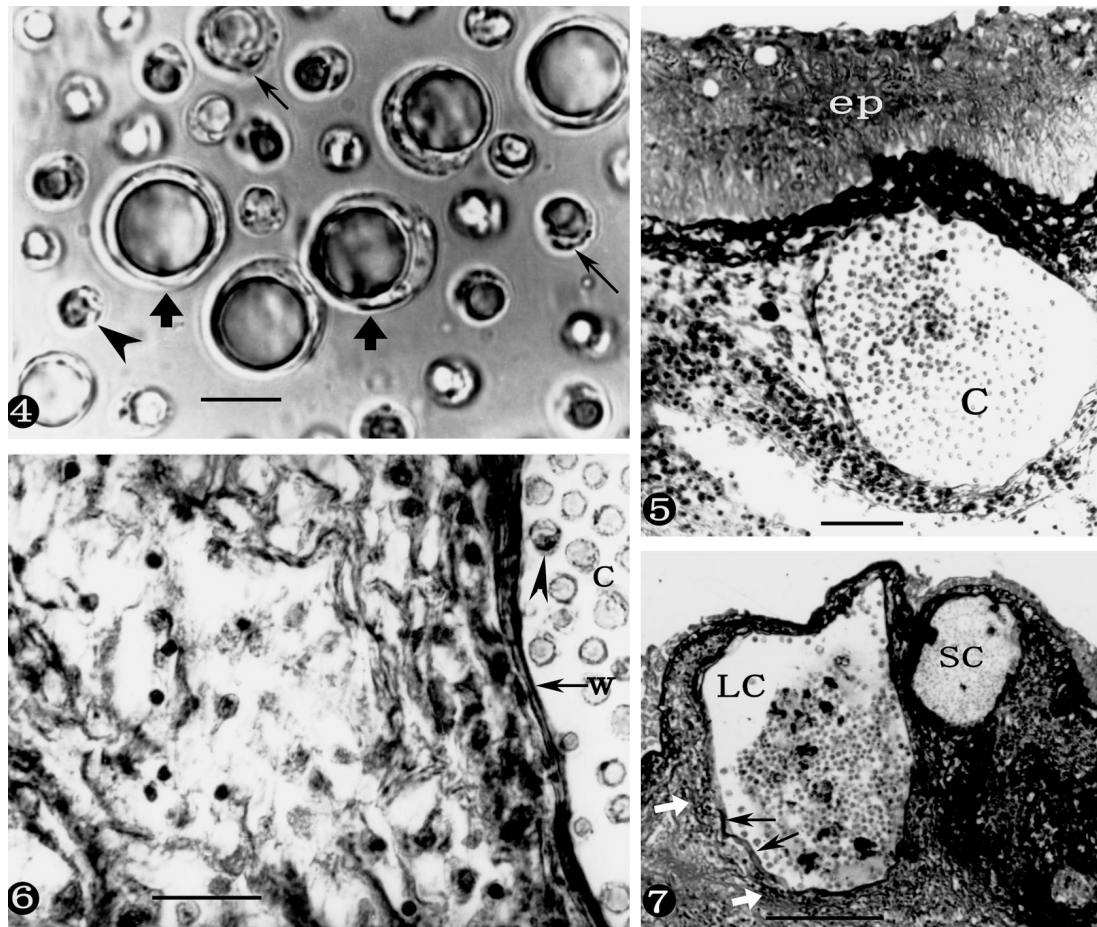
Light microscopy

Wet-mount preparations of fresh or fixed cyst contents of the *Dermocystidium* species revealed a massive number of spherical to oval spores which were ca. 3.2 to 15 μm in diameter, with a refractile body (2.08 to

10.83 μm in diameter) (Fig. 4). The spores were not uniform, and occurred in different sizes even in the same cyst (Fig. 4). Microscopical examination of stained sections of the affected tissues revealed that the cyst wall in the dermis of the fish skin was surrounded by a hyperplastic connective tissue (Figs. 5 & 7), in which inflammatory (predominantly mononuclear) cells were visible in some sections (Fig. 6). This suggested that the cysts provoke a slight inflammatory cell response in the tissue around the cysts. An epidermis layer overlying a cyst was occasionally observed



Figs. 1 to 3. *Dermocystidium* sp. infecting *Silurus meridionalis*. Infected juvenile southern catfish cultured in a net cage in Jialing River, Chongqing, China. Fig. 1. Individual juvenile catfish infected by *Dermocystidium* sp. Note ca. 42 pink or red parasitic sites; cysts of *Dermocystidium* sp. marked with arrows. Scale bar = 1 cm. Fig. 2. Ventral view of the infected catfish. Note the parasitic sites displaying hyperaemia and oedema; ruptured epidermis marked with arrowheads, cysts of the parasite marked with arrows. Scale bar = 1 cm. Fig. 3. Lateral view of the infected partial body; whitish cysts marked with arrows, cysts in the anal fin marked with arrowheads. Scale bar = 1 cm



Figs. 4 to 7. *Dermocystidium* sp. infecting *Silurus meridionalis*. Photomicrographs of both a wet mount preparation of the *Dermocystidium* sp. and H&E-stained sections of infected skin. Fig. 4. Wet mount of *Dermocystidium* sp. parasitizing the juvenile southern catfish; largest spores marked with bold arrows, medium-sized spores marked with thin arrows, smaller spore marked with an arrowhead. Scale bar = 10 μ m. Fig. 5. A parasite cyst (C) within the catfish dermis containing numerous spores. Note the intact epidermis layer (ep) overlaying the cyst. Scale bar = 50 μ m. Fig. 6. Higher magnification of a cyst (c) and tissues around it. Note cyst wall (w), spores (arrowhead) and a slight infiltrate of mixed inflammatory cells to the left of the cyst. Scale bar = 20 μ m. Fig. 7. Photomicrograph of 2-cyst cross section. Note the larger cyst (LC) enclosing larger spores than those in smaller cyst (SC), hyperplastic fibrous connective tissues (bold white arrows) around the cyst wall (thin arrows), and the epidermis layer overlaying the cysts has disappeared. Scale bar = 200 μ m

(Fig. 5), but was often necrotic and had disappeared (Fig. 7). In summary, the catfish skin, especially the epidermis, was often destroyed by cysts.

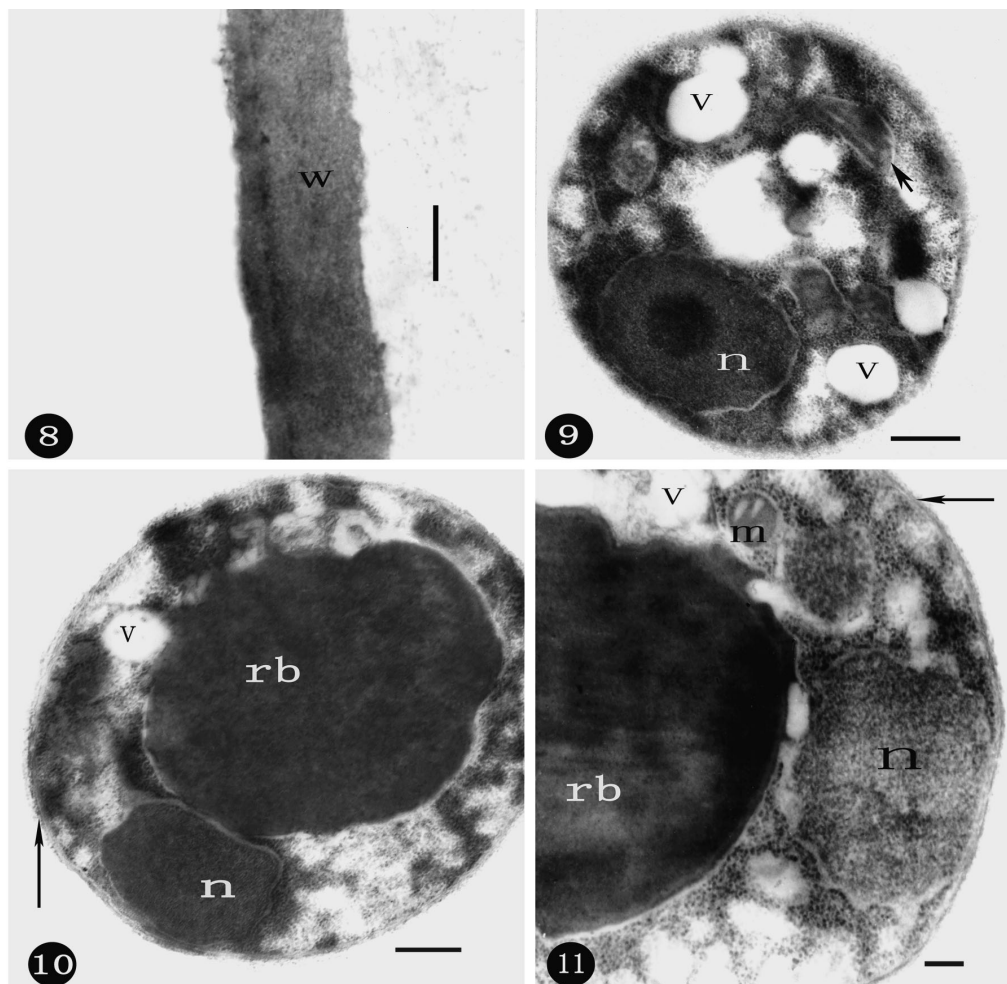
Electron microscopy

Electron microscopy showed that the cyst wall of the *Dermocystidium* species was homogeneously thin and composed of just one layer (Fig. 8), which consisted of an aggregation of amorphous material; neither cellular components or membranes were found.

In spite of the various sizes, the spores possessed very similar structures, such as a thin spore membrane (Figs. 9 to 12), a large refractile body in most spores

(Figs. 10 to 12), a spherical to oval nucleus ($1.1\text{--}1.8 \times 0.5\text{--}1.6 \mu\text{m}$ in diameter) to one side towards the periphery of a spore (Figs. 9 to 12), mitochondria (Figs. 9, 11 & 12), and vacuoles (Figs. 9 to 12).

Several types of spore of different size and structure were observed. The first was small in diameter, and contained a prominent nucleus with a well-defined nucleolus, several vacuoles in various sizes, some mitochondria, and no refractile body (Fig. 9). The second was a medium-sized spore, with a refractile body of medium size, an obvious peripheral nucleus, some vacuoles and mitochondria in cytoplasm (Figs. 10 & 11). The third was a large spore with a large refractile body occupying most of the space of a mature spore, a small nucleus without a nucleolus in the peripheral



Figs. 8 to 11. *Dermocystidium* sp. infecting *Silurus meridionalis*. Transmission electron micrographs of cyst wall, small and medium-sized spores. Fig. 8. Cyst wall (w) consisting of an aggregation of amorphous material. Scale bar = 0.2 μ m. Fig. 9. Small spore with a nucleus (n), mitochondrion (short arrow) and vacuoles (v), but without a refractile body. Scale bar = 0.5 μ m. Fig. 10. Medium-sized spore bearing a nucleus (n), a medium-sized refractile body (rb) and vacuole (v); thin arrow: thin spore membrane. Scale bar = 0.7 μ m. Fig. 11. Partial medium-sized spore with a clear nucleus (n), mitochondrion (m), vacuoles (v) and a partial refractile body (rb); thin arrow: thin spore membrane. Scale bar = 0.2 μ m

cytoplasm, and few other cellular organelles (Fig. 12). All 3 spore types possessed a thin, cellular membrane.

On the ultrastructural level, a deterioration of the residual plasmodium was observed in mature cysts (Fig. 13). The nuclei in the residual plasmodium did not have any role in the formation of spores, and became swollen and progressively vacuolated during the disintegration of the nucleoplasm (Fig. 14). The outer membrane of the remaining nuclei was separated from the inner one, and protruded outwards to form various vesicles (Figs. 14 [insert] & 15). Numerous vesicles with ribosomes were observed in the remnant plasmodium (Fig. 16), and presumably came from the disintegrated nuclei. This sequence probably represents the degenerative process of residual plasmodium, especially the residual nuclei, in a cyst.

DISCUSSION

In the present study we describe spore morphology, histopathology and gross pathological signs of *Dermocystidium* species in the skin of reared juvenile catfish *Silurus meridionalis* Chen. This is, thus far, the first description of *Dermocystidium* species parasitizing catfish belonging to the order Siluriformis.

The most characteristic feature of the parasite described above is a spherical or oval spore with a refractile body and peripheral cytoplasm, which is the diagnostic feature of the genus *Dermocystidium* (Pauley 1967, Lotman et al. 2000). Additionally, the ultrastructures described above, i.e. the mitochondrion, vacuoles and a peripheral nucleus in the spore, are also characteristic of the genus *Dermocystidium*. It

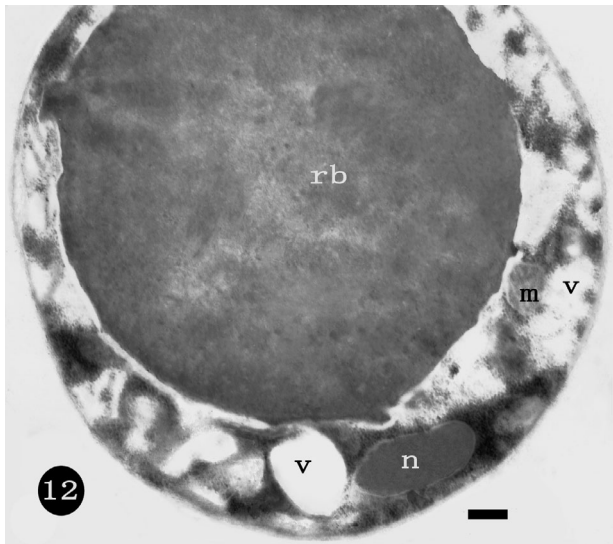
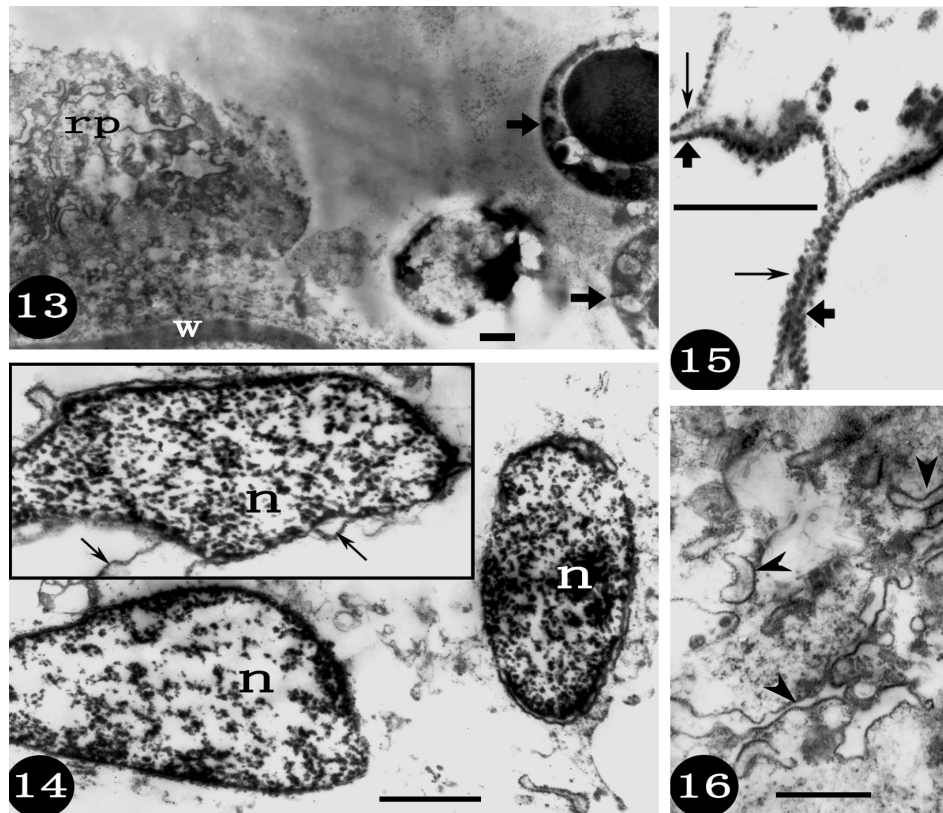


Fig. 12. *Dermocystidium* sp. infecting *Silurus meridionalis*. Transmission electron micrographs of a larger spore. Large refractile body (rb), a small nucleus (n), a mitochondrion (m) and a vacuole (v) are shown. Scale bar = 1.2 μ m

is therefore clear that the parasite in the catfish is definitely in the genus *Dermocystidium*. Moreover, this species resembles *D. koi* Hoshina and Sahara, 1950 and *D. gasterostei* Elkan, 1962 in the following respects (Hoshina & Sahara 1950, Elkan 1962): (1) they were all parasitic in the skin or fins of fish, (2) they all possessed white worm-like or filiform cysts, (3) their hypnospores all had a peripheral nucleus and a large refractile body. However, the dimensions of spores and cysts differed, and the coenocytic cysts in the early developmental stage of the life cycle described for *D. koi* and *D. gasterostei* (Hoshina & Sahara 1950, Elkan 1962, Dykova & Lom 1992, Wildgoose 1995) were not apparent in the species we observed in the catfish. Therefore, its taxonomic name cannot be assigned confidently until further evidence about its life cycle is available, and it can only tentatively be named as *Dermocystidium* sp.

It has been reported that the early stage of the life cycle for some *Dermocystidium* spp. is a multinuclear plasmodium (Elkan 1962, Dykova & Lom 1992, Lotman et al. 2000, Pekkarinen et al. 2003). Although the



Figs. 13 to 16. *Dermocystidium* sp. infecting *Silurus meridionalis*. Transmission electron micrographs of the degenerative residual plasmodium in a mature cyst. Fig. 13. Residual plasmodium (rp) and spores marked with bold arrows in the cyst. w: cyst wall. Scale bar = 1 μ m. Fig. 14. Residual nuclei (n) in the plasmodium. Insert: note the protruded outer membrane (arrows) of the remaining nucleus. Scale bar = 1 μ m. Fig. 15. Higher magnification of a partial residual nucleus. Note the protruded outer membrane (bold arrows) with ribosomes (thin arrows). Scale bar = 0.5 μ m. Fig. 16. Partial residual plasmodium. Note various vesicles (arrowheads) with ribosomes, probably resulting from the disintegration of residual nuclei. Scale bar = 1 μ m

coenocytic plasmodium was not found in *Dermocystidium* sp., remnants of a multinuclear plasmodium were observed in mature cysts with spores, and the nuclei in the residual plasmodium were disintegrating. This suggests that the cyst containing spores probably came from an early coenocytic plasmodium stage.

The refractile body of the spore arose from a vacuole in *Dermocystidium cyprini* (Červinka et al. 1974), and acted as a possible nutrient source in *D. gasterostei* Elkan, 1962, when the spore entered a new host (Elkan 1962). This suggests that the refractile body appeared after the vacuole in the spore. Based on the absence or presence and various sizes of refractile bodies, a hypothesis is proposed to deduce the possible developmental process of the young spores of *Dermocystidium* sp. observed in the catfish, viz.: the first type of spore, with vacuoles and no refractile body, develops into the second type with a small refractile body, and goes into the third type, with a large refractile body.

Dermocystidium sp. was only found from cultured catfish in net cages of Jialing River, and not from catfish in ponds. It only appeared in juvenile catfish from mid-May to June when the water temperature was 18 to 23°C, which was similar to the temperature for the appearance of *D. koi* in carp (Wildgoose 1995). However, at the same range of water temperature from October to mid November in Jialing River, the parasite was not found in the catfish, and they went on to grow into adults (Zhang & Wang unpubl. obs.). This suggests transmission of the parasite from wild catfish or other fishes to reared juvenile catfish in the net cages of the river, and that juvenile catfish were more susceptible to the parasite than adults.

In addition to the infection of the parasite, bacterial plates yielded growth of some bacteria, which were not identified for its taxonomic position, when they were inoculated from the focal lesions caused by the parasite in the skin of the catfish (Zhang & Wang unpubl. obs.). Therefore, both *Dermocystidium* and bacteria concurrently infected the juvenile catfish, and were responsible for about 3 to 5% mortality of the juveniles. Similar observations were made regarding concurrent infections of *Dermocystidium* spp. and bacteria by other authors (Pauley 1967, Höglund et al. 1997), and Pauley (1967) thought that the bacterium was a secondary invader. Höglund et al. (1997) did not determine whether the bacterium was the primary or secondary infectious pathogen. However, the bacteria could be presumed to be secondary invaders in this study, because bacterial infections only occurred in the lesions caused by *Dermocystidium* sp.

Acknowledgements. The authors are indebted to Dr M. Pekkarinen, Department of Biosciences, Division of Animal Physiology, University of Helsinki, Finland, and Dr J. Höglund,

Department of Parasitology, National Veterinary Institute and Swedish University of Agricultural Sciences, for offering their published papers, and are also grateful to Dr G. T. Wang for providing some literature. This work was supported by both the Key Scientific and Technological Project of Chongqing and the Natural Science Foundation of Chongqing.

LITERATURE CITED

- Allen RL, Meekin TK, Pauley GB, Fujihara MP (1968) Mortality among Chinook salmon associated with the fungus *Dermocystidium*. J Fish Res Board Can 25:2467–2475
- Červinka S, Vítovec J, Lom J, Hoška J, Kubů F (1974) Dermocystidiosis—a gill disease of the carp due to *Dermocystidium cyprini* n. sp. J Fish Biol 6:689–699
- Dykova I, Lom J (1992) New evidence of fungal nature of *Dermocystidium koi* Hoshina and Sahara, 1950. J Appl Ichthyol 8:180–185
- Elkan E (1962) *Dermocystidium gasterostei* n. sp., a parasite of *Gasterosteus aculeatus* L. and *Gasterosteus pungitius* L. Nature 196:958–960
- Hedrick RP, Friedman CS, Modin J (1989) Systemic infection in Atlantic salmon *Salmo salar* with a *Dermocystidium*-like species. Dis Aquat Org 7:171–177
- Herr RA, Ajello L, Taylor JW, Arseculeratne SN, Mendoza L (1999) Phylogenetic analysis of *Rhinosporidium seeberi*'s 18s small-subunit ribosomal DNA groups this pathogen among members of the protactistan mesomycetozoa clade. J Clin Microbiol 37:2750–2754
- Höglund J, Alfvorden A, Nikkilä T (1997) Infection of juvenile salmon *Salmo salar* with a *Dermocystidium*-like organism in Sweden. Dis Aquat Org 30:171–176
- Hoshina T, Sahara Y (1950) A new species of the genus *Dermocystidium*, *D. koi* sp. nov., parasitic in *Cyprinus carpio* L. Bull Jpn Soc Sci Fish 15:825–829 (in Japanese with English abstract)
- Lotman K, Pekkarinen M, Kasesalu J (2000) Morphological observations on the life cycle of *Dermocystidium cyprini* Červinka and Lom, 1974, parasitic in carps (*Cyprinus carpio*). Acta Protozool 39:125–134
- Nash G, Southgate P, Richards RH, Sochon E (1989) A systemic protozoal disease of cultured salmonids. J Fish Dis 12:157–173
- Olson RE, Holt RA (1995) The gill pathogen *Dermocystidium salmons* in Oregon salmonids. J Aquat Anim Health 7:111–117
- Pascolini R, Daszak P, Cunningham AA, Tei S, Vagnetti D, Bucci S, Fagotti A, Di Rosa I (2003) Parasitism by *Dermocystidium ranae* in a population of *Rana esculenta* complex in central Italy and description of *Amphibiocystidium* n. gen. Dis Aquat Org 56:65–74
- Pauley GB (1967) Prespawning adult salmon mortality associated with a fungus of the genus *Dermocystidium*. J Fish Res Board Can 24:843–848
- Pekkarinen M, Lom J, Murphy CA, Ragan MA, Dyková I (2003) Phylogenetic position and ultrastructure of two *Dermocystidium* species (Ichthyosporea) from the common perch (*Perca fluviatilis*). Acta Protozool 42:287–307
- Ragan MA, Goggin CL, Cawthorn RJ, Cerenius L and 5 others (1996) A novel clade of protistan parasites near the animal–fungal divergence. Proc Natl Acad Sci USA 93:11907–11912
- Wildgoose WH (1995) *Dermocystidium koi* found in skin lesions in koi carp (*Cyprinus carpio*). Vet Rec 137:317–318
- Xiao C, Chen C (1993) A new species—*Dermocystidium sinensis* sp. nov. from freshwater fishes of China. Trans Res Fish Dis 1:95–97 (in Chinese with English abstract)
- Zhang J, Qiu Z, Ding X (1999) Parasites and parasitic diseases of fishes. Science Press, Beijing, China (in Chinese)

Submitted: February 25, 2004; Accepted: January 28, 2005
Proofs received from author(s): June 24, 2005

Editorial responsibility: Wolfgang Körting,
Hannover, Germany