

Euclinostomum heterostomum infection in guppies *Poecilia reticulata* cultured in southern Thailand

Naraid Suanyuk¹, Suchanya Mankhakhet¹, Hatem Soliman², Mona Saleh²,
Mansour El-Matbouli^{2,*}

¹Kidchakan Supamattaya Aquatic Animal Health Research Center, Department of Aquatic Science,
Faculty of Natural Resources, Prince of Songkla University, Hat Yai, Songkhla 90112, Thailand

²Clinical Division of Fish Medicine, University of Veterinary Medicine, Veterinaerplatz 1, 1210 Vienna, Austria

ABSTRACT: During April to June 2009 and February 2010 to February 2011, numerous digenetic trematode metacercariae were observed embedded in the muscles of guppies *Poecilia reticulata* cultured at Kidchakan Supamattaya Aquatic Animal Health Research Center, Songkhla, southern Thailand. A total of 424 guppies were examined to identify the parasite and to study its pathogenicity. Based on conventional parasitological techniques, the parasitic digenean found in the guppies was identified as *Euclinostomum heterostomum* Rudolphi, 1809. Histological analysis revealed numerous metacercariae embedded in the fish muscle. A life cycle study indicated that the snail *Indoplanorbis exustus* was the first intermediate host, with the guppies serving as the second intermediate host. No *E. heterostomum* metacercariae were found in cohabited fish species, giant sailfin molly *Poecilia velifera* or platy *Xiphophorus maculatus*, which indicated that the guppy was the only suitable fish host present.

KEY WORDS: Trematoda · *Euclinostomum heterostomum* · Guppy · *Poecilia reticulata* · Life cycle · Pathogenicity

Resale or republication not permitted without written consent of the publisher

INTRODUCTION

Guppies *Poecilia reticulata* are small tropical fish, native to coastal streams of northeast South America. They are popular aquarium fish, known for their colorful males and live-bearing females, and are a premier model system for the study of ecology, evolution, genetics and sexual selection (Breden 2006). In Thailand, the guppy is one of the most common ornamental fish farmed commercially, nationwide. However, cultivation of guppies is impacted worldwide by a range of pathogens: bacteria (Pate et al. 2005), viruses (Hedrick & McDowell 1995) and parasites (Kim et al. 2002a,b, Thilakaratne et al. 2003, Leibowitz & Zilberg 2009).

Euclinostomum spp. are parasitic trematodes, subclass Digenea, family Clinostomidae, that have a

wide distribution and are common parasites of piscivorous birds in Europe, Asia, Africa and America (Ukoli 1966, Yamaguti 1971, Jhansilakshmibai & Madhavi 1997, Kannev et al. 2002a). Life cycles have been elucidated for *E. minutus* (Zaidi & Khan 1975), *E. ardeolae* (El-Naffar & Khalifa 1981) and *E. heterostomum* (Dönges 1974, Jhansilakshmibai & Madhavi 1997). For *E. heterostomum* in India and Nigeria, planorbisid snails are the first intermediate host, tilapia and murrel are the second intermediate host, and herons and egrets (family Ardeidae) are the definitive host.

This is the first report of *Euclinostomum heterostomum* infestation in cultured guppies in southern Thailand, including the identification of the first intermediate host, the snail *Indoplanorbis exustus*.

*Corresponding author.
Email: mansour.el-matbouli@vetmeduni.ac.at

MATERIALS AND METHODS

Fish and snails

From April to June 2009 and February 2010 to February 2011, numerous metacercariae were observed embedded in the muscle tissue of guppies cultured in an earthen pond, glass aquaria and a cement tank at Kidchakan Supamattaya Aquatic Animal Health Research Center, Faculty of Natural Resources, Prince of Songkla University, Songkhla province, southern Thailand (Fig. 1). Body weights and macroscopic lesions were recorded for each fish. The metacercarial cysts were counted and then opened to remove the metacercariae for morphometry done under a light microscope. Prevalence and mean intensity of infection and the total number of metacercariae per fish were calculated (Rózsa et al. 2000). The frequency was calculated by grouping the total number of parasites in each infected fish.

To find the primary intermediate host, 48 snails living in the same microhabitats with the infected guppies were collected. The snails were identified, crushed and studied for the presence of rediae and cercariae. Morphometry of rediae and cercariae was done under a light microscope.

Scanning electron microscopy

Metacercariae collected from infected guppies were fixed with 2.5% glutaraldehyde in cacodylate buffer (pH 7.4) at 4°C for 2 h, washed 3 times in buffer (4% NaCl in 0.1 M cacodylate buffer), then post-fixed with 1% OsO₄ in 0.1 M cacodylate buffer



Fig. 1. *Poecilia reticulata*. Guppies showing a high abundance of parasites in the muscle

(pH 7.4). The sample was then dehydrated through a graded ethanol series and dried under a critical point dryer (CPD-Hitachi), then coated with 15 nm gold particles in a Polaron sputter coater. The parasites were viewed with a Jeol scanning electron microscope at 15 kV, and digital images were recorded.

Parasite identification

Parasites were identified based on morphology observed under light and electron microscopy, using keys for the superfamily Clinostomoidea and family Clinostomidae (Kannev et al. 2002a,b) and the descriptions of Fischthal & Kuntz (1963) for *Euclinostomum heterostomum* isolated from fish.

Histopathological study

Nineteen infected fish were fixed in 10% buffered formalin solution and processed using standard histological techniques (Humason 1979). Histological sections were stained with haematoxylin and eosin (H&E) and examined by light microscope for pathological changes in muscle, brain, heart, kidney, liver and spleen.

Susceptibility of other species to parasites

Giant sailfin molly *Poecilia velifera* and platy *Xiphophorus maculatus* cultured in the same environment as the infected guppies for at least 1 yr before the parasitic infection were collected, dissected and examined by light microscopy for the presence of metacercariae in the skin, muscles, liver and intestines.

Fish husbandry and water quality parameters

Fish in glass aquaria and cement tanks were cultured with aeration. No aeration was supplied for fish cultured in an earthen pond. During cultivation, fish were fed with commercial fish feed. Water quality parameters, analyzed by standard methods (Boyd & Tucker 1992, APHA/AWWA/WEF 1998) during sample collection were pH 7.05 to 8.52, 32.5 to 132.5 mg l⁻¹ alkalinity, 6.02 to 7.23 mg l⁻¹ dissolved oxygen and 26 to 32°C temperature.

RESULTS

Clinical signs

Guppies (424) were examined, and metacercariae were observed embedded in the muscles of very small to large fish (0.002 to 1.187 g; Fig. 1). Infected fish exhibited abnormal swimming behavior. Some of the fish died due to severe infection by parasites.

The number of metacercariae varied from 1 to 50 fish⁻¹. The parasite was more abundant in fish reared in the glass aquaria than in the earthen pond and cement tank. Prevalence and abundance data for the different microhabitats are shown in Table 1. The frequency percentage of the grouped total parasitic digenean numbers are shown in Fig. 2.

Metacercariae of *Euclinostomum heterostomum*

Parasite morphology was consistent with the family Clinostomidae, subfamily Euclinostominae: with a uterus mainly anterior to its terminal genitalia and a caecum with numerous lateral branches and diverticulae. From the description by Fischthal & Kuntz (1963) it was deduced that the parasitic digenean in the present study was *E. heterostomum*, possessing a pharynx, and the anterior tip of the uterine sac being relatively close to the acetabulum and lying well anterior of the middle of the postacetabular body length, with no apparent esophagus. Body and organ sizes according to metacercaria size are shown in Table 2. Stage I metacercariae had an oval body with muscular movements, and the gut was prominent and filled with granular material. Oral suckers were located at the anterior end of the body, with the acetabulum in the middle of the body (Fig. 3a). Stage II metacercariae had a black caecum and had commenced development of diverticulae, with rudimentary gonads in the parenchyma (Fig. 3b). Stage III metacercariae had well-developed diverticulae, body size had increased considerably and the testes, ovary and cirrus pouch had become distinct (Fig. 3c).

Scanning electron microscopy of the metacercariae produced slightly smaller dimensions than those from the fresh specimens. The parasites had elongated, broad bodies, rounded at both ends (Fig. 4a,b), with the excretory pore dorsal, subterminal at the posterior end (Fig. 4c). The oral sucker was small and anterior to the cephalic collar (Fig. 4d). The acetabulum was large and located approximately one-third of the body length from the anterior end (Fig. 4d).

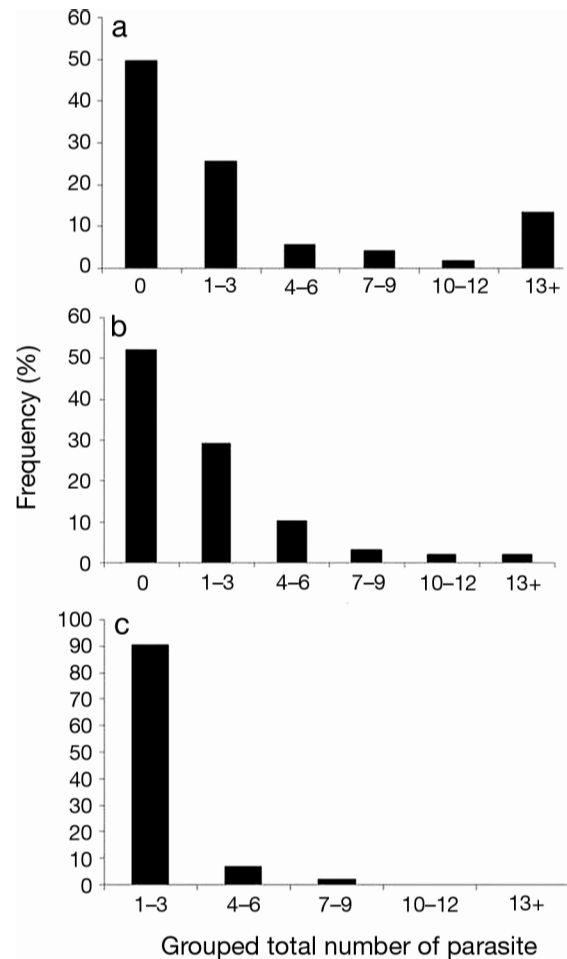


Fig. 2. *Euclinostomum heterostomum* isolated from guppies *Poecilia reticulata*. Percentage frequency of grouped total parasite numbers in guppies cultured in (a) glass aquaria, (b) a cement tank and (c) an earthen pond

Table 1. *Euclinostomum heterostomum*. Incidence of *E. heterostomum* metacercariae in guppies *Poecilia reticulata*

Holding method	n	Fish weight (g)		Parasite prevalence (%)	Metacercarial abundance	
		Mean ± SD	Range		Mean ± SD	Range
Earthen pond	42	–	–	–	1.86 ± 1.37	1–7
Glass aquaria	173	0.13 ± 0.19	0.004–1.187	50.29	8.14 ± 10.18	1–50
Cement tank	209	0.07 ± 0.10	0.002–0.61	47.85	4.00 ± 4.04	1–24

Table 2. *Euclinostomum heterostomum*. Body and organ sizes of *E. heterostomum* metacercariae in guppy *Poecilia reticulata* muscle. l: length; w: width. Data given are means (\pm SD)

Organ	Metacercaria size (μm)		
	Stage I (n = 7)	Stage II (n = 11)	Stage III (n = 46)
Body (l)	277.2 \pm 80.91	2238.02 \pm 736.80	4715.45 \pm 1248.99
Body (w)	249.15 \pm 65.49	857.69 \pm 289.19	1981.82 \pm 276.57
Acetabulum (l)	128.7 \pm 49.00	506.70 \pm 160.30	945.10 \pm 111.94
Acetabulum (w)	110.88 \pm 33.13	481.50 \pm 152.10	919.94 \pm 114.17
Oral sucker (l)		216.0 \pm 70.54	472.95 \pm 137.53
Oral sucker (w)		119.70 \pm 42.34	271.33 \pm 83.89
Anterior testis (l)		221.10 \pm 91.99	555.68 \pm 132.05
Anterior testis (w)		125.40 \pm 40.01	198.98 \pm 48.90
Posterior testis (l)		145.75 \pm 59.56	392.12 \pm 103.89
Posterior testis (w)		102.38 \pm 50.25	251.25 \pm 68.82
Ovary (l)			172.70 \pm 42.24
Ovary (w)			150.90 \pm 43.76
Cirrus pouch (l)			239.08 \pm 59.78
Cirrus pouch (w)			181.46 \pm 54.76

Rediae and cercariae of *Euclinostomum heterostomum*

Snails (n = 48) were collected sympatric with infected guppies and identified as *Filopaludina martensi martensi* (n = 7), *Indoplanorbis exustus* (n = 31) and *Radix rubiginosa* (n = 10). Light microscopy revealed 2/31 (6.45%) *I. exustus* with rediae and cercariae embedded in their tissue. Rediae were elongated, 129 (86.67 to 220.00) \times 535 (346.67 to 740.00) μm , and transparent, with a pharynx and a long gut filled with brownish material. The body cavity was filled with germ-balls and cercariae at various stages of development.

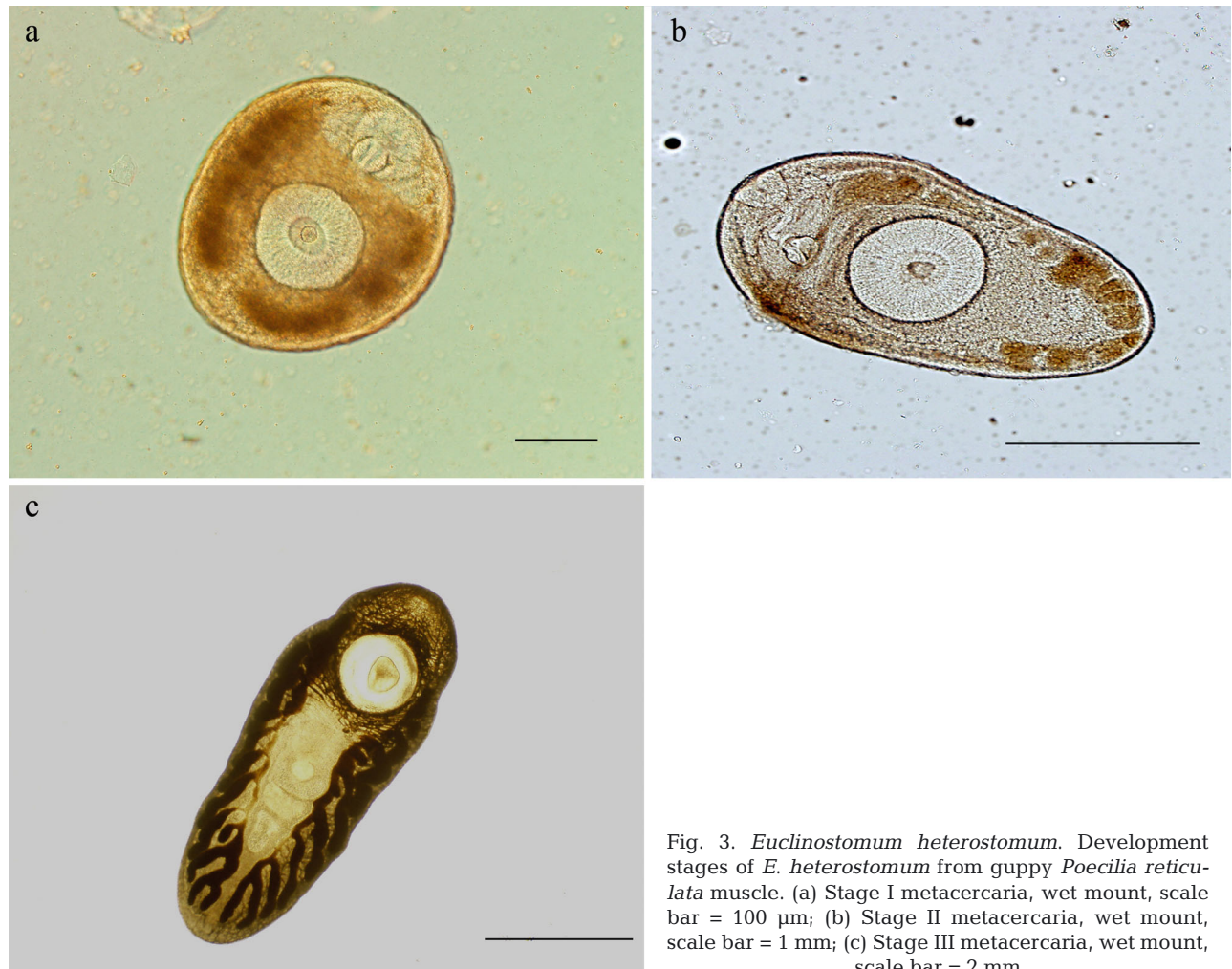


Fig. 3. *Euclinostomum heterostomum*. Development stages of *E. heterostomum* from guppy *Poecilia reticulata* muscle. (a) Stage I metacercaria, wet mount, scale bar = 100 μm ; (b) Stage II metacercaria, wet mount, scale bar = 1 mm; (c) Stage III metacercaria, wet mount, scale bar = 2 mm

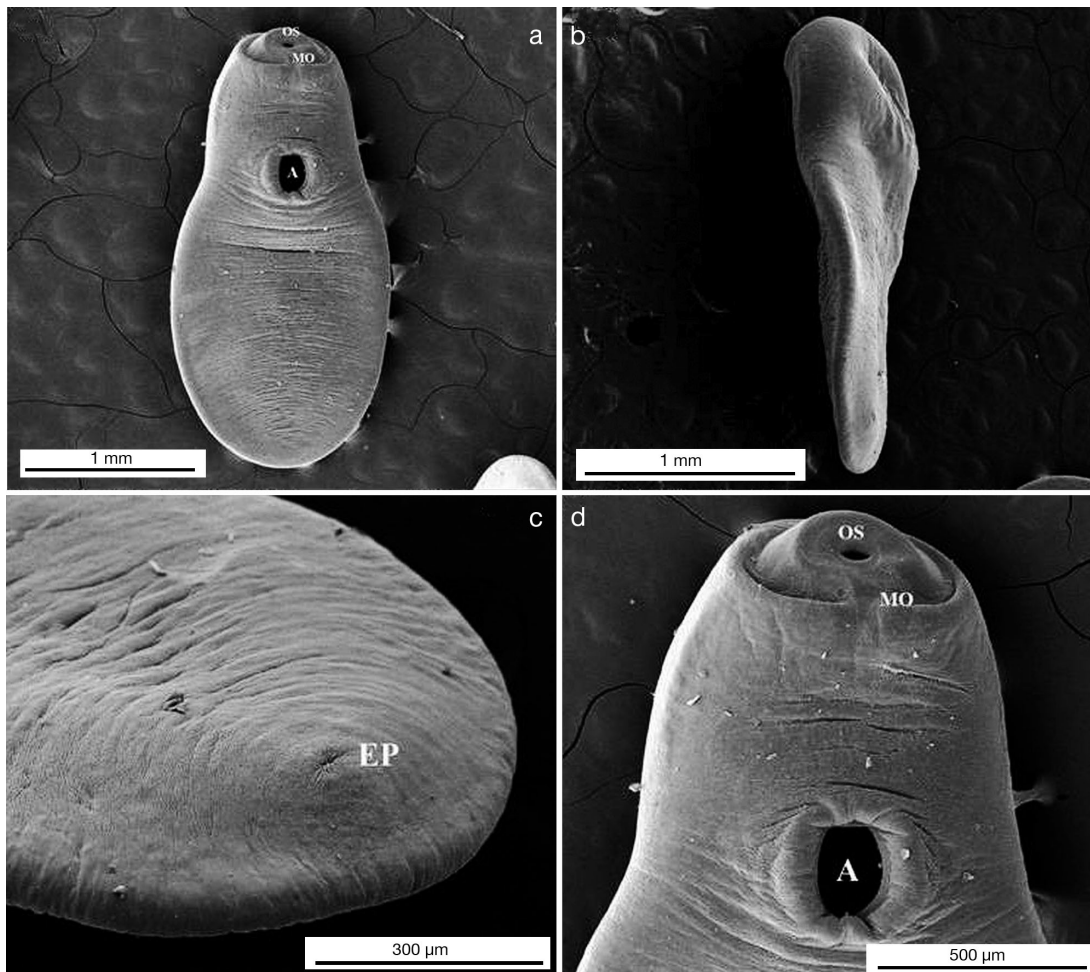


Fig. 4. *Euclinostomum heterostomum*. Scanning electron micrographs of an *E. heterostomum* metacercaria from guppy *Poecilia reticulata* muscle, showing (a,b) a broad elongated body, (a,d) a large acetabulum approximately one-third the body length from the anterior end and (c) an excretory pore, dorsally subterminal at the posterior end. OS: oral sucker; MO: mouth; A: acetabulum; EP: excretory pore

Cercariae were brevifurcate, furco-lophocercous and oculate, with a small body of 39.66 (25.00 to 56.25) \times 132.97 (100.00 to 165.00) μm , with a pair of eye-spots on either side of the esophagus, and a slender tail of 26.27 (13.33 to 45.00) \times 229.00 (166.67 to 318.75) μm . Furcae were highly motile, long and slender, 14.69 (6.67 to 20.00) \times 83.02 (53.33 to 126.67) μm . No rediae or cercariae were found in *Filopaludina martensi martensi* or *Radix rubiginosa*.

Histopathological study

Infected guppies demonstrated numerous *Euclinostomum heterostomum* metacercariae embedded in muscle tissue only (Figs. 5 & 6). Parasites were surrounded by connective tissue. The brain had granu-

lomas and lymphocytic infiltrates, and the kidneys had lymphocytic infiltrates.

Susceptibility of other fish species

Only guppies were found to harbor metacercariae of *Euclinostomum heterostomum*. No parasitic digeneans were found in giant sailfin molly or platy cohabited with the guppies.

DISCUSSION

Parasitic digeneans of the family Clinostomidae are widely distributed, with trematode flukes of the genus *Euclinostomum* found as common parasites of

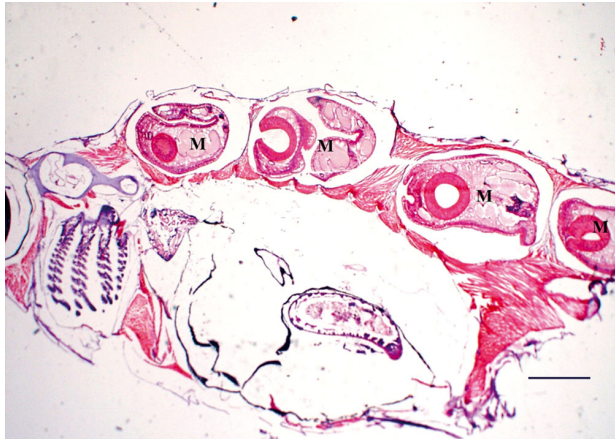


Fig. 5. *Poecilia reticulata*. Numerous *E. heterostomum* metacercariae (M) embedded in muscle. H&E, scale bar = 2 mm

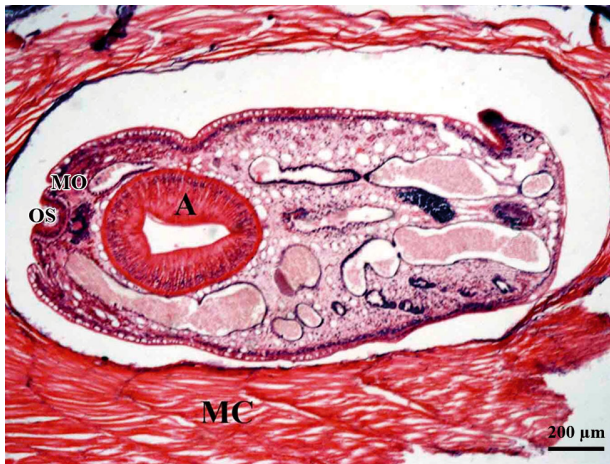


Fig. 6. *Poecilia reticulata*. Stage II metacercaria of *E. heterostomum* embedded in the muscle and surrounded by connective tissue. A: acetabulum; MC: muscle; OS: oral sucker; MO: mouth. H&E, scale bar = 200 μm

piscivorous birds in many regions of Europe, Asia, Africa and America. Herein we report, for the first time, infection by a clinostomid digenean in guppies cultured in southern Thailand and describe the parasite life cycle and metacercarial development.

Using conventional parasitological analysis, we identified the parasite as a member of the family Clinostomidae, subfamily Euclinostominae, and classified it as *Euclinostomum heterostomum*. Observed metacercarial growth within the fish host indicated that Stage I, II and III *E. heterostomum* metacercariae in guppy muscle from the present study are closely related to those isolated from *Channa punctatus* at 10, 30 and 55 d (Jhansilakshmibai & Madhavi 1997). Our observations indicated that this parasite is able to remain in fish muscle for at least 1 yr.

We determined that the snail *Indoplanorbis exustus* was the first intermediate host, with the guppy as the second intermediate host. Although the complete life cycle was not observed in this study because of practical, legal and ethical issues regarding avian research, pond herons *Ardeola bacchus* were observed seasonally around the facility, between November and April, and may serve as the final host of *Euclinostomum heterostomum*.

The prevalence of metacercariae in guppies was higher than in other clinostomid infections (e.g. Boane et al. 2008, Echi et al. 2009). We suspect that this is because the guppies were cultured at high density in a closed system which allowed fish to be easily infected by cercariae. Rediae and cercariae of *Euclinostomum heterostomum* from the snail *Indoplanorbis exustus* and metacercariae from guppies were morphologically similar to those observed by Jhansilakshmibai & Madhavi (1997), who reported metacercariae in *Channa punctatus*, adults in piscivorous birds (*Ardeola grayii*, *Bubulcus ibis*) and rediae and cercariae in the snails *I. exustus*.

Metacercariae may affect the growth and survival of fish, or may disfigure fish so that they lose their market value as either food or an ornamental product (Paperina 1991). In the present study, histopathological analysis revealed histozoic parasite stages embedded in fish muscle, while no parasites were observed in other fish tissues. Infection of guppies by metacercariae of *Euclinostomum heterostomum* may decrease fish immunity, allowing secondary infections by other pathogens.

Euclinostomum heterostomum infections have been reported in a variety of fish species, including tilapia (Dönges 1974, Britz et al. 1985, Olurin & Somorin 2006) and murrels (Jhansilakshmibai & Madhavi 1997). In this study, no metacercariae of *E. heterostomum* were found in other ornamental fish species cultured in the same microhabitat as the guppies, which suggested that the guppy was the only susceptible fish host present.

Strategies for the prevention and control of parasitic digenean infections in fish are limited, since infected fish cannot be treated and the parasite stages remain resident in fish for months or years. Control of the other hosts, snails and piscivorous birds, may be the best way to prevent this parasitic infection in fish.

In conclusion, parasitic digeneans have a wide geographical distribution. *Euclinostomum heterostomum* should be regarded as a threat to aquaculture systems globally through international trade in aquarium fish, food fish and fish products, where quarantine systems may not yet be fully established or compliant with international best practice.

Acknowledgements. This work was supported by the Higher Education Research Promotion and National Research University Project of Thailand, Office of the Higher Education Commission. The authors thank the ornamental fish group, Department of Aquatic Science, Faculty of Natural Resources, Prince of Songkla University, for providing infected samples; and Michael Currie (Prince of Songkla University) and Stephen Atkinson (Oregon State University) for editing the manuscript.

LITERATURE CITED

- APHA/AWWA/WEF (American Public Health Association/American Water Works Association/Water Environment Federation) (1998) Standard methods for the examination of water and wastewater. APHA/AWWA/WEF, Washington, DC
- Boane C, Cruz C, Saraiva A (2008) Metazoan parasites of *Cyprinus carpio* L. (Cyprinidae) from Mozambique. *Aquaculture* 284:59–61
- Boyd CE, Tucker CS (1992) Water quality and pond soil analyses for aquaculture. Alabama Agricultural Experiment Station, Auburn University, AL
- Breden F (2006) Guppies. *Curr Biol* 16:R865–R866
- Britz J, Van As JG, Saayman JE (1985) Occurrence and distribution of *Clinostomum tilapiae* Ukoli, 1966 and *Euclinostomum heterostomum* (Rudolphi, 1809) metacercarial infections of freshwater fish in Venda and Lebowa, southern Africa. *J Fish Biol* 26:21–28
- Dönges J (1974) The life cycle of *Euclinostomum heterostomum* (Rudolphi, 1809) (Trematoda: Clinostomatidae). *Int J Parasitol* 4:79–90
- Echi PC, Eyo JE, Okafor FC (2009) Co-parasitism and morphometrics of three clinostomatids (Digenea: Clinostomatidae) in *Sarotherodon melanotheron* from a tropical freshwater lake. *Anim Res Int* 6:982–986
- El-Naffar MK, Khalifa RM (1981) *Euclinostomum ardeolae* sp. nov. (Trematoda: Clinostomatidae). *J Egypt Soc Parasitol* 11:175–181
- Fischthal JH, Kuntz RE (1963) Trematode parasites of fishes from Egypt, Part VI. The metacercaria of *Euclinostomum heterostomum* (Rudolphi, 1809) Travassos, 1928 (Clinostomidae), with a review of the genus. *Trans Am Microsc Soc* 82:335–342
- Hedrick RP, McDowell TS (1995) Properties of iridoviruses from ornamental fish. *Vet Res* 26:423–427
- Humason GL (1979) Animal tissue techniques. WH Freeman and Company, San Francisco, CA
- Jhansilakshmbai K, Madhavi R (1997) *Euclinostomum heterostomum* (Rudolphi, 1809) (Trematoda): life-cycle, growth and development of the metacercaria and adult. *Syst Parasitol* 38:51–64
- Kannev I, Radev V, Fried B (2002a) Family Clinostomidae Lühe, 1901. In: Gibson DI, Jones A, Bray RA (eds) Keys to the trematoda, Vol 1. CAB International and the Natural History Museum, London, p 111–112
- Kannev I, Radev V, Fried B (2002b) Superfamily Clinostomoidea Lühe, 1901. In: Gibson DI, Jones A, Bray RA (eds) Keys to the trematoda, Vol 1. CAB International and the Natural History Museum, London, p 113–120
- Kim JH, Hayward CJ, Heo GJ (2002a) Nematode worm infections (*Camallanus cotti*, Camallanidae) in guppies (*Poecilia reticulata*) imported to Korea. *Aquaculture* 205:231–235
- Kim JH, Hayward CJ, Joh SJ, Heo GJ (2002b) Parasitic infections in live freshwater tropical fishes imported to Korea. *Dis Aquat Org* 52:169–173
- Leibowitz MP, Zilberg D (2009) *Tetrahymena* sp. infection in guppies, *Poecilia reticulata* Peters: parasite characterization and pathology of infected fish. *J Fish Dis* 32:845–855
- Olurin KB, Somorin CA (2006) Intestinal helminths of the fishes of Owa stream, South-West Nigeria. *Res J Fish Hydrobiol* 1:6–9
- Paperna I (1991) Diseases caused by parasites in the aquaculture of warm water fish. *Annu Rev Fish Dis* 1:155–194
- Pate M, Jenčič V, Žolnir-Dovč M, Očepk M (2005) Detection of mycobacteria in aquarium fish in Slovenia by culture and molecular methods. *Dis Aquat Org* 64:29–35
- Rózsa L, Reiczigel J, Majoros G (2000) Quantifying parasites in samples of hosts. *J Parasitol* 86:228–232
- Thilakarathne IDSIP, Rajapaksha G, Hewakopara A, Rajapakse RPVJ, Faizal ACM (2003) Parasitic infections in freshwater ornamental fish in Sri Lanka. *Dis Aquat Org* 54:157–162
- Ukoli FMA (1966) On *Euclinostomum heterostomum* (Rudolphi, 1809). *J Helminthol* 40:227–234
- Yamaguti S (1971) Synopsis of digenetic trematodes of vertebrates, Vol 1. Keigaku Publishing Company, Tokyo
- Zaidi DA, Khan D (1975) Life history of *Euclinostomum minutus* Bhutta and Khan 1975 (Digenea: Euclinostomidae). *Pak J Zool* 7:161–176

Editorial responsibility: Dieter Steinhagen, Hannover, Germany

*Submitted: October 4, 2012; Accepted: March 6, 2013
Proofs received from author(s): May 17, 2013*