



## Case Report

# Cardiac tamponade caused by tuberculous pericarditis: A case report

Ali M. Assiri<sup>1</sup>, Tariq A. Al Azraqi<sup>2</sup>, A. Rauoof Malik<sup>3</sup>, Hamdan M. Al-shehri<sup>4</sup>

<sup>1</sup>Demonstrator, Internal Medicine Department, Aseer Central Hospital, Najran University, Saudi Arabia

<sup>2</sup>Associate Professor, Internal Medicine Department, Aseer Central Hospital, King Khalid University, Saudi Arabia

<sup>3</sup>Associate Professor, Internal Medicine Department, Aseer Central Hospital, King Khalid University, Saudi Arabia

<sup>4</sup>Demonstrator, Internal Medicine Department, Aseer Central Hospital, Najran University, Saudi Arabia

\*Corresponding Authors E-mail: [Ali-8505@hotmail.com](mailto:Ali-8505@hotmail.com)

## Abstract

Pericarditis is a rare but potentially serious complication of tuberculosis. The clinical features of Tuberculous pericarditis are often subtle and nonspecific, leading to delayed or missed diagnosis. As a result, patients of Tuberculous pericarditis often present with late complications and have increased mortality. We present a 51-year-old male who was admitted to our hospital for pericardial effusion investigation which was found to be of tuberculosis etiology based on polymerase chain reaction and pericardial effusion culture. Clinicians should keep in mind tuberculosis as an important cause of pericardial effusion, as it may reflect increasing tuberculosis endemic and to consider using polymerase chain reaction to aid in reaching the diagnosis.

**Keywords:** Cardiac tamponade, Polymerase chain reaction, Tuberculous pericarditis.

## Abbreviations

Acid fast bacilli (AFB).  
Computed tomography (CT).  
Chest x-ray (CXR).  
Electrocardiogram (ECG).  
Enzyme linked immunosorbent assay (ELISA).  
Juglar venous pulsation(JVP).  
Polymerase chain reaction (PCR).  
Tuberculosis(TB).

## INTRODUCTION

The normal pericardium is a fibroelastic sac surrounding the heart that contains a thin layer of fluid. A pericardial effusion is considered to be present when accumulated fluid within the sac exceeds the small amount that is normally present. Pericardial effusion

can develop in patients with virtually any condition that affects the pericardium, including acute pericarditis and a variety of systemic disorders. TB is responsible for 1% (Ben Horin et al., 2006) to 5% (Imazio et al., 2010) of the reported cases. The symptoms of tuberculous pericarditis can be nonspecific; fever, weight loss and nocturnal hyperhidrosis which generally precede cardiopulmonary complaints, resulting in missed diagnosis or presenting late after succumbing complications such as constrictive pericarditis. Tuberculous pericarditis should always be considered in the evaluation of patients with pericarditis who do not have a self-limited course in the setting of risk factors for tuberculosis (TB) exposure (Permanyer-Miralda et al.,1985) and increasing AIDS prevalence globally. The diagnosis is established by detecting of tubercle bacilli in smear or culture of pericardial fluid, and/or detection of tubercle bacilli or caseating granulomas in the pericardial tissue biopsy (Mayosi et al., 2005).

## Case report

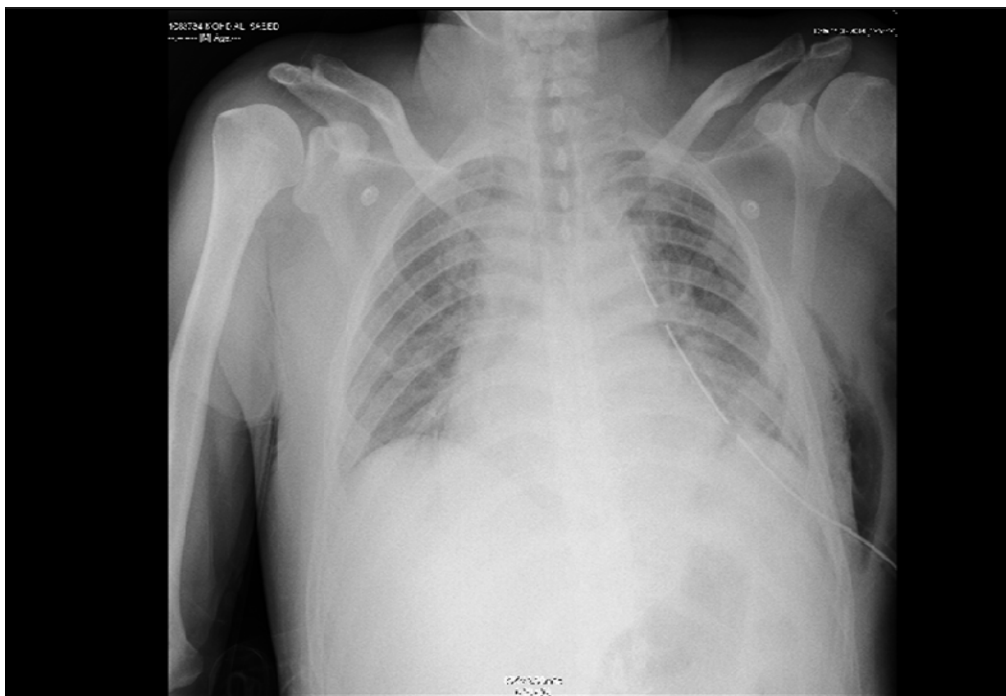
A 51-year-old man, presented to the hospital with two months history of un-intentional weight loss, anorexia, fever and sweating. The patient complained of pleuritic chest pain, progressive dyspnea and dry cough. There was no orthopnea or paroxysmal nocturnal dyspnea, foamy urine or face puffiness. On examination, patient was febrile (38 °C) with sinus tachycardia and muffled heart sounds, left basal rales, raised jugular venous pulsation(JVP) and lower limb pitting oedema. Electrocardiography (ECG) showed sinus tachycardia with V1-V4 T wave inversion. Chest x-ray and computed tomography(CT scan) (Figure 1,2) showed pericardial effusion with left sided pleural effusion. Echocardiography (Figure 3) revealed 2.2 cm pericardial effusion with thickened pericardium and signs of right ventricle collapse suggestive of tamponade. Cardiothoracic surgeon was consulted for the case. Pleural and pericardial windows were created and samples of the pericardial fluid were sent for Ziel-Neelsen staining to detect acid fast bacilli(AFB), PCR and culture. Results did not show acid-fast bacilli in neither sputum nor pericardial fluid. Pericardial tissue biopsy(Figure 4) showed chronic lymphocytic infiltrate and focal necrosis without clear caseating granuloma. PCR (Figure 5) was positive for Mycobacterium tuberculosis. HIV 1&2 testing by enzyme linked immunosorbent assay(ELISA) was negative, the patient eventually was started on anti-tuberculous chemotherapy, (rifampin, isoniazid, pyrazinamide and ethambutol with pyridoxine) and glucocorticoids. Pericardial fluid culture later on revealed Mycobacterium tuberculosis, Fever subsided and drains were removed. He was discharged after 14 days to be followed in outpatient clinic.

## DISCUSSION

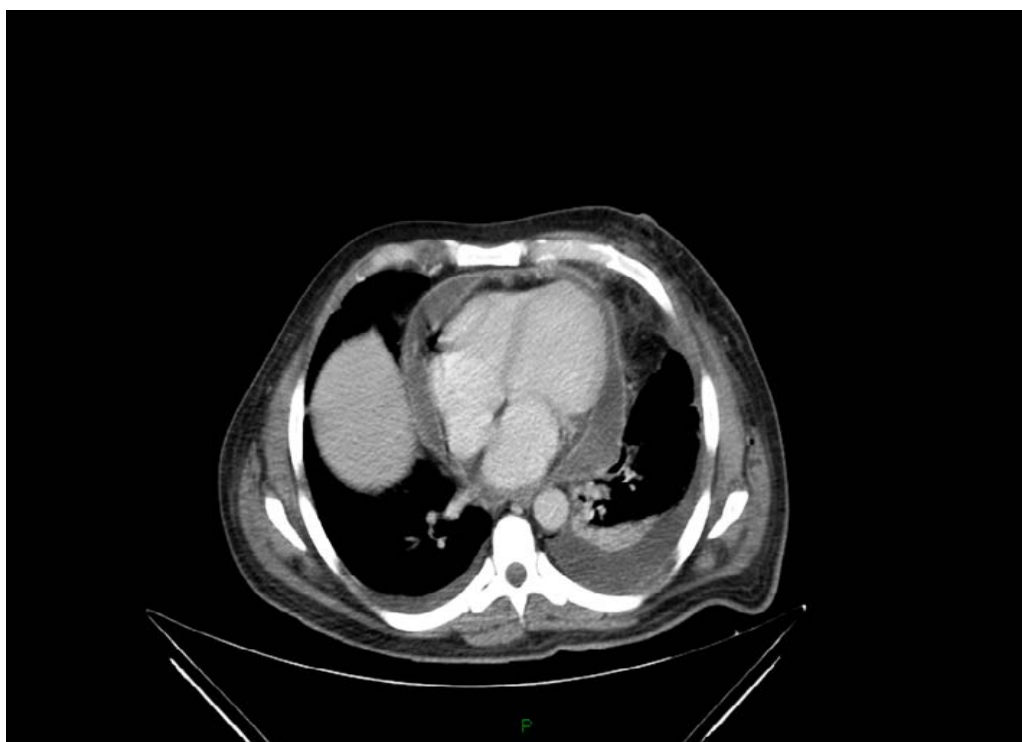The diagnostic work-up of acute pericarditis should take into account the local epidemiology in developing countries, Tuberculous pericarditis accounts for at least 5% of pericarditis cases (Imazio et al., 2010). The yield of pericardial fluid and tissue for acid-fast smear and culture is generally highest in the effusive stage (Strang et al., 1991) (Barr,1955). In the absence of treatment, Resorption of the effusion with resolution of symptoms occurs over two to four weeks in approximately 50% of cases (Barr,1955). Subsequently, constriction may or may not occur. Antituberculous therapy has been shown to reduce both the mortality among patients with Tuberculous pericarditis by 90 % (Harvey and Whitehill, 1937) and constrictive pericarditis from 88 % down to 10 % of treated cases (Gooi and

and Smith, 1978) (Long et al., 1989). The benefit of glucocorticoids in tuberculous pericarditis still controversial. The 2003 guidelines issued by the American Thoracic Society, Centers for Disease Control and Infectious Diseases Society of America recommended corticosteroids for treatment of all patients with Tuberculous pericarditis. However, Mayosi et al. recently published a paper (Mayosi et al., 2014) revealed no significant effect on composite of death, tamponade or constrictive pericarditis. There is no consensus in the literature regarding the clinical use of PCR to diagnose Tuberculous pericarditis due to its false +ve results. Cegielski JP. (Cegielski et al., 1997) compared PCR to culture and histopathology for the diagnosis of tuberculous pericarditis in 36 specimens of pericardial fluid and 19 specimens of pericardial tissue from 20 patients. The study found overall accuracy of PCR approaching the results of conventional methods, nevertheless PCR was much faster. (Tzoanopoulos et al., 2001) reported a 63-year-old woman with Tuberculous pericarditis diagnosed by using a nested PCR. The patient had an excellent response to a three-drug combination anti-tuberculous regimen and 1 year later was asymptomatic without any evidence of constrictive pericarditis. (Rana et al.,1999) reported a 23-year-old man presented with progressive dyspnoea was found to have a massive pericardial effusion. Despite extensive investigations the cause remained elusive, until samples were sent for Mycobacterium tuberculosis PCR. The World Health Organization (WHO) endorsed the Xpert MTB/RIF PCR for use in TB endemic countries and declared it a major milestone for global TB diagnosis. This followed 18 months of rigorous assessment of its field effectiveness in TB (Small and Pai, 2010). A review to assess the diagnostic accuracy of Xpert TB found that when used as an initial test to replace smear microscopy it had pooled sensitivity of 88% and specificity of 98%. However when Xpert TB was used as an add-on for cases of negative smear microscopy the sensitivity was only 67% and specificity 98% (Steingart et al., 2013). In a clinical study conducted the sensitivity of the MTB/RIF test on just 1 sputum sample was 92.2% for culture-positive TB; 98.2% for smear- and culture-positive cases; and 72.5% for smear-negative, culture-positive cases, with a specificity of 99.2%. Sensitivity and higher specificity were slightly higher when 3 samples were tested (Boehme et al., 2010).

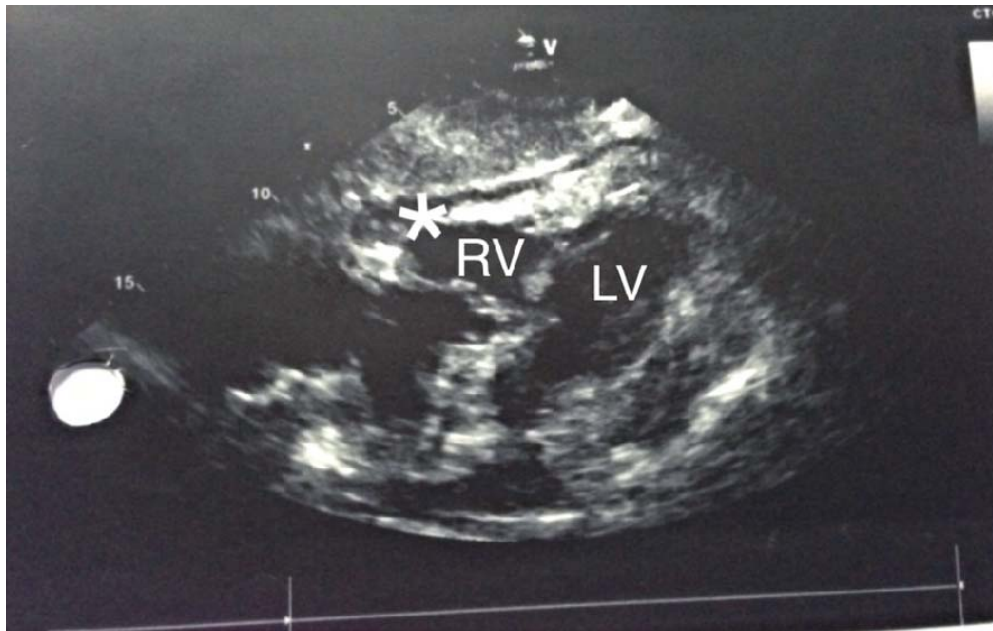
As we experienced with our patient, PCR was a valuable test that helped in reaching the diagnosis, especially when invasive biopsy was disappointing. Meriting the use of PCR after balancing the cost with the devastating consequences of the constrictive



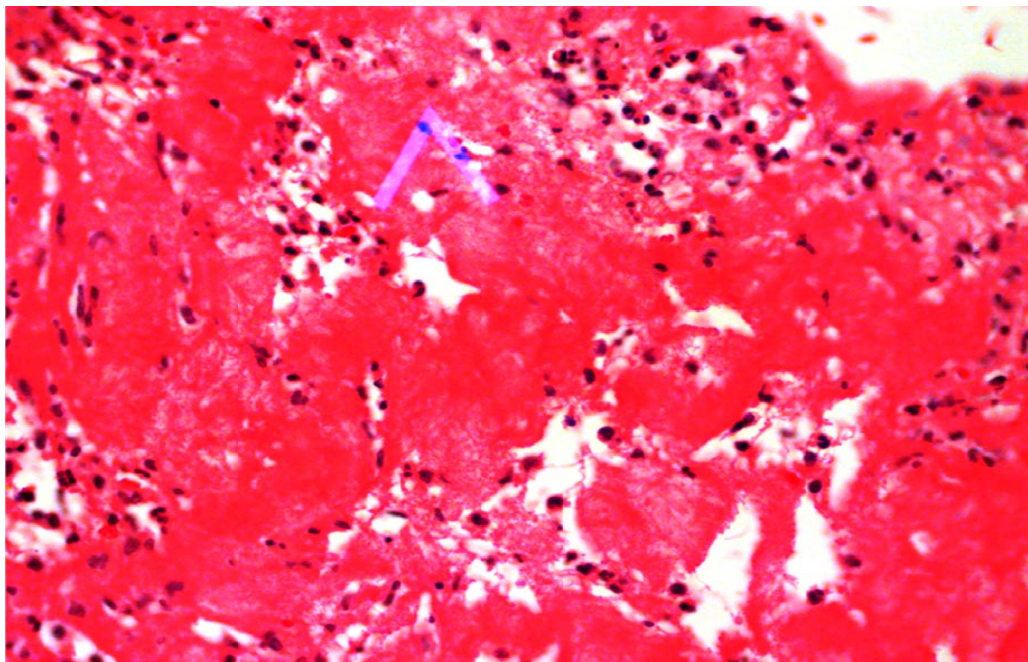
**Figure 1.** Chest radiograph showing flask-shaped heart indicating pericardial effusion.



**Figure 2.** CT scan showing pericardial and pleural effusion with calcified pericardium.



**Figure 3.** Short-axis modified view on two-dimensional echocardiography, revealing pericardial effusion as 2.2 cm echo-free space with thickened pericardium (asterix) and right ventricle collapse.



**Figure 4.** Biopsy revealed fibrocollagenous tissue covered by fibrino-purulent exudates (arrow head) composed of fibrin and predominant chronic lymphocytic infiltrate and focal areas of necrosis.



Test Type:	Specimen			
Sample Type:	Pericardil			
<b>Assay Information</b>		Assay Version	Assay Type	
Assay	Xpert MTB-RIF Assay G4	5	In Vitro Diagnostic	
<b>Test Result:</b> MTB DETECTED MEDIUM; Rif Resistance NOT DETECTED				
<b>Test and Analyte Result</b>				
Analyte Name	Ct	EndPt	Analyte Result	Probe Check Result
Probe D	23.4	221.0	POS	PASS
Probe C	22.2	236.0	POS	PASS
Probe E	23.4	137.0	POS	PASS
Probe B	23.9	128.0	POS	PASS
SPC	26.4	291.0	NA	PASS
Probe A	21.7	153.0	POS	PASS
QC-1	0.0	0.0	NEG	PASS
QC-2	0.0	0.0	NEG	PASS
User:	<None>	Start Time:	26/02/14 21:16:59	
Status:	Done	End Time:	26/02/14 23:01:08	
Expiration Date*:	06/07/14	Instrument S/N:	710296	
S/W Version:	4.4a	Module S/N:	630392	
Cartridge S/N*:	210489042	Module Name:	A2	
Reagent Lot ID*:	12501			
Notes:	TB LAB NO-217			

**Figure 5.** Polymerase chain reaction test analysis which was positive for *Mycobacterium tuberculosis*.

pericarditis and subsequently pericardiectomy (Long et al., 1989) which can be prevented by starting anti-tuberculous treatment early in the clinical course.

## REFERENCES

- Barr JF (1955). The use of pericardial biopsy in establishing etiologic diagnosis in acute pericarditis. *AMA Arch Intern Med.* Nov;96(5):693-6.
- Ben-Horin S, Bank I, Guetta V, Livneh A (2006). Large symptomatic pericardial effusion as the presentation of unrecognized cancer: a study in 173 consecutive patients undergoing pericardiocentesis. *Medicine (Baltimore).*85(1):49.
- Boehme CC, Nabeta P, Hillemann D, names Nicol MP, Shenai S, Krapp F, Allen J, Tahirli, R, Blakemore R, Rustomjee R, Milovic A, Jones M, O'Brien SM, Persing DH, Ruesch-Gerdes S, Gotuzzo E, Rodrigues C, Alland D, Perkins MD, (2010). Rapid molecular detection of tuberculosis and rifampin resistance. *Nm. Engl. J. Med.* 363:1005-1015.
- Cegielski JP, Devlin BH, Morris AJ, Kitinya JN, Pulipaka UP, Lema LE, wakatare JL, Reller LB (1997). Comparison PCR, culture and histopatholgy for the diagnosis of tuberculous pericarditis. *J. Clin. Microbiol. Dec;* 35(12): 3254–3257.
- Gooi HC, Smith JM (1978). Tuberculous pericarditis in Birmingham. *Thorax.*;33(1):94.
- Harvey AM, Whitehill MR (1937). Tuberculous pericarditis. *Medicine*;16:45-94.
- Long R, Younes M, Patton N, Hershfield E (1989). Tuberculous pericarditis: long term outcome in patients who received medical therapy alone. *Am Heart J.*117(5):1133.
- Massimo I, Spodick DH, Brucato A, Trincherio R, Adler Y (2010). Controversial Issues in the Management of Pericardial Diseases. *Circulation*;121:916-928.
- Mayosi BM, Burgess LJ, Doubell AF (2005). Tuberculous pericarditis. *Circulation.* Dec;112(23):3608-16.
- Mayosi BM, Ntsekhe M, Bosch J, Pandie S, Jung H, Gumedze F, Pogue J, Thabane L, Smieja M, Francis V, Joldersma L, Thomas KM, Thomas B, Awotedu AA, Magula NP, Naidoo DP, Damasceno A, Banda AC, Brown B, Manga P, Kirenga B, Mondo C, Mntla P, Tsitsi JM, Peters F, Essop MR, Russell JB, Hakim J, Matenga J, Barasa AF, Sani MU, Olunuga T, Ogah O, Ansa V, Aje A, Danbauchi S, Ojji D, Yusuf S, (2014). Prednisolone and mycobacterium indicus pranii in tuberculous pericarditis. *N. Engl. J. Med.* 371:1121-1130.
- Permanyer-Miralda G, Sagristá-Sauleda J, Soler-Soler J (1985). Primary acute pericardial disease: a prospective series of 231 consecutive patients. *Am J Cardiol.*;56(10):623.
- Rana B, Jones R, Simpson I (1999). Recurrent pericardial effusion, the value of PCR in diagnosis of tuberculosis. *Heart.* Aug 82(2): 246–247.
- Small PM, Pai M (2010). "Tuberculosis diagnosis – time for a game change" *N. Engl. J. Med.* 363: 1070-1071.
- Steingart KR, Sohn H, Schiller I, Kloda LA, Boehme CC, Pai M, Dendukuri N, (2013). Xpert® MTB/RIF assay for pulmonary tuberculosis and rifampicin resistance in adults. *Cochrane Database of Systematic Reviews* 2013: DOI: 10.1002/14651858.CD009593.pub2
- Strang G, Latouf S, Commerford P, Roditi D, Duncan-Traill G, Barlow D, Forder A (1991). Bedside culture to confirm Tuberculous pericarditis. *Lancet.* Dec;338(8782-8783):1600-1.
- Tzoanopoulos D, Stakos D, Hatseras D, Ritis K, Kartalis G (2001). Detection of *Mycobacterium tuberculosis* complex DNA in pericardial fluid, bone marrow and peripheral blood in a patient with pericardial tuberculosis. *Neth J Med.* Oct;59(4):177-80.