

# Anterior Cutaneous Nerve Entrapment Syndrome: A Common Cause of Chronic Abdominal Pain after Bariatric Surgery

Chekame Nizak<sup>1\*</sup>,  
Guy Hej Vijgen<sup>1</sup>,  
Ralph PM Gadiot<sup>2</sup>,  
Martin Dunkelgrun<sup>1</sup>,  
Ulas Biter L<sup>1</sup> and  
Jan A Apers<sup>1</sup>

## Abstract

**Background:** Unexplained abdominal pain after bariatric surgery is common and described in up to 7% of the population, leading to unnecessary opioid prescription and emergency department or outpatient clinic visits. In these patients, anterior cutaneous nerve entrapment syndrome (ACNES) can be a possible cause of the abdominal pain. ACNES is caused by local entrapment of the intercostal nerves by the anterior fascia of the abdominal wall. The aim of this study was to describe the patient characteristics, incidence, diagnostics and treatment results of ACNES in patients with a Laparoscopic Roux-en-Y gastric bypass (LRYGB) or laparoscopic sleeve gastrectomy (LSG) in their medical history.

**Methods:** A retrospective observational cohort study was performed on patients with the diagnosis ACNES and a medical history of LRYGB or LSG, who were treated between 2015 and 2017 in a large teaching hospital.

**Results:** A total of 34 patients were evaluated. Twenty-two out of 34 (65%) patients had a medical history of LRYGB and 12 out of 34 (35%) a LSG. The incidence of ACNES after bariatric surgery in our hospital is estimated at 2-5%. The median interval between the bariatric surgery and treatment for ACNES was 28.2 months. Lidocaine injection as treatment was effective in 32% of the patients and 68% underwent a subsequent surgical local neurectomy. The success rate after surgical neurectomy was 92%.

**Conclusion:** ACNES is a common late complication after bariatric surgery and could be a cause of unexplained abdominal pain. Local neurectomy can be an effective treatment for this diagnosis.

**Keywords:** Unexplained abdominal pain; Bariatric Surgery; Anterior Cutaneous Nerve Entrapment Syndrome (ACNES); Neuropathic pain

- 1 Department of Surgery, Franciscus Gasthuis & Vlietland, Rotterdam, The Netherlands
- 2 Department of Surgery, Rijnstate Hospital, Arnhem, The Netherlands

\*Corresponding author: Chekame Nizak

✉ c.nizak89@gmail.com

Department of Surgery, Franciscus Gasthuis & Vlietland, Rotterdam, The Netherlands.

Tel: 0623741580

**Citation:** Nizak C, Vijgen GH, Gadiot RPM, Dunkelgrun M, Biter LU, et al. (2021) Anterior Cutaneous Nerve Entrapment Syndrome: A Common Cause of Chronic Abdominal Pain after Bariatric Surgery. J Univer Surg. Vol.9 No.3:12

**Received:** January 07, 2021; **Accepted:** January 28, 2021; **Published:** February 04, 2021

## Introduction

Bariatric surgery is currently the most effective treatment for morbid obesity [1–3]. In 2016 more than 600,000 bariatric/metabolic procedures were performed worldwide [4]. Research shows an increase in use of prescribed opioids after bariatric surgery after an initial decrease post-surgery, suggesting the existence of chronic pain [5].

Unexplained abdominal pain after bariatric surgery has an estimated prevalence of 7%, leading to extra emergency and outpatient clinic visits [6]. Frequently, no explanation is found

for the abdominal pain, even after several diagnostic tests or interventions, such as endoscopy, CT scans and surgical exploration. Improvement of symptoms is only seen in 43% of the performed laparoscopies in patients with chronic abdominal pain [7]. Recently, ACNES gained the attention of general surgeons as a possible cause of chronic abdominal pain [8,9].

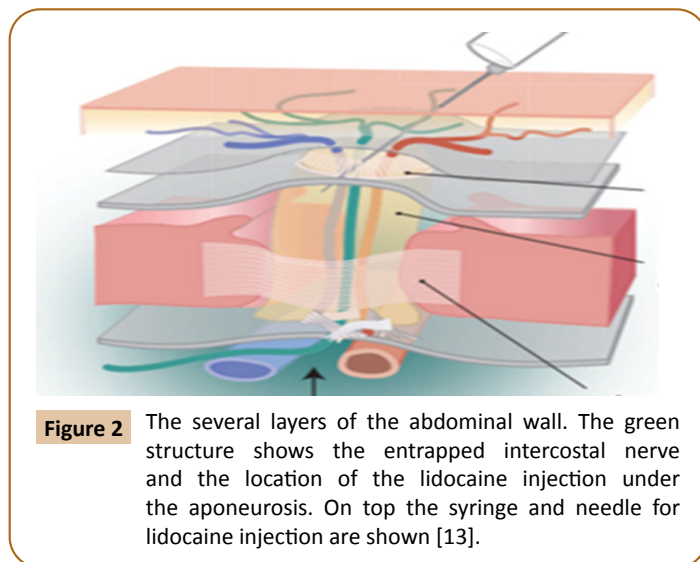
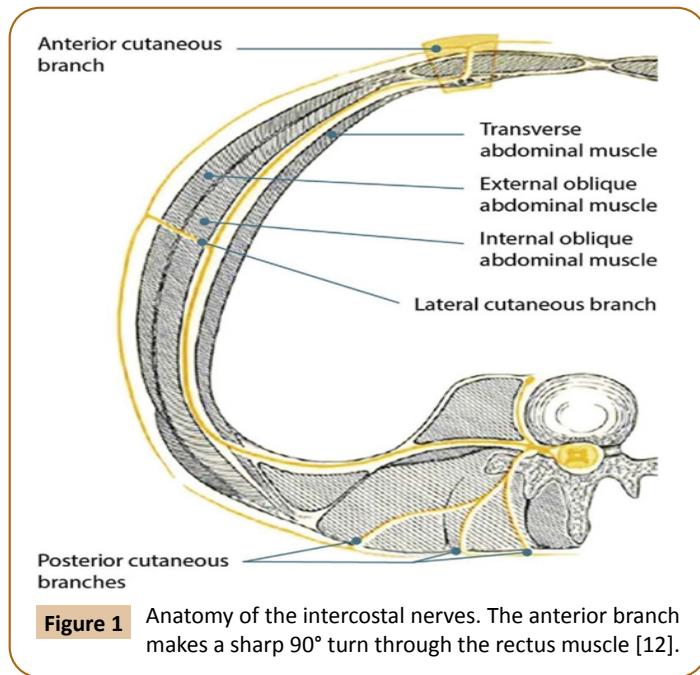
ACNES is characterized by the entrapment of cutaneous intercostal nerves between the aponeurosis and the rectus abdominis muscle which causes neuropathic abdominal wall pain [10]. **Figure 1** shows the anatomy of the abdominal wall and the cutaneous intercostal nerves. In 1926, Carnett called

this condition “intercostal neuralgia” [11]. One of the theories is that increased pressure behind the abdominal wall can cause the nerve bundle to herniate through the fibrous ring and aponeurotic opening. ACNES is a clinical diagnosis and can be diagnosed using the Carnett’s sign and the Pinch test in patients with no abnormalities found in laboratory and imaging tests.

The aim of this study was to describe patient characteristics, incidence, diagnostics, and treatment of ACNES in patients with a history of a LRYGB or LSG in their medical history. To our knowledge, this paper describes Anterior Cutaneous Nerve Entrapment Syndrome (ACNES) as a possible cause of unexplained chronic abdominal pain after bariatric surgery, for the first time in literature [12] (Figure 2).

## Research Methodology

A retrospective observational cohort study was performed in



patients with the diagnosis ACNES and a medical history of LRYGB or LSG, who were treated between 2015 and 2017 in a large teaching hospital. Patients with unexplained abdominal pain that underwent several laboratory and imaging tests without any abnormalities and /or showed typical clinical symptoms of ACNES such as a positive Carnett’s sign or Pinch test were included in the study. The Carnett’s sign is performed by asking the patient to lie in supine position and lift the head and shoulders from the examination table to tense the abdominal muscles and is considered positive when the patient experiences more pain when doing this while the doctor is compressing the tender point. The Pinch test consists of picking up the patient’s skin and subcutaneous fat with the thumb and index finger at the point of maximum pain. It is considered positive when the pain increases during this examination. Data were collected by studying patient files by the main researcher. The therapeutic options are conservative therapy or local neurectomy. In conservative therapy a lidocaine injection is given, which is also of diagnostic value. Lidocaine injections were given by injecting 10 ml 1 percent lidocaine into the point of maximal abdominal wall pain just beneath the anterior fascia of the rectus abdominis muscle. Local neurectomy was performed under general anesthesia through a small incision at the point of maximum abdominal wall pain, exploring the nerve and dissection of the nerve as described by Boelens et al. [9]. Subsequently a questionnaire was sent to all the included patients to evaluate the success rate of the different therapeutic options [13].

Successful treatment was defined as patients who reported no more pain after treatment or did not visit the hospital (outpatient clinic, emergency department) complaining of abdominal pain caused by ACNES after therapy with a follow up of 6 months. Continuous data were reported as median and categorical data were reported as count (percentage).

## Results

A total of 34 patients were evaluated. Patient characteristics are shown in **Table 1**. We estimated an incidence of 1.7% to 2.6% based on the amount of patients who presented with symptoms divided by the number of bariatric procedures in that year (10/568 resp. and 24/892). In 56% (19/34) of the cases the pain was located in the left upper abdominal wall. Median VAS score before treatment was 6.5 in patients with lidocaine therapy (only 4 out of 11 recorded scores). In the neurectomy group the median VAS score was 7 (18 out of 23 recorded scores). Frequently multiple imaging tests were performed with negative findings before the diagnosis ACNES was confirmed. **Table 2** shows the different types of imaging tests that had been performed. In 15% of the patients ACNES was clearly evident and no other additional diagnostics were needed to confirm the diagnosis (5/34). Although conservative treatment alone was possible in 32% (11/34) the majority of the included patients 68% (23/34) underwent additional surgical neurectomy as shown in **Table 3**. The success rate of the lidocaine therapy combined with surgical neurectomy in this group was 92%, which means that in 8% of the cases, neither lidocaine injections, nor surgical neurectomy was effective. No other diagnoses were found as an alternative cause

**Table 1** Patients characteristics.

Patients (N)	34
Male: Female	2:34 (6%)
Age (Median)	47.5
LRYGB	22 (65%)
LSG	12 (35%)
Median weight loss after surgery (kg)	43.5
Median BMI loss after surgery (kg/m <sup>2</sup> )	16.3
Lidocaine injection	11 (32%)
Neurectomy	23 (68%)
Median interval between bariatric surgery and first patient out clinic visit in month	28.2
Laparoscopic cholecystectomy performed after bariatric surgery	9 (26%)
Pain located at left upper abdominal wall	19 (56%)
Median VAS score Lidocaine group	6.5
Median VAS score neurectomy group	7

N: Number of total patients, LRYGB: Laparoscopic Roux-En-Y Gastric Bypass, LSG: Laparoscopic Sleeve Gastrectomy, Kg: Kilogram, BMI: Body Mass Index, %: Percentage, VAS: Visual Analogue Score.

**Table 2** Type and frequency of performed imaging diagnostics.

Type of Diagnosis	N	%
Abdominal Ultrasound	23	67%
Abdominal CT-scan	23	67%
Barium swallow X-ray	13	38%
Gastroscopy	11	32%
No imaging	5	14%

N: Number of patients, %: Percentage of performed imaging diagnostics in study population

**Table 3** Types of therapy.

Types of therapy	N
Lidocaine injection	32.4% (11)
Neurectomy	67.6% (23)
Total	100% (34)

N: Number of patients, %: Percentage of patients

of chronic abdominal pain after ACNES treatment. Only one patient with persistent abdominal pain underwent diagnostic laparoscopy with negative findings. The majority of the patients in this study responded positively in a questionnaire concerning the experience of their treatment and the provided care in this hospital, as shown in **Tables 4A-4D**. More detailed 80% of the patients who responded to the questionnaire would recommend this hospital to friends/family for this treatment with a rate of 7 or higher and a mean of 7.6 out of 10.

## Discussion

ACNES is a relatively uncommon diagnosis and often not considered as a possible cause of chronic abdominal pain after bariatric surgery. Most clinicians think of an intra-abdominal cause when patients present with chronic pain. Frequently additional diagnostics are performed to rule out acute causes of abdominal pathology. In this report it was shown that in 29 of the 34 (85%) patients imaging tests were performed with negative findings.

**Table 4A** Questions asked to study subjects regarding information.

Questions	Mean ± SD
1. Information regarding the provided treatment?	4.4 ± 1.1
2. Did you determine your treatment together with the care provider?	4.0 ± 1.5
3. Were you informed about the pros/cons?	3.9 ± 1.7
4. Were your preferences taken into account when choosing the right treatment?	4.4 ± 1.3
5. Did you receive information about the side effects?	3.8 ± 1.5
6. Did you receive advice on how to deal with your illness/complaints?	3.0 ± 1.6
7. Did the care taker listen to what you were saying?	4.2 ± 1.2
8. Did you have confidence in the expertise of the care providers?	4.5 ± 1.2
9. Was there good cooperation between the care providers?	4.2 ± 1.4
10. Does the various agreements fit in well with each other?	4.1 ± 1.4
11. Has your safety been taken into account?	4.4 ± 1.2
12. The caregivers worked hygienic.	4.5 ± 0.8

Answer options provided were; 1. No, 2. A little bit, 3. Partly, 4. Largely, 5. Yes, completely, 6. I don't know/not applicable. Values shown are Mean ± Standard deviation.

**Table 4B** Question regarding subject's health after the treatment.

Question	Mean ± SD
13. How was your health after the treatment?	3.1 ± 1.8

Answer options provided were; 1. Much better, 2. Better, 3. Slightly better, 4. Same, 5. Slightly worse, 6. Much worse, 7. Very much worse 8 don't know / not applicable. Values shown are Mean +/- Standard deviation.

**Table 4C** Question asked to study subject's satisfaction. Answer options provided were; 1 definitely not, 10 certainly yes. Values shown are Mean ± Standard deviation.

Question	Mean ± SD
14. Would you recommend this hospital to others with the same symptoms as yours?	7.6 ± 2.7

**Table 4D** Questions asked to study subject's satisfaction.

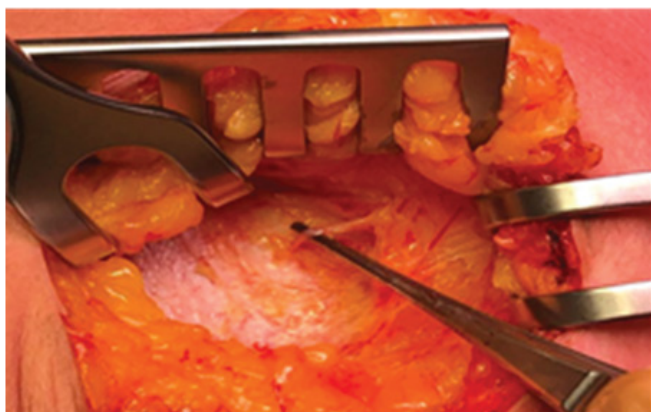
Question	Mean ± SD
15. How would you rate the care provided by the hospital?	8.0 ± 1.8

Answer options provided; 1. Very poor, 10. Excellent. Values shown are Mean ± Standard deviation.

It should be considered a part of a learning curve to recognize the diagnosis. ACNES is a clinical diagnosis and it is important to differentiate between acute abdominal pain caused by an intra-abdominal disease or complication and chronic neuropathic pain of the abdominal wall, which has specific clinical findings (**Figure 3**).

In this study ACNES is diagnosed after a median of 28.2 months after bariatric surgery. Due to the long interval between surgery and the description of chronic pain it is hypothesized that this is not directly caused by the bariatric operation. It is most probably that the delay in diagnosing ACNES in this group is due to the fact that it is a diagnosis per exclusionism, meaning that other





**Figure 3** The abdominal wall explored *in vivo*. We are looking at the anterior rectus sheath. The black strings and the red vessel loop mark the explored entrapped anterior intercostal nerve which will be dissected (Picture taken by author Jan. A. Apers).

diagnoses must be ruled out first in able to confirm the diagnosis. Also, there is frequently a delay in recognition of the signs and symptoms.

Possibly, the nerve entrapment is caused by weight loss and loss of abdominal circumference. Hence, loss of circumference is the cause of local entrapment at the level of the abdominal wall on the peripheral nerve, which does not shorten or lose length, while the abdominal wall does.

In 92% of the patients treatment seemed successful. However, data on postoperative VAS scores are lacking. To confirm

adequacy of therapy as a sort of control mechanism, a validated questionnaire was used to ask patient about their experience: most of the patients were satisfied about their treatment and reported improvement of symptoms. The prevalence of unexplained abdominal pain after bariatric surgery is estimated to be around 7% [6]. In this study ACNES incidence is roughly estimated 2-3%. This estimate could be biased by the delay of symptoms and could be higher. Possibly, a large part of the patients with unexplained chronic abdominal pain could be diagnosed and treated under this diagnosis. This study emphasizes the importance of the awareness of the diagnosis ACNES amongst clinicians and bariatric surgeons, and could hopefully lead to less cases of unexplained (chronic) abdominal pain. This in turn might lead to less unnecessary emergency department visits, diagnostics, treatments, reduction of unnecessary opioid use and a possible better quality of life.

## Conclusion

Although ACNES as a cause of unexplained abdominal pain after bariatric surgery is a relatively unknown condition it should be on the list of possible diagnoses. Local injections with lidocaine in combination with local neurectomy are effective treatments. Bariatric surgeons and other physicians who treat post-bariatric patients should be more aware of this diagnosis as a cause of chronic abdominal pain. Subsequently, this might prevent unnecessary opioid prescription, diagnostics or even surgical interventions by appropriate treatment or referral.

## Conflicts of Interest

The authors declare no conflicts of interest.

## References

- 1 Buchwald H, Avidor Y, Braunwald E, Jensen MD, Pories W, et al. (2010) Bariatric surgery: A systematic review and meta-analysis. *JAMA* 292: 1724-1737.
- 2 Hirth DA, Jones EL, Rothchild KB, Mitchell BC, Schoen JA (2015) Laparoscopic sleeve gastrectomy: A long-term weight loss outcomes. *Surg Obes Relat Dis* 11: 1004-1007.
- 3 Obeid NR, Malick W, Concors SJ, Fielding GA, Kurian MS, et al. (2016) Long-term outcomes after Roux-en-Y gastric bypass: 10-to 13-year data. *Surg Obes Relat Dis* 12: 11-20.
- 4 Angrisani L, Santonicola A, Iovino P, Vitiello A, Higa K, et al. (2018) IFSO worldwide survey 2016: primary, endoluminal, and revisional procedures. *Obes Surg* 28: 3783-3794.
- 5 King WC, Chen JY, Belle SH, Courcoulas AP, Dakin GF, et al. (2017) Use of prescribed opioids before and after bariatric surgery: A prospective evidence from a US multicenter cohort study. *Surg Obes Relat Dis* 13: 1337-1346.
- 6 Pierik AS, Coblijn UK, De Raaff CA, Van Veen RN, Van Tets WF, et al. (2017) Unexplained abdominal pain in morbidly obese patients after bariatric surgery. *Surg Obes Relat Dis* 13: 1743-1751.
- 7 Alsulaimy M, PUNCHAI S, Ali FA, Kroh M, Schauer PR, et al. (2017) The utility of diagnostic laparoscopy in post-bariatric surgery patients with chronic abdominal pain of unknown etiology. *Obes Surg* 27: 1924-1928.
- 8 Boelens OB, Scheltinga MR, Houterman S, Roumen RM (2013) Randomized clinical trial of trigger point infiltration with lidocaine to diagnose anterior cutaneous nerve entrapment syndrome. *Brit J Surg* 100: 217-221.
- 9 Boelens OB, van Assen T, Houterman S, Scheltinga MR, Roumen RM (2013) A double-blind, randomized, controlled trial on surgery for chronic abdominal pain due to anterior cutaneous nerve entrapment syndrome. *Ann Surg* 257: 845-849.
- 10 Applegate WV (2002) Abdominal cutaneous nerve entrapment syndrome (ACNES): a commonly overlooked cause of abdominal pain. *Perm J* 6: 20.
- 11 Carnett JB (1926) Intercostal neuralgia as a cause of abdominal pain and tenderness. *Surg Gynecol Obstet* 42: 625-632.
- 12 Applegate WV (1972) Abdominal cutaneous nerve entrapment syndrome. *Surgery* 71: 118-124.
- 13 Roumen RM, Scheltinga MR (2006) Abdominale intercostale neuralgie: een vergeten oorzaak van buikpijn. *Ned Tijdschr Geneesk* 150: 1909-1915.