

# Cladophialophora bantiana, the Neurotropic Fungus – A Mini Review

GANAVALLI S. AJANTHA, RAGHAVENDRA D. KULKARNI

## ABSTRACT

*Cladophialophora bantiana* is the most common and dangerous neurotropic fungus which causes brain abscess. The infection which is caused due to this fungus is risky, not only to the patient due to the poor prognosis, but also to the clinician because of the difficulty in its management as well as to the

laboratory personnel who handle it. Only few clinicians are aware of this fungus. Complete awareness among the clinicians and other health care personnel is essential for the successful management of these infections. On this basis, we have reviewed the microbiological, clinical and the therapeutic aspects of the *C. bantiana* infections.

**Key Words:** Cladophialophora - *Cladophialophora bantiana* - Brain abscess - Neurotropic fungi – Dematiaceous fungi – Phaeoid fungi - Cerebral phaeohyphomycosis

## KEY MESSAGE

- *C. bantiana* is the commonest cause of non-traumatic CNS infections.

## INTRODUCTION

CNS infections which are caused by fungi except *Cryptococcus neoformans* are always a surprise, as the incidence is very less, especially in immunocompetent individuals [1]. Apart from *Cryptococcus neoformans*, a few fungal species like *Cladophialophora bantiana*, *Exophiala dermatitidis*, *Rhinocladiella mackenziei* and *Ochroconis gallopava* are the recognized neurotropes. *C. bantiana*, a phaeoid fungus, is the commonest cause of cerebral phaeohyphomycosis [2-4]. The purpose of this review was to provide adequate and clinico-microbiologically meaningful information to the health care personnel who were involved in the management of neurological infections. We searched the English language manuscripts which were published on 'any date', through PubMed, Google Scholar, ScienceDirect, MDConsult, Ovid and Medknow. The search terms which were used were 'Brain abscess', 'Cerebral Phaeohyphomycosis', 'Phaeohyphomycosis', 'Cladophialophora', '*Cladophialophora bantiana*', '*Cladophialophora bantianum*', '*Xylohypha bantiana*', '*Xylohypha emmonsii*', and '*Cladosporium trichoides*'.

## DEMATIACEOUS FUNGI

Dematiaceous, melanized or phaeoid fungi are a heterogeneous collection of generally unrelated fungi which share the common phenotypic feature of being darkly coloured. Their dark pigmentation results from the presence of dihydroxynaphthalene melanin in the cell walls. There is an argument that the term, 'dematiaceous' is epistemologically incorrect. Therefore, the term 'phaeoid' (which is derived from the Greek word "phaeo," meaning "dark") came to be used as a replacement. Both the terms, 'dematiaceous fungi' or 'phaeoid fungi' have no real taxonomic significance [5, 6]. Now-a-days, the term "melanized" is more frequently used. Though the

debate about using different terms to describe the same character continues, all these terms are in common use. Dematiaceous fungi, though they are mainly saprophytic, are important agents of human and animal diseases. At present, over 150 species and 70 genera of dematiaceous fungi are known to cause various diseases and the list of potential pathogens is expanding rapidly [7]. This group includes hyphomycetes, coelomycetes and ascomycetes. The clinical conditions which are associated with dematiaceous fungi are broadly classified into chromoblastomycosis, eumycotic mycetoma, and phaeohyphomycosis [Table/Fig-1] [6, 8-10].

The second nomenclature committee of the International Society for Human and Animal Mycology (ISHAM) recommends that the term "phaeohyphomycosis" should be a generic term for any mycosis which involves a dematiaceous fungus [5]. Clinical laboratories have to maintain high vigil and diligence in the task of identifying the dark moulds and in assessing their clinical significance.

## TAXONOMY OF C. BANTIANA

*C. bantiana* is a melanized hyphomycetous (hyphomycetous - conidia not enclosed within any special structure) fungus which belongs to the order, Chaetothyriales [4]. This fungus has been christened several times by taxonomists; hence, different names like *Cladosporium bantianum*, *Cladosporium trichoides*, *Xylohypha bantiana* and *Xylohypha emmonsii* have been found to be used for the same organism in the literature. [2-5, 11]

The genus, *Cladophialophora* represents the anamorph members of ascomycetes in the order, Chaetothyriales, in the family, Herpotrichiellaceae. [9] These members are encountered in human infections which range from mild cutaneous lesions to fatal CNS infections. [12] *C. bantiana* was earlier under the genus, *Cladosporium* and it was later transferred to the genus, *Xylohypha*. [13] *C. carrionii*

Disease in humans	Common agents
Chromoblastomycosis	<i>Fonsecaea pedrosoi</i> (most common)
	<i>F. compacta</i>
	<i>Cladophialophora carrionii</i>
	<i>Phialophora verrucosa</i>
	<i>Rhinochadiella aquaspersa</i>
	<i>Exophiala jeanselmei</i>
	<i>Exophiala spinifera</i>
Eumycetoma	<i>Fonsecaea monophora</i>
	<i>Madurella mycetomatis</i>
	<i>Madurella grisea</i>
	<i>Exophiala jeanselmei</i>
	<i>Leptosphaeria senegalensis</i>
	<i>Pyrenochaeta</i> species
<b>Phaeohyphomycosis</b>	
Superficial phaeohyphomycosis	<i>Tinea nigra</i> : <i>Hortaea werneckii</i> Black piedra: <i>Piedraia hortae</i>
Cutaneous phaeohyphomycosis	<i>Exophiala jeanselmei</i> <i>Natrasia mangiferae</i> / <i>Scytalidium dimidiatum</i>
Subcutaneous phaeohyphomycosis	<i>Exophiala</i> spp. <i>Alternaria</i> spp. <i>Phialophora</i> spp. <i>Bipolaris</i> spp.
Corneal phaeohyphomycosis (Mycotic keratitis)	<i>Curvularia</i> spp. <i>Alternaria</i> spp. <i>Bipolaris</i> spp. <i>Lasioidiplodia theobromae</i>
Sinusitis	<i>Bipolaris</i> spp. <i>Curvularia</i> spp.
Deep-seated phaeohyphomycosis (DSP)	Disseminated DSP <i>Scedosporium prolificans</i> (Some experts do not consider it dematiaceous) <i>Bipolaris</i> spp. <i>Curvularia</i> spp. <i>Exophiala</i> spp. <i>Wangiella</i> spp.
	Cerebral phaeohyphomycosis
	<i>Cladophialophora bantiana</i> (Most common)
	<i>Ochroconis gallopavum</i>
	<i>Rhinochadiella mackenziei</i>

**[Table/Fig-1]:** Melanized Fungi and Diseases in Humans [5, 6, 8-10]

and *C. devriesii* also were included in the genus, *Cladosporium*. Large subunit rRNA sequencing studies and nutritional physiology tests have led to the taxonomic reclassification of many fungal pathogens into the genus, *Cladophialophora*. Other species which are included under the genus, *Cladophialophora* are *C. emmonsii*, *C. modesta*, *C. arxii*, *C. saturnica*, and *C. boppii*. [6, 14, 15]

The type species of the genus, *C. carrionii*, causes chromoblastomycosis. *C. bantiana* and *C. modesta* cause brain infections, *C. devriesii* and *C. arxii* cause disseminated disease and *C. boppii*, *C. emmonsii* and *C. saturnica* cause cutaneous infections. [12, 16, 17]

## MICROBIOLOGY OF C. BANTIANA

Phaeoid fungi need intensive efforts for their identification upto the species level. Morphological, physiological and biochemical characters are used in their identification. Molecular studies now provide precision in the identification when the routine procedures are inconclusive. Among the vast array of these dematiaceous fungi, *C. bantiana* remains a comparatively easier species for identification,

mainly because of its typical morphology and the source of the clinical specimen. It can grow on routine fungal culture media. The more commonly used media are potato dextrose agar, oatmeal agar and malt agar. Sabouraud's dextrose agar is not generally preferred for black mould identification because the colonies may fail to develop their characteristic colour on this medium and the conidiation or sporulation may also be delayed or poor. [6]

There are few important growth requirements and colony characteristics that may help towards the identification of this fungus. [6, 14, 18, 19] Its growth rate is moderate and it takes around 7-8 days of incubation to see visible growth. This fungus grows at both room temperature and at 37°C. The colonies mature within 15 days and they show a velvety texture and olivaceous-gray to brown discoloration with a black reverse [Table/Fig-2]. They do not produce any diffusible pigment.

*C. bantiana* has few important microscopic features which help in its identification. [6, 14, 18, 19] The fungus shows hyaline-to-brown, septate hyphae. Smooth walled, single-celled, pale olivaceous, ellipsoidal to spindle-shaped conidia of approximately 2.5-5 x 6-11 µm in size are seen. They are arranged in long, strongly coherent (non-fragile) chains and rarely show branching [Table/Fig-3] and [Table/Fig-4]. The chains of the conidia arise directly from the hyphae. Chlamydoconidia are seen occasionally.

The *Cladophialophora* species are prone to identification problems because of the high degree of phenotypic similarity between its different species. *Cladophialophora* and *Cladosporium* can be differentiated, as the former do not display the dark scars of attachment. The type species of the genus *Cladophialophora*, *Cladophialophora carrioni*, shows densely-branched conidial chains. The chains arise from branched or unbranched denticles in *C. carrioni*.


There are some conventional biochemical tests and physiological tests which are commonly used in the identification of *C. bantiana*. [6, 20, 21] This fungus grows at 42-43°C, it can grow on media which contain cycloheximide, it is urease positive and the Fontana-Masson staining stains it black (Table/Figure-3). The Fontana-Masson stain is specific for melanin. This species is non-proteolytic on casein agar and it is unable to liquefy 12% gelatin. However, molecular methods like sequencing are the most dependable tools which can be used for its confirmation.

*C. bantiana* has rarely been isolated from nonhuman sources and only a few reports of its isolation from nature are on record. [20] The precise ecological niche of the fungus is unknown, but it is believed to be a soil fungus. [2, 12] The occupational association of the *C. bantiana* infection with farming is suggestive of the presence of this fungus in this environment. [22, 23]

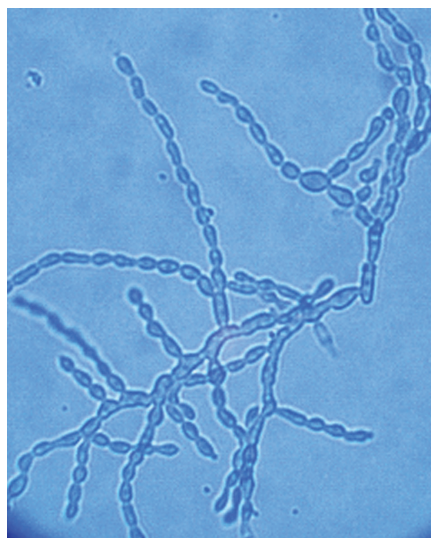
Its primary pulmonary colonization may be important, following which it is transferred through the haematogenous route to the CNS. [2, 5, 16, 21, 24] This fungus has been shown to be present in the lungs of cerebral phaeohyphomycosis patients. [25] Animal experiments have shown that the organism is carried via blood to the CNS. [20] The presence of fungal elements in the arterial walls has been considered as the evidence of its spread to the CNS through the blood vessels. The multiple brain abscesses which are seen frequently also suggest its dissemination through the blood stream. [4] The rarely occurring cutaneous or subcutaneous infections result from its traumatic inoculation. [26]

The laboratory personnel who handle this organism should not ignore the fact that pulmonary colonization is the initial event

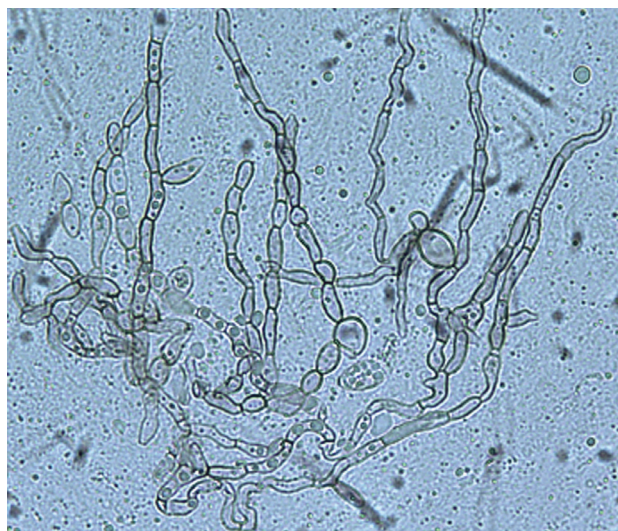




[Table/Fig-2]: Photograph showing *C. bantiana* colonies



[Table/Fig-3]: Photograph showing *C. bantiana* morphology on Lactophenol cotton blue mount



[Table/Fig-4]: Photograph showing *C. bantiana* morphology on KOH mount

and that the fungus is capable of infecting immunocompetent individuals. This species has been included in the list of fungi which should be kept under biosafety level-2 containment and therefore the use of a biosafety cabinet is imperative. [9, 18]

The fungi which are commonly encountered in non-traumatic brain infections are *C. bantiana*, *C. modesta*, *Exophiala dermatitidis*, *Fonsecaea monophora*, *Ochroconis gallopava* and *Rhinoctadiella mackenzie*. Amongst them, *C. bantiana* is the most frequently

isolated fungus from cerebral phaeohyphomycosis. [2] This fungus has the ability to cause CNS infections in immunocompetent young individuals with no underlying risk factors for the fungal invasion. [2, 4] The infection with *C. bantiana* is commonly reported in transplant recipients, intravenous drug abusers or in patients on steroids. The condition may be mistaken for tubercular abscess. [27] Though extracranial infection is extremely rare, the fungus has also been reported to cause cutaneous and subcutaneous phaeohyphomycosis. [16, 24, 29, 26]

The virulence attributes of *C. bantiana* have not been adequately understood. Melanin production and thermotolerance (above 40°C) have been considered to be the important virulence factors which are responsible for its pathogenicity. [12] Animal pathogenicity studies have confirmed its affinity to the glial tissue. [20] The evolutionary advantage, if any, of its growth in the living brain tissue remains unclear. [16] Neurotropism is related to the introns in the 18S rDNA subunit of the fungi. [30] Melanin may play a role in the CNS localization, probably, as it scavenges the free radicals which are produced by the phagocytic cells. [4] Melanin, as a virulence factor, has also been suggested in the CNS metastasis of malignant melanoma. Although the tumour spreads to many parts of the body, it has a predilection for the brain. [4, 31] However, melanin may not be the only factor for the CNS infection, as many other melanized fungi are not the frequent invaders of the CNS.

The infection provokes a granulomatous reaction which contains large numbers of giant cells. The fungal elements inside the phagocytes retain their viability. The suppression of innate cellular immunity by using cortisone is demonstrated to promote the *C. bantiana* infection. The first line of defense probably includes the complement system and PMNs, but T cell-mediated immunity also plays a role. [16, 22]

## CEREBRAL PHAEOHYPHOMYCOSIS

*C. bantiana* infections are increasing in recent years. [2] The organism has a general preference for warmer climates with high humidity. Cases from arid climatic zones are rare. [16] Most infections occur in the 2<sup>nd</sup> or 3<sup>rd</sup> decades of life. However, it is noteworthy that the youngest patient who was reported was a six day old neonate. [32]

The brain infection may present as a solitary, well-defined abscess, multiple abscesses or poorly demarcated cerebritis with extensive necrotic lesions. [2, 5, 7, 23, 25] Brain abscess is the commonest manifestation. [2] The abscesses are usually hemispheric and they affect the white matter and show a predilection for the frontal lobes. However, choroid plexus, thalamic, diencephalic, and cerebellar involvement can also occur. [16, 23] The extent and delineation of the lesions may vary according to the immune status and to immune response of the subject. [6] Rare presentations such as meningitis and meningoencephalitis have also been reported. [2, 32] Whether the character of the lesion is an important determinant of the clinical outcome or not, is not clear. [2, 23] Diffuse lesions or multiple lesions may complicate the surgical management. [33]

CNS infections which are caused by *C. bantiana* have been reported worldwide. [16, 21, 22, 24, 25, 28, 33] The first culture-proven case was reported in 1952. [34] The first culture-proven Indian case was reported from Mumbai in 1966. [35] Many reports from various parts of India are available since then. [23, 27, 36-41]

Recently, we isolated this fungus from a case of brain abscess. During the literature search, we could not come across any report of the isolation of this pathogen from north Karnataka. Therefore,

to the best of our knowledge, this is the first culture-proven case of cerebral phaeohyphomycosis which was caused by *C. bantiana*, from north Karnataka. The patient was treated by a near-total excision of the lesion and amphotericin B for two weeks, followed by fluconazole for six months. He was advised 5-flucytocin in addition to amphotericin-B; however, he could not afford any antifungal other than fluconazole. The patient was doing well at follow up after three months. The case was discussed, where the radiological aspects were highlighted. [42]

## MANAGEMENT

Cerebral phaeohyphomycosis is one of the most difficult conditions to treat. The mortality rate could reach up to as high as 70%, even in the treated cases. [2] When left untreated, the CNS infections which are caused by *C. bantiana* can be fatal within one to six months. [18] Complete excision of the brain abscess is better than simple aspiration or partial excision, and this is recommended. [2, 4, 5] Total excision of the well-defined abscess helps in reducing the pressure effects, reduction of the fungal load and in enhancing the response to the antifungal therapy. However, recurrence is a noted problem. [23]

Antifungal therapy is essential in spite of surgical excision. The probability of residual fungal elements cannot be ruled out even after a thorough excision. [37] In addition, there are no standard guidelines for antifungal therapy which are available so far. The recommendations are based on anecdotal personal experiences. The rarity of this infection does not permit in gathering evidence which is based on authentic clinical trials. Monotherapy is not preferred as it often results in treatment failure. [4] Although amphotericin B has an antifungal activity against *C. bantiana*, the fungus may have innate or acquired resistance to it. [5] In an Indian case series, mixed results were noted with the drug. [23] Flucytosine has an antifungal activity against *C. bantiana*, and it also has excellent penetration into the CSF. [2] Because of the increasing risk of resistance, it has to be used in combination with other antifungal agents. [43] Ketoconazole, miconazole and fluconazole are not recommended. [18] In spite of having negligible activity, fluconazole has been used in some of the cases because of its low cost. [10] Identical problems were encountered in our case and because of the financial inability of the patient, we had to put him on fluconazole, hoping for at least a little support to the immune apparatus, to combat the residual fungal elements after thorough excision. Voriconazole has a fungicidal effect on *C. bantiana*. [44] It has good penetration into the CNS, but its MIC for *C. bantiana* is high. The clinical significance of the high MIC is not clear. Both success and failure have been reported. [10, 28, 33, 45, 46] Hence, it might not be the first choice of treatment in such infections. [14]

Caspofungin has poor antifungal activity against this fungus. Posaconazole and itraconazole have the best in vitro activity against *C. bantiana*, followed by isavuconazole. [14] Concerns over the adverse effects and the lack of intravenous formulations are the problems with itraconazole. [7] Isavuconazole needs further evaluation. Experimental studies in murine models have shown best responses with posaconazole, where it prolonged the survival and reduced the level of the brain's fungal burden significantly as compared to itraconazole. [47] At present, posaconazole appears to be the promising drug against *C. bantiana* as it also has good penetration into the CNS. [14] However, it must be noted that the action of posaconazole against *C. bantiana* is static and not cidal. [47]

The number of isolates which have been tested against various antifungal drugs to date is low and therefore, the susceptibility profiles have a limited predictive value. The clinical correlation data are limited. [10] Complete surgical excision in combination with multi-antifungal therapy, seems to be the best treatment option at present. Initial combination therapy with liposomal amphotericin B and high dose azole (itraconazole, voriconazole or posaconazole), with or without 5-FC has been suggested in the literature. [2, 4, 14, 23, 27] Again, there is no standard guideline on the duration of the therapy. It can be as short as 3 months, which can be extendable up to or more than a year. The therapy should be continued until a complete radiographical resolution occurs. [4] The importance of a continuous long term follow up cannot be over emphasized.

## DIFFICULTIES IN THE DEVELOPING WORLD

Most of the antifungals which are available for human therapy have two important drawbacks; the first being toxicity and the second, the cost. In the developing world, the cost becomes the primary issue. In addition to affordability, the uncertainty of the outcome is another deterrent which influences the decision making to initiate the therapy, as ultimately it is the patient who is going to select one of the different therapeutic options which are offered to him/her. The investigations and hospitalization charges add to the expenses. The approximate cost of only 6-8 weeks of the most economical therapy exceeds at least three hundred thousand Indian National Rupees. Because of this limitation, many cases in India are being treated with non-lipid based amphotericin B, with or without combination, which is within the reach of the Indian population. In many cases, even fluconazole has been used in spite of its proved inefficacy.

The development of a more effective as well as economical antifungal therapy, along with an accurate non-invasive diagnostic technique only will end this uncertainty about the outcome of the treatment and will ensure a better prognosis for this fatal fungal infection. Also, the pace of the research on this topic has to be stepped up further. It should be emphasized on the clinical fraternity that advanced imaging techniques including MR spectroscopy are far from being perfect in the establishment of the aetiological diagnosis. The culture and identification of the causative fungal agent is indispensable for its management. The identification of the fungus upto the species level is crucial in selecting the antifungal agent, as the choice of the antifungal agent varies with the species. When the fungus is isolated from clinical samples, a compatible histopathology is also a must.

## CONCLUSIONS

Brain abscesses are diagnosed early and more frequently because of the advancements in radiology. *C. bantiana* is one of the most important fungal agents which cause nontraumatic brain abscess. Culturing and histopathological studies together give the confirmatory evidence of the aetiological diagnosis. The laboratory physicians need to exercise a meticulous approach while handling the specimens. Awareness, as well as a high index of suspicion among the clinicians is the key in diagnosing this potentially fatal neurotropic fungal infection. Though the therapy is difficult, newer azoles like posaconazole have shown some promising results.

**Conflict of Interest:** None declared

## REFERENCES

- [1] Rajshekhar V. Surgical management of intracranial fungal masses. *Neuro India*. 2007; 55: 268-73.



- [2] Revankar SG, Sutton DA, Rinaldi MG. Primary central nervous system phaeohyphomycosis: A review of 101 cases clinical infectious diseases. 2004; 38: 206–16.
- [3] Chakrabarti A. Epidemiology of CNS mycoses. *Neurol India*. 2007; 55: 191-7.
- [4] Li DM, de Hoog GS. Cerebral phaeohyphomycosis—a cure at what lengths? *Lancet Infect Dis* 2009; 9: 376–83.
- [5] Cooper CR Jr. Deep phaeohyphomycosis. In: Merz WG, Hay RJ, editors. *Topley and Wilson's Microbiology and Microbial Infections—Medical Mycology*. 10<sup>th</sup> ed. Hodder Arnold Publishers: London; 2005; 739-48.
- [6] Sutton DA, Rinaldi MG, Sanche SE. Dematiaceous fungi. In: Anaissie EJ, McGinnis MR, Pfaller MA, editors. *Clinical Mycology*. 2<sup>nd</sup> ed. Churchill Livingstone-Elsevier: Philadelphia; 2009; 329-54.
- [7] Revankar SG, Sutton DA. Melanized fungi in human disease. *Clin Microbiol Rev* 2010; 23(4): 884-928.
- [8] Pappas PG. Dematiaceous fungal infections. In: Goldman L, Ausiello D, editors. *Cecil Medicine*. 23<sup>rd</sup> ed. Saunders-Elsevier: Pennsylvania; 2007; 2368-70.
- [9] Revankar SG. Phaeohyphomycosis. *Inf Dis Clin NA*, 2006; 20: 609-20
- [10] Revankar SG. Dematiaceous Fungi. *Mycoses* 2007; 50: 91-101.
- [11] McGinnis MR, Sigler L, Rinaldi MG. Some medically important fungi and their common synonyms and the names of uncertain applications. *Clin Inf Dis* 1999;29:728–30
- [12] Badali H, Gueidan C, Najafzadeh MJ, Bonifaz A, Gerrits van den Ende AHG, de Hoog GS. Biodiversity of the genus *Cladophialophora*. *Studies in Mycology* 2008; 61: 175–91.
- [13] Espinel-Ingroff A. History of medical mycology in the United States. *Clinical Microbiology Reviews* Apr. 1996; 9(2): 235–72.
- [14] Badali H, de Hoog GS, Curfs-Breuker I, Klaassen CHW, Meis JF. The use of amplified fragment length polymorphism to identify 42 *Cladophialophora* strains which were related to cerebral phaeohyphomycosis with in vitro antifungal susceptibility. *Journal of Clinical Microbiology* July 2010;48(7): 2350–6.
- [15] Guarro J, Gene J, Stchigel AM. Developments in fungal taxonomy. *Clinical Microbiology Reviews* July 1999; 12(3): 454–500.
- [16] Horr e R, de Hoog GS. Primary cerebral infections which were caused by melanized fungi: A review. *Studies in Mycology* May 1999; 176-93.
- [17] DE Hoog GS, Nishikaku AS, Fernandez-Zeppenfeldt G, Padin-Gonzalez C, Burger E, Badali H, Richard-Yegres N, Gerrits van den Ende AHG, et al The molecular analysis and pathogenicity of the *Cladophialophora carrionii* complex, with the description of a novel species. *Studies in Mycology* 2007; 58: 219-34.
- [18] Schell WA, Salkin IF, McGinnis MR. Bipolaris, Exophiala, Scedosporium, Sporothrix, and other dematiaceous fungi. In: Murray PR, Baron EJ, Jorgensen JH, Pfaller MA, Tenover FC, Tenover FC, editors. *Manual of Clinical Microbiology*, 8<sup>th</sup> ed. ASM Press; Washington DC: 2003; 1820-47.
- [19] Larone DH. In: *Medically important fungi*. 4<sup>th</sup> ed. Washington: ASM Press; 2002; 195.
- [20] Dixon DM, Shadomy HJ, Shadomy S. Dematiaceous fungal pathogens which were isolated from nature. *Mycopathologia* 1980; 70(3): 153-61.
- [21] Emmens RK, Richardson D, Thomas W, Hunter S, Hennigar RA, Wingard JR, Nolte FS, et al Necrotizing cerebritis in an allogeneic bone marrow transplant recipient due to *Cladophialophora bantiana*. *Journal of Clinical Microbiology*, 1996; 34 (5): 1330–2.
- [22] Kantarcioglu AS, de Hoog GS. Infections of the central nervous system which were caused by melanized fungi: a review of cases which were presented between 1999 and 2004. *Mycoses* 2004; 47: 4–13.
- [23] Garg N, Devi IB, Vajramani GB, Nagarathna S, Sampath S, Chandramouli BA, Chandramukhi A, Shankar SK, et al Central nervous system cladosporiosis: An account of ten culture-proven cases. *Neurology India* 2007; 55(3): 282-8.
- [24] Keyser A, Schmid FX, Linde HJ, Merk J, Birnbaum DE. Disseminated *Cladophialophora bantiana* infection in a heart transplant recipient. *The Journal of Heart and Lung Transplantation*. April 2002; 21(4): 503-5
- [25] Roche M, Redmond RM, O'Neill S, Smyth E. A case of multiple cerebral abscesses due to infection with *Cladophialophora bantiana*. *Journal of Infection* 2005; 51: e285–e8
- [26] Werlinger KD, Moore AY. Eumycotic mycetoma which was caused by *Cladophialophora bantiana* in a patient with systemic lupus erythematosus. *J Am Acad Dermatol* 2005;52(5):p. S114-7.
- [27] Borkar SA, Sharma MS, Rajpal G, Jain M, Xess I, Sharma BS et al Brain abscess which was caused by *Cladophialophora bantiana* in an immunocompetent host: the need for a novel cost-effective antifungal agent. *IJMM* 26(3): 271-4.
- [28] Levin TP, Baty DE, Fekete T, Truant AL, Suh B. *Cladophialophora bantiana* brain abscess in a solid-organ transplant recipient: case report and review of the literature. *J Clin Microbiol* 2004; 42(9): 4374–8.
- [29] Patterson JW, Warren NG, Kelly LW. Cutaneous phaeohyphomycosis due to *Cladophialophora bantiana*. *Journal of the American Academy of Dermatology*. 40(2): Part 2: 364-6
- [30] Gerrits van den Ende AHG, de Hoog GS Variability and molecular diagnostics of the neurotropic species, *Cladophialophora bantiana*. *Studies in Mycology* 1999; 43: 151–2
- [31] Cotton DWK. Skin. In: Underwood JCE, editors. *General and Systematic Pathology*. 3<sup>rd</sup> ed. Churchill Livingstone: Edinburgh; 2000; 667-97.
- [32] Banerjee TK, Patwari AK, Dutta R, Anand VK, Chabra A. Cladosporium bantianum meningitis in a neonate. *Indian J Pediatr*. 2002 Aug; 69(8):721-3.
- [33] Hanieh S, Miller R, Daveson L, Oman K, Norton R. Cerebral phaeohyphomycosis which was caused by *Cladophialophora bantiana* in a patient with chronic lymphocytic leukemia. *Clinical Microbiology Newsletter* 2006; 28: 110-2.
- [34] Binford CH, Thompson RK, Gorhan ME. Mycotic brain abscess due to *C. trichoides*, a new species: Report of a case. *Am J Clin Pathol* 1952;22:535–42.
- [35] Dastur HM, Chaukar AP, Rebello MD. Cerebral chromoblastomycosis due to *Cladosporium trichoides* (Bantianum). I. (A review and case report). *Neurology India*. 1966 Jan-Mar; 14(1): 1-5
- [36] Deb S, Khan AK, Debasish B, Intracranial necrotizing granuloma which is caused by *Cladophialophora bantiana*. *Neurol India* 2005; 53: 335–6.
- [37] Jayakeerthi SR, Dias M, Nagarathna S, Brain abscess due to *Cladophialophora bantiana*. *Indian J Med Microbiol* 2004; 22: 193–5.
- [38] Sood P, Dogra V, Thakur A, Mishra B, *Brain abscess due to Xylohypha bantiana*. *Scand J Infect Dis* 2000; 32: 708–09.
- [39] George IA, Mathews MS, Karthik R, John L, Sundar A, Abraham OC, Joseph V, et al Fatal cerebral abscess which is caused by *Cladophialophora bantiana*. *JAPI* June 2008; 56: 470-2.
- [40] Menon S, Bharadwaj R, Chowdhary A, Kaundinya DV, Palande DA. Current epidemiology of intracranial abscesses: a prospective 5 year study. *Journal of Medical Microbiology* 2008; 57: 1259–68.
- [41] Lakshmi V, Padmasri C, Umabala P, Sundaram C, Panigrahi M. Cerebral phaeohyphomycosis due to *Cladophialophora bantiana*. *IJMM* 2008; 392-5
- [42] Kamalapur MG, Patil PB, Joshi SK, Satish M, Patil SH, Ajantha GS, et al. The role of magnetic resonance imaging in distinguishing the fungal from the non-fungal multiple brain abscesses. *Egypt J Radiol Nucl Med*. In press 2011.
- [43] Vermes A, Guchelaar HJ, Dankert J.. Flucytosine: a review of its pharmacology, clinical indications, pharmacokinetics, toxicity and drug interactions. *J. Antimicrob. Chemother.* 2000; 46:171–9.
- [44] Johnson EM, Szekeley A, Warnock DW. In-vitro activity of voriconazole, itraconazole and amphotericin B against filamentous fungi. *J Antimicrobial Chemotherapy* 1998; 42: 741-5.
- [45] Lyons MK, Blair JE, Leslie KO. Successful treatment with voriconazole of fungal cerebral abscess due to *Cladophialophora bantiana*. *Clin Neurol Neurosurg* 2005; 107: 53–4.
- [46] Fica A, Diaz MC, Luppi M, . Unsuccessful treatment with voriconazole of a brain abscess due to *Cladophialophora bantiana*. *Scand J Infect Dis* 2003;35: 892–3.
- [47] Al-Abdely HM, Najwar LK, Bocanegra R, Graybill JR. Antifungal therapy of experimental cerebral phaeohyphomycosis due to *Cladophialophora bantiana*. *Antimicrobial Agents Chemotherapy* 2005; 49: p. 1701-7.

**AUTHOR(S):**

1. Dr. Ganavalli S. Ajantha
2. Dr. Raghavendra D. Kulkarni

**PARTICULARS OF CONTRIBUTORS:**

1. Corresponding Author
2. MBBS, MD (Microbiology), Associate Professor,  
Department of Microbiology, SDM College of Medical  
Sciences & Hospital, Sattur, Dharwad -580 009, India
3. MBBS, MD (Microbiology), Professor and Head,  
Department of Microbiology, SDM College of Medical  
Sciences & Hospital, Sattur, Dharwad -580 009, India

**NAME, ADDRESS, TELEPHONE, E-MAIL ID OF THE  
CORRESPONDING AUTHOR:**

Ajantha GS,  
Department of Microbiology,  
SDM College of Medical Sciences & Hospital, Sattur,  
Dharwad -580 009 (Karnataka State, India)  
Email: [ajju\\_dwd@rediffmail.com](mailto:ajju_dwd@rediffmail.com), [ajanthagaganavalli@gmail.com](mailto:ajanthagaganavalli@gmail.com)

**DECLARATION ON COMPETING INTERESTS:**

No competing Interests.

Date of Submission: **Aug 12, 2011**

Date of per review: **Sep 15, 2011**

Date of acceptance: **Sep 17, 2011**

Date of Publishing: **Nov 11, 2011**