

SPECTRUM OF RADIOGRAPHIC MANIFESTATIONS IN RHEUMATIC HEART DISEASE

Aman Gupta, Chandrajeet Yadav, Somya Gupta, Abhishek Dwivedi

1. Professor & Head. Department of Radio diagnosis, SAIMS Medical College & PG Institute, Indore.
2. Assistant Professor. Department of Radio diagnosis, SAIMS Medical College & PG Institute, Indore.
3. Resident. Department of Radio diagnosis, SAIMS Medical College & PG Institute, Indore.
4. Resident. Department of Radio diagnosis, SAIMS Medical College & PG Institute, Indore.

CORRESPONDING AUTHOR

Dr. Aman Gupta,
201, Dilpasand Avenue,
5/2, Manorama Ganj,
Indore-452001,(M.P.) .
E-mail: aman_sono@yahoo.co.in
Ph: 0091 9827010206

ABSTRACT: Acute rheumatic fever and its sequelae, Rheumatic Heart Disease continues to be a major health problem in our country. Lack of specific criteria had lead to diagnostic chaos until the Jones Criteria in 1944. Despite Jones criteria and four revision and modifications Acute rheumatic fever is often under diagnosed. Modern facility like radiography and ECHO is not included in Jones criteria.

Chest radiograph is an important part of the evaluation of patients with disease. Medical and Surgical treatment of mitral valve disease is particularly successful early in the course of the disease; therefore detection at initial presentation is of considerable importance. Characteristic changes in cardiac contour, are helpful in confirming the radiographic diagnosis in affected patients. The pulmonary parenchymal manifestations are the result of either pulmonary venous hypertension in mitral stenosis or abnormal regurgitation into pulmonary veins in mitral insufficiency.

In this study we discuss and illustrate the imaging appearances of a variety of cardiac and pulmonary parenchymal manifestations of Rheumatic Heart Disease including selective chamber enlargement, pulmonary venous cephalization, pulmonary edema, diffuse alveolar hemorrhage, haemosiderosis and ossification.

Familiarity with the gamut's of cardiac and pulmonary findings in patients with rheumatic heart disease, is crucial for early and rapid diagnosis and optimal patient care; thereby, decreasing patients morbidity and mortality.

KEYWORDS: rheumatic heart disease, acute rheumatic fever.

MESH TERMS: RHD, ARF, MS.

INTRODUCTION: Acute rheumatic fever (ARF) and its long term sequelae, Rheumatic Heart Disease (RHD) is a major health problem in children, adolescents and young adults¹. Despite the tremendous progress made in cardiology, the menace of morbidity and mortality due to acute rheumatic fever and its consequences remain very high in India². Precise diagnosis of acute rheumatic fever has presented problems since Hippocrates, who provided the first written description of arthritis in man in 400 BC³. Lack of specific criteria had led to diagnostic chaos until the Jones criteria in 1944⁴. Despite the Jones criteria and four revisions and modifications⁵⁻⁷, ARF is either under diagnosed leading to nearly 50% of established RHD not receiving

REVIEW ARTICLE

prophylaxis or over diagnosed by depending on traditional characteristic auscultatory findings for diagnosing carditis.

Unfortunately, modern facilities like radiography and echocardiography are not included in Jones criteria. Early diagnosis of ARF, though difficult, but is very important to prevent the serious consequences in young.

DISEASE BURDEN: In India, rheumatic fever is endemic and remains one of the major causes of cardiovascular disease, accounting for nearly 25-45% of the acquired heart disease. The annual incidence of rheumatic fever is 100-200 times greater than that observed in developed countries and fluctuates between 100-200 per 1,00,000 children of school age⁸. India is in the phase of 'epidemiological transition'. On one hand there is a substantial burden due to RHD for the treatment of which enormous money is spent, on the other hand the government resources are scarce to treat and prevent the disease. Not only the cost of treatment is phenomenal, the morbidity and mortality is also enormous. Hence "Prevention is better than cure" is very apt for rheumatic fever.

EPIDEMIOLOGY: The prevalence of ARF/RHD in India has been reported to be varying from very infrequent to very high levels depending upon the source of information e.g., Registrar General, population sources, and hospital admissions. Recent data from India suggest that a large number of cases of ARF/RHD are still seen frequently in young children under the age of 10 years⁹. Though lately, many published studies and ICMR data are suggestive of decline in disease prevalence in the society. Recently, one of the published studies, entirely based on echocardiography has refuted the previous claims by showing very high prevalence of RHD¹⁰. On the contrary, a large study from the Uttar Pradesh, so called BIMAROU states (Bihar, Madhya Pradesh, Rajasthan, Orissa and Uttar Pradesh) screening 5000 school going children with echocardiography had shown relatively low incidence (0.5/1000)¹¹. India has its share of vulnerable population afflicted with ARF and RHD like any other developing countries. If the current data from school centric studies are to be believed, there is an encouraging trend towards decline in the prevalence (< 1/ 1000)^{11,12-14}.

P.Yadav,P.Joshi et al in there study showed prevalence of RF and RHD in Malwa region in school children aged 5 to 16 years to be 0.73 per 1000¹⁵.

Rajeev Bhardwaj et al in there study Prevalence of Rheumatic Fever and Rheumatic Heart Disease in Rural population of Himachal found prevalence to be 5.8/1000¹⁶.

PATHOPHYSIOLOGY: Rheumatic fever develops in some children and adolescents following pharyngitis with group A beta-hemolytic Streptococcus (ie, Streptococcus pyogenes). The organisms attach to the epithelial cells of the upper respiratory tract and produce a battery of enzymes allowing them to damage and invade human tissues. After an incubation period of 2-4 days, the invading organisms elicit an acute inflammatory response with 3-5 days of sore throat, fever, malaise, headache, and an elevated leukocyte count.

In 0.3-3% of cases, infection leads to rheumatic fever several weeks after the sore throat has resolved. Only infections of the pharynx initiate or reactivate rheumatic fever. The organism spreads by direct contact with oral or respiratory secretions, and spread is enhanced by crowded living conditions. Patients remain infected for weeks after symptomatic resolution of pharyngitis and may serve as a reservoir for infecting others. Penicillin treatment shortens the

REVIEW ARTICLE

clinical course of streptococcal pharyngitis and, more importantly, is effective in decreasing the incidence of major sequelae.

Acute rheumatic heart disease often produces a pancarditis characterized by endocarditis, myocarditis, and pericarditis. Endocarditis is manifested as valve insufficiency. The mitral valve is most commonly and severely affected (65-70% of patients), and the aortic valve is second in frequency (25%). The tricuspid valve is deformed in only 10% of patients and is almost always associated with mitral and aortic lesions. The pulmonary valve is rarely affected. Severe valve insufficiency during the acute phase may result in congestive heart failure and even death (1% of patients). Whether myocardial dysfunction during acute rheumatic fever is primarily related to myocarditis or is secondary to congestive heart failure from severe valve insufficiency is not known. Pericarditis, when present, rarely affects cardiac function or results in constrictive pericarditis.

Chronic manifestations due to residual and progressive valve deformity occur in 9-39% of adults with previous rheumatic heart disease. Fusion of the valve apparatus resulting in stenosis or a combination of stenosis and insufficiency develops 2-10 years after an episode of acute rheumatic fever, and recurrent episodes may cause progressive damage to the valves.

A diagnosis of rheumatic heart disease is made after confirming antecedent rheumatic fever. The modified Jones criteria (revised in 1992) provide guidelines for the diagnosis of rheumatic fever⁵.

The Jones criteria require the presence of 2 major or 1 major and 2 minor criteria for the diagnosis of rheumatic fever. The major diagnostic criteria include carditis, polyarthritis, chorea, subcutaneous nodules, and erythema marginatum. The minor diagnostic criteria include fever, arthralgia, prolonged PR interval on ECG, elevated acute phase reactants (increased erythrocyte sedimentation rate [ESR]), presence of C-reactive protein, and leukocytosis.

Additional evidence of previous group A streptococcal pharyngitis is required to diagnose rheumatic fever. One of the following must be present:

Positive throat culture or rapid streptococcal antigen test result

Elevated or rising streptococcal antibody titer

History of previous rheumatic fever or rheumatic heart disease

These criteria are not absolute; the diagnosis of rheumatic fever can be made in a patient with chorea alone if the patient has had documented group A streptococcal pharyngitis.

After a diagnosis of rheumatic fever is made, symptoms consistent with heart failure, such as difficulty breathing, exercise intolerance, and a rapid heart rate out of proportion to fever, may be indications of carditis and rheumatic heart disease.

PITFALLS IN JONES CRITERIA:⁸ The precise diagnosis of carditis in ARF is eluding the clinician because of many pitfalls in Jones criteria.

1. It is difficult to diagnose ARF when carditis is the only manifestation of the disease particularly in a recurrence.
2. When patient has sub clinical carditis the clinicians fail to detect clinically
3. Clinically apparent carditis is present but supportive minor criteria are not fulfilled¹⁷.

REVIEW ARTICLE

4. When previous cardiac status is unknown it is not possible to know in a new case whether the findings are due to acute carditis or it is recrudescence or it is established old case of RHD.

5. In cases of polyarthralgia, which is a minor criterion, if the patient is neglected and not evaluated for ARF, they would go undiagnosed, and could end up with RHD, allegedly without any past history of ARF, as the patient and the parents would have long forgotten the joint pain.

Due to these lacunae in Jones criteria the diagnosis of 'carditis' in ARF is eluding the clinicians. Modern imaging modalities such as radiography and echocardiography are not included in Jones Criteria. Because of the symptoms consistent with heart failure, such as dyspnoea, exercise intolerance, tachycardia; chest radiography is often the first investigation for which these patients are referred, detection of RHD at initial presentation is of considerable importance. Clinicians must be aware with the characteristic changes in cardiac contour and various pulmonary parenchymal manifestations of the disease.

RADIOGRAPHIC FINDINGS: Mitral valve is most common and severely affected in R.H.D. Mitral stenosis develops by fusion of leaflet commissures, thickening of valve leaflets and shortening, thickening and adherence of chordae tendineae.

Plain film signs are those of "selective left atrial enlargement". Enlargement of left atrial appendage is almost universally present as part of left atrial enlargement and always suggest rheumatic mitral disease. This chamber may be the only one affected, atleast at the early stage of this valvular lesion. EARLY ROENTGENOLOGIC recognition of left atrial enlargement is desirable, as diagnosis may depend upon this knowledge. The cardiac configuration in rheumatic mitral stenosis "mitral configuration" is, as a rule, sufficiently distinct in conventional roentgenograms to suggest the diagnosis. In the early stages of mitral valvular disease, however, the size the heart may appear normal on the postero-anterior roentgenogram.

The left atrial appendage is the only portion of the left atrium that forms part of the left border of the heart. On PA radiographs it occupies the portion of the left heart border between the main pulmonary artery segment and the superior portion of the left ventricular contour. When left atrial pressure and volume are normal, this segment of the left heart border is concave. Early or mild enlargement of the left atrium may be detected as enlargement of the left atrial appendage with 'straightening of this segment of the left heart border'(Fig.1).With continued enlargement, this segment will become convex.As the left atrium moves towards the right side resulting in 'double contouring of the right heart border'(Fig. 2). The right and left atrium can be differentiated because the left atrial shadow is usually less dense and touches the diaphragm.

Other findings which can suggest LA enlargement include 'posterior esophageal displacement' on barium swallow. Minor degrees of left atrial enlargement may conceivably escape detection, if the barium swallow is given with the patient erect, the volume of the heart being decreased by lesser venous return. In the recumbent position, however, the left atrium, along with the other chambers, is filled with a greater amount of blood and, as a result of gravity, comes into closer relation with the esophagus. This position may, therefore, provide a possibility of demonstrating even minor degrees of atrial enlargement. Such enlargement would be visualized by the localized posterior displacement of the barium-filled esophagus(Fig. 3) in the recumbent right anterior oblique position¹⁸.

Secondary to left atrial cephalad enlargement, there is elevation of the left main stem bronchus, causing 'widening of the carinal angle' (n=60-75°)(Fig. 4).¹⁹

REVIEW ARTICLE

As the enlarged left atrium pushes the heart anteriorly with subsequent dilatation of the right ventricle, there is 'obliteration of the retrosternal space' Enlargement of the right ventricle due to back pressure lifts the apex of the heart away from the diaphragm and causes 'cardiomegaly', which is a three-chamber phenomenon excluding the left ventricle(Fig. 5).

In cases of long-standing stenosis, the 'LA wall may calcify'. Mitral valve calcification is only seen 10% of cases (Note: Calcification of the mitral valve annulus does not indicate mitral stenosis).

Involvement of Aortic valve will lead to back pressure on left ventricle resulting in 'left ventricular enlargement'.

Multi-valvular disease with involvement of tricuspid valve shows enlargement of right atrium bulging the heart shadow to the right.(Right atrial enlargement can usually be distinguished from left atrial enlargement by the entry of I.V.C.) leading to 'gross cardiomegaly'(Fig. 6).

The pulmonary parenchymal manifestations of mitral valve disease relate to pulmonary vascular engorgement. The findings are frequently non-specific but have characteristic appearances that facilitate the diagnosis. The increased left ventricular filling pressure in M.S. leads to compensatory dilatation of left atrium and pulmonary venous hypertension on frontal chest visible as 'upper lobe blood diversion' or 'pulmonary vascular cephalization'(Fig. 7).Eventually postcapillary pulmonary arterial hypertension develops which on radiograph can be appreciated as 'enlarged main and central pulmonary arteries with dilated descending branch of the right pulmonary artery (upto 16mm in men and 15mm in women)²⁰ and peripheral pruning'(Fig. 8).Chronically raised left atrial pressure leads to right ventricular failure.

When left ventricular filling is compromised, cardiac output is diminished and signs of interstitial pulmonary oedema including 'septal lines' are frequently visible(Fig. 9).Patients with M.S. are prone to develop acute pulmonary oedema after volume overload which on radiographs give rise to characteristic para-hilar alveolar shadowing with air-bronchograms, 'bat-wing appearance'(Fig.10).

Patients with mitral stenosis may present with hemoptysis and 'diffuse alveolar hemorrhage' Hemorrhage early in the course of disease may be related to rupture of microvasculature or later in the disease to abnormally engorged sub-mucosal bronchial veins that are exposed to elevated pressures through the anastomoses with the pulmonary veins. Radiographic findings consist of diffuse, confluent acinar or ground-glass areas of increased opacity, often sparing the peripheral parenchyma and creating the so called "window frame" effect. Radiographic differentiation of diffuse alveolar hemorrhage from hydrostatic pulmonary edema can be difficult, although the presence of hemoptysis and air-bronchograms may help.

Accumulation of hemosiderin in alveolar, lobular and perivascular interstitium, filling of alveoli with hemosiderin-laden macrophages and fibrosis leads to pulmonary haemosiderosis in chronic M.S.(Fig. 11). At radiography haemosiderosis is seen in 10-25% of patients with M.S.²¹. It is characterized by small (1-3mm diameter), ill-defined nodules or by coarse reticular areas of increased opacity in middle and lower lung regions²².

A rare late sequel that is virtually pathognomonic for chronic M.S. is parenchymal ossification, which manifest radiographically as densely calcified, 1-5mm nodules, mainly in middle and lower lungs, with a tendency for confluence.

REVIEW ARTICLE

The prevalence of bone formation ranges from 3% to 13% in reported series and may not always correlate with the degree of pulmonary hypertension or underlying haemosiderosis^{23,24}.

CONCLUSION: ARF and its sequelae RHD continue to be a major health problem in children and adolescents. The menace of morbidity and mortality due to ARF remains very high in our country, hence early diagnosis of the disease is important. Characteristic changes in cardiac contour and various pulmonary parenchymal manifestations are frequently seen in rheumatic carditis. These changes usually facilitate the diagnosis of disease. Familiarity with gamut's of cardiac and pulmonary findings in the patients with RHD is crucial for rapid diagnosis and optimal patient care.

REFERENCES:

1. Sanyal SK, Thapar MK, Ahmed SH, Hooja V, Tewari P. The initial attack of acute rheumatic fever during childhood in North India; a prospective study of the clinical profile. *Circulation*.1974;49:7-12.
2. Sanyal SK, Berry AM, Duggal S, Hooja V, Ghosh S. Squeal of the initial attack of acute rheumatic fever in children from north India. A prospective 5-year follow-up study. *Circulation*.1982;65: 375-9.
3. Hippocrates. The genuine works of Hippocrates (translated form Greek by Francis Adams) New York. Wood.1986:192-273.
4. Jones TD: Diagnosis of rheumatic fever. *JAMA*.1944;126: 481- 484.
5. Ad hoc committee on Rheumatic Fever and Bacterial Endocarditis of the American Heart Association. Jones criteria (revised) for guidance in the diagnosis of Rheumatic Fever. *Circulation*.1965; 32: 664-668.
6. Committee on Rheumatic Fever and Bacterial Endocarditis of the American Heart Association. Jones criteria (revised) for guidance in the diagnosis of rheumatic fever. *Circulation*.1984;69: 203A- 208A.
7. Special writing group of the Committee on Rheumatic fever, Endocarditis and Kawasaki disease of the Council of Cardiovascular disease in the young of the American Heart Association. Guidelines for the diagnosis of rheumatic fever: Jones criteria: 1992 update. *JAMA*.1992;268: 2069-2073.
8. Acute Rheumatic Fever: Current Scenario in India, IB Vijayalakshmi;Bengaluru;Medicine Update.2012;22
9. Mishra TK, Acute Rheumatic Fever and Rheumatic Heart Disease: Current Scenario. *Indian Academy of Clinical Medicine* 2007; 8:324-30.
10. Bhava M., Panwar S. Beniwal RI, Panwar RB. High prevalence of rheumatic heart disease detected by echocardiography in school children. *Echocardiography*.2010;27: 448-453.
11. Mishra M, Mittal M, Singh RK, Verma AM, Rai R. et al. Prevalence of rheumatic heart disease in school going children of eastern Uttar Pradesh. *Indian Heart Journal*.2007;59: 42-43.
12. Lalchandani A, Kumar HRP, Alam SM. Prevalence of rheumatic fever and rheumatic heart disease in rural and urban school children of district Kanpur. *Indian Heart Journal*.2000;50:672.
13. Kumar RK, Mary P, Paul TF. RHD in India: Are we ready to shift from secondary prophylaxis to vaccinating high risk children? *Current Science*.2009;97:397-404.
14. Bharani.A Prevalence of Rheumatic Fever/Rheumatic Heart Disease in India: Lessons From Active Surveillance and A Passive Registry. *J Am Coll Cardiol*.2010;55:A151.E1415

REVIEW ARTICLE

15. P. Yadav, P. Joshi, J. Gupta, D. Joseph, P. Sakhi .Prevalance of rheumatic feverand rheumatic heart disease in school children in malwa region of MP.National Journal of Community Medicine.2010;1(2).
16. Rajeev Bhardwaj, Arvind Kandoria et al .Prevalence of Rheumatic Fever and Rheumatic Heart Disease in Rural Population of Himachal- A Population Based Study;JAPI.2012 May.60.
17. Narula J, Chopra P, Talwar KK, Vasani RS, Reddy KS, Tandon R, Bhatia ML, Southern JF. Does endomyocardial biopsies aid in the diagnosis of acute rheumatic carditis?.Circulation.1993; 88:2198 -2205.
18. S. Schorr; F. Dreyfuss et al.The Recumbent Esophagogram;An X-Ray Method for Early Detection of Left Atrial Enlargement.1951 August. Radiology;57:208-213.
19. David Sutton.Textbook of radiology and imaging ;7th ed. ;Elsevier Churchill Livingstone;1:05.
20. David Sutton.Textbook of radiology and imaging ;7th ed. ;Elsevier Churchill Livingstone;1:287.
21. Steiner RE,Goodwin J. Fac.Some observations on mitral valve disease.Radiology.1954;5:167-177.
22. Fraser RD,Pare PD; et al.Diagnosis of diseases of chest;3rd ed.; Philadelphia:Saunders.1989;2
23. Galloway RW,Epstein EJ,Coulshed N. Pulmonary ossific nodules of mitral valve disease.BR Heart J.1961.
24. Kevin wolley,Paul stark.Pulmonary parenchymal manifestations of mitral valve disease.Radiographis.1999.19(4).

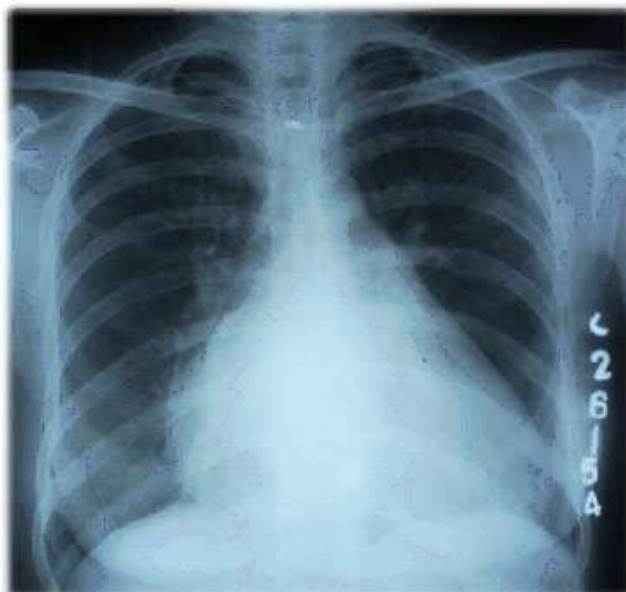


FIGURE 1: RADIOGRAPH OF CHEST PA VIEW SHOWING 'STRAIGHTENING OF LEFT HEART BORDER' DUE TO ENLARGEMENT OF LEFT ATRIAL APPENDAGE.

REVIEW ARTICLE

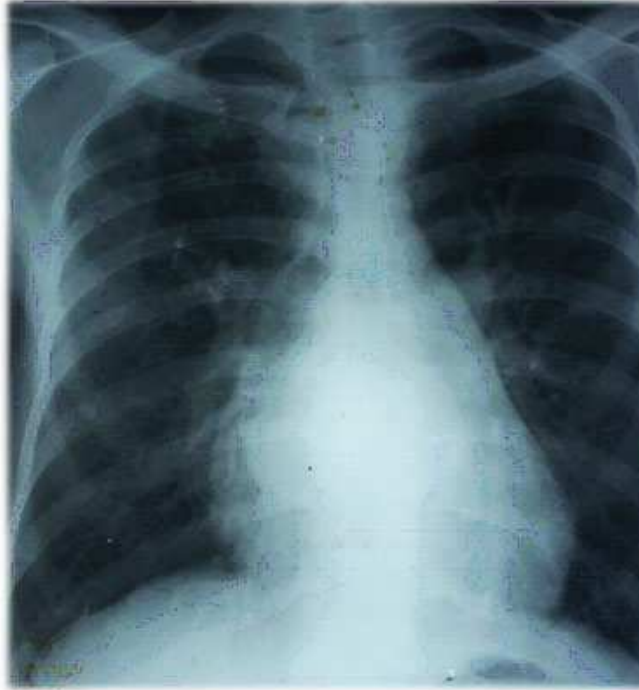

FIG. 2: RADIOGRAPH OF CHEST PA VIEW SHOWING 'DOUBLE CONTOURING' OF THE RIGHT HEART BORDER.

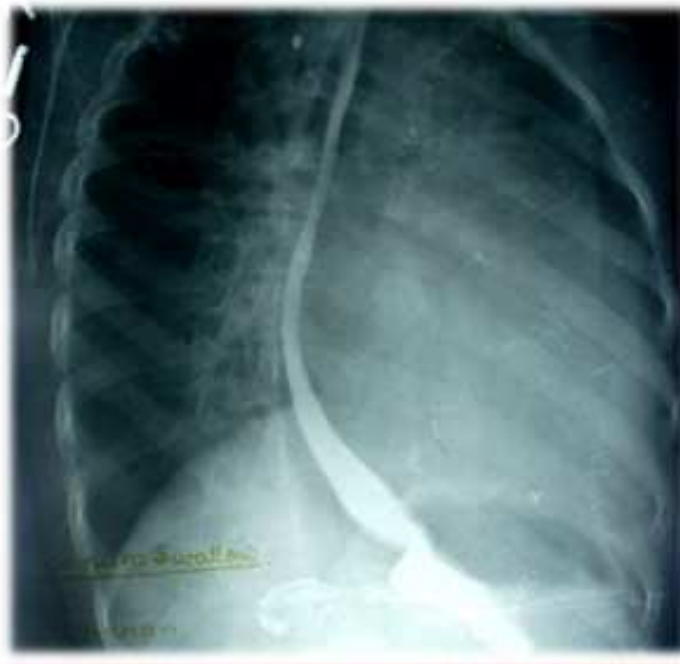

Fig.3: BARIUM SWALLOW EXAMINATION SHOWING POSTERIOR ESOPHAGEAL DISPLACEMENT WITH SMOOTH CONCAVE IMPRESSION ON ANTERIOR BORDER OF ESOPHAGUS DUE TO LEFT ATRIAL ENLARGEMENT.

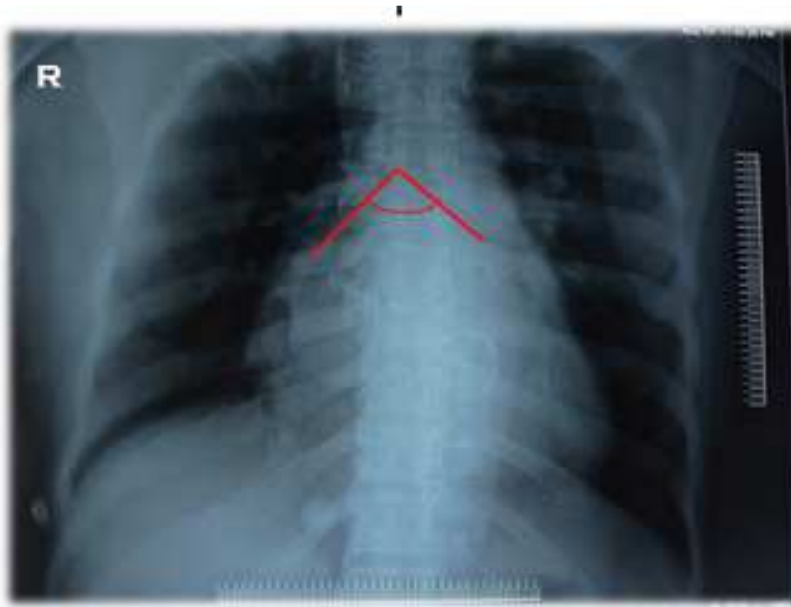


FIG. 4: RADIOGRAPH OF CHEST PA VIEW SHOWING WIDENED CARINAL ANGLE, 85° (NORMAL CARINAL ANGLE IS BETWEEN $60-75^{\circ}$)

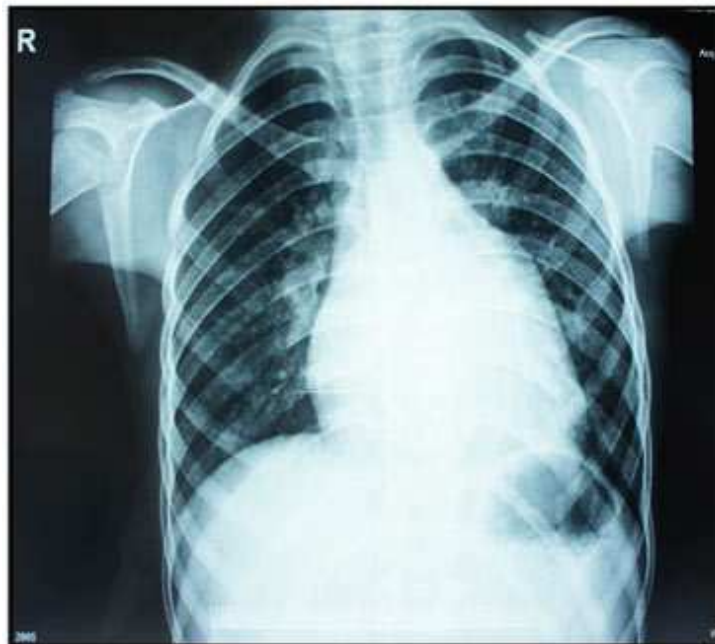

FIG. 5: RADIOGRAPH OF CHEST PA VIEW SHOWING CARDIOMEGALY WITH ENLARGEMENT OF RIGHT VENTRICLE DUE TO BACK PRESSURE.

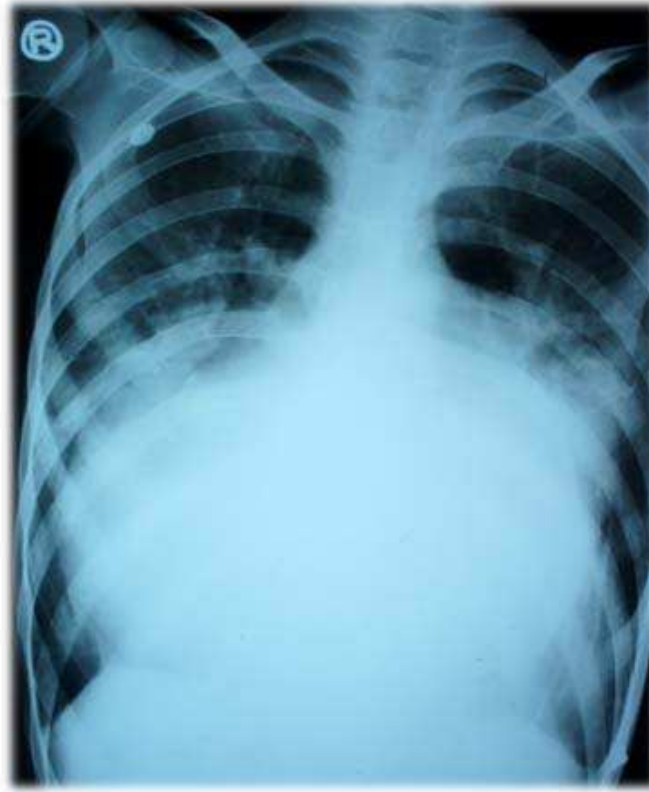

FIG. 6: RADIOGRAPH OF CHEST PA VIEW SHOWING GROSS CARDIOMEGALY WITH PLETHORIC LUNG FIELDS DUE TO MULTI-VALVULAR INVOLVEMENT.

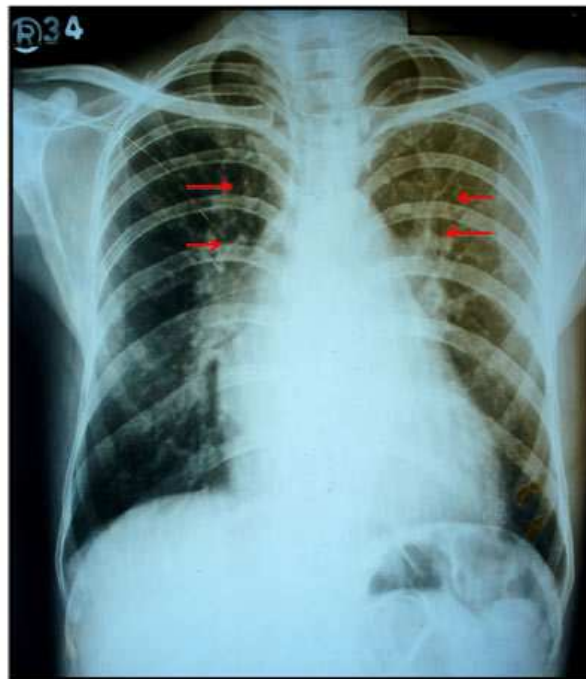


FIG. 7: RADIOGRAPH OF CHEST PA VIEW SHOWING FEATURES OF PULMONARY VENOUS HYPERTENSION AS 'PULMONARY VASCULAR CEPHALIZATION' .

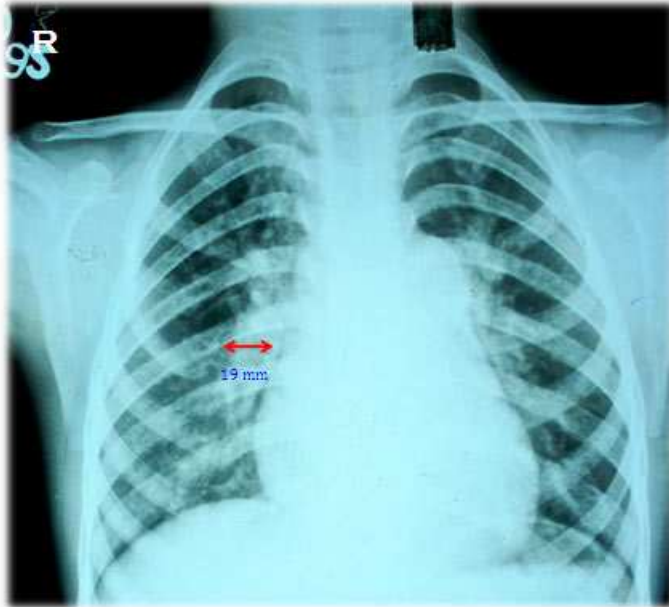


FIG.8: RADIOGRAPH OF CHEST PA VIEW SHOWING FEATURES OF PULMONARY ARTERIAL HYPERTENSION APPRECIATED AS ENLARGED MAIN AND CENTRAL PULMONARY ARTERIES WITH PERIPHERAL PRUNING AND DIALATATION OF DESENDING BRANCH OF RIGHT PULMONARY ARTERY(19mm).

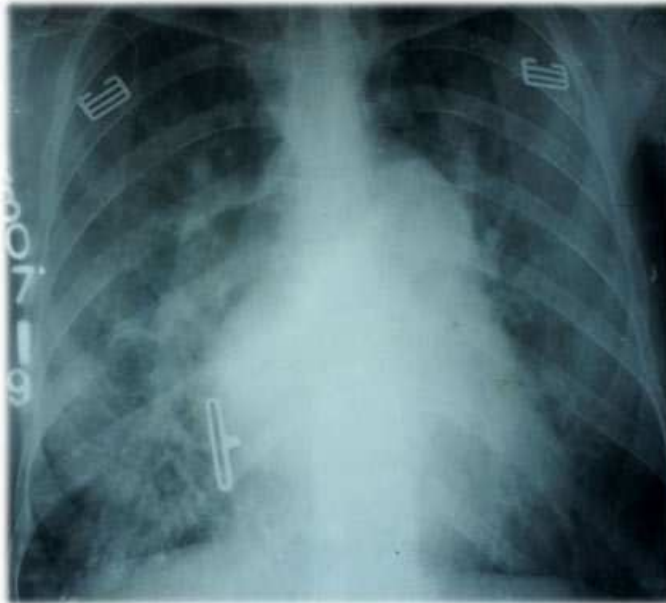


FIG. 9 :RADIOGRAPH OF CHEST PA VIEW SHOWING SIGNS OF INTERSTITIAL PULMONARY ODEMA WITH SEPTAL LINES (KERLEY-B LINES) AT BASES.

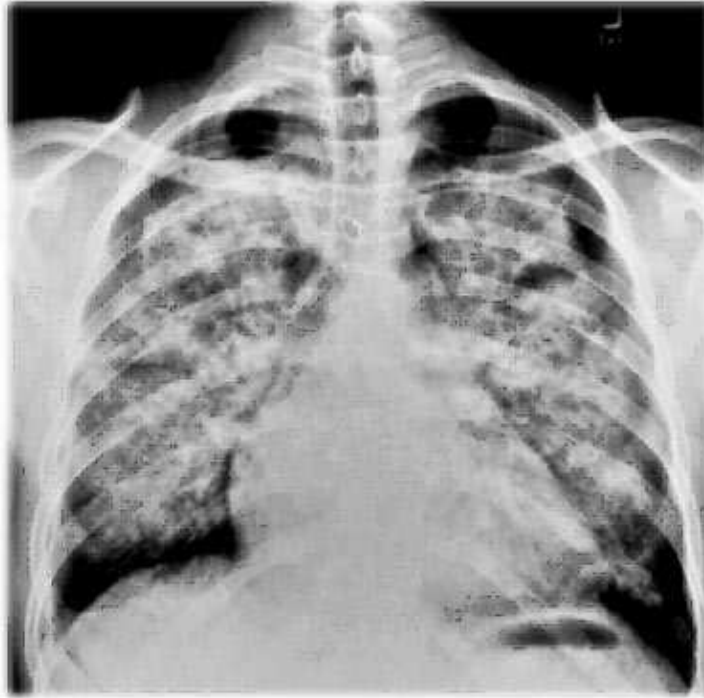


FIG. 10: RADIOGRAPH OF CHEST PA VIEW SHOWING PARA-HILAR ALVEOLAR SHADOWING WITH AIR BRONCHOGRAMS GIVING RISE TO CHARACTERISTIC 'BAT-WING APPEARANCE' DUE TO ACUTE PULMONARY OEDEMA.

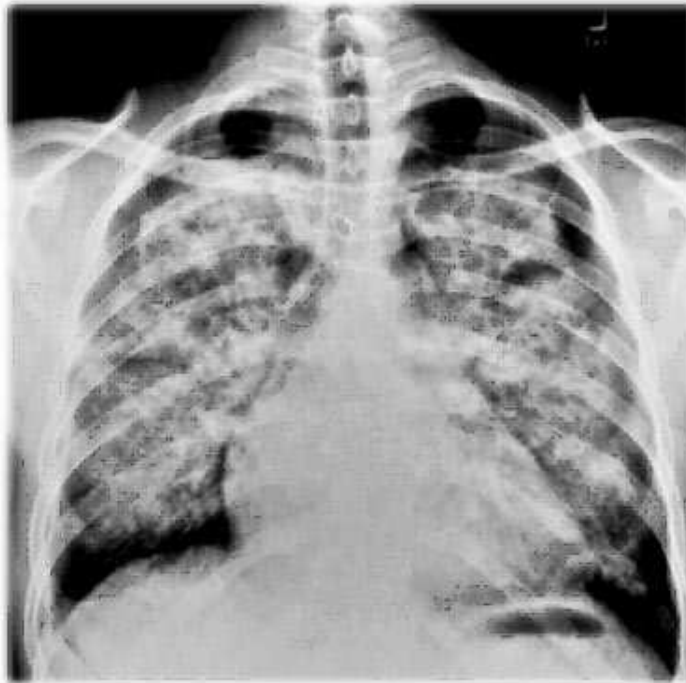


FIG.11: RADIOGRAPH OF CHEST PA VIEW SHOWING COARSE RETICULAR AREAS OF INCREASED OPACITY PREDOMINANTLY IN MID AND LOWER ZONES SUGGESTING PULMONARY HAEMOSIDEROSIS.