

CASE STUDY

THE IMPORTANCE OF CBCT IN THE DIAGNOSIS OF CEMENTOBLASTOMA: A RARE ODONTOGENIC TUMOR

***¹Dr. Prashant Nahar, ¹Dr. Deeptanshu Daga, ¹Dr. Mohit Pal Singh, ¹Dr. Bhuvaneshwari, S. and ²Dr. Bipin A. Ruva Annawar**

¹Department of OMDR, Pacific Dental College & Hospital, India

²Department of OMFS, Pacific Dental College & Hospital, India

ARTICLE INFO

Article History:

Received 17th October, 2017

Received in revised form

26th November, 2017

Accepted 21st December, 2017

Published online 19th January, 2018

ABSTRACT

Cementoblastoma is a true cemental neoplasm characterized by proliferation of cementum-like tissue and in almost all cases tends to be associated with an erupted permanent tooth, most often the first molar. The lesion appears as a well defined bulbous periapical radiopacity with a well-defined radiolucent band with intact crown, external resorption of its roots and amorphous pattern of the trabeculae. Because of the characteristics of cementoblastoma, the CBCT images are a resource of fundamental importance for evaluation of pathognomonic features.

Key words:

Cementoblastoma, CBCT,
Radiolucent band, Periapical pathosis.

Copyright © 2018, Dr. Prashant Nahar et al. This is an open access article distributed under the Creative Commons Attribution License, which permits unrestricted use, distribution, and reproduction in any medium, provided the original work is properly cited.

Citation: Dr. Prashant Nahar, Dr. Deeptanshu Daga, Dr. Mohit Pal Singh, Dr. Bhuvaneshwari, S. and Dr. Bipin A. Ruva Annawar, 2018. "The importance of cbct in the diagnosis of cementoblastoma: A rare odontogenic tumor", *International Journal of Current Research*, 10, (01), 64076-64079.

INTRODUCTION

Benign cementoblastoma is a rare odontogenic neoplasm of mesenchymal origin. The World Health Organization has classified benign cementoblastoma and cementifying fibroma as the only true cemental neoplasms that represents less than 1% of all odontogenic tumours (Milani *et al.*, 2012). The benign cementoblastoma should be distinguished from non-neoplastic processes that may also produce a radiopaque lesion around the root apex, such as periapical cemental dysplasia or condensing osteitis. (Bruce R. Pynn *et al.*, 2001) Cementoblastoma is characterized by proliferation of cementum-like tissue and in almost all cases tends to be associated with an erupted permanent tooth, most often the first molar (Amaral *et al.*, 2012; Lemberg *et al.*, 2007). We present a case of a large cementoblastoma that affected the left mandibular body.

Case Report

A 26 years old male patient was referred to the Department of Oral Medicine, Diagnosis and Radiology with the chief complaint of pain and gradually increasing swelling since the past 3 months.

***Corresponding author: Dr. Prashant Nahar,**
Department of OMDR, Pacific Dental College & Hospital, India.

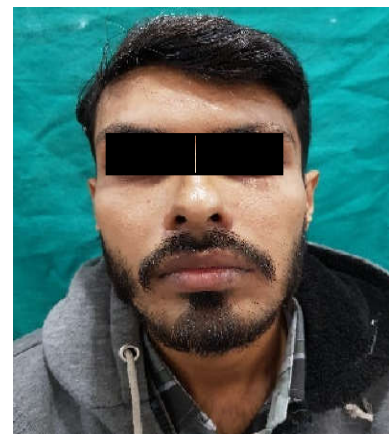

Fig. 1. Front Profile of patient

According to the patient, he experienced mild pain in the left side of the lower jaw posterior tooth region about 6 months ago followed by a swelling which was noticeable since the last 3 months with gradual increase in size leading to mild facial asymmetry accompanied with mild pain in the tooth which aggravated on chewing. On clinical examination, the patient presented with facial asymmetry on the left lower one-third of the face due to a bony hard, non-tender swelling. (Fig.1) On intra-oral examination 36 was tender on percussion with grade 1 mobility associated with an irregular, hard, non-tender

swelling on its buccal aspect with vestibular obliteration. The swelling extended from the distal aspect of 35 to the mesial of 37 (Fig. 2 &3). Electric pulp vitality testing revealed non-vital 36.

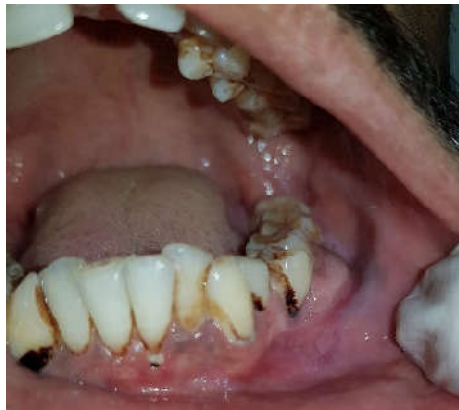
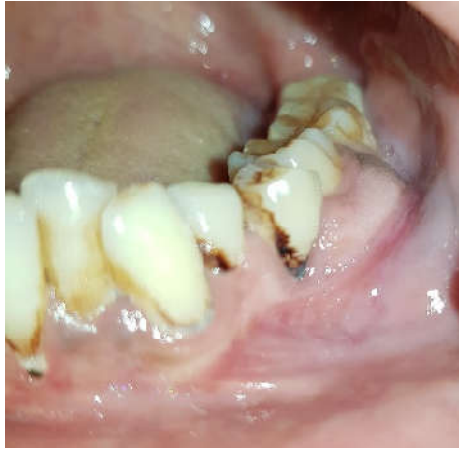
Fig. 2&3. Intra Oral appearance of swelling

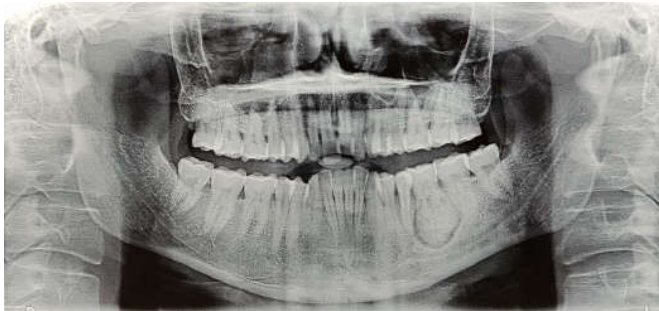

Fig. 4. Initial OPG

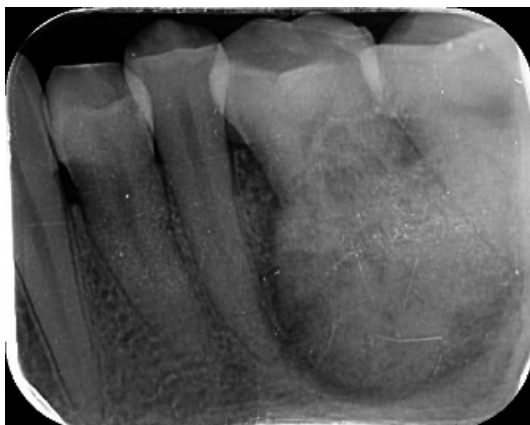

Fig. 5. IOPA

IOPA (Fig. 5) and OPG (Fig. 4) revealed intact coronal morphology of 36 with a well-defined peri-apical radiopacity surrounded by a radiolucent band associated with root resorption. The lesion was well separated from the mandibular canal.

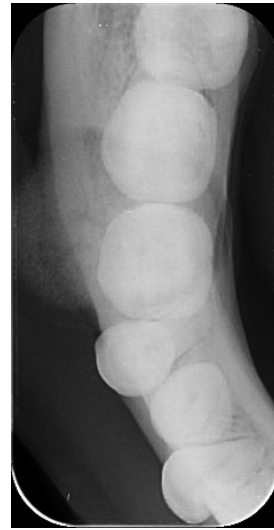

Fig. 6. Cross sectional Occussal

Cross Sectional occlusal radiograph (Fig. 6) revealed a well defined semi-circular radiopaque mass overlying the buccal cortex of 36 with altered trabecular pattern (i.e. ground glass appearance). The lingual cortex revealed no abnormality. Based on these findings a provisional diagnosis of Benign Odontogenic Tumour or Fibrosseous lesion associated with 36 was made. Patient was advised CBCT of the 36 region.

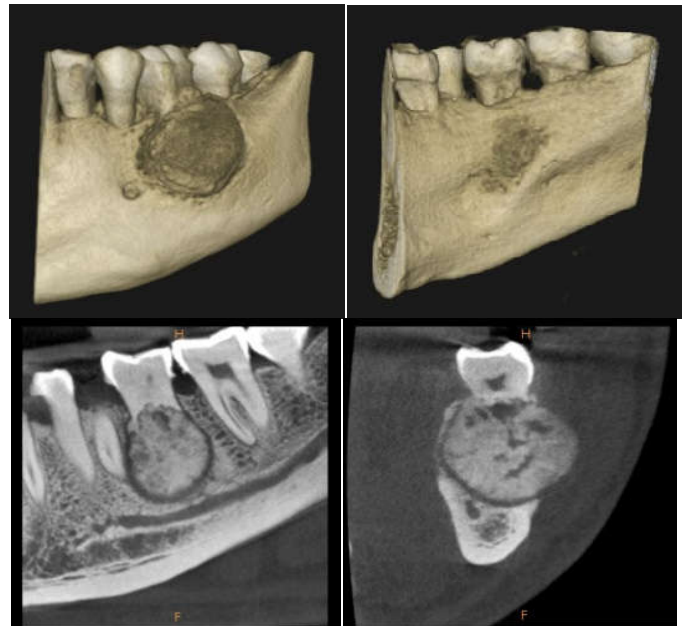


Fig. 7. Only buccal expansion and well separated from mandibular canal

CBCT scan was performed on Carestream 9300C at 5x5 FOV with slice thickness of 0.09mm and spacing of 1 mm. The scans (Fig. 7) revealed a well defined bulbous periapical radiopacity with a well-defined radiolucent band irt 36. The crown of the tooth was intact with external resorption of its roots. The internal structure of the periapical lesion revealed mixed radiodensity with amorphous pattern of the trabeculae.

The lesion had caused erosion/resorption of the buccal cortex and appeared to extrude or extend through it. However, the lingual cortex appeared intact and normal. The lesion extended mesiodistally from the distal aspect of 35 till the mesial aspect of the root of 37. It measured (Fig. 8) 18.7 to 19.4mm buccolingually, 14.1 to 15.8mm mesiodistally and 16.8mm in vertical dimension. The lesion appeared to be well separated from the superior cortex of mandibular canal lying on its inferior aspect.

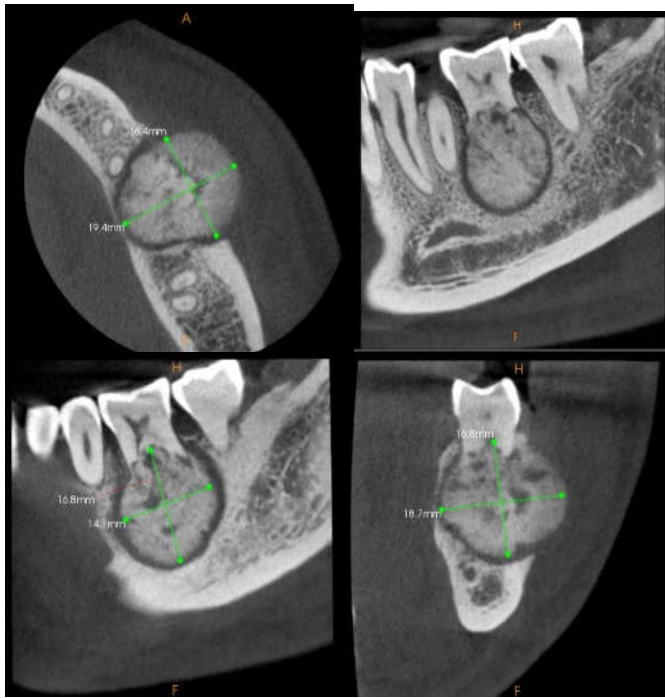


Fig. 8. Axial, Coronal and Sagittal sections

The overall clinical and radiographic features were suggestive of Cementoblastoma irt 36 with a differential diagnosis of PCOD. The patient was referred to the department of OMFS, for opinion and needful treatment where excision of the lesion along with extraction of 36 was performed and the specimen sent for histopathological evaluation. (Fig.9)

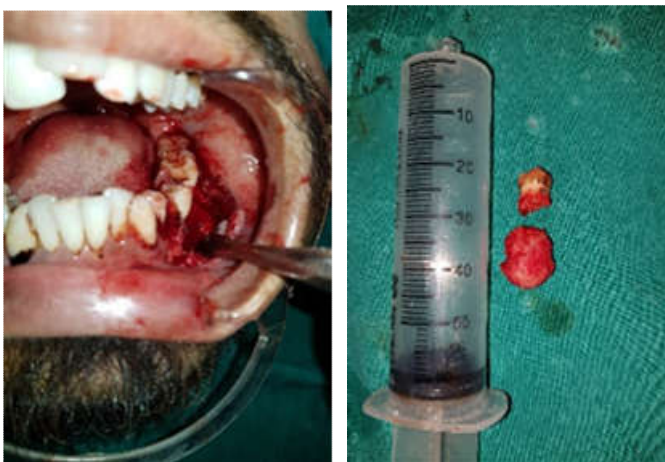

Fig 9. Excision and specimen

The ground section of the lesion (Fig. 10) revealed sheets of cementum like tissue and soft tissue component consisting of fibrillar, vascular and cellular elements.

DISCUSSION

Benign Cementoblastoma most commonly occurs on the posterior region of the mandible and is often attached to the root of an erupted permanent premolar or first molar. On rare occasions, an impacted tooth, multiple teeth or a deciduous tooth may be affected as well. (Armağan Çalışkan *et al.*, 2016) Almost 50% involve the first permanent molar. The neoplasm occurs predominantly in children and young adults, with about 50% arising before the age of 20 years and 75% occurring before the age of 30 years. (Oral and Maxillofacial Pathology 3rd edition -Neville) Pain, tenderness, and swelling are present in most patients with cementoblastoma, although the lesion can be asymptomatic. The involved tooth is vital and often exhibits pain. (Armağan Çalışkan *et al.*, 2016) However in the present case the tooth was non-vital.

Clinical features

Pain and swelling are present in approximately two thirds of reported patients. Although most investigators consider the cementoblastoma to represent a rather innocuous neoplasm, signs of locally aggressive behaviour may be observed, including bony expansion, cortical erosion, displacement of adjacent teeth, envelopment of multiple adjacent teeth, maxillary sinus involvement, and infiltration into the pulp chamber and root canals. (Oral and Maxillofacial Pathology 3rd edition -Neville). The present lesion exhibited erosion of the buccal cortex and extended beyond it to cause clinically perceptible mass irt the buccal vestibule of 36.

Radiographic Features (Textbook of Oral Medicine 2nd edition- Anil Govindrao Ghom)

The lesion normally presents as

- Well defined radiopacities usually attached to the roots of premolars and molars surrounded at the border by a radiolucent halo.
- Appearance—the radiological appearance of the cementoblastoma is highly characteristic, seen as circular radiopaque mass attached to the root of the one or more teeth. A narrow radiolucent zone surrounds the lesion and delineates from adjacent bone.
- Root outline—the outline of the affected root is generally obliterated because of resorption of the root and fusion of the mass to the tooth.
- Internal structure—they are mixed radiolucent radiopaque lesion that may be amorphous or may have wheel-like spoke pattern. Density of cementum obscures the outline of the enveloped root.
- Effect on surrounding structures—the outline of the tooth is obliterated because of resorption of the root and fusion of the mass to the tooth.
- Expansion—occlusal radiograph will demonstrate its expansive nature (Textbook of Oral Medicine 2nd edition- Anil Govindrao Ghom).

Differential Diagnosis

The most common lesion to simulate this appearance is a solitary lesion of Periapical Cemental Osseous Dysplasia. Generally, the band around the cementoblastoma is better defined and uniform than osseous dysplasia. In case of

Periapical cemental dysplasia there is no expansion of the jaws and females are more commonly affected. Also, the overall shape of cementoblastoma is more uniform and circular. (White and Pharoah, First South Asia Edition) Moreover, the affected teeth are vital with intact root and lamina dura. In case of Chronic focal sclerosing osteomyelitis and Periapical osteosclerosis no radiolucent halo is present. The affected tooth is non-vital and deeply carious. Radiolucent halo present in case of cementoblastoma. (Van der Waal, 2005) Other lesion that may be included is Hypercementosis. It should be surrounded by a periodontal membrane which is usually thinner than the soft tissue capsule of cementoblastoma. Also, there is no root resorption or jaw expansion. (White and Pharoah, First South Asia Edition) In the present case, the patient was mostly asymptomatic, but the tooth was non-vital and presented text book features.

Histologic Features

The section shows irregular bone trabeculae in fibrous stroma. The trabeculae are lined by osteoblasts with no evidence of dysplastic and malignant changes.

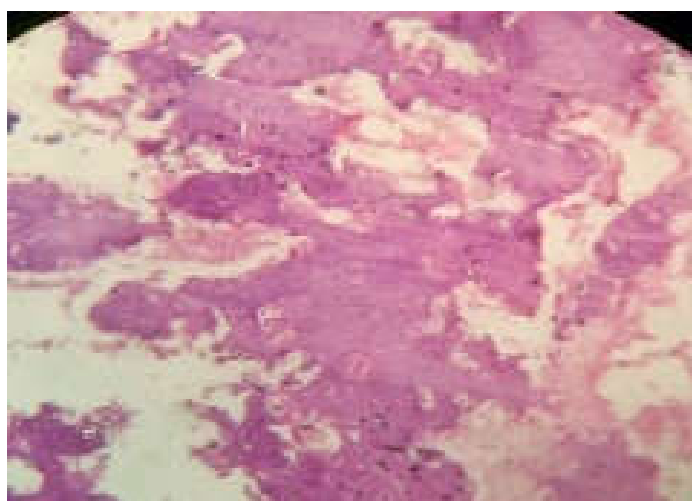
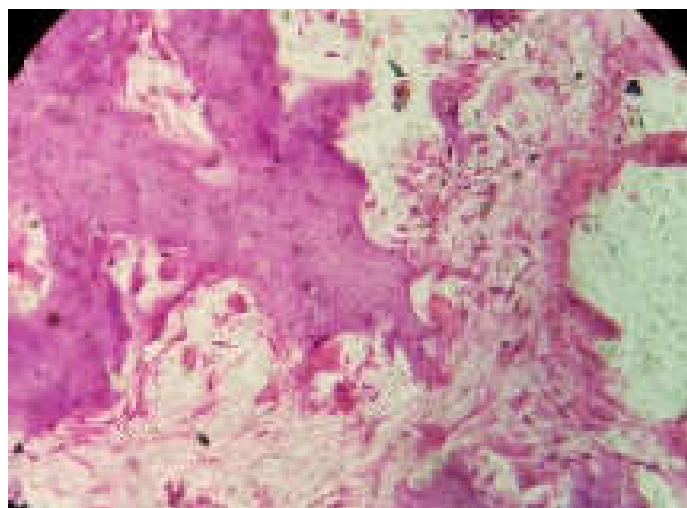


Fig 10. Histopathological Sections

Many of the cemental trabeculae in area of activity are bordered by layers of cementoblasts. Away from these trabecular surfaces, cementoclasts may be evident. (Ulmansky et al., 1994)

Conclusion

In conclusion, because of the characteristics of cementoblastoma, the CBCT images are a resource of fundamental importance for evaluation of pathognomonic features related to fusion of the tumour at the root of the tooth in the early stages of development (Amaral et al., 2012).

REFERENCES

- Amaral T. M. P. et al. 2012. The Importance of the Three-Dimensional Image in the Early Diagnosis of Cementoblastoma. *Open Journal of Radiology*, 2, 10-13
- Armağan Çalışkan et al. 2016. Benign cementoblastoma of the anterior mandible: an unusual case report. *Korean Assoc Oral Maxillofac Surg.*, 42:231-235
- Bruce R. Pynn et al. 2001. Benign Cementoblastoma: A Case Report. *Journal of the Canadian Dental Association*, Vol. 67, No. 5
- Lemberg, K., J. Hagström, J. Rihtniemi and K. Soikkonen, 2007. "Benign Cementoblastoma in a Primary Lower Molar, a Rarity," *Dentomaxillofacial Radiology*, Vol. 36, No. 6, pp. 364-366. doi:10.1259/dmfr/58249657
- Milani C. M. et al. 2012. Mandibular cementoblastoma: Case report, *Open Journal of Stomatology*, 2; 50-53
- Oral and Maxillofacial Pathology 3rd edition -Neville
- Oral Radiology Principles and Interpretation. First South Asia Edition. White and Pharoah.
- Textbook of Oral Medicine 2nd edition- Anil Govindrao Ghom
- Textbook of Oral Pathology 7th edition- Shafer
- Ulmansky, M., E. Hjørtting-Hansen, F. Praetorius and M. F. Haque, 1994. "Benign Cementoblastoma. A Review and Five New Cases," *Oral Surgery, Oral Medicine, Oral Pathology, Oral Radiology & Endodontics*, Vol. 77, No. 1, pp. 48-55.
- Van der Waal, I. 2005. "Cementoblastoma," In: L. Barnes, J. W. Eveson, P. Reichart and D. Sidransky, Eds., *World Health Organization Classification of Tumours, Pathology & Genetics: Head and Neck Tumours*, Lyon, IARC Press.
