

# Broader applications of arterial pressure wave form analysis



Mahesh Nirmalan MD FRCA PhD FFICM  
Paul M Dark FRCS PhD FFICM

## Key points

Arterial waveforms may provide a deeper insight into overall haemodynamic status.

An understanding of the principles of ventricular-vascular coupling is essential.

Vasodilatation usually causes lower systolic/diastolic pressures associated with a wide pulse pressure (PP) and delayed dicrotic notch.

Vasoconstriction is usually associated with a narrow PP.

Regular calibration is essential when pulse contour analysis is used to measure cardiac output.

Invasive arterial pressure monitoring is one of the most frequent monitoring techniques used in critically ill patients and in anaesthetized subjects in whom rapid changes in the haemodynamic status is anticipated during the peri-operative period. The arterial waveforms obtained via an indwelling arterial cannula are transduced and displayed on a monitor providing a beat-to-beat estimate of the systolic, diastolic, and mean arterial pressures (MAPs). However, it is now well established that a more detailed study of the arterial waveforms and their interactions with respiration, may provide a more informative and composite assessment of the overall cardiovascular status. Understanding of the physiological determinants that influence the shape of an arterial pressure waveform is however an absolute prerequisite if we are to successfully utilize the simple arterial waveforms to evaluate global haemodynamic status in our patients.

## Ventricular-vascular coupling: physiological determinants of the shape of an arterial waveform

The arterial waveform is produced through the dynamic interactions between the volume of blood ejected by the heart during each beat, the speed with which this volume is ejected by the heart, the ability of the vascular tree to distend and accommodate this ejected volume, the rate at which the ejected volume of blood is able to flow away from the central arterial compartment into the peripheral tissues. Figure 1 shows the aortic pressure and aortic flow recorded in an animal model showing very clearly the time lag that exists between the flow peak and the pressure peak indicating that the pressure peak is the result of a dynamic interaction between the stroke volume (SV) and the vascular wall.<sup>1</sup> When evaluating an arterial waveform it is important to recognize two very broad components

of this wave form: a steady component which is reflected by the mean pressure within the system (or the MAP); and a pulsatile component which oscillates around this mean value in a complex manner and determined by:<sup>2</sup>

- (i) SV,
- (ii) vascular capacitance, SV/VC = Systolic BP
- (iii) peripheral vascular resistance, and TPR/HR = Diastolic BP
- (iv) heart rate.

These physiological concepts, broadly referred to as ventricular-vascular coupling<sup>3</sup> should be at the very heart of our attempts in evaluating an arterial waveform. For clinical purposes, it is useful to consider that systolic pressure (SP) which is the maximum pressure recorded in the arterial tree during ventricular ejection is primarily influenced by SV and vascular capacitance—a measure of how stiff or distensible the arteries are. When vascular capacitance is constant, an increase in SV will result in an increase in SP, and for a given SV, a change in vascular capacitance will have a corresponding effect on SP. The ability to maintain pressure within the arterial tree during diastole (when the ventricle is not contracting and the aortic valves have closed) depends on the ability of the proximal arteries to recoil and continue to squeeze the blood forwards against the resistance offered by the peripheral vascular beds. These factors explain why elderly subjects have a higher SP (reduced vascular compliance associated with arteriosclerosis) and a lower diastolic pressure (inability of the stiff arteries to recoil and maintain the pressure within the compartment) and why a neonate tends to have a lower SP (because of a very compliant or distensible arterial tree) and a higher diastolic pressure (because of the compliant vessels being able to recoil well and sustain the pressure better within the arterial compartment when cardiac ejection has ceased).

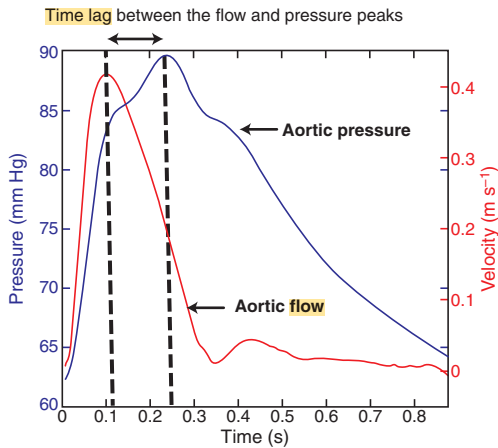
Figure 2 illustrates some of the principles inherent in ventricular-vascular coupling during an acute change in arterial capacitance associated with the application of an aortic cross

Mahesh Nirmalan MD FRCA PhD FFICM

Reader and Honorary Consultant in Intensive Care Medicine  
Manchester Royal Infirmary and University of Manchester  
Oxford Road  
Manchester M13 9WL  
UK  
Tel: +44 (0)161 276 4712  
E-mail: m.nirmalan@manchester.ac.uk  
(for correspondence)

Paul M Dark FRCS PhD FFICM

Reader and Honorary Consultant in Intensive Care Medicine  
Salford Royal Hospitals and University of Manchester  
Manchester  
Manchester  
UK

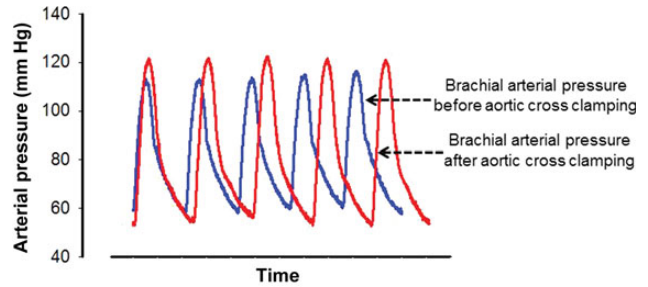


**Fig 1** The waveforms were measured simultaneously using a Sphygmocor device to measure ascending aortic pressure and phase contrast magnetic resonance angiography to measure the aortic flow waveform at the same point. The waveforms were then aligned at their maximum systolic upstroke gradient using automated software.

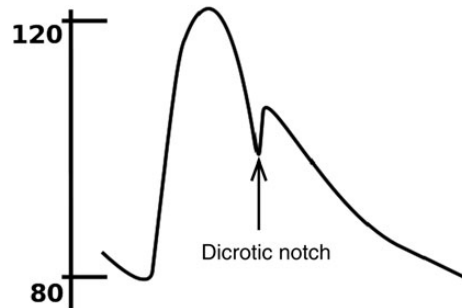
clamp. The reduction in vascular compliance associated with the aortic cross clamp decreases the ability of the vascular tree to expand during ventricular ejection resulting in a higher SP. Similarly, the reduced vascular volume also impairs the ability of the vascular tree to recoil and thereby sustaining the diastolic pressure when the ventricular ejection has ended resulting in a lower diastolic pressure. Blood flow within the arteries during diastole will be determined by the pressure gradient achieved through the elastic recoil of the proximal aorta and the downstream pressure caused by systemic vascular resistance. In the presence of vasodilatation (and a consequent reduction in peripheral vascular resistance) the elastic recoil of the aorta is able to maintain a forward flow for a longer period until a much lower diastolic pressure is achieved. Consequently, a low diastolic pressure (and therefore a possible widening of the PP) is a common feature associated with systemic vasodilatation (Fig. 3).

### The dicrotic notch

Most clinicians are familiar with the dicrotic notch seen in any typical arterial pressure waveform. The notch represents the nadir point that occurs immediately after the closure of the aortic valves and precedes the secondary dicrotic wave. The notch is frequently used as a marker for the end of the ventricular ejection period. The secondary dicrotic wave occurs as the elastic recoil of the arterial tree clamps down against a closed aortic valve causing a secondary pressure increase. As the dicrotic notch is associated with the closure of the aortic valve, it is usually seen one-third of the way down the descending limb of the pressure wave as it is at this point that the pressure gradients conducive for closure of the aortic valve (pressure in the aortic compartment > pressure in the left ventricle) is achieved. In the presence of marked vasodilatation, the above pressure gradients can only be achieved later in the cardiac cycle



**Fig 2** Brachial arterial pressure tracings in a patient undergoing abdominal aortic aneurysm repair, before (blue) and after (red) the application of the aortic cross clamp. Note that, the application of the aortic cross-clamp results in an acute reduction in vascular compliance. This is reflected by an acute increase in the SP and an acute reduction in the diastolic pressure.



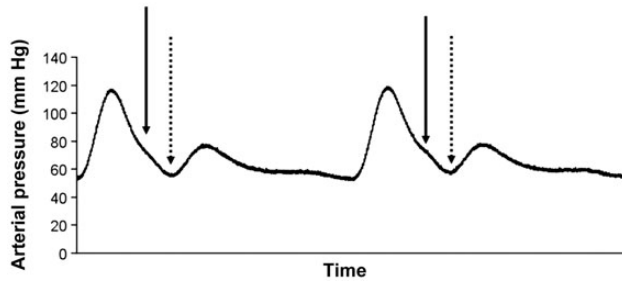
**Fig 3** Arterial pressure wave showing the dicrotic notch. Adapted from: Wikimedia Commons with acknowledgement to the original uploader of this image Benutzer:Lupino under the Creative Commons Attribution/Share-Alike License.

causing a downward shift of the dicrotic notch. This downward shift will usually be associated with a low SP, low diastolic pressure, and widened PP, which are all attributable to vasodilatation and reduced peripheral vascular resistance. This is clearly evident in Figures 4 and 5, which were recorded in two different patients with severe sepsis. Therefore, the characteristic features of significant peripheral dilatation on an arterial pressure waveform are:

- (i) low SP,
- (ii) low diastolic pressure,
- (iii) wide PP, and
- (iv) delayed dicrotic notch.

### Heart–lung interactions and fluid responsiveness

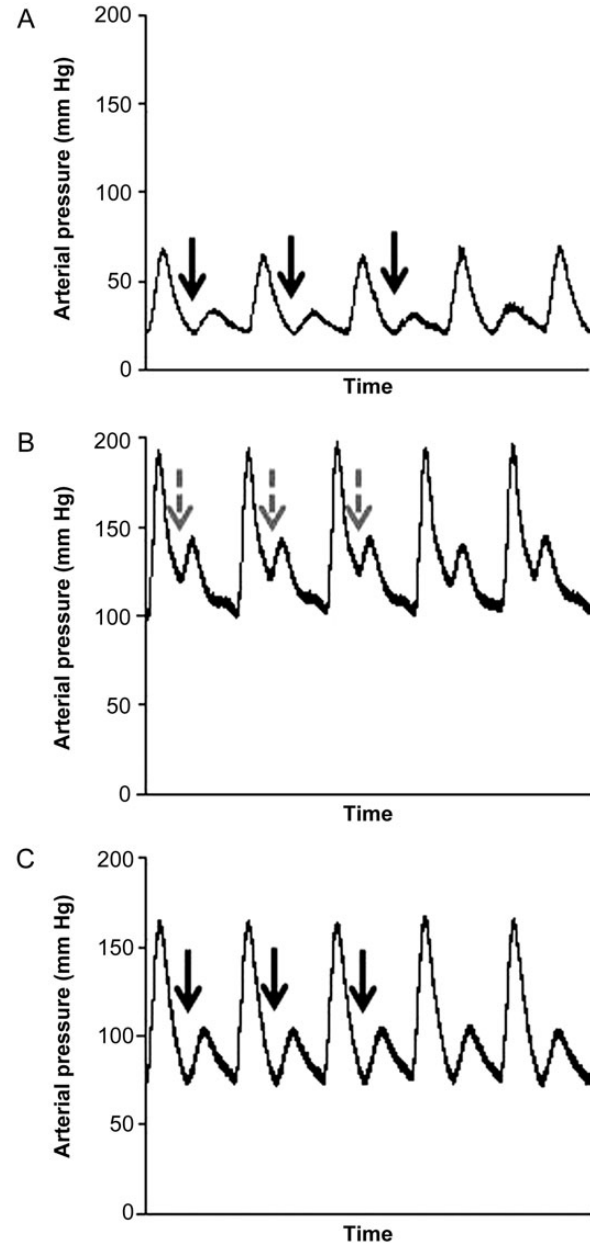
The changes in the arterial pressure waveforms in response to the intra-thoracic pressure fluctuations associated with mechanical ventilation have been used very extensively to assess the adequacy of ventricular filling and to determine whether or not a given patient will respond favourably after a fluid challenge (fluid responsiveness). Mechanical ventilation results in a cyclical increase (during inspiration) and decrease (during expiration) of intra-thoracic pressures and these pressure fluctuations in turn will alter the diastolic



**Fig 4** Arterial pressure in a patient with **severe sepsis**. Note the effects of **vasodilatation** on the position of the **dicrotic notch**. The solid arrow indicates where one would expect to see the notch (approximately one-third the way down the descending limb) and the dashed arrow shows where the notch was actually seen. The considerable **delay in the timing of the dicrotic notch** makes the **secondary dicrotic wave** appear almost as a **separate and distinct** wave. All the distinct properties of vasodilatation, reduced SP, reduced DP, widened PP, and a delayed dicrotic notch, are evident in this example.

filling of the right and left ventricles. The initial increase in intra-thoracic pressure during inspiration leads to a transient increase in venous return to the left atrium because of the squeezing effects on the pulmonary capillaries. This transient increase in venous return will be reflected by a corresponding increase in the left ventricular SV, which in turn will be reflected by a progressive increase in the arterial PP. Unlike in the left heart however, on the right side of the heart an increase in intra-thoracic pressure during the inspiratory phase will be associated with an immediate reduction in venous return. This reduction in venous return (and therefore the right ventricular SV) **feeds through** very rapidly (usually **within 4–5 beats**) to the left ventricle, and therefore, the left ventricular SV (and hence the arterial PP) will gradually decrease after the transient increase alluded to previously. This dynamic interplay between intra-thoracic pressure fluctuations, and left ventricular output (or the PP) has been known for a very long time and has been discussed extensively as heart–lung interactions within the critical care/anaesthesia literature.<sup>4</sup> The key practical points to consider in this context however are:

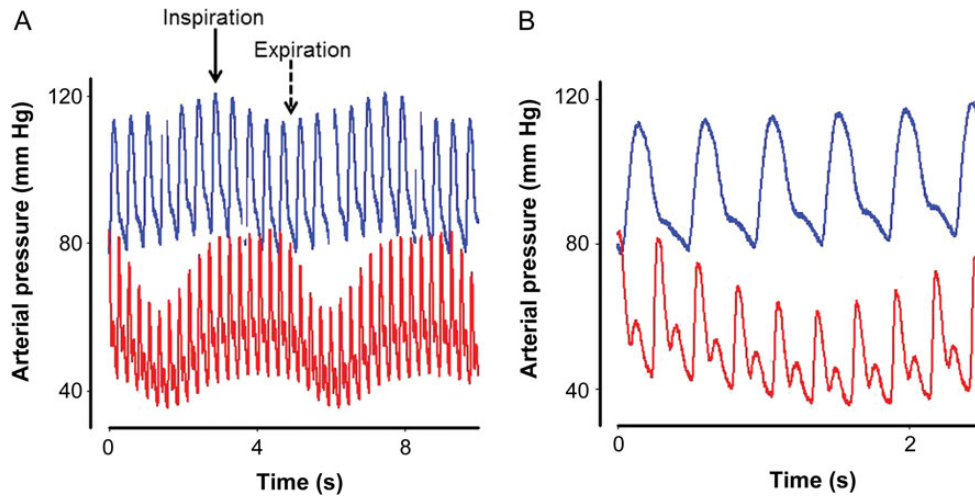
- (i) The effects of intra-thoracic pressure on venous return are **amplified in the presence of hypovolaemia**. Therefore, arterial pressure wave fluctuations are amplified in the presence of hypovolaemia: commonly referred to as an exaggerated ‘**swing**’ on the arterial pressure wave.
- (ii) In subjects with **very severe hypovolaemia**, in addition to the exaggerated ‘**swing**’ of the entire arterial pressure waveform, there would also be a **beta-to-beat variation in SV** (or PP) reflecting the **exaggerated** effects of intra-thoracic pressure on venous return under these conditions.
- (iii) The extent of the above ‘**swing**’ is very closely linked to the extent of the intra-thoracic pressure fluctuations (and therefore will be dependent on **tidal volumes**, inspiratory **pressure** and positive end-expiratory **pressure**).
- (iv) The ‘**swing**’ may be evident during **spontaneous** and mechanical ventilation though clearly the extent of the ‘**swing**’ and



**Fig 5** Arterial pressure recording in a patient with **severe sepsis** showing the **delayed dicrotic notch** (A, solid arrows) and the upward shift of the dicrotic notches during an increased dose of **vasopressors** (B, dashed arrows) and the return of the dicrotic notch to its delayed position when the high dose vasopressor infusion ended (C, solid arrows).

beat-to-beat variations will be **greater** in **mechanically** ventilated subjects in keeping with the greater intra-thoracic fluctuations during mechanical ventilation.

- (v) In the presence of low tidal volumes and **markedly reduced lung compliance** [as in patients with severe acute respiratory distress syndrome (ARDS)] **intra-alveolar pressure fluctuations** associated with mechanical ventilation may be **poorly transmitted to the intra-pleural compartment**. This may **mask** the above-



**Fig 6** Arterial pressure recording in an animal model of severe hypovolaemic shock. (A) Notice the effect of IPPV on arterial pressure during normovolaemic (blue) and hypovolaemic (red) conditions. (B) Observe the following effects of severe hypovolaemia: marked oscillation on systolic and diastolic pressure with respiration and very prominent beat-to-beat changes in PP and the area under the systolic portion of the arterial trace ( $P_{sys}$ ).

mentioned manifestations of hypovolaemia on the arterial pressure tracings: Lakhal and colleagues<sup>5,6</sup> have demonstrated that in ARDS patients mechanically ventilated with low tidal volumes and high ventilatory frequencies, PP variation may in fact be a poor indicator of both circulating volume status and volume responsiveness.

Figure 6 clearly shows the effects of IPPV on arterial pressure under normovolaemic and hypovolaemic conditions. Focus on the following points:

- (i) The normal fluctuations in the arterial pressure waveforms associated with IPPV and the transient increase in pressure during inspiration followed by a reduction during the expiratory phases.
- (ii) Note the beat-to-beat variations in PP and the ‘exaggerated swing’ in the presence of hypovolaemia.

### Pulse contour analysis and the indirect estimation of cardiac output

As explained in the previous section, the size of the pulsatile component of the arterial pressure waveform (either PP or the area under the systolic portion of the waveform  $A_{sys}$ ) are intimately linked to SV, vascular capacitance, and the systemic vascular resistance (the role of the heart rate is in fact relatively minor in this context). Under steady states and relatively stable conditions, when the vascular capacitance and the systemic vascular resistance are relatively constant, SV becomes the main determinant of both PP and  $A_{sys}$  (see Fig. 7). Under such conditions, if it is in fact feasible to measure cardiac output (CO) directly using an independent method (such as pulmonary artery thermal dilution or transpulmonary thermal dilution),<sup>7,8</sup> it then becomes possible to establish the mathematical relationship between PP,  $A_{sys}$ , and the independently measured SV. This relationship—once established through this calibration step—can

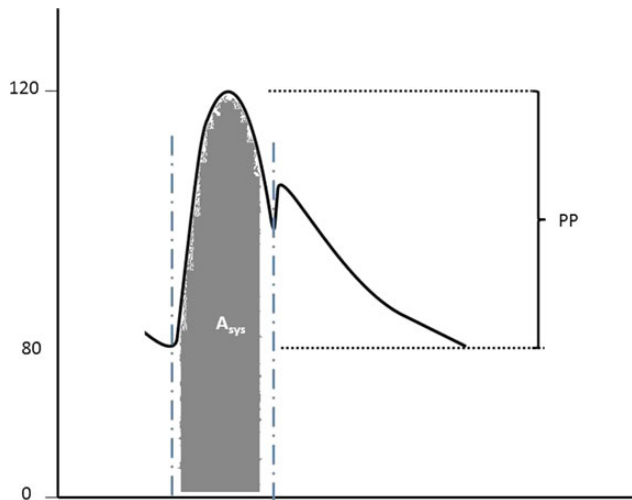
then be used to convert subsequent PP and  $A_{sys}$  to estimates of SV and therefore CO. This approach of making an indirect estimate of CO using parameters that are derived from a high-fidelity arterial trace (usually the PP and  $A_{sys}$ ) is commonly referred to as ‘Pulse contour analysis’ (PCA). It, however, has to be borne in mind that the estimates of CO obtained through PCA remains valid only as long as the mathematical relationships established between the different parameters remains accurate. In other words, should either vascular capacitance or peripheral vascular resistance change because of the onset of new sepsis, use of vasopressors, administration of regional blocks, etc. The estimates of CO obtained through PCA also becomes inaccurate unless recalibration is undertaken under the new set of circumstances. Vascular capacitance and peripheral vascular resistance are very variable in anaesthetized/critically unwell subjects and therefore monitoring devices that claim to undertake PCA without adequate provision for regular/periodic calibration can be potentially misleading and should not be accepted for clinical use in high-risk patients.<sup>9</sup>

Two commonly used systems that utilize PCA for the estimation of CO are the PiCCO (PULSION Medical Systems, Munich, Germany) and the LiDCO (LiDCO Group Plc, London, UK) systems. Both systems utilize transpulmonary indicator dilution techniques to provide periodic calibration of the arterial trace before PCA is used to derive CO. Whereas the former is based on transpulmonary thermal dilution, the latter depends on transpulmonary lithium dilution to achieve this calibration. The relative merits and validity of these systems in the clinical arena have been reviewed extensively before.<sup>10</sup>

### Pressure wave reflections

In addition to the primary SP peak and the dicrotic wave, several other smaller secondary waves are frequently evident in an arterial pressure trace (Fig. 8). Such secondary waves are usually produced



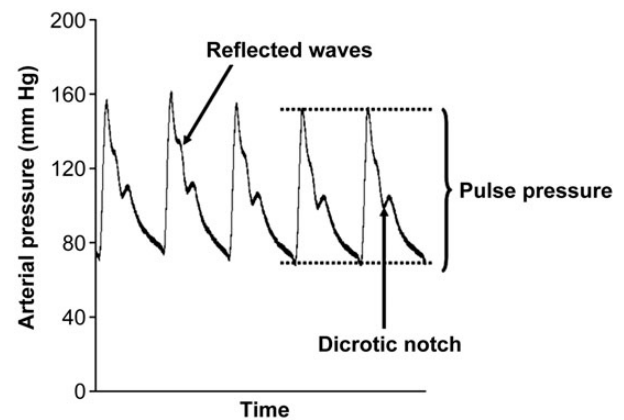


**Fig 7** Schematic figure showing PP and the area under the systolic portion of the arterial pressure waveform ( $A_{sys}$ ).

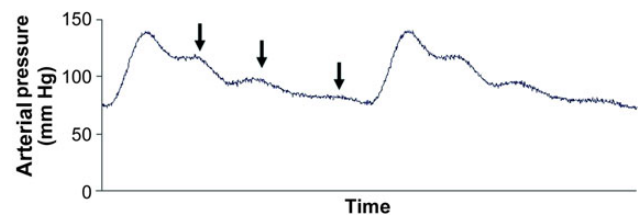
by pressure reflections that occur within the arterial system. Whereas the physiological basis of these abnormal waves has been extensively studied,<sup>1</sup> their clinical significance still remain poorly understood. However, when multiple wave reflections are evident in any given patient, an abnormal circulation—most probably associated with vasoconstriction or abnormal vessel structure must be considered as a possibility. This is clearly evident in Figure 9, which shows pressure wave reflections during systole and in diastole in a patient with severe systemic lupus disease.

### The concept of pattern recognition using the arterial pressure waveforms

Invasive arterial pressure measurements have been undertaken for several decades in operating theatres and in intensive care units. Apart from giving a beat-to-beat estimate of systolic, diastolic, and MAPs, the arterial waveforms contain a range of information that could provide a deeper insight into the overall haemodynamic status. Whereas a detailed understanding of ventricular-vascular coupling is necessary to interpret many of these changes, the arterial waveforms sometimes show very characteristic morphological features and recognizing these simple patterns could help in the management of even complex haemodynamic situations. The respiratory ‘swing’ associated with hypovolaemic status, changes in PP (or  $A_{sys}$ ) during a fluid challenge, the position of the dicrotic notch, etc. alluded to above produced typical waveforms that could be used to distinguish between the different shock states. Furthermore, the procedure is only minimally invasive and a high-fidelity arterial trace may be established with minimal delay and risks to patients. For these reasons, direct arterial pressure monitoring remains one of the most important monitoring techniques in the management of critically unwell patients both during anaesthesia and in the intensive care unit.



**Fig 8** Reflected waves in a patient undergoing surgery. Note that these waves, in general, occur during the ejection phase before the closure of the aortic valve.



**Fig 9** Multiple wave reflections—evident during systole and in diastole, in a patient with significant small vessel disease. This patient had very severe systemic lupus erythematosus (SLE) and the pressure recording was done when the patient was critically unwell because of an acute exacerbation of the disease. These multiple wave reflections are non-specific indicators of significant flow abnormalities within the arteries and may also be evident during vasoconstriction associated with hypovolaemia.

### Declaration of interest

None declared.

### References

- Dark P, Little R, Nirmalan M, Purdy J. Systemic arterial pressure wave reflections during acute hemorrhage. *Crit Care Med* 2006; **34**: 1497–505
- Pinsky MR. Use of minimally invasive hemodynamic monitoring to assess dynamic changes in cardiac output at the bedside. *Crit Care* 2011; **15**: 406
- Chantler PD, Lakatta EG, Najjar SS. Arterial-ventricular coupling: mechanistic insights into cardiovascular performance at rest and during exercise. *J Appl Physiol* 2008; **105**: 1342–51
- Pinsky MR. Heart-lung interactions. *Curr Opin Crit Care* 2007; **13**: 528–31
- Lakhal K, Ehrmann S, Boulain T. Pulse pressure variation: does lung compliance really matter? *Crit Care Med* 2012; **40**: 1691–2
- Lakhal K, Ehrmann S, Benzekri-Lefevre D et al. Respiratory pulse pressure variation fails to predict fluid responsiveness in acute respiratory distress syndrome. *Crit Care* 2011; **15**: R85
- Nirmalan M, Niranjana M, Willard T, Edwards JD, Little RA, Dark PM. Estimation of errors in determining intrathoracic blood volume using thermal dilution in pigs with acute lung injury and haemorrhage. *Br J Anaesth* 2004; **93**: 546–51

8. Nirmalan M, Willard TM, Edwards DJ, Little RA, Dark PM. Estimation of errors in determining intrathoracic blood volume using the single transpulmonary thermal dilution technique in hypovolemic shock. *Anesthesiology* 2005; **103**: 805–12
9. Sakka SG, Kozieras J, Thuemer O, van HN. Measurement of cardiac output: a comparison between transpulmonary thermodilution and uncalibrated pulse contour analysis. *Br J Anaesth* 2007; **99**: 337–42
10. Hadian M, Kim HK, Severyn DA, Pinsky MR. Cross-comparison of cardiac output trending accuracy of LiDCO, PiCCO, FloTrac and pulmonary artery catheters. *Crit Care* 2010; **14**: R212

Please see multiple choice questions 25–28.